

# ***PRENATAL MOUSE BRAIN ATLAS***

# ***PRENATAL MOUSE BRAIN ATLAS***

---

Color images and annotated diagrams of:  
Gestational Days 12, 14, 16 and 18  
Sagittal, coronal and horizontal section

Uta Schambra, Ph.D.  
Department of Anatomy and Cell Biology,  
Quillen College of Medicine  
East Tennessee State University  
Johnson City, TN 37614

Illustrations by Barbara A. Connelly





*Author*

Uta Schambra  
Department of Anatomy and Cell Biology  
Quillen College of Medicine  
East Tennessee State University  
P.O. Box 70852  
Johnson City, TN 37614  
USA  
schambra@etsu.edu

ISBN: 978-0-387-47089-4

e-ISBN: 978-0-387-47093-1

Library of Congress Control Number: 2008924612

© 2008 Springer Science+Business Media, LLC

All rights reserved. This work may not be translated or copied in whole or in part without the written permission of the publisher (Springer Science+Business Media, LLC, 233 Spring Street, New York, NY 10013, USA), except for brief excerpts in connection with reviews or scholarly analysis. Use in connection with any form of information storage and retrieval, electronic adaptation, computer software, or by similar or dissimilar methodology now known or hereafter developed is forbidden.

The use in this publication of trade names, trademarks, service marks, and similar terms, even if they are not identified as such, is not to be taken as an expression of opinion as to whether or not they are subject to proprietary rights.

While the advice and information in this book are believed to be true and accurate at the date of going to press, neither the authors nor the editors nor the publisher can accept any legal responsibility for any errors or omissions that may be made. The publisher makes no warranty, express or implied, with respect to the material contained herein.

Printed on acid-free paper

9 8 7 6 5 4 3 2 1

springer.com

To my children Eric, Kirsten, and Heidi

---

# CONTENTS

|   |         |
|---|---------|
| Preface   | ix      |
| Acknowledgements  | xi      |
| Introduction  | xiii    |
| Methods   | xv      |
| References  | xvii    |
| Index   | xix     |
| <br>  |         |
| <u>Gestational Day 12</u>   |         |
| 16 Sagittal Sections  | 1-33    |
| Enlargements: Ganglia, Inner Ear                                    | 4       |
| Pituitary   | 20      |
| 22 Coronal Sections   | 35-79   |
| Enlargements: Cranial Nerve Nuclei 1 (III, IV, VI)                  | 64      |
| Cranial Nerve Nuclei 2 (Vmo, Vsen, Vmes, VII)                       | 66      |
| 18 Horizontal Sections  | 81-117  |
| Enlargements: Cortical, Thalamic and Tectal Neuroepithelium         | 84      |
| Eyes  | 98      |
| <br>  |         |
| <u>Gestational Day 14</u>   |         |
| 20 Sagittal Sections  | 119-159 |
| Enlargements: Ganglia, Inner Ear                                    | 136     |
| Cerebellum  | 151     |
| 33 Coronal Sections   | 161-227 |
| Enlargements: Septal Area, Olfactory Bulb and Nerve                 | 168     |
| Eyes  | 184     |
| 24 Horizontal Sections  | 229-277 |
| Enlargements: Cortical Neuroepithelium, Lateral Ganglionic Eminence | 238     |
| Internal Capsule, Stria terminalis, Stria Medullaris                | 249     |
| Medulla   | 274     |
| Cervical Spinal Cord  | 276     |

|   |         |
|---|---------|
| <u>Gestational Day 16</u>                             |         |
| 16 Sagittal Sections                                  | 279-311 |
| Enlargements: Olfactory Bulb                          | 292     |
| Cerebellum  | 302     |
| 30 Coronal Sections                                   | 313-373 |
| Enlargements: Cortex, Lateral Ganglionic Eminence     | 330     |
| Hippocampus, Thalamus                                 | 350     |
| 17 Horizontal Sections                                | 375-409 |
| Enlargements: Cortex                                  | 390     |
| Cervical Spinal Cord                                  | 400     |
| <br>  |         |
| <u>Gestational Day 18</u>                             |         |
| 17 Sagittal Sections                                  | 411-445 |
| Enlargements: Hippocampus, Thalamus, Internal Capsule | 422     |
| Midline Forebrain Structure                           | 442     |
| 26 Coronal Sections                                   | 447-499 |
| Enlargements: Olfactory Bulb                          | 450     |
| Corpus Callosum, Septal Area                          | 464     |
| 15 Horizontal Sections                                | 501-531 |
| Enlargements: Cerebellum                              | 509     |
| Olfactory Bulbs                                       | 523     |

---

# ***PREFACE***

This atlas is designed to support research in neuroscience, gene manipulation, molecular biology and neurotoxicology. For researchers unfamiliar with the developing mouse brain, full sections are shown to aid in the orientation and comparison to their own sections. This atlas provides complete sets of sagittal, coronal and horizontal sections, useful when determining which plane of sectioning may be most advantageous for a particular study. For instance, sagittal and horizontal sections are well suited for a quick scan of a brain, while coronal sections provide more detailed information. In the color images the hematoxylin stain provides excellent information on neurons at different stages of development, i.e., neuroblasts in ventricular zones are darkly

stained while maturing neurons in intermediate zones are lightly stained. In contrast, developing pathways and their glial scaffolding are stained deeply pink with eosin. Regions of particular developmental interest, for example the eye, cranial nerve nuclei, or ganglia, are photographed at higher power to show different stages of development. Special attention has been given to ventricular zones, the origin of all brain structures, in order to assist tracking cells carrying a specific gene. For instance, using the bacterial artificial chromosome vector method of producing transgenic mice (Nature 425: 917-925, 2003), the development of the neurons in a gene specific nucleus could be traced back to two progenitor cell in a related ventricular zone.

---

## ***ACKNOWLEDGEMENTS***

I want to acknowledge my autistic son Eric, whose continued struggle with his developmental disabilities inspired me to study normal and abnormal brain development in order to contribute to the research into the puzzle of autism.

Also I want to thank my graduate advisors, Drs. Jean Lauder and Kathy Sulik who supported and encouraged me as an adult student to begin this work. Part of my Ph. D. dissertation resulted in the first prenatal mouse brain atlas (*Atlas of the Prenatal Mouse Brain*, Uta B. Schambra, Jean M. Lauder and Jerry Silver, Academic Press, 1992). That effort reflected my still growing knowledge of the developing mouse brain. I trust that the revisions in this new brain atlas reflect the most recent knowledge in the field of murine developmental neuroanatomy.

I am greatly indebted and thankful to my assistant, Barbara A. Connelly, for her outstanding technical work in preparation of the computer drawings from my tracings. She skillfully and patiently dealt with the never-ending stream of annotations, and prepared the manuscript and DVD for publication. I particularly appreciate her tireless and good-natured help throughout this project.

I also wish to express my gratitude to Brunhilde Tober-Meyer, DVM, MS, who out of friendship gave up golden days of retirement to tackle the unwieldy index (13,000+ entries were included). Her positive attitude towards this project and meticulous work was a great relief to me. I am very thankful for her help.

I thank the Pathology Department at East Tennessee State University for the permission to use their Shandon Veristain 24-4 automated hematoxylin and eosin stainer to process the large number of slides for this project.

This work was supported by the Dean of the Quillen College of Medicine and the Department of Anatomy and Cell Biology at East Tennessee State University and by Springer Science + Business Media, LLC.

Thanks for their encouragement and patience to the editorial and production staff at Springer, Joseph Burns, Ann Avouris, Deborah Doherty and Laurin Becker.

Last, but not least, I want to recognize the excellent works by Altman and Bayer, Paxinos et al., Jacobowitz and Abbott, and Kaufman (see reference list) whose publications helped me tremendously in my understanding of the developing rodent brain.

---

# *INTRODUCTION*

This Prenatal Mouse Brain Atlas provides comprehensive documentation of mouse brain development until shortly before birth (gestational day (GD) 19.5 average). It follows brain development from early discernable structures in embryonic heads on GD 12 and GD 14 to more clearly defined structures in fetal brains on GD 16 and GD 18. For additional information, sections are presented in the three cardinal planes, sagittal, coronal and horizontal. Genetic or toxicological manipulations may result in damaged offspring which are recognized by the mouse dams and cannibalized within the first few days. This makes studying the effects of manipulation in postnatal animals problematic, thus giving importance to a prenatal mouse brain atlas.

For ease of use, we only use unabbreviated annotations. Structures are identified with terms used in adult animals even if they are only an anlage or a precursor. Tracts are often labeled even though axons have not grown along the brightly eosin stained glial pathway.

For convenience, a DVD is provided which contains all color images, matching drawings and the drawings superimposed on the images. This DVD provides an additional tool for the researcher who may want to print specific pages for further use.

The web site, Electronic Prenatal Mouse Brain Atlas, [www.epmba.org](http://www.epmba.org), provides expanded sets of annotated GD 12 and GD 16 coronal images, which can be viewed in high magnification. The GD 12 coronal set can also be viewed as 3D presentation, and can be virtually sectioned at different planes.

---

## ***METHODS***

The widely used inbred mouse strain, C57Bl/6J (The Jackson Laboratories), was chosen for preparation of this atlas. Ten- to 20-week-old females were time-mated from 9 to 10 am. The day a copulation plug was found was considered gestational day (GD) 0. At the time of sacrifice (10 am) on GD 12, 14, 16, or 18, pregnant dams were anesthetized with an intraperitoneal injection of chloral hydrate (350 mg/kg body weight). Embryos/fetuses were removed from the uterus, and their crown-rump length (CRL) recorded. Specimens of average CRL were chosen as follows: GD 12, 8 mm; GD 14, 12 mm; GD 16, 15 mm; and GD 18, 21 mm.

GD 12 embryos were immersed in Bouin's fixative for 24 hrs, and then rinsed in 70% ethanol for 1 week. GD 14 embryos and GD 16 and GD 18 fetuses were perfused transcardially at room temperature, first with 5 ml of 0.01 M phosphate buffered saline (PBS), and then for 5 to 10 min (depending on size) with 4% paraformaldehyde in PBS using a Masterflex pump (flow rate 0.1 ml/min). Following perfusion, whole heads (GD 14) or brains (GD 16, GD 18) were immersed overnight in the same fixative at 4°C, and then washed for two days in several changes of PBS.

Specimens with similar CRL were selected and dehydrated in an ascending series of ethanols and xylenes. For embedding in Paraplast, specimens were placed on their sides for sagittal, with faces down for coronal, on their ventral surfaces for horizontal sectioning. Sagittal, coronal and horizontal sections were then cut at 10 µm with a rotary microtome. Because of sidewise rotation of the GD 12 embryos and the mesencephalic and pontine flexures, sections are not always strictly parallel to the midline or coronal. The GD 12

coronal embryo suffered forceps damage to its right cortex, which resulted in hematomas in the brain. Interestingly, these show well the still nucleated red and other developing blood cells.

Tissue sections were deparaffinized in xylenes (3 x 6 min); ethanols (100%: 3 x 1 min, 95%: 1 x 1 min); running tap water (1 min); stained with hematoxylin (Richard Allan #7211, Fisher Scientific; 9 min); rinsed with running tap water (3 min); background staining removed with acid alcohol (4 ml conc. HCl / 750 ml 70% ethanol; 2 sec); rinsed in running tap water (2 min); passed through a bluing solution (ammonia water; 2 ml NH<sub>3</sub> / 750 ml H<sub>2</sub>O; 25 sec); rinsed in running tap water (3 min) and 95% ethanol (2 x 30 sec); stained with eosin Y (Richard Allan #7111, Fisher Scientific; 6 min); dehydrated with 95% ethanol (1 x 1 min); 100% ethanol (2 x 1 min); and xylenes (2 x 3 min).

Stained sections were selected by areas of interest rather than at equal intervals. Whole sections were photographed with a Spot Insight 4 ver. 4.5.9.3 digital camera (Diagnostic Instruments) using a Leica Wild M420 macroscope. High magnification images were photographed using a Leitz Laborlux S with 4x, 10x and 20x objectives. Images were captured on a Mac Power PC G5, and then traced using Adobe Illustrator CS2 ver. 12.0.1 computer graphics systems. Structures were delineated as follows: central nervous system structures, inner ear and eye, 1 point (pt) solid; fiber tracts, 0.5 pt dashed; ganglia, olfactory and auditory epithelium, 0.75 pt solid; peripheral nerves, 1.0 pt dotted; head structures, 0.5 pt solid; vessels, 0.5 pt dashed. Color of images was adjusted, if necessary, in Adobe Photoshop CS2 ver. 8.0.

---

## *REFERENCES*

- Altman, J., and S. A. Bayer. (1995). "Atlas of the prenatal rat brain development." CRC Press, Ann Arbor.
- Altman, J., and S. A. Bayer. (1997). "Development of the cerebellar system in relation to its evolution, structure, and functions." CRC Press, Ann Arbor.
- Cajal, S. R. Y. (1995). "Histology of the nervous system of man and vertebrates, Vol. 1." Translated by Neely Swanson and Larry W. Swanson. Oxford University Press, New York.
- Cajal, S. R. Y. (1995). "Histology of the nervous system of man and vertebrates, Vol. 2." Translated by Neely Swanson and Larry W. Swanson. Oxford University Press, New York.
- Carpenter, M. B. (1976). "Human neuroanatomy," 2<sup>nd</sup> Ed. Williams and Wilkins, Baltimore.
- Haines, D. E. (2008). "Neuroanatomy: an atlas of structures, sections, and systems," 7<sup>th</sup> Ed. Lippincott Williams and Wilkins, Philadelphia.
- Jacobowitz, D. M., and L. C. Abbott. (1998). "Chemoarchitectonic atlas of the developing mouse brain." CRC Press, New York.
- Jones, E. G. (2007). "The thalamus." Cambridge University Press, Cambridge.
- Kaufman, M. H. (1992). "The atlas of mouse development." Academic Press, San Diego.
- Paxinos G. (1995). "The rat nervous system", 2<sup>nd</sup> Ed. Academic Press, San Diego.
- Paxinos, G., K., W. S. Ashwell, and I. Törk. (1994). "Atlas of the developing rat nervous system," 4<sup>th</sup> Ed. Academic Press, San Diego.
- Paxinos, G., and K. B. J. Franklin. (2001). "The mouse brain in stereotaxic coordinates," 2<sup>nd</sup> Ed. Academic Press, San Diego.
- Paxinos, G., G. Halliday, C. Watson, Y. Koutcherov, and H. Wang. (2007). "Atlas of the developing mouse brain at E17.5, P0, and P6." Academic Press, San Diego.
- Valverde, F. (1998). "Golgi atlas of the postnatal mouse brain." Springer-Verlag, New York.



---

# INDEX

---

## A

- A4-7 (Noradrenergic nuclear complex) · 60, 62, 68
- A6 (Locus coeruleus) · 140, 142, 210, 212, 256, 258, 294, 296, 366, 382-386, 424, 426, 440, 444, 490, 492, 512, 514
- A9 (Substantia nigra) · 30, 58, 90, 132, 134, 138, 140, 204, 246, 250, 252, 296, 356, 358, 360, 382-386, 392, 426, 428, 440, 444, 510-516
- A9 (Substantia nigra, compact part) · 56, 200, 202, 486
- A9 (Substantia nigra, reticular part) · 196-202, 484, 486
- A9-10 (Dopaminergic nuclear complex) · 56
- A10 (Ventral tegmental area) · 16, 18, 22, 26-30, 56-60, 90, 138, 144, 146, 152, 198-204, 250, 252, 296-300, 304, 356-364, 384, 388, 430-436, 486, 512
- Abducens nerve (VI) · 52, 126-130, 156, 188, 190, 262
- Abducens nucleus · 14, 16, 22, 60-64, 108-112, 152, 208, 264, 298, 308, 366, 396, 434-438, 520
- Accessory cuneate nucleus · *See* External (lateral) cuneate nucleus
- Accessory nerve (XI) · 216, 496
- Accessory nucleus · 276, 396, 430
- Accessory olfactory bulb · 126-130, 140, 142, 162, 164, 242, 286-296, 308, 310, 314, 428, 430, 448, 452, 516, 518
- Accumbens nucleus · 44, 100, 102, 124-130, 146, 152-156, 176, 178, 246, 284-288, 294-298, 308, 320-328, 332, 336, 402, 406, 420, 426, 428, 430, 438, 440, 444, 456-462, 466, 520, 524
- Accumbens nucleus, ventricular zone, lateral ventricle · 42
- Adenohypophysis (Pituitary, anterior lobe) · 16-22, 108, 110, 146, 148, 152-156, 196-200, 262, 482
- Adrenergic nucleus (C1) · 218
- Alveus · 288, 290, 414, 418-424, 432, 434, 474-478, 504, 506, 514
- Ambiguous nucleus · 30, 76, 114, 148, 152, 218, 220, 222, 270, 272, 370, 372, 398, 436, 496, 498, 524
- Amygdala · 6, 8, 48, 50, 90-94, 100, 186, 346, 414, 476, 478, 518
- Amygdala, subventricular zone, lateral ventricle · 346, 348
- Amygdala, ventricular zone, lateral ventricle · 346, 348
- Amygdalohippocampal area · 282, 414-418
- Amygdaloid neuroepithelium · 90, 92, 96, 98, 122, 124-128, 158, 246-254, 280-284, 346, 348, 416, 418, 520
- Anterior ampulla · 206
- Anterior amygdaloid area · 156, 282, 284, 340-344, 416, 418, 472-476
- Anterior cerebral artery · 32, 48, 94, 96, 100, 102, 172-178, 326, 456, 460, 462, 456, 472
- Anterior chamber of eye · 182, 184
- Anterior commissure · 122-130, 152-158, 178, 246, 250, 252, 280-300, 304-310, 320-328, 332-406, 416, 426, 430-444, 518
- Anterior commissure, anterior part · 126-130, 152, 154, 158, 172-176, 246, 250, 252, 284-296, 308, 320-336, 338, 340-406, 424-428, 444, 458-462, 466-470, 520
- Anterior commissure, intrabulbar part · 522
- Anterior commissure, posterior part · 122-126, 154, 156, 178, 246, 250, 280-290, 294, 300, 308, 334-402, 414-420, 424-428, 468-472, 520
- Anterior diencephalic fold · 14-18, 30, 32, 48-52
- Anterior hypothalamic area · 28, 94, 96, 104, 140, 142, 148, 258, 398, 428, 436, 474-478
- Anterior hypothalamic area, intermediate zone · 50
- Anterior hypothalamic area, ventricular zone · 50
- Anterior hypothalamic neuroepithelium · 12, 26
- Anterior hypothalamic nucleus · 100, 102, 188-192, 254, 256, 300, 304, 402, 404
- Anterior lobe (of pituitary, Adenohypophysis) · 16-24, 108, 110, 146-156, 196-200, 262, 264, 482
- Anterior olfactory nucleus · 102, 122, 130, 146, 164-168, 244, 246, 250, 286, 290,

292, 296, 304, 308, 310, 318, 406, 430, 440, 444, 526  
 Anterior olfactory nucleus, dorsal part · 286, 288, 292, 430  
 Anterior olfactory nucleus, lateral part · 286, 288, 426, 452, 454  
 Anterior olfactory nucleus, medial part · 520  
 Anterior olfactory nucleus, posterior part · 290-296, 454  
 Anterior olfactory nucleus, ventral part · 292, 428, 430, 444, 522, 524, 528, 530  
 Anterior pretectal nucleus · 16, 152, 188-196, 240, 242, 298, 300, 348-354, 380, 382, 430, 480, 482, 504, 506  
 Anterior (superior) semicircular canal · 68-74, 106, 108, 114, 116, 136, 204, 208-218, 260  
 Anterior thalamic nucleus · 16, 18, 46, 88, 92, 132, 138-148, 178, 180, 240-250, 430, 444  
 Anterior thalamic nucleus, intermediate zone · 178  
 Anterior thalamic nucleus, ventricular zone · 22, 26, 90  
 Anterodorsal hypothalamic nucleus · 306, 342, 344, 398, 430, 432, 518, 520  
 Anterodorsal preoptic nucleus · 520  
 Anterodorsal thalamic nucleus · 338, 340, 392, 472  
 Anteromedial thalamic nucleus · 298, 300, 304, 306, 310, 338, 394, 396, 432, 436-442, 472, 514, 516  
 Anteroventral hypothalamic nucleus · 306, 342, 344, 398, 402, 430, 432, 524  
 Anteroventral thalamic nucleus · 296, 338, 340, 394, 472, 474, 512, 514  
 Aqueduct · 10-16, 22-32, 56-76, 82-100, 140-158, 182, 186, 188, 194-220, 236, 240-244, 246, 250-258, 302-310, 348,

352-370, 376-380, 434, 436, 440-444, 480-484, 488, 492, 494, 502-506  
 Aqueduct, intermediate zone, inferior colliculus · 246, 250, 252  
 Aqueduct, intermediate zone, tegmentum · 60  
 Aqueduct, subventricular zone, tectum · 208  
 Aqueduct, ventricular zone, inferior colliculus · 72, 76, 210-214, 218, 254, 368  
 Aqueduct, ventricular zone, periaqueductal gray · 32  
 Aqueduct, ventricular zone, superior colliculus · 200, 210, 212, 216, 368  
 Aqueduct, ventricular zone, tectum · 14, 16, 56-62, 68, 196, 198, 208  
 Aqueduct, ventricular zone, tegmentum · 14, 16, 56-62, 68, 194-198  
 Arcuate hypothalamic nucleus · 14, 16, 54, 100, 144, 194, 196, 258, 260, 298, 300, 304-308, 352-356, 398, 402-406, 430-434, 480-484, 524-530  
 Area postrema · 142-152, 266  
 Atlas (C1 vertebra) · 220  
 Auditory cortex · 346-352, 480, 482  
 Auditory cortex, cortical plate · 350  
 Auditory cortex, lateral ventricle, intermediate zone · 350  
 Auditory cortex, marginal zone · 350  
 Auditory cortex, lateral ventricle, subventricular zone · 350  
 Auditory cortex, lateral ventricle, ventricular zone · 350  
 Auditory meatus · 202

---

**B**

B1 (Raphe pallidus nucleus) · 66, 154, 156, 210, 214-218, 224, 370, 402, 404, 498

B1-3 (Serotonergic nuclear complex) · 72-76  
 B2 (Raphe obscurus nucleus) · 14, 16, 114, 116, 154, 156, 222, 264, 266, 276, 372, 396, 398, 402, 494, 498  
 B3 (Raphe magnus nucleus) · 14, 18, 20, 62-66, 70, 102-108, 112, 202-206, 258, 262, 362, 366, 368, 404, 428, 488-494, 524-530  
 B5 (Median raphe nucleus, pons) · 18, 20, 22, 56-58, 60, 148, 152, 200-204, 208, 254-260, 360-364, 384-388, 392-396, 488, 512-518  
 B6 (Dorsal raphe nucleus, pons) · 18, 148, 152-256, 298, 306-310, 432  
 B7 (Dorsal raphe nucleus, midbrain) · 22, 24, 62, 68, 148, 152, 154, 206-212, 246, 250-254, 360, 364, 366, 380, 382, 438, 488, 490, 510  
 B8 (Median raphe nucleus, midbrain) · 204-208, 386  
 Basal nucleus of Meynert · 286, 470-474  
 Basilar artery · 14-20, 56-64, 68-74, 92-96, 100, 112-116, 198-206, 210-222, 268-272, 364-370, 486, 488  
 Basioccipital bone · 202-206, 216, 272  
 Basolateral amygdaloid nucleus · 124, 126, 280, 346, 348, 398, 412, 476-480, 518, 520  
 Basomedial amygdaloid nucleus · 158, 254, 282, 346, 348, 398, 414-420, 476-480, 524  
 Basosphenoid bone · 188-200  
 Bed nucleus of accessory olfactory tract · 284  
 Bed nucleus of stria terminalis · 14, 16, 28, 46-50, 92, 132, 134, 138-142, 152, 178-182, 246-252, 290, 294, 296, 308, 310, 338, 340, 398, 402, 428, 430, 442, 468-472, 516-520

Blood vessel · 40, 42, 66, 84, 86, 330, 442  
 Brachium of inferior colliculus · 12, 88,  
 204, 214, 242-246, 254, 294, 296, 360-  
 366, 376, 424, 426, 484-490, 502-506  
 Brachium of superior colliculus · 12, 54,  
 56, 82, 86, 88, 132, 134, 144, 154-158,  
 192-200, 232-236, 240, 294, 296, 300,  
 348-364, 378, 422, 424, 428, 442, 444,  
 480, 482, 504, 506

---

**C**

- C1 (Adrenergic nucleus) · 218  
 CA1 (Hippocampal region) · 422, 474-478  
 CA2 (Hippocampal region) · 422, 474-478  
 CA3 (Hippocampal region) · 422, 476, 478  
 CA4 (Hippocampal region) · 478  
 Cajal-Retzius cells · 390  
 Caudate-putamen · *See also* striatum · 8-12,  
 32, 122-1126, 152-158, 170-174, 242,  
 244, 282-288, 318-342, 388, 392-398,  
 414-428, 458-462, 466-480, 510-518  
 Cavernous sinus · 6-10, 28-32, 52-62,  
 68-72, 104-108, 112  
 Cavity of lens vesicle · 50, 96, 98, 110  
 Cavum of septum pellucidum · 466, 512  
 Central amygdaloid nucleus · 126,  
 188-192, 252, 282, 344, 346, 396,  
 398, 414-418, 476-480, 518, 520  
 Central canal · 78, 158, 226, 272-276,  
 394-400, 428  
 Central canal, ventricular zone, spinal cord  
 · 16, 428  
 Central gray · *See* Periaqueductal gray  
 Central lateral thalamic nucleus · 88  
 Central medial thalamic nucleus · 18, 28,  
 90, 140-144, 180, 182, 186-190, 240-  
 244, 300, 308, 310, 342, 344, 388, 392,  
 432-436, 440, 474-478, 480, 512, 514  
 Central medial thalamic nucleus,  
 subventricular zone, third ventricle ·  
 180, 182, 186  
 Central medial thalamic nucleus,  
 ventricular zone, third ventricle · 92,  
 180, 182, 186  
 Central tegmental tract · 32, 240, 242, 378  
 Central thalamic nucleus · *See* Rhomboid  
 thalamic nucleus  
 Cephalic flexure · *See* Mesencephalic  
 flexure  
 Cerebellar neuroepithelium · 2, 6-18,  
 22-32, 68  
 Cerebellar nuclear neurons, migrating · 12,  
 26-32, 260, 382  
 Cerebellum · 130-138, 146, 150-158,  
 210-220, 258-262, 284-290, 296-310,  
 366-370, 380-386, 414-420, 424-440,  
 444, 490-498, 504-512  
 Cerebellum, intermediate zone, fourth  
 ventricle · 74  
 Cerebellum, rhombic lip · 210  
 Cerebellum, ventricular zone, fourth  
 ventricle · 74, 76, 150, 214, 216, 220,  
 368, 370  
 Cerebral peduncle · 14-18, 22-32, 54-60,  
 64, 88-94, 132, 140, 144, 148, 194-202,  
 246, 250, 252-258, 288, 296, 342-348,  
 352-360, 384, 386, 392-396, 422-428,  
 440, 476-486, 510-520  
 Cervical flexure · 14, 22  
 Cervical spinal cord · 400  
 Cervical spinal nerves · 220  
 Choroid fissure · 100, 112  
 Choroid plexus · 8-18, 22-32, 42, 78, 110,  
 112, 126-132, 136-158, 174-178, 182,  
 214-220, 236, 240, 248, 262, 264, 284,  
 286, 298-306, 328-340, 344, 350, 368,  
 370, 382-388, 394, 414-418, 430, 432,  
 436-440, 468-472, 492-498, 504,  
 510-516  
 Cingulate cortex · 84-90, 132, 134, 162,  
 164, 166, 170, 172, 174, 176, 178, 234,  
 236, 240, 304, 306, 316-328, 332, 334,  
 376-380, 434-442, 454-462, 466-470,  
 502-506, 514  
 Cingulate cortex, marginal zone · 24  
 Cingulate cortex, ventricular zone, lateral  
 ventricle · 22, 38, 40  
 Cingulum · 318-328, 332, 334, 456-472,  
 502-506, 514  
 Claustrum · 120, 164, 282, 284, 318-328,  
 334-338, 414-420, 454-462, 466-470  
 Cochlear duct · 4-10, 26-30, 60, 62, 68,  
 108, 112-116, 132-146, 158, 202-210,  
 264-270  
 Cochlear nerve (VIII) · 4, 28, 62, 68, 108,  
 114, 116, 144, 266, 268  
 Cochlear neuroepithelium · 2-6, 32, 68, 70,  
 72, 100-112, 132, 136, 140, 206-210,  
 214, 216, 262, 296, 392, 414, 492, 494  
 Cochlear (spiral) ganglion · 4-8, 28, 30, 62,  
 68, 106-114, 136-144, 158, 204-210,  
 264-270  
 Commissure of inferior colliculus · 502  
 Commissure of superior colliculus ·  
 140-146, 194, 196, 200, 204, 234, 308,  
 354-364, 430, 438, 484-492, 502  
 Cornea · 178-186, 256-260  
 Corneal epithelium · 98, 108, 254  
 Corneal stroma · 98  
 Corpus callosum · 316-328, 332, 414-418,  
 424, 430, 468, 470, 510, 514, 516  
 Corpus callosum, anterior forceps ·  
 316-326, 420, 430-434, 454-460, 502, 504  
 Corpus callosum, genu · 326, 328, 332,  
 396, 436, 440, 444, 460-466, 504, 506,  
 510, 512

Corpus callosum, posterior forceps · 416-420, 426, 472, 474, 502-506  
 Corpus callosum, splenium · 432, 442, 444  
 Cortex, intermediate zone, lateral ventricle · 120-124, 138, 144-148, 152-158, 164, 166, 172-178, 230-238, 280, 284-292, 304, 306, 316-340, 376, 378, 382, 390, 422, 454-462, 466, 502-506  
 Cortex, subventricular zone, lateral ventricle · 28, 120-124, 130, 146, 158, 164, 166, 172-176, 230-238, 280, 284, 288-292, 306, 310, 318, 320-340, 350, 376, 378, 382, 384-390, 394, 398, 404, 420, 428, 456, 462-468, 504, 506  
 Cortex, ventricular zone, lateral ventricle · 6, 8, 28, 120-124, 130, 144-148, 152-158, 164, 166, 172-176, 230-238, 280, 284, 288, 290, 304, 306, 318-340, 376, 378, 382-390, 394, 398, 404, 406, 438, 444, 456, 462-466, 502-506, 520  
 Cortical amygdaloid nucleus · 128, 130, 188-192, 254, 282, 344-348, 352, 398, 402, 404, 412-418, 476-482, 524-530  
 Cortical neuroepithelium · 6-10, 82-86, 120-130, 146, 148, 152-158, 172, 236, 238, 280-288, 306, 318-328, 332-340, 390, 396, 434, 456-468  
 Cortical plate · 120-124, 130, 134, 138, 144-148, 152-158, 162-166, 172-176, 230-238, 280, 284-292, 304, 306, 316-340, 350, 376-394, 414, 416, 452-462, 466, 468, 502-506  
 Crista (of anterior ampulla) · 206  
 Crista (of posterior ampulla) · 212-216  
 Cuneate fasciculus · 156, 224, 226, 270, 272, 276, 298, 372, 400, 426, 434, 436  
 Cuneate nucleus · 156, 224, 268, 270, 274, 276, 298, 372, 426, 434-438

---

**D**

Decussation of superior cerebellar peduncle · 64, 152, 306, 362, 436, 488, 510, 512  
 Dentate gyrus · 130, 154, 156, 248, 290, 294, 298, 342-354, 384, 388, 420, 432, 434, 472-482, 506, 510, 512  
 Dentate gyrus, dorsal part · 424  
 Dentate gyrus, neuroepithelium · 250  
 Dentate gyrus, ventral part · 424  
 Dentate (lateral) nucleus · 138, 140, 158, 212, 214, 368, 382, 386, 416-420, 440, 444, 490-496, 508, 510  
 Dentatothalamic fasciculus · 140, 188, 200  
 Diagonal band of Broca · 174, 244, 326, 332-336, 460, 462, 466, 520  
 Dopaminergic nuclear complex (A9-10) · 56  
 Dorsal cochlear nucleus · 110, 136, 212, 214, 262, 264, 290, 368, 388, 392, 414-420, 444, 494  
 Dorsal diencephalic sulcus · 190, 348  
 Dorsal endopiriform nucleus · 120, 282, 318-328, 332-340, 412-420, 456-462, 466, 468-474, 478  
 Dorsal funiculus · 10, 274, 388, 392-400  
 Dorsal horn · 10, 156, 226, 396-408, 420, 424-428  
 Dorsal lateral geniculate nucleus · 12, 52, 54, 86, 130, 154, 156, 188-192, 236, 242, 290, 294, 342-346, 350, 378-386, 422-426, 474-480, 506, 510  
 Dorsal lateral olfactory tract · 126, 128, 140, 142, 162, 286, 288, 292, 294, 308, 310, 406, 448, 452, 518  
 Dorsal longitudinal fasciculus · 376, 504  
 Dorsal motor nucleus of vagus · 14, 22, 78, 116, 154, 158, 220, 268, 270, 306, 308, 372, 392, 394, 428, 430, 498, 516

Dorsal nucleus of lateral lemniscus · 62, 68, 206, 208-212, 244, 256, 294, 296, 362, 364, 366, 382, 384, 424, 426, 488, 512, 514  
 Dorsal premammillary nucleus · 482  
 Dorsal raphe nucleus, midbrain (B7) · 22, 24, 62, 68, 148, 152, 154, 206-212, 246, 250-254, 360, 364, 366, 380, 382, 438, 488, 490, 510  
 Dorsal raphe nucleus, pons (B6) · 18, 148, 152-256, 298, 306-310, 432  
 Dorsal root ganglion · 78, 152, 222, 224  
 Dorsal tegmental bundle · 442  
 Dorsal tegmental nucleus · 28, 382-386, 430, 432, 438, 490, 492, 510  
 Dorsal thalamus, neuroepithelium · 14-18, 28, 30, 32, 44-52, 88  
 Dorsomedial hypothalamic nucleus · 24, 52, 96, 100, 102, 194, 256, 258, 298, 304-308, 346, 348, 352, 398, 430-434, 480, 524  
 Dorsomedial tegmental area · 490  
 Dorsomedial thalamic nucleus · *See* Mediodorsal thalamic nucleus

---

**E**

Ear canal · 266-270  
 Enamel organ (lower incisor) · 186, 188  
 Enamel organ (lower molar) · 190, 192  
 Enamel organ (upper incisor) · 172, 174  
 Enamel organ (upper molar) · 186-192  
 Endolymphatic duct · 76, 108, 110, 114, 136, 212-218, 220  
 Entopeduncular nucleus · 130, 186, 252, 290, 294, 296, 424, 474, 518  
 Entorhinal cortex · 6, 8, 52, 100, 122, 126, 194, 196, 280-286, 352-358, 392, 394, 412-418, 482-486

Ependyma · 422, 508  
 Epidural space · 222  
 Epithalamic neuroepithelium · 30, 44-48, 50, 52, 84, 178, 234  
 Epithalamus · 16, 18, 22, 24, 32, 42, 134, 438, 440, 478, 506, 510  
 Epithalamus, ventricular zone, third ventricle · 22, 24, 42, 134  
 Esophagus · 210-214, 216, 272  
 Eustachian tube · 26, 28, 56, 58, 112-116, 202, 266-270  
 External auditory meatus · 204, 206, 210, 212, 266-270  
 External capsule · 122, 124, 148, 152-158, 162-166, 170-180, 190, 240-244, 280-286, 324, 326-340, 388, 392-398, 412-420, 424, 458-462, 466-476, 480, 510-520  
 External granular layer (of cerebellum) · *See* External germinal layer (of cerebellum)  
 External germinal layer (of cerebellum) · 100-104, 110, 132, 134, 138, 144, 146, 150, 206, 210-220, 258, 260, 286-290, 294-310, 366-370, 380-384, 414-420, 424, 426, 432-440, 444, 490-498, 508, 510, 512  
 External (lateral) cuneate nucleus · 116, 156, 266, 268, 372, 420, 440, 444, 496  
 External medullary lamina · 14-18, 30, 48-52, 88, 132, 134, 140-144, 148, 152, 180, 182, 186, 244, 290, 294, 296, 310, 342-348, 388, 392, 394, 422-430, 440, 442, 474-480, 510-516  
 External plexiform layer · 168, 286, 290, 292, 300, 304, 314, 316, 428, 432, 434, 438, 440, 448, 450, 452, 522, 524  
 Extreme capsule · 242, 394, 516, 518  
 Eye · 50, 96, 120, 158

Eye, outer layer · 176  
 Eyelid · 98, 254, 258, 260

---

**F**

Facial nerve (VII) · 2-10, 26-32, 60-64, 68, 108-116, 128, 130, 136, 142-148, 156, 158, 200-214, 262-268, 288, 290, 294, 296, 310, 364, 366, 396, 416, 418, 426, 438, 488, 490, 518, 520  
 Facial nerve (VII), genu · 60-64, 112, 152, 154, 206, 208, 262, 264, 298, 308, 366, 434, 492  
 Facial nucleus · 10, 12, 22, 24, 66-72, 112, 144-148, 208-214, 266-270, 294, 366, 368, 402, 404, 418, 420, 434-438, 490-494, 524, 530  
 Facial nucleus, lateral part · 402, 404, 526, 528  
 Facial nucleus, medial part · 402, 404, 526, 528  
 Facial nucleus, ventricular zone, fourth ventricle · 66, 490, 518  
 Fasciculus retroflexus · 16, 18, 30, 48-56, 86, 88, 132, 134, 138-148, 180, 182, 186, 190-198, 236, 240-246, 250, 300, 304, 306, 310, 342-348, 352-362, 384, 386, 432-444, 474-486, 510, 512  
 Fastigial (medial) nucleus · 148, 150, 156, 214, 216, 258, 300-304, 370, 428, 430, 494-498, 508, 510  
 Fimbria · 88, 128-132, 172, 174, 178, 240, 286-290, 298, 310, 336-352, 388, 392, 394, 420, 422, 470-474, 478-482, 510-514  
 Floor of fourth ventricle · 18, 396, 520  
 Floor plate · 224, 274  
 Forel's field · 152, 346, 352, 438, 480, 512, 518  
 Fornix · 140, 172, 174, 182, 190, 194, 196, 242, 254, 294, 298, 300, 304-308, 336-340, 344, 346, 352-358, 388, 392, 396, 398, 402, 432-436, 464, 472, 474, 478, 480-484, 512, 514, 520, 526  
 Fornix, column · 252, 332, 336, 338, 398, 436, 468, 470, 516  
 Fornix, postcommissural · 430-442, 518, 520  
 Fornix, precommissural · 442  
 Fourth ventricle · 2-32, 60-78, 96, 100-116, 130-140, 144-158, 206-224, 258-372, 384, 386, 388, 392-396, 414-418, 430, 432, 436, 492-496, 508-520  
 Fourth ventricle, intermediate zone, cerebellum · 74  
 Fourth ventricle, ventricular zone · 490, 518  
 Fourth ventricle, ventricular zone, cerebellum · 74, 76, 150, 214, 216, 220, 368, 370  
 Fourth ventricle, ventricular zone, medulla · 14, 18, 78, 150, 304  
 Fourth ventricle, ventricular zone, pons · 58, 60-66, 366  
 Fourth ventricle, ventricular zone, precerebellar nuclei · 368  
 Fourth ventricle, ventricular zone, vestibular nuclei · 74, 76  
 Frontal cortex · 14-18, 28, 30, 82-92  
 Frontal cortex, marginal zone · 40, 44, 48  
 Frontal cortex, ventricular zone, lateral ventricle · 38, 42, 84, 162  
 Frontopolar cortex · 448, 452  
 Frontopolar cortex, marginal zone · 36  
 Frontopolar cortex, ventricular zone, lateral ventricle · 36  
 Fusion of palatal shelves · 180, 182, 186-192



**G**

Ganglion cell layer · 122, 180, 184, 256, 258  
 Gasserian ganglion · *See* Trigeminal (semilunar) ganglion  
 Geniculate ganglion · 2-6, 32, 60, 62, 108, 110, 114, 124, 132, 136, 200-210, 264  
 Germinal trigone · 104, 110, 132, 134, 138, 144, 146, 150, 154, 206-216, 258, 260, 294-310, 368, 370, 388, 414-418, 514, 516  
 Gigantocellular reticular nucleus · 22, 24, 66, 70, 72, 110-116, 154, 208-212, 216, 218, 264-268, 272, 298, 306-370, 396, 426-434, 490-496  
 Glial palisades · 154, 304-308, 430  
 Glial wedge · 324-328, 458-468, 510  
 Globus pallidus · 12, 28-32, 90-96, 126, 128, 156, 180, 182, 242-248, 284, 286, 338-342, 392-396, 416-420, 424, 470-476, 514-518  
 Glomerular layer · 138, 168, 286, 290, 292, 296, 300, 314, 316, 428, 434, 438, 440, 444, 448, 450, 452, 516-524  
 Glossopharyngeal nerve (IX) · 2-6, 26, 30, 68-72, 114, 142, 144, 212, 214, 266, 268, 496  
 Gracile fasciculus · 158, 226, 272, 276, 400, 428, 430  
 Gracile nucleus · 158, 224, 268, 270-274, 276, 372, 428, 430  
 Granular layer (of dentate gyrus) · 290, 422, 472, 484, 506, 512  
 Granular layer (of olfactory bulb) · *See* Granule cell layer (of olfactory bulb)  
 Granule cell layer (of dentate gyrus) · *See* Granular layer (of dentate gyrus)  
 Granule cell layer (of olfactory bulb) · 162-166, 250, 286, 290-294, 300, 304,

308, 314, 428-434, 440, 448-452, 518-524, 528

**H**

Habenular commissure · 48, 50, 138, 180, 182, 232, 234, 300, 304-308, 342, 344, 382, 438, 440-474, 476, 478, 504  
 Habenular neuroepithelium · 82-86  
 Habenular nuclei · 42  
 Habenular recess · 84, 232, 234, 384-388, 392, 474-478  
 Habenulointerpeduncular tract · *See* Fasciculus retroflexus  
 Hair follicle · 192  
 Hematoma · 38-48, 52, 74, 82  
 Hippocampal fissure · 288, 422, 424  
 Hippocampal formation · 130, 290, 350, 420, 432, 476, 478, 484, 510  
 Hippocampal neuroepithelium · 10, 12, 32, 86-92, 126, 128, 172, 250, 280, 282-288, 350, 388  
 Hippocampal region (CA1) · 422, 474-478  
 Hippocampal region (CA2) · 422, 474-478  
 Hippocampal region (CA3) · 422, 476, 478  
 Hippocampal region (CA4) · 478  
 Hippocampus · 42-48, 130, 132, 140, 142, 146, 152-158, 176-182, 186, 190-194, 232-236, 240, 244, 246, 252, 254, 310, 334-348, 352, 354, 382-388, 392, 394, 412-422, 428, 434, 442, 472-482, 504, 506, 512, 514  
 Hippocampus, dorsal part · 420, 424  
 Hippocampus, intermediate zone · 42, 130, 142, 146, 152-158, 174-182, 186, 190-194, 232-236, 240, 252  
 Hippocampus, subventricular zone · 130, 232, 234  
 Hippocampus, ventral part · 130, 420

Hippocampus, ventricular zone · 18, 22, 26, 28, 40-48, 130, 142, 146, 154-158, 174-182, 186, 190-194, 232-236, 240, 244, 246, 252, 254, 290, 338  
 Hook bundle · 216, 218, 258, 368  
 Horizontal (lateral) semicircular canal · 126, 128, 130, 136, 206-214, 264-270  
 Hyaloid artery · 184  
 Hyaloid cavity · 98, 120, 122, 256  
 Hyaloid vascular plexus · 50, 98, 108, 110, 120, 122, 184, 254, 256  
 Hypoglossal nerve (XII) · 6, 8, 12, 14, 22-28, 32, 76, 132, 138, 142-148, 152, 194  
 Hypoglossal nucleus · 12-16, 76, 78, 116, 156, 158, 222, 224, 270, 272, 304, 306, 372, 392, 394, 428, 430, 498, 518, 520  
 Hypothalamic neuroepithelium · 12-16, 24, 26, 92, 148, 152  
 Hypothalamus · 304, 306, 346, 356, 428-440, 444, 484  
 Hypothalamus, ventricular zone, third ventricle · 194, 196, 306

**I**

Indusium griseum · 328, 332, 334, 460-468  
 Inferior alveolar nerve (V<sub>3</sub>) · 194  
 Inferior cerebellar peduncle · 4-8, 30, 32, 62, 68-76, 100-116, 134-142, 150, 156, 158, 206-220, 258-266, 286-290, 296-300, 366-372, 382, 386, 388, 392, 394, 416, 418, 424, 440, 444, 490, 494, 496, 508, 510, 516  
 Inferior cervical ganglion · 146, 152  
 Inferior colliculus · 10-18, 22-32, 70, 74, 94, 96, 100, 134, 138-142, 148-158, 210, 212, 214, 216, 218-222, 242, 244, 252-256, 294-310, 360-370, 376, 378, 380, 424-440, 444, 488-498, 502-506

- Inferior colliculus, intermediate zone, aqueduct · 246, 250, 252
- Inferior colliculus, neuroepithelium · 302, 506
- Inferior colliculus, ventricular zone, aqueduct · 72, 76, 210-214, 218, 254, 368
- Inferior facial ganglion · *See* Geniculate ganglion
- Inferior glossopharyngeal (petrosal) ganglion · 2, 4, 26-30, 114, 142, 144, 208-212
- Inferior medullary velum · 2-14, 18, 22, 32, 70-78, 112-116, 216, 222, 224, 264-268
- Inferior oblique muscle · 122, 124
- Inferior olive · 72-76, 114, 116, 154-158, 220, 222, 272, 274, 370, 372, 398, 400, 402, 424-430, 496, 498, 526-530
- Inferior rectus muscle · 122-126, 156, 180-184
- Inferior vagal (nodose) ganglion · 2-6, 142, 146, 214, 272
- Inferior vestibular nucleus · 10, 28, 30, 76, 114, 116, 148, 152, 216-222, 262, 264, 266, 298, 368, 370, 426, 494-498
- Infralimbic cortex · 92, 134, 318, 320, 458
- Infundibular recess · 18, 22, 24, 50, 102-106, 148, 196, 260, 300, 406, 482, 528, 530
- Infundibular stalk · 198
- Infundibulum · 152, 408
- Insular cortex · 8, 10, 38, 40, 120, 162, 166, 170, 174-178, 280-284, 316-328, 332-340, 412, 414, 416-424, 454, 456-462, 466, 468
- Interfascicular nucleus · 308, 386, 512
- Interhemispheric fissure · *See* Longitudinal cerebral fissure
- Intermediate gray (of spinal cord) · 12, 156, 158, 224, 400, 402, 408, 426
- Intermediate hemisphere (of cerebellum) · *See* Paravermis
- Intermediate horn · 400
- Intermediate lobe (of pituitary) · 20, 106-110, 148, 152, 262
- Intermediate nerve · 108
- Intermediate nucleus of lateral lemniscus · 488
- Intermediate reticular nucleus · 370, 496
- Intermediate subpallial sulcus · 44, 46, 92, 100, 144, 174, 240-246
- Intermediate zone, anterior hypothalamus · 50
- Intermediate zone, anterior thalamic nucleus · 178
- Intermediate zone, aqueduct, inferior colliculus · 246, 250, 252
- Intermediate zone, aqueduct, tegmentum · 60
- Intermediate zone, fourth ventricle, cerebellum · 74
- Intermediate zone, hippocampus · 42, 130, 142, 146, 152-158, 174-182, 186, 190-194, 232-236, 240, 252
- Intermediate zone, lateral ventricle, auditory cortex · 350
- Intermediate zone, lateral ventricle, cortex · 120-124, 138, 144-148, 152-158, 164, 166, 172-178, 230-238, 280, 284-292, 304, 306, 316-340, 376, 378, 382, 390, 422, 454-462, 466, 502-506
- Intermediate zone, lateral ventricle, lateral ganglionic eminence · 40-48, 88, 172
- Intermediate zone, lateral ventricle, medial ganglionic eminence · 46, 176, 178
- Intermediate zone, lateral ventricle, pallidum · 46
- Intermediate zone, lateral ventricle, piriform cortex · 38
- Intermediate zone, lateral ventricle, septal area · 24, 44, 168
- Intermediate zone, neural retina · 122, 254, 258
- Intermediate zone, olfactory ventricle, olfactory bulb · 126, 140, 144, 146, 250
- Intermediate zone, third ventricle, lateral preoptic area · 48
- Intermediate zone, third ventricle, medial preoptic area · 46
- Intermediate zone, third ventricle, paratenial thalamic nucleus · 178
- Internal arcuate fibers · 274, 276
- Internal capsule · 10, 50, 52, 92, 96, 100-106, 122-134, 138, 154-158, 170, 172, 180, 182, 186-192, 242-254, 282, 284-290, 294, 320-346, 392, 394, 396, 398, 414-426, 458-462, 466-480, 510-518
- Internal carotid artery · 8-12, 26, 30, 32, 50, 52, 56-62, 68, 90-96, 100-112, 156, 188, 190, 194, 196, 200-210, 214, 216, 260, 272, 478
- Internal jugular vein · 4, 6, 26, 30, 32, 212-218, 272
- Internal medullary lamina · 348
- Internal plexiform layer · 286, 292, 300, 308, 314, 428, 440, 444, 448-452, 516, 518, 522, 524
- Interpeduncular fossa · 24, 56, 198, 202, 252, 310, 358, 360, 362, 386
- Interpeduncular nucleus · 16, 22, 24, 56, 90, 148, 250, 252, 304, 306, 310, 362, 384, 386, 432-438, 486, 512
- Interpeduncular nucleus, caudal part · 198
- Interpeduncular nucleus, rostral part · 196
- Interposed nucleus · 146, 158, 214, 218, 296, 368, 370, 382, 386, 420, 424, 426, 438, 494-498, 508, 510
- Interstitial nucleus · 146, 200, 310, 356, 358, 382, 384

Interventricular foramen · 16, 18, 26,  
42-46, 92-96, 100, 138, 144, 146,  
176-180, 244, 246, 250, 298, 304, 306,  
396, 514, 516  
Intraretinal (subretinal, ventricular) space  
(of eye) · 2, 50, 98, 120, 188, 260  
Intrinsic muscle · 180  
Isthmal canal · 70, 72  
Isthmal neuroepithelium · 212, 214  
Isthmal recess · 254-260  
Isthmus · 12, 16, 18, 22-30, 62, 68, 70, 94,  
96, 150, 156, 210, 254-262, 290, 294,  
492

---

**J**

Jacob's organ · *See* Vomeronasal organ  
Jugular (superior vagal) ganglion · *See*  
Superior vagal (jugular) ganglion

---

**L**

Lacunosum-moleculare layer · 416, 418,  
422, 504, 506, 510-514  
Lamina terminalis · 18, 22, 26, 42, 44,  
84-92, 106, 176, 336, 528, 530  
Laryngopharynx · 204-208  
Larynx · 206-212, 272  
Lateral amygdaloid nucleus · 124, 190,  
192, 250, 280, 344, 346, 394-398, 412,  
476-480, 518  
Lateral cuneate nucleus · *See* External  
(lateral) cuneate nucleus  
Lateral (dentate) nucleus (of cerebellum) ·  
138, 140, 158, 212, 214, 368, 382,  
386, 416-420, 440, 444, 490-496,  
508, 510  
Lateral dorsal thalamic nucleus · 14, 32,  
46, 48, 138, 154, 180, 182, 186, 240,

294, 296, 342-386, 424-430, 474-480,  
510  
Lateral dorsal thalamic nucleus, ventricular  
zone, third ventricle · 86  
Lateral funiculus · 156, 224, 226, 398, 400,  
402, 420  
Lateral ganglionic eminence · 8, 10, 12, 32,  
44-48, 90-96, 126-130, 144-148, 152-  
158, 170-178, 236-242, 288, 294, 296,  
310, 320, 322, 324, 326, 328, 332-340,  
388-396, 458, 460, 462, 466  
Lateral ganglionic eminence, intermediate  
zone, lateral ventricle · 40-48, 88, 172  
Lateral ganglionic eminence,  
subventricular zone, lateral ventricle ·  
40-48, 88, 172, 176, 178, 236, 238, 290,  
320-326, 328, 330-340, 462  
Lateral ganglionic eminence, ventricular  
zone, lateral ventricle · 38-48, 88,  
172-178, 236, 238, 290, 320-340  
Lateral habenular nucleus · 16, 18, 30,  
44-48, 132, 144, 180, 182, 236, 300,  
304, 310, 342, 344, 384-388, 392,  
434-444, 474-478, 506, 510  
Lateral hemisphere (of cerebellum) · 70,  
72, 76, 132, 134, 138, 140, 212, 368,  
370, 380-386, 414, 418, 490-496,  
504-510  
Lateral horn · 420, 424  
Lateral hypothalamic area · 96, 102,  
138-142, 154, 192, 254, 258, 296, 342,  
346, 348, 394, 424, 426, 474-480, 518,  
520, 528  
Lateral hypothalamus, peduncular part ·  
356, 484  
Lateral lemniscus · 10, 12, 30, 32, 60, 62,  
68-72, 132, 134, 138, 140, 156, 202-  
214, 220, 250, 252, 256, 294, 296, 300-  
304, 360-366, 378-388, 392, 394, 424,  
426, 440, 444, 486-490, 492, 510-520

Lateral mammillary nucleus · 134, 138,  
140, 154, 254, 296, 356, 358, 426, 484,  
518, 520  
Lateral migratory stream · 172-182,  
186, 240, 244, 280-288, 318-340, 388,  
392-396, 412-424, 444, 474, 476, 480,  
510-520  
Lateral migratory stream, head · 318-340,  
458, 460, 462, 466, 468, 470, 472  
Lateral migratory stream, reservoir · 282,  
284, 318-328, 332-340, 412, 416, 418,  
456-462, 466, 468, 470, 472  
Lateral olfactory tract · 102, 120-130,  
140, 148, 152-158, 162-188, 244,  
246, 250-254, 280, 282-288, 308, 310,  
316-328, 332-346, 402-408, 412-420,  
424, 426, 452-462, 466-476, 520-530  
Lateral orbital cortex · 452  
Lateral parabrachial nucleus · 382, 490,  
512  
Lateral paragigantocellular nucleus · 66  
Lateral posterior thalamic nucleus · 14, 32,  
48, 50, 86, 132, 154, 186, 188, 240, 296,  
300, 344-350, 382, 428, 430, 474-480,  
506  
Lateral preoptic area · 10, 32, 104, 132,  
154, 180-188, 254, 288-296, 338, 340,  
404, 406, 424-428, 468-472, 528  
Lateral preoptic area, intermediate zone,  
third ventricle · 48  
Lateral preoptic area, ventricular zone,  
third ventricle · 46  
Lateral preoptic nucleus · 340  
Lateral rectus muscle · 122-126, 156  
Lateral reticular nucleus · 116, 372, 492  
Lateral septal nucleus · 132, 134, 140,  
144, 168, 170-174, 244, 246, 296, 298,  
304, 308, 320-328, 332-336, 396, 398,  
402, 404, 430, 438, 440, 444, 460-466,  
512-520



- Lateral septal nucleus, dorsal part · 464  
 Lateral septal nucleus, intermediate part · 464  
 Lateral septal nucleus, ventral part · 468  
 Lateral tracts · 274, 276  
 Lateral ventricle · 6-18, 22-32, 38-50, 84-90, 120, 124-132, 138-144, 148, 152-158, 164-178, 182, 192, 194, 232-246, 250-254, 280-288, 296, 298, 310, 318-340, 344-352, 378, 380, 384-398, 404, 406, 414-420, 458-462, 466-472, 482, 484, 502-510, 512  
 Lateral ventricle, anterior horn · 94, 96, 100, 126, 318, 320, 382, 388, 394, 398, 456, 510, 520  
 Lateral ventricle, intermediate zone, auditory cortex · 350  
 Lateral ventricle, intermediate zone, cortex · 120-124, 138, 144-148, 152-158, 164, 166, 172-178, 230-238, 280, 284-292, 304, 306, 316-340, 376, 378, 382, 390, 422, 454-462, 466, 502-506  
 Lateral ventricle, intermediate zone, lateral ganglionic eminence · 40-48, 88, 172  
 Lateral ventricle, intermediate zone, medial ganglionic eminence · 46, 176, 178  
 Lateral ventricle, intermediate zone, pallidum · 46  
 Lateral ventricle, intermediate zone, piriform cortex · 38  
 Lateral ventricle, intermediate zone, septal area · 24, 44, 168  
 Lateral ventricle, posterior horn · 52, 92-96, 126, 130, 286, 344-348, 352, 388, 392-396, 510, 516  
 Lateral ventricle, subventricular zone, amygdala · 346, 348  
 Lateral ventricle, subventricular zone, auditory cortex · 350  
 Lateral ventricle, subventricular zone, cortex · 28, 120-124, 130, 146, 158, 164, 166, 172-176, 230-238, 280, 284, 288, 290, 292, 306, 310, 318-340, 350, 376, 378, 382-390, 394, 398, 404, 420, 428, 456, 462-468, 504, 506  
 Lateral ventricle, subventricular zone, lateral ganglionic eminence · 40-48, 88, 172, 176, 178, 236, 238, 290, 320-340, 462  
 Lateral ventricle, subventricular zone, medial ganglionic eminence · 46, 48, 334, 336-340  
 Lateral ventricle, subventricular zone, pallidum · 30  
 Lateral ventricle, subventricular zone, septal area · 168, 306, 310, 318-324, 456, 468  
 Lateral ventricle, subventricular zone, subiculum · 128  
 Lateral ventricle, ventricular zone, accumbens nucleus · 42  
 Lateral ventricle, ventricular zone, amygdala · 346, 348  
 Lateral ventricle, ventricular zone, auditory cortex · 350  
 Lateral ventricle, ventricular zone, cingulate cortex · 22, 38, 40  
 Lateral ventricle, ventricular zone, cortex · 6, 8, 28, 120-124, 130, 144-148, 152-158, 164, 166, 172-176, 230-238, 280, 284, 288, 290, 304, 306, 318-340, 376, 378, 382-390, 394, 398, 404, 406, 438, 444, 456, 462-466, 502-506, 520  
 Lateral ventricle, ventricular zone, frontal cortex · 38, 42, 84, 162  
 Lateral ventricle, ventricular zone, frontopolar cortex · 36  
 Lateral ventricle, ventricular zone, lateral ganglionic eminence · 38-48, 88, 172, 176, 178, 236, 238, 290, 320-340  
 Lateral ventricle, ventricular zone, medial ganglionic eminence · 24, 46, 48, 334-340  
 Lateral ventricle, ventricular zone, occipital cortex · 50, 52  
 Lateral ventricle, ventricular zone, pallidum · 30  
 Lateral ventricle, ventricular zone, parietal cortex · 40-44, 48  
 Lateral ventricle, ventricular zone, septal area · 24, 40-44, 168, 310, 318-324, 456  
 Lateral ventricle, ventricular zone, subiculum · 128  
 Lateral vestibular nucleus · 8, 10, 28, 30, 62, 68, 70, 74, 108-112, 140, 142, 206-212, 262, 264, 290, 294, 366, 368, 392, 420, 424, 440, 444, 490, 492  
 Laterodorsal tegmental nucleus · 208  
 Lens · 50, 96, 98, 108, 110, 120, 180, 184, 256, 258  
 Lens bow region · 98, 184, 256  
 Lens epithelium · 50, 96, 98, 110, 182, 184  
 Lenticular fasciculus · 132, 134, 152, 342, 344, 474, 516  
 Lingual nerve (V<sub>3</sub>) · 194  
 Lithoid nucleus · 310, 382  
 Locus coeruleus (A6) · 140, 142, 210, 212, 256, 258, 294, 296, 366, 382-386, 424, 426, 440, 444, 490, 492, 512, 514  
 Longitudinal cerebral fissure · 38, 40, 86, 88, 90, 92, 162, 164, 166, 170, 172, 176, 178, 230-234, 240, 322, 452-458, 502  
 Longitudinal fasciculus, pons · 298, 308, 310, 360, 402, 428, 434, 486  
 Longitudinal stria · 464  
 Lower eyelid · 178-182, 184, 186  
 Lower jaw (mandible) · 186, 272

**M**

- Macula (of utricle) · 208, 212
- Magnocellular nucleus (of lateral hypothalamus) · 294, 480, 482
- Magnocellular nucleus of posterior commissure · 310
- Magnocellular preoptic nucleus · 296, 338, 468, 472
- Mammillary area, ventricular zone, third ventricle · 54
- Mammillary body · 16, 24, 28, 96
- Mammillary neuroepithelium · 14, 18, 26, 56, 94, 102, 148, 198
- Mammillary peduncle · 198
- Mammillary recess · 18, 22, 24, 56, 94, 96, 100, 148, 256, 304, 358, 396, 398, 402, 430, 484, 524, 526
- Mammillotegmental tract · 16, 26, 28, 56, 92, 144, 148, 194-202, 246, 250, 252, 300, 304, 306, 352-360, 384-388, 392-396, 430-436, 484, 486, 510-520
- Mammillothalamic tract · 140, 182, 190-300, 308, 310, 346, 348, 352-358, 388, 392-396, 430, 436, 438, 442, 444, 472-484, 512-520
- Mandibular nerve ( $V_3$ ) · 2-10, 52, 54, 106, 110-116, 126, 130-134, 154-158, 194-198, 266, 268
- Mandibular process · 6, 8, 22-28, 50-54, 108, 110, 114, 116, 182, 186
- Marginal zone · 2, 14, 28, 84, 120-124, 148, 152-158, 162, 172-176, 230-238, 280, 284-290, 304, 316-340, 350, 376, 378, 382, 390, 452-462, 466, 502-506
- Marginal zone, auditory cortex · 350
- Marginal zone, cingulate cortex · 24
- Marginal zone, frontal cortex · 40, 44, 48
- Marginal zone, frontopolar cortex · 36
- Marginal zone, parietal cortex · 38, 46
- Marginal zone, somatosensory cortex · 158
- Masseter muscle · 266, 268, 270
- Maxilla · 120-132
- Maxillary nerve ( $V_2$ ) · 2, 6-10, 44-52, 102-106, 112, 116, 124-134, 138, 154, 156, 176-182, 186, 188, 190, 260, 262
- Maxillary process · 6, 8, 22, 26, 28, 38, 40-52, 108-116, 176, 178, 182
- Meckel's cartilage · 10, 12, 54, 132, 134, 186-200, 266-272
- Medial accessory oculomotor nucleus · 358
- Medial amygdaloid nucleus · 52, 54, 128, 130, 156, 158, 188, 254, 284, 346, 348, 398, 418, 476-480, 518, 520, 524
- Medial diencephalic sulcus · 52, 54, 190, 348
- Medial (fastigial) nucleus (of cerebellum) · 148, 150, 156, 214, 216, 258-304, 370, 428, 430, 494-498, 508, 510
- Medial forebrain bundle · 50, 54, 96, 182, 186-194, 258, 260, 320-324, 332-348, 352-356, 406, 428, 444, 456, 458, 462, 470-474, 478-482, 520, 524, 528
- Medial ganglionic eminence · 12-18, 26-32, 44, 48, 90-94, 128-134, 144, 146, 174-182, 240, 242, 248, 334-340, 396
- Medial ganglionic eminence, intermediate zone, lateral ventricle · 46, 176, 178
- Medial ganglionic eminence, subventricular zone, lateral ventricle · 46, 48, 334-340
- Medial ganglionic eminence, ventricular zone, lateral ventricle · 24, 46, 48, 334-340
- Medial geniculate nucleus · 12, 32, 52, 54, 90, 94, 96, 130, 152-156, 192, 194, 198, 200, 236, 240-246, 250, 290, 294, 348-354, 382, 386, 424-428, 478-484, 510
- Medial habenular nucleus · 22, 44, 46, 132, 138, 180, 182, 236, 300, 304-310, 342, 344, 384-388, 392, 436-442, 474-478, 506, 510
- Medial habenular nucleus, ventricular zone, third ventricle · 26, 180
- Medial lemniscus · 12-18, 30, 50-60, 68-76, 88, 90, 94, 96, 100-108, 112-116, 134, 138-142, 148, 154, 188, 190, 198-222, 246, 250, 252-274, 290, 296-300, 306, 344-348, 352-370, 384, 388, 392-398, 426-432, 442, 478-482, 486-498, 512-516, 520
- Medial longitudinal fasciculus · 12-18, 22-30, 58-76, 90, 92, 94, 100, 104-116, 140-152, 158, 202-224, 246, 250, 252-256, 260, 262, 266-276, 300, 302-310, 356-372, 378-382, 394, 430-440, 444, 486-498, 510
- Medial mammillary nucleus · 142-146, 152, 196, 256, 298, 300, 304-310, 356, 358, 394-398, 428-440, 484, 518, 520
- Medial motor nucleus (of spinal cord) · 400
- Medial nasal prominence · 12-16, 24
- Medial orbital cortex · 452
- Medial parabrachial nucleus · 206, 490, 492
- Medial paralemniscal nucleus · 486
- Medial preoptic area · 12, 14, 22, 30, 100, 106, 134, 140, 142, 148, 152, 180, 250, 254, 304, 308, 334-340, 406, 430, 434-440, 444, 472
- Medial preoptic area, intermediate zone, third ventricle · 46
- Medial preoptic area, ventricular zone, third ventricle · 22, 48
- Medial preoptic nucleus · 182, 186, 254, 256, 298, 300, 306, 308, 338, 402, 404, 468, 470, 524-530

- Medial pretectal nucleus · 188, 190, 380, 382, 480, 504  
 Medial rectus muscle · 122-126, 156, 178, 180-184  
 Medial septal nucleus · 22, 42, 44, 96, 138, 142, 172-178, 244, 298, 300, 304, 306, 322-328, 332, 398, 402, 404, 432, 434, 444, 460, 462-466, 518, 520  
 Medial tuberal nucleus · 100, 104, 142, 154, 294, 296, 406, 426, 428, 436, 480, 482, 526, 528  
 Medial vestibular nucleus · 22, 68, 70, 74, 76, 108, 110, 114, 116, 146, 148, 152, 156, 208, 210-220, 262-266, 296, 298, 310, 368, 370, 388, 394, 420, 426, 428, 436-440, 490-498  
 Median eminence · 18-24, 52, 106, 148, 194, 262, 300, 304, 352, 398, 430, 444, 480, 482, 530  
 Median fibrous septum (of tongue) · 180  
 Median preoptic nucleus · 398, 434, 468, 470  
 Median raphe nucleus, midbrain (B8) · 204-208, 386  
 Median raphe nucleus, pons (B5) · 18-22, 56-60, 148, 152, 200-204, 208, 254-260, 360-364, 384-388, 392-396, 488, 512-518  
 Mediodorsal thalamic nucleus · 16, 18, 28, 30, 46, 48, 88, 132, 134, 138-148, 180, 182, 240, 242, 298, 300, 304-310, 342, 344, 384, 386, 432-440, 444, 474, 476, 510, 512  
 Mediodorsal thalamic nucleus, subventricular zone, third ventricle · 182  
 Mediodorsal thalamic nucleus, ventricular zone, third ventricle · 182  
 Medulla · 14, 20, 150, 304, 392, 394, 398, 400, 428, 430, 434, 438, 440, 444, 378, 380, 392, 432, 436, 454-462, 466-474, 502-506  
 Medulla, ventricular zone, fourth ventricle · 14, 18, 78, 150, 304  
 Mesencephalic flexure · 22, 58, 200, 202  
 Mesencephalic trigeminal nucleus · 12, 26, 28, 62, 66-74, 94, 96, 100-104, 158, 210, 212, 252-260, 290, 294-304, 360, 362, 366, 376, 378, 384, 424, 426, 432, 434, 444, 490, 492, 502, 504, 508-512  
 Mesencephalic trigeminal tract (V) · 96, 290, 294, 298, 300, 302, 376, 378, 504  
 Microcellular tegmental nucleus · 156, 158, 206, 208, 210, 254, 296, 362-366, 380, 428, 488  
 Midbrain · 58, 428-440, 444, 506, 510  
 Middle cerebellar peduncle · 138, 142, 154, 198, 206-216, 254, 256, 290, 294-300, 360, 362, 366, 382-388, 392, 396, 414-420, 424-432, 436, 438, 486, 490, 492, 510-514  
 Middle cerebral artery · 42, 46, 472  
 Middle cerebral vein · 48  
 Middle diencephalic fold · 14-18, 30, 32, 48, 50, 52, 186  
 Midline · 304  
 Midline fusion of palatal shelves · 262  
 Midline zipper glia · 322-326  
 Mitotic cells · 28, 64, 66, 84, 98, 390  
 Mitral cell layer · 142, 144, 162-168, 250, 286-300, 304-310, 314, 316, 406, 408, 426-434, 438, 440, 444, 448, 450, 452, 516-524  
 Molecular layer (of cerebellum) · 150, 216, 286, 288, 290, 296-310, 368, 380, 382-384, 416, 418, 432-440, 444, 490, 492, 496  
 Molecular layer (of hippocampus) · 290, 350  
 Motor cortex · 128, 146, 162-166, 170-180, 230-236, 240, 286-290, 294-300, 308, 310, 316-322, 324-328, 332-340, 376, 378, 380, 392, 432, 436, 454-462, 466-474, 502-506  
 Motor neurons · 426, 428  
 Motor nucleus (of ventral horn) · 156, 224, 404
- 
- N*  
 Nasal capsule · 162-166  
 Nasal cartilage · 260  
 Nasal cavity · 12-16, 24-30, 40-48, 100-112, 144, 162-178, 254, 256-262  
 Nasal septum · 40-44, 164, 166, 172-176, 180, 182, 256  
 Nasopharynx · 180, 182, 186-202, 264  
 Neural retina · 2, 50, 52, 96, 98, 106-110, 120-124, 158, 178-184, 254-258  
 Neural retina, intermediate zone · 122, 254, 258  
 Neural retina, ventricular zone · 94, 98, 100, 112, 122, 124, 184, 186, 254-260  
 Neuroepithelium, amygdaloid · 90, 92, 96, 98, 122-128, 158, 246-254, 280, 282, 284, 346, 348, 416, 418, 520  
 Neuroepithelium, cerebellar · 2, 6-18, 22-32, 68, 70, 72, 76, 100-110, 220, 260  
 Neuroepithelium, cochlear · 2-6, 32, 68-72, 100-112, 132, 136, 140, 206-210, 214, 216, 262, 296, 392, 414, 492, 494  
 Neuroepithelium, cortical · 6-10, 82-86, 120-130, 146, 148, 152-158, 172, 236, 238, 280-288, 306, 318-328, 332-340, 390, 396, 434, 456-468  
 Neuroepithelium, dentate gyrus · 250  
 Neuroepithelium, dorsal thalamus · 14-18, 28, 30, 32, 44-52, 88  
 Neuroepithelium, epithalamic · 30, 44-52, 84, 178, 234  
 Neuroepithelium, habenular · 82-86

Neuroepithelium, hippocampal · 10, 12, 32, 86-92, 126, 128, 172, 250, 280-288, 350, 388  
 Neuroepithelium, hypothalamic · 12, 14, 24, 26, 92, 148, 152  
 Neuroepithelium, inferior colliculus · 302, 506  
 Neuroepithelium, isthmal · 212, 214  
 Neuroepithelium, mammillary · 14, 18, 26, 56, 94, 102, 148, 198  
 Neuroepithelium, olfactory · 96, 100, 102, 126-130, 166, 244, 246, 286, 294, 296, 304, 306, 310, 314, 430, 450, 454  
 Neuroepithelium, pallidal · 12-18, 26, 28-32, 44-48, 90-94, 128-134, 144, 146, 180, 182, 240, 242, 334-340, 396  
 Neuroepithelium, pontine · 24, 432  
 Neuroepithelium, posterior hypothalamic · 92  
 Neuroepithelium, posterior precerebellar · 218-222  
 Neuroepithelium, precerebellar · 214, 264, 304-308, 368, 430, 444  
 Neuroepithelium, preoptic · 12, 26, 28, 30, 100, 102, 146, 250, 256  
 Neuroepithelium, pretectal · 14-18, 32, 82  
 Neuroepithelium, septal · 10, 12, 16, 18, 22, 26, 32, 94, 96, 128, 130, 134, 144, 146, 168-174, 242, 244, 294, 296, 306, 310, 318, 320, 322-326, 430, 456, 458  
 Neuroepithelium, spinal cord · 12, 14, 400  
 Neuroepithelium, striatal · 8-12, 32, 42-48, 88-96, 126-130, 144-148, 152-158, 172, 176, 236, 240, 242, 280-290, 294, 296, 310, 320-340, 388-392, 394, 396, 430, 432, 458, 460, 462, 466, 468, 518  
 Neuroepithelium, tectal · 54, 72, 74, 82-96, 150, 202-208, 214, 236, 240, 242, 256  
 Neuroepithelium, tegmental · 64, 92-96

Neuroepithelium, thalamic · 48, 50, 84, 140, 142, 240-248  
 Neuroepithelium, ventral thalamus · 14-18, 28-32, 48-52  
 Neuroepithelium, vestibular · 12, 60, 70, 72, 102-106, 110, 114, 206, 208, 260, 264, 392  
 Neurohypophysis (Pituitary, posterior lobe) · 16-22, 104, 106, 152, 154, 196-200, 262  
 Nigrostriatal bundle · 352, 354, 394  
 Nodose ganglion · *See* Inferior vagal (nodose) ganglion  
 Noradrenergic nuclear complex (A4-7) · 60, 62, 68  
 Nostril (external naris) · 108, 110, 260  
 Nuclei of lens fibers · 50, 96, 98, 108, 110, 182, 184, 256, 258  
 Nucleus of brachium of inferior colliculus · 204-212, 244, 246, 254, 506  
 Nucleus of Darkschewitsch · 26, 244, 306-310, 352, 380, 382, 438, 484  
 Nucleus of horizontal limb of diagonal band · 46, 102, 128, 132, 140, 178, 180, 250, 252, 294, 296, 308, 324-328, 332-340, 408, 428, 444, 462, 466-472, 524  
 Nucleus of inferior colliculus · 360-366, 378, 428, 430, 488, 490, 492, 502, 506  
 Nucleus of lateral olfactory tract · 130, 188, 282, 284, 344, 346, 402, 416, 418, 474, 476, 524, 528  
 Nucleus of optic tract · 186, 298, 300, 380, 382, 434, 480, 506  
 Nucleus of posterior commissure · 310, 352, 482  
 Nucleus of stria medullaris · 178, 180, 252, 398, 518  
 Nucleus of trapezoid body · 364, 398, 432, 434, 488, 526, 528

Nucleus of vertical limb of diagonal band · 42, 44, 168-178, 242, 246, 298, 300, 304, 306, 320-328, 332, 334, 404, 432, 434, 460, 462, 466, 518, 520  
 Nucleus proprius · 400

---

**O**

Occipital cortex · 10, 14, 16, 52, 82, 86, 88, 90  
 Occipital cortex, ventricular zone, lateral ventricle, · 50, 52  
 Occipital sinus · 2  
 Oculomotor nerve (III) · 10, 12, 30, 32, 50, 54, 56, 90-96, 106, 128, 130, 154, 158, 182-190  
 Oculomotor nucleus · 16, 18, 26, 58, 60, 64, 90, 92, 146, 148, 202, 204, 246, 308, 360, 362, 378, 436, 438, 486, 506  
 Olfactory artery · 18, 40-44, 172, 174, 460, 462, 466  
 Olfactory bulb · 40, 94, 96, 100, 102, 126-134, 138, 142-146, 162-166, 244, 246, 252, 286, 290-294, 298, 300, 304, 308, 310, 314, 406, 408, 428-440, 444, 448-452, 516-528  
 Olfactory bulb, intermediate zone, olfactory ventricle · 126, 140, 144, 146, 250  
 Olfactory bulb, subventricular zone, olfactory ventricle · 244, 246, 290, 292, 300, 314, 316, 448, 450, 452, 454  
 Olfactory bulb, ventricular zone, olfactory ventricle · 26, 126, 138, 140, 144, 146, 244, 246, 288, 290, 292, 300, 314, 316, 406, 450, 454, 520  
 Olfactory cortex · *See* Piriform cortex  
 Olfactory epithelium · 10-18, 24, 26-32, 40-48, 100, 102-112, 126-134, 138, 140-148, 152, 162-178, 182, 254-258

- Olfactory nerve (I) · 10, 14-18, 24-30, 38-44, 96, 100, 102, 128-134, 140-148, 152, 168-176, 246, 250-254, 316, 406, 448, 450, 452, 522, 524
- Olfactory nerve layer · 40, 132, 134, 138, 142, 144, 162-168, 250, 252, 286, 290, 292, 300, 304, 308, 316, 408, 428, 432, 436, 440, 444, 448-452, 518, 522-528
- Olfactory neuroepithelium · 96, 100, 102, 126-130, 166, 244, 246, 286, 294, 296, 304, 306, 310, 314, 430, 450, 454
- Olfactory tubercle · 42, 130, 134, 170, 174-178, 250, 252, 282, 284, 294, 296, 306, 318-324, 328, 332, 334, 406, 416-420, 424-428, 444, 456-462, 466-472, 524-528
- Olfactory ventricle · 94, 100, 128, 130, 140-144, 164-168, 244, 246, 286, 290, 292, 300, 304, 314, 316, 402, 406, 408, 430, 432, 444, 448, 450-454
- Olfactory ventricle, intermediate zone, olfactory bulb · 126, 140, 144, 146, 250
- Olfactory ventricle, subventricular zone, olfactory bulb · 244, 246, 290, 292, 300, 314, 316, 448-454
- Olfactory ventricle, ventricular zone, olfactory bulb · 26, 138, 140, 144, 146, 244, 246, 288-292, 300, 314, 316, 406, 450, 454, 520
- Olivary pretectal nucleus · 186-190, 504
- Ophthalmic nerve (V<sub>1</sub>) · 6, 8, 52, 100, 108, 110, 132, 134, 138, 156, 158, 260, 262
- Optic chiasm · 28, 48, 140-148, 152, 188, 190, 192, 260, 290, 294-300, 304-308, 408, 428-440, 444, 472, 474, 476, 530
- Optic cup, inner layer · 98
- Optic cup, outer layer · 98
- Optic disk · 98, 184
- Optic fiber layer · 96, 98, 122, 124, 184, 256, 258
- Optic nerve (II) · 100, 126-134, 138, 154, 156, 158, 182-190, 258, 280-284, 288, 290, 294, 428, 434, 436, 466-472, 528, 530
- Optic pit · 258
- Optic recess · 10, 12, 16, 18, 24-30, 46, 48, 104, 106, 108, 142-148, 152, 258, 298, 338, 432, 468, 470, 524-530
- Optic stalk · 6, 8, 32, 98, 100, 102, 108, 138, 140, 184, 190, 192, 300
- Optic tract · 10, 12, 26, 30, 32, 52, 54, 88-96, 100, 102-106, 130-134, 138, 144-148, 152-156, 186-194, 236, 240-246, 250-258, 286-290, 294, 296-300, 304, 310, 346, 348, 350, 380-384, 388, 394-398, 402-408, 420-426, 430, 432, 438, 440, 476-482, 504, 506, 510-520, 524-530
- Oral cavity · 12, 16, 24, 28, 50, 52, 108-112, 144, 172-178, 186-192, 264, 266, 268, 270
- Orbital cavity · 126
- Orbital cortex · 92, 128, 138, 146, 162, 164, 286-300, 304, 308, 310, 316, 454, 518
- Organum vasculosum · 176, 178
- Oriens layer · 412, 414, 418, 422, 424, 470, 484, 504, 514
- Oropharynx · 112-116, 152, 180, 182, 194-202, 262-270
- Otic ganglion · 196-200
- Otocyst · 2-10, 26-32, 60, 62, 68-76, 106-116
- Outer nuclear layer of retina · 184
- 
- P**
- Palatal shelf · 26, 52-60, 180, 182, 186-202, 262, 268, 270
- Pallidal neuroepithelium · 12-18, 26-32, 44-48, 90-94, 128-134, 144, 146, 180, 182, 240, 242, 334-340, 396
- Pallidum, intermediate zone, lateral ventricle · 46
- Pallidum, subventricular zone, lateral ventricle · 30
- Pallidum, ventricular zone, lateral ventricle · 30
- Parabigeminal nucleus · 380
- Parabrachial nucleus · 12, 68, 100, 106, 208, 210, 256, 294-298, 366, 384, 386, 424, 426
- Paracollicular tegmentum · 380
- Parafascicular thalamic nucleus · 18, 30, 48, 50, 88, 134, 146, 190, 192, 236, 300, 304, 306, 310, 346, 348, 384, 432-436, 440, 442, 478, 510
- Paramedian raphe nucleus · 202, 206, 392, 486, 488
- Parapyramidal reticular nucleus · 208, 210, 268, 366, 368, 490
- Parasubthalamic nucleus · 296, 354, 394, 482
- Paratenial thalamic nucleus · 138, 144, 178, 246, 248, 338, 340, 432, 472
- Paratenial thalamic nucleus, intermediate zone, third ventricle · 178
- Paraventricular hypothalamic nucleus · 14, 52, 54, 94, 96, 144, 148, 188, 250, 252, 298, 304-308, 342-348, 396, 398, 428, 432, 434, 438, 472-478, 518, 520
- Paraventricular hypothalamic nucleus, ventricular zone, third ventricle · 92
- Paraventricular thalamic nucleus · 22, 42, 44-48, 88, 138, 146, 180, 236, 240, 242, 250, 300, 304-308, 338-344, 384, 386, 394, 396, 434-440, 472, 474-478, 510-514



- Paraventricular thalamic nucleus,  
subventricular zone, third ventricle · 146
- Paraventricular thalamic nucleus,  
ventricular zone, ventricular zone · 24,  
26, 92, 146, 180
- Paravermis · 152, 158, 218, 368, 370,  
380-384, 506-510
- Parietal cortex · 2, 6-12, 32, 40, 86-90
- Parietal cortex, marginal zone · 38, 46
- Parietal cortex, ventricular zone, lateral  
ventricle · 40, 42, 44, 48
- Parvocellular reticular nucleus · 420
- Pedunculopontine tegmental nucleus · 206,  
208
- Periaqueductal gray · 62, 140, 198, 200,  
202, 206-212, 242, 246, 302-308, 348,  
348, 352-366, 376-382, 434-438, 442,  
444, 480-494, 502-506
- Periaqueductal gray, ventricular zone,  
aqueduct · 32
- Perineural mesenchyme · 2, 36, 84
- Periolivary nucleus · 200
- Periventricular hypothalamic nucleus · 342,  
468, 472-476, 524
- Petrosal ganglion · *See* Inferior  
glossopharyngeal (petrosal) ganglion
- Pharynx · 56-62
- Philtrum · 266-270
- Pia-arachnoid · 238
- Pia mater · 292, 390
- Pineal gland · 26, 42, 44, 82, 138, 180,  
232, 308, 310, 342, 344, 376-382,  
440-444, 478, 480, 502, 504
- Pineal recess · 24, 26, 42, 44, 82, 138, 140,  
180, 232, 308, 382, 440, 442, 502, 504
- Pinna (of ear) · 120-124, 206-212, 264-272
- Piriform cortex · 2, 6-10, 38-44, 90-96,  
120, 122, 164, 166, 170-182, 188-192,  
242-246, 250-254, 280-286, 318-328,  
332-348, 398, 402-406, 412-420,  
454-462, 466-476, 520, 524
- Piriform cortex, intermediate zone, lateral  
ventricle · 38
- Pituitary · 16-24, 106-110, 146, 148,  
152-156, 196, 198, 200, 262, 264
- Pituitary, anterior lobe (Adenohypophysis)  
· 16-22, 108, 110, 146, 148, 152-156,  
196-200, 262, 482
- Pituitary, intermediate lobe · 20, 106-110,  
148, 152, 262
- Pituitary, posterior lobe (Neurohypophysis)  
· 16-22, 104, 106, 152, 154, 196-200,  
262
- Polymorph layer (of hippocampus) · 290,  
350
- Pons · 20, 58, 150, 298, 308, 310, 360-368,  
384, 388, 392, 396, 428-440, 444, 508
- Pons, ventricular zone, fourth ventricle ·  
58-66, 366
- Pontine flexure · 24, 366
- Pontine neuroepithelium · 24, 432
- Pontine nuclei · 140-144, 156, 258, 260,  
290, 294-300, 306, 308, 310, 360, 362,  
396, 398, 402, 426-436, 486, 520, 524
- Pontine reticular nucleus · 14-18, 22-28,  
56-60, 100-104, 110, 144, 146, 202,  
204, 208, 258, 260, 290, 296, 308, 428,  
430, 432, 488
- Posterior ampulla · 212-216
- Posterior cerebral artery · 10, 14, 16, 56,  
58, 88, 200
- Posterior commissure · 14-18, 22-32, 52,  
82, 138, 140-144, 186-192, 234, 236,  
308, 310, 346, 348, 352, 376, 378-382,  
438-444, 480, 482, 504
- Posterior communicating artery · 32, 54
- Posterior diencephalic fold · 14-18, 30, 32,  
52, 82
- Posterior dorsal tegmental nucleus · 492
- Posterior hypothalamic area · 28, 94, 96,  
144, 148, 194, 254, 298, 304, 310, 348,  
352, 354, 392, 394, 432-436, 482, 518,  
520
- Posterior hypothalamic area, ventricular  
zone, ventricular zone · 54
- Posterior hypothalamic neuroepithelium ·  
92
- Posterior hypothalamic nucleus · 256
- Posterior lobe (of pituitary,  
Neurohypophysis) · 16-22, 104, 106,  
152, 154, 196-200, 262
- Posterior precerebellar neuroepithelium ·  
218-222
- Posterior pretectal nucleus · 192, 298, 354,  
430, 484
- Posterior semicircular canal · 2, 70, 74,  
112, 116, 128, 130, 208, 214-218,  
264-268
- Posterior thalamic nucleus · 52, 54, 86, 88,  
132, 134, 154, 186-194, 236-242, 294,  
296, 306, 344, 346, 348, 352, 384, 386,  
428-432, 476-482, 510
- Posterior thalamic nucleus, ventricular  
zone, ventricular zone · 86, 90
- Precerebellar (extramural) migration · 200,  
204
- Precerebellar (intramural) migration · 198,  
200, 256
- Precerebellar migration · 136, 138, 154,  
156, 210, 220, 222, 258-264, 272, 274,  
290, 296, 298, 306, 360-370, 384, 386,  
394-398, 402, 418, 420, 424, 434, 440,  
514-520
- Precerebellar nuclei, ventricular zone,  
fourth ventricle · 368
- Precerebellar neuroepithelium · 214, 264,  
304-308, 368, 430, 444

Precommissural nucleus · 138, 142, 144, 186, 188, 306, 378, 382, 438, 442, 480, 482, 506  
 Prelimbic cortex · 318, 456  
 Premammillary nucleus · 54, 196, 298, 310, 352-356, 428, 434  
 Preoptic area · 94, 286  
 Preoptic neuroepithelium · 12, 26-30, 100, 102, 146, 250, 256  
 Prepositus hypoglossal nucleus · 16, 18, 74, 114, 154, 158, 212-220, 266, 268, 308, 368, 370, 394, 430, 494, 496, 520  
 Presphenoid wing · 176, 178, 186-190  
 Pretectal neuroepithelium · 14-18, 32, 82  
 Pretectum · 26-30, 48-52, 86, 134, 144-148, 234, 236, 296, 304, 346, 348, 376, 378, 432, 436, 438  
 Pretectum, ventricular zone, third ventricle · 22, 24, 28  
 Primary lens fibers · 98  
 Primary palate · 264, 266  
 Principal mammillary tract · 14, 26, 28, 94, 96, 144, 146, 152, 196, 198, 254, 256, 298, 300, 308, 356, 358, 388, 394, 396, 428, 484, 518, 520  
 Principal (sensory) trigeminal nucleus · 8, 58, 60, 66, 100-112, 134-140, 158, 200-204, 258-264, 284, 288, 290, 362-366, 388, 392-398, 414-418, 440, 444, 488, 490, 516-520, 524  
 Purkinje cell layer · 150, 212-218, 286, 288, 290, 296-310, 368, 370, 380-386, 416-420, 424-440, 444, 490-496, 508-512  
 Purkinje cells, migrating · 258, 260  
 Pyramidal cell layer (of hippocampus) · 284, 290, 294, 298, 308, 310, 350, 382-388, 416-422, 432, 434, 442, 472, 474, 484, 504, 506, 510-514  
 Pyramidal decussation · 154, 224, 276

Pyramidal tract · 12-18, 24, 56-64, 68-76, 90, 94, 96, 100-116, 202-222, 252-274, 360-372, 396-400, 424, 426, 432-436, 488-494, 516, 520, 526-530

---

**R**

Radiatum layer · 422, 484, 514  
 Raphe magnus nucleus (B3) · 14, 18, 20, 62-66, 70, 102-108, 112, 202-206, 258, 262, 362, 366, 368, 404, 428, 488-494, 524-530  
 Raphe obscurus nucleus (B2) · 14, 16, 114, 116, 154, 156, 222-266, 276, 372, 396, 398, 402, 494, 498  
 Raphe pallidus nucleus (B1) · 66, 154, 156, 210, 214-218, 224, 370, 402, 404, 498  
 Rathke's pouch · 14-24, 104-110, 148, 152, 154, 198, 200, 262, 264  
 Red blood cells (nucleated) · 2, 4, 36-50, 64, 66, 70, 72, 82, 84, 98  
 Red nucleus · 18, 26, 28, 56, 88, 142, 144, 148, 152, 198-202, 244, 246, 250, 252, 300, 304, 306, 356-362, 382, 430-436, 440, 444, 486, 510  
 Reticular formation, medulla · 74, 76, 222, 270, 274, 276, 370, 372, 424, 426, 434, 494, 496  
 Reticular formation, midbrain · 88, 196, 200-204, 240, 244, 354-360, 364, 366, 482-486  
 Reticular formation, pons · 362-368, 392, 394, 424, 426, 434, 490, 512, 514  
 Reticular thalamic nucleus · 14-18, 28-32, 48-52, 90, 92, 132, 134, 154, 182, 186, 244-248, 288, 290, 294-298, 342-346, 388, 392, 394, 420-424, 426-430, 442, 444, 474-480, 512-516  
 Reticulospinal tract · 274, 276

Reticulotegmental nucleus · 24, 96, 100, 364, 398, 402, 430, 432, 488  
 Retinal pigment epithelium · 2, 48, 50, 52, 94-100, 106-112, 120-124, 158, 178-186, 254-260  
 Retrorubral field · 298  
 Retrosplenial cortex · 12, 26, 28, 30, 82, 86, 182, 186, 234, 236, 288, 290, 294-300, 308, 310, 336-348, 378-382, 392, 436, 438, 472-504  
 Reuniens thalamic nucleus · 90, 92, 140, 142, 146, 180, 182, 186, 240-250, 300, 304, 340, 342, 344, 394, 434, 474-480, 512-516  
 Reuniens thalamic nucleus, subventricular zone, third ventricle · 146, 180, 182, 186  
 Reuniens thalamic nucleus, ventricular zone, third ventricle · 146, 180, 182, 186, 250  
 Rhinal fissure · 164, 166, 284, 318, 424, 436, 452-456  
 Rhomboid thalamic nucleus · 304, 474, 476  
 Roof of lateral ventricle · 82  
 Roof of oral cavity · 20  
 Roof plate · 226, 274, 276  
 Rostral linear raphe nucleus · 196, 200  
 Rubrospinal tract · 274, 276

---

**S**

Sacculae · 2, 32, 70, 72, 110-116, 128, 134, 136, 206, 208, 210, 264-268  
 Scarpa's ganglion · *See* Vestibular (Scarpa's) ganglion  
 Sclera · 120, 176-188, 254, 260  
 Semilunar ganglion · *See* Trigeminal (semilunar) ganglion  
 Septal area, intermediate zone, lateral ventricle · 24, 44, 168

- Septal area, subventricular zone, lateral ventricle · 168, 310, 318-324, 456, 468
- Septal area, ventricular zone, lateral ventricle · 24, 40-44, 168, 310, 318-324, 456
- Septal cartilage · 162, 170-178
- Septal neuroepithelium · 10, 12, 16, 18, 22, 26, 32, 94, 96, 128, 130, 134, 144, 146, 168-174, 242, 244, 294, 296, 306, 310, 318, 320-326, 430, 456, 458
- Septofimbrial nucleus · 336, 436, 468, 470, 516
- Septohippocampal nucleus · 458-462
- Serotonergic nuclear complex (B1-3) · 72-76
- Serous gland · 162-166
- Sinusoids · 2, 36, 84
- Sling cells · 328, 332, 458, 460, 464, 466
- Solitary tract · 8, 10, 18, 22-28, 76, 78, 114, 116, 146-156, 216, 218, 220-224, 266-270, 310, 368, 370, 372, 388, 392, 394, 420-428, 432, 436, 438, 494-498, 516, 518
- Solitary tract nucleus · 8, 10, 18, 22-26, 76, 78, 114, 116, 146-154, 158, 214-218, 220-224, 266-274, 298, 310, 368-372, 388, 392, 394, 420-428, 432, 436, 438, 494-498, 516, 518
- Somatosensory cortex · 120, 122, 158, 170-182, 186, 236, 240, 242, 280, 282-286, 290, 318-328, 332-344, 376-380, 384, 386, 392, 394, 412-422, 454-462, 466-478, 502-506
- Somatosensory cortex, marginal zone · 158
- Spinal cord · 16, 78, 156, 394, 396, 398, 402, 406, 408, 420, 424-428
- Spinal cord neuroepithelium · 12, 14, 400
- Spinal cord, ventricular zone, central canal · 16
- Spinal trigeminal nucleus · 60, 62, 68, 70-78, 104, 106, 112-116, 138-142, 146, 148, 152-156, 208-226, 262-276, 364-372, 388, 396, 398, 416-420, 432-440, 444, 490-498, 520
- Spinal trigeminal tract (V) · 2-8, 30, 32, 58-62, 68-78, 96, 100-116, 132-148, 152, 154, 200-226, 258-262, 266-276, 364-372, 396, 398, 414-420, 440, 444, 490-498, 516-520
- Spinal vestibular nucleus · *See* Inferior vestibular nucleus
- Spinocerebellar tract · 274, 276
- Spinothalamic tract · 274, 276
- Spiral (cochlear) ganglion · *See* Cochlear (spiral) ganglion
- Stria medullaris · 14-18, 22, 26-32, 46-50, 82, 84, 88, 90-94, 132, 134, 138, 144-148, 178-182, 186, 236-242, 246-252, 294-300, 310, 338-344, 384-388, 392-398, 428-444, 472-478, 506, 510-518
- Stria terminalis · 124-130, 134, 138, 142-146, 154-158, 180, 182, 186, 190, 244-252, 280-296, 310, 338, 340-346, 396, 398, 416-430, 444, 470-480, 514-520
- Striatal neuroepithelium · 8-12, 32, 42-48, 88-96, 126-130, 144-148, 152-158, 172, 176, 236, 240, 242, 280-290, 294, 296, 310, 320-340, 388-396, 430, 432, 458-462, 466, 468, 518
- Striatum · *See also* Caudate-putamen · 40, 44, 46, 90, 94, 96, 174
- Subcommissural organ · 138-142, 186, 188-198, 234, 308, 310, 346, 348, 352, 354, 376-382, 442, 480-484, 504
- Subfornical organ · 128, 140, 142, 240, 242, 286, 288, 294, 300, 306, 336, 338, 394, 422, 442, 472, 512, 514
- Subgeniculate nucleus · 348, 350
- Subiculum · 128, 130, 284, 286, 288, 294, 348, 352, 354, 416, 418, 424, 478, 482, 484, 504, 514
- Subiculum, subventricular zone, lateral ventricle · 128
- Subiculum, ventricular zone, lateral ventricle · 128
- Submandibular gland · 138, 140, 196-204, 272
- Subparafascicular thalamic nucleus · 140, 246, 252, 296, 352, 354, 394, 426, 442, 480, 512
- Subplate · 166, 170, 172, 176, 230-238, 280, 284-290, 316-338, 386, 390, 454-462, 466, 502-506
- Subretinal space · *See* Intraretinal (subretinal, ventricular) space (of eye)
- Substantia gelatinosa · 226, 396-400
- Substantia innominata · 28, 30, 128, 130, 154, 284, 286, 288, 418-426, 468-474
- Substantia nigra (A9) · 30, 58, 90, 132, 134, 138, 140, 204, 246, 250, 252, 296, 356, 358, 360, 382-386, 392, 426, 428, 440, 444, 510-516
- Substantia nigra (A9), compact part · 56, 200, 202, 486
- Substantia nigra (A9), reticular part · 196-202, 484, 486
- Subthalamic nucleus · 14, 16, 30, 54, 92, 94, 132, 194, 196, 252, 294, 296, 348, 352, 394, 426, 444, 480, 482, 516, 518
- Subventricular zone, aqueduct, tectum · 208
- Subventricular zone, central medial thalamic nucleus · 180, 182, 186
- Subventricular zone, hippocampus · 130, 232, 234
- Subventricular zone, lateral ventricle, amygdala · 346, 348



- Subventricular zone, lateral ventricle, auditory cortex · 350
- Subventricular zone, lateral ventricle, cortex · 28, 120-124, 130, 146, 158, 164, 166, 172-176, 230-238, 280, 284, 288-292, 306, 310, 318-340, 350, 376, 378, 382-390, 394, 398, 404, 420, 428, 456, 462-468, 504, 506
- Subventricular zone, lateral ventricle, lateral ganglionic eminence · 40-48, 88, 172, 176, 178, 236, 238, 290, 320-340, 462
- Subventricular zone, lateral ventricle, medial ganglionic eminence · 46, 48, 334-340
- Subventricular zone, lateral ventricle, pallidum · 30
- Subventricular zone, lateral ventricle, septal area · 168, 306, 310, 318-324, 456, 468
- Subventricular zone, lateral ventricle, subiculum · 128
- Subventricular zone, olfactory ventricle, olfactory bulb · 244, 246, 290, 292, 300, 314, 316, 448-454
- Subventricular zone, third ventricle, central medial thalamic nucleus · 180, 182, 186
- Subventricular zone, third ventricle, mediodorsal thalamic nucleus · 182
- Subventricular zone, third ventricle, paraventricular thalamic nucleus · 146
- Subventricular zone, third ventricle, reuniens thalamic nucleus · 146, 180, 182, 186
- Sulcus limitans · 114, 116, 222, 368, 370
- Superior cerebellar artery · 58, 60, 200
- Superior (anterior) semicircular canal · 68-74, 106, 108, 114, 116, 136, 204, 208-218, 260
- Superior cerebellar peduncle · 74, 76, 88, 140, 142, 144, 146, 152, 154, 158, 188, 190, 200-204, 244, 246, 250, 296, 298, 300-308, 354, 382, 384, 392, 420, 424-428, 432, 436-440, 444, 486, 492, 508-512
- Superior cervical ganglion · 146, 212-216, 272
- Superior colliculus · 10-18, 22-32, 54-62, 68-74, 82, 86-94, 132, 134, 138-142, 146-158, 194-218, 232-242, 296-300, 304-310, 352-368, 376, 378, 426-444, 482-494, 502, 504
- Superior colliculus, ventricular zone, aqueduct · 200-212, 216, 368
- Superior glossopharyngeal ganglion · 2-6, 30, 114, 142, 144
- Superior mammillary nucleus · 54
- Superior medullary velum · 8-12, 16, 18, 22, 28, 32, 102-110, 210, 212, 370
- Superior oblique muscle · 122-126, 156, 178
- Superior olive · 10, 58-62, 104, 106, 144, 146, 156, 202-206, 262-266, 296, 308, 310, 362, 364, 402, 404, 420, 424, 426, 436, 488, 524-530
- Superior rectus muscle · 122-126, 178-184
- Superior sagittal sinus · 38, 40, 86, 88, 162, 164, 170-180, 230
- Superior semicircular canal · *See* Anterior (superior) semicircular canal
- Superior vagal (jugular) ganglion · 2-6, 26-30, 74, 76, 114, 116, 142, 144, 214-218, 270
- Superior vestibular nucleus · 62, 68, 104, 106, 138, 140, 206, 208, 256, 262, 294, 296, 366, 388, 392, 490, 492
- Suprachiasmatic nucleus · 152, 182, 192, 260, 296, 300, 304, 306, 310, 340, 406, 408, 430-434, 440, 474-478, 526-530
- Supramammillary decussation · 356, 484, 516
- Supramammillary nucleus · 140, 298, 354, 392, 394, 428, 430, 436, 516
- Supramammillary nucleus, lateral part · 484
- Supramammillary nucleus, medial part · 484
- Supraoptic nucleus · 190, 346, 404, 476, 478, 524, 526
- 
- T**
- Tectal neuroepithelium · 54, 72, 74, 82-88, 90-96, 150, 202-208, 214, 236, 240, 242, 256
- Tectospinal tract · 210, 270, 274, 276, 364, 366, 372, 488
- Tectum · 196, 198, 208, 376, 378
- Tectum, subventricular zone, aqueduct · 208
- Tectum, ventricular zone, aqueduct · 14, 16, 56-62, 68, 196, 198, 208
- Tegmental neuroepithelium · 64, 92-96
- Tegmentum · 196, 198
- Tegmentum, intermediate zone, aqueduct · 60
- Tegmentum, ventricular zone, aqueduct · 14, 16, 56-62, 68, 194-198
- Tela choroidea · 42
- Temporal cortex · 6, 256
- Temporal cortex, ventricular zone · 50
- Tenia tecta · 456, 458, 460
- Terete hypothalamic nucleus · 426
- Thalamic fasciculus · 134, 138
- Thalamic neuroepithelium · 48, 50, 84, 140, 142, 240-248
- Thalamocortical tract · 476, 478
- Thalamus · 290, 346, 424-434, 438, 440, 442, 444, 474-482, 506, 510-514

Third ventricle · 14-26, 44-54, 82-96,  
100-106, 138-148, 176-196, 236,  
240-258, 298, 300, 304, 308, 338-348,  
352, 354, 380, 382, 386, 388, 392, 396,  
398, 402, 406, 408, 430-440, 468-484,  
506, 510-520, 524-530

Third ventricle, intermediate zone, lateral  
preoptic area · 48

Third ventricle, intermediate zone, medial  
preoptic area · 46

Third ventricle, intermediate zone,  
paratenial thalamic nucleus · 178

Third ventricle, subventricular zone,  
mediodorsal thalamic nucleus · 182

Third ventricle, subventricular zone,  
paraventricular thalamic nucleus · 146

Third ventricle, subventricular zone,  
reuniens thalamic nucleus, · 146, 180,  
182, 186

Third ventricle, ventricular zone · 308,  
436

Third ventricle, ventricular zone, anterior  
hypothalamus · 50

Third ventricle, ventricular zone, anterior  
thalamic nucleus · 22, 26, 90

Third ventricle, ventricular zone, central  
medial thalamic nucleus · 92, 180, 182,  
186

Third ventricle, ventricular zone,  
epithalamus · 22, 24, 42, 134

Third ventricle, ventricular zone,  
hypothalamus · 194, 196, 306,

Third ventricle, ventricular zone, lateral  
dorsal thalamic nucleus · 86

Third ventricle, ventricular zone, lateral  
preoptic area · 46

Third ventricle, ventricular zone,  
mammillary area · 54

Third ventricle, ventricular zone, medial  
habenular nucleus · 26, 180

Third ventricle, ventricular zone, medial  
preoptic area · 22, 48

Third ventricle, ventricular zone,  
mediodorsal thalamic nucleus · 182

Third ventricle, ventricular zone,  
paraventricular hypothalamic nucleus ·  
92

Third ventricle, ventricular zone,  
paraventricular thalamic nucleus · 24,  
26, 92, 146, 180

Third ventricle, ventricular zone, posterior  
hypothalamus · 54

Third ventricle, ventricular zone, posterior  
thalamic nucleus · 86, 90

Third ventricle, ventricular zone, pretectum  
· 22, 24, 28

Third ventricle, ventricular zone, reuniens  
thalamic nucleus · 146, 180, 182, 186,  
250

Thyroid gland · 214

Tongue · 12-18, 22, 50-56, 110, 112, 132,  
134, 138-144, 154, 180, 182, 186-200,  
268, 270

Tooth bud, lower molar · 266-270

Tooth bud, upper incisor · 144, 264

Trachea · 210-216

Transverse cerebral fissure · 502

Transverse pontine fibers · 520, 524

Transverse sinus · 42-46, 52

Trapezoid body · 364, 526

Triangular septal nucleus · 336, 470,  
514-518

Trigeminal motor nucleus · 10, 30, 32, 56,  
58, 66, 100, 102, 106, 108, 138, 140,  
142, 158, 202, 204, 258, 260, 290, 294,  
364, 394, 420, 424, 440, 444, 488, 516,  
518

Trigeminal nerve (V), motor root · 8, 32,  
56, 66, 102-108, 132-138, 198, 204,  
364, 486, 488, 518, 524

Trigeminal nerve (V), sensory root · 2-8,  
32, 56-60, 66, 100, 102, 106, 110, 112,  
132-136, 158, 198-202, 258, 260, 288,  
360, 396, 444, 488, 524

Trigeminal (semilunar) ganglion · 2-8, 32,  
54-60, 66, 100-112, 128-140, 156, 158,  
194-202, 258-262, 520

Trochlear nerve (IV) · 6, 8, 62, 66, 68, 72,  
74, 92, 94, 126-134, 156

Trochlear nucleus · 14-18, 26, 62, 64, 94,  
146, 206, 252, 308, 364, 380, 434, 438,  
488, 506

Tuberoinfundibular tract · 406, 528, 530

Tympanic cavity · 2-8, 30, 32, 132, 134,  
138-142

---

*U*

Upper eyelid · 176-180, 184, 186

Upper lip · 266-270

Utricle · 2, 4, 32, 70-74, 106-116, 128,  
130, 136, 138, 208-212, 262, 264, 268,  
270

---

*V*

Vagus nerve (X) · 4-8, 26-30, 74, 76, 114,  
116, 142, 212-220, 266-370, 496

Vascular organ of lamina terminalis · 140,  
186, 244, 298, 338, 470

Vascular plexus of choroid fissure · 42

Ventral anterior thalamic nucleus · 134,  
152, 244, 246, 512

Ventral cochlear nucleus · 4, 32, 68, 72, 74,  
108, 132-138, 208, 210, 262-366, 368,  
394, 396, 414, 416, 490-494, 516-520

Ventral diencephalic sulcus · 190, 348

Ventral funiculus · 10-16, 156, 158, 224,  
398-402, 420, 424, 428

- Ventral hippocampal commissure · 298, 304-308, 334, 396, 432-444, 468, 470, 510-514
- Ventral horn · 10-16, 396-404, 408, 426
- Ventral horn, motor neurons · 156, 224, 400, 404
- Ventral lateral geniculate nucleus · 12, 32, 50-54, 88, 130, 154, 156, 182, 186-192, 242, 244, 288, 290, 294, 344-350, 386, 420-426, 474, 476, 478, 480, 518
- Ventral lateral thalamic nucleus · 30, 46, 48, 88, 90, 132, 152, 180, 182, 244, 246, 250, 296, 298, 342, 388, 392, 430, 444, 474, 476, 512, 514
- Ventral medial thalamic nucleus · 90, 140, 146, 182, 190, 244, 246, 248, 250, 298, 308, 310, 342, 344, 346, 392, 394, 432, 438-444, 474, 478, 480, 512, 514
- Ventral nucleus of lateral lemniscus · 60, 198, 200, 202, 256, 294, 296, 360, 362, 386, 388, 392-396, 424, 426, 440, 444, 486, 516-520
- Ventral pallidum · 26, 28, 96, 102, 128, 130, 148, 156, 176, 180, 284, 286, 320, 322-328, 406, 426, 456-460, 466, 526
- Ventral posterior lateral thalamic nucleus · 14, 30, 32, 48, 50, 52, 88, 90, 132, 152, 186-190, 244, 290, 294, 296, 344-348, 388, 392, 394, 422-428, 476-480, 510-514
- Ventral posterior medial thalamic nucleus · 14, 16, 28, 48, 50, 52, 88, 90, 134, 138, 152, 154, 186-190, 244, 296, 344-348, 352, 388, 392, 394, 426-430, 442, 444, 476-482, 510-514
- Ventral premammillary nucleus · 482
- Ventricular space (of eye) · *See* Intraretinal (subretinal) space (of eye)
- Ventral spinocerebellar tract · 276
- Ventral tegmental area (A10) · 16, 18, 22, 26-30, 56-60, 90, 138, 144, 146, 152, 198-204, 250, 252, 296-300, 304, 356, 358, 360-364, 384, 388, 430, 432-436, 486, 512
- Ventral tegmental decussation · 486
- Ventral tegmental nucleus · 490
- Ventral thalamus, neuroepithelium · 14-18, 28-32, 48-52
- Ventricular zone, aqueduct, inferior colliculus · 72, 76, 210-214, 218, 254, 368
- Ventricular zone, aqueduct, periaqueductal gray · 32
- Ventricular zone, aqueduct, superior colliculus · 200, 210, 212, 216, 368
- Ventricular zone, aqueduct, tectum · 14, 16, 56, 58, 60, 62, 68, 196, 198, 208
- Ventricular zone, aqueduct, tegmentum · 14, 16, 56-62, 68, 194, 196, 198
- Ventricular zone, central canal, spinal cord · 16, 428
- Ventricular zone, fourth ventricle · 490, 518
- Ventricular zone, fourth ventricle, cerebellum · 74, 76, 150, 214, 216, 220, 368, 370
- Ventricular zone, fourth ventricle, medulla · 14, 18, 78, 150, 304
- Ventricular zone, fourth ventricle, pons · 58, 60-66, 366
- Ventricular zone, fourth ventricle, precerebellar nuclei · 368
- Ventricular zone, fourth ventricle, vestibular nuclei · 74, 76
- Ventricular zone, hippocampus · 18, 22, 26, 28, 40-48, 130, 142, 146, 154-158, 174-182, 186, 190-194, 232-240, 244, 246, 252, 254, 290, 338
- Ventricular zone, lateral ventricle, accumbens nucleus · 42
- Ventricular zone, lateral ventricle, amygdala · 346, 348
- Ventricular zone, lateral ventricle, auditory cortex · 350
- Ventricular zone, lateral ventricle, cingulate cortex · 22, 38, 40
- Ventricular zone, lateral ventricle, cortex · 6, 8, 28, 120-124, 130, 144-148, 152-158, 164, 166, 172, 174, 176, 230-238, 280, 284, 288, 290, 304, 306, 318-340, 376, 378, 382-390, 394, 398, 404-406, 438, 444, 456, 462, 464, 466, 502-506, 520
- Ventricular zone, lateral ventricle, frontal cortex · 38, 42, 84, 162
- Ventricular zone, lateral ventricle, frontopolar cortex · 36
- Ventricular zone, lateral ventricle, lateral ganglionic eminence · 38-48, 88, 172-178, 236, 238, 290, 320, 322-340
- Ventricular zone, lateral ventricle, medial ganglionic eminence · 24, 46, 48, 334-340
- Ventricular zone, lateral ventricle, occipital cortex · 50, 52
- Ventricular zone, lateral ventricle, pallidum · 30
- Ventricular zone, lateral ventricle, parietal cortex · 40-44, 48
- Ventricular zone, lateral ventricle, septal area · 24, 40, 42, 44, 168, 310, 318, 320-324, 456
- Ventricular zone, lateral ventricle, subiculum · 128
- Ventricular zone, neural retina · 94, 98, 100, 112, 122, 124, 184, 186, 254, 256, 258, 260

Ventricular zone, lateral ventricle, temporal cortex · 50

Ventricular zone, olfactory ventricle, olfactory bulb · 26, 126, 138, 140, 144, 146, 244, 246, 288-292, 300, 314, 316, 406, 450, 454, 520

Ventricular zone, third ventricle · 28, 306, 308, 436

Ventricular zone, third ventricle, anterior hypothalamus · 50

Ventricular zone, third ventricle, anterior thalamic nucleus · 22, 26, 90

Ventricular zone, third ventricle, central medial thalamic nucleus · 92, 180, 182, 186

Ventricular zone, third ventricle, epithalamus · 22, 24, 42, 134

Ventricular zone, third ventricle, hypothalamus · 194, 196, 306

Ventricular zone, third ventricle, lateral dorsal thalamic nucleus · 86

Ventricular zone, third ventricle, lateral preoptic area · 46

Ventricular zone, third ventricle, mammillary area · 54

Ventricular zone, third ventricle, medial habenular nucleus · 26, 180

Ventricular zone, third ventricle, medial preoptic area · 22, 48

Ventricular zone, third ventricle, mediodorsal thalamic nucleus · 182

Ventricular zone, third ventricle, paraventricular hypothalamic nucleus · 92

Ventricular zone, third ventricle, paraventricular thalamic nucleus · 24, 26, 92, 146, 180

Ventricular zone, third ventricle, posterior hypothalamus · 54

Ventricular zone, third ventricle, posterior thalamic nucleus · 86, 90

Ventricular zone, third ventricle, preectum · 22, 24, 28

Ventricular zone, third ventricle, reuniens thalamic nucleus · 146, 180, 182, 186, 250

Ventromedial hypothalamic nucleus · 14, 16, 20, 24, 30, 52, 100-108, 144, 147, 152, 194, 258, 260, 296-308, 346, 348, 352, 402, 404, 430-434, 478-482, 526-530

Vermis · 70-76, 150, 154, 156, 218, 302, 368, 370, 380, 382, 494-498, 506-510

Vertebral artery · 76, 220

Vestibular nerve (VIII) · 4, 30, 62, 68, 112-116, 268, 270

Vestibular neuroepithelium · 12, 60, 70, 72, 102-106, 110, 114, 206, 208, 260, 264, 392

Vestibular nuclei, ventricular zone, fourth ventricle · 74, 76

Vestibular (Scarpa's) ganglion · 2-6, 30, 32, 60, 62, 68, 110-114, 132-136, 204-210, 264

Vestibulocochlear nerve (VIII) · 2, 6, 30, 32, 68, 70, 72, 106-110, 134-140, 206, 208-216, 264-368, 414, 416, 490-494

Visual cortex · 230-236, 240, 280, 282, 284, 286, 290, 294, 346, 348, 352, 378, 380, 414-420, 480, 482, 502, 504

Vitreous space · 180-184, 258

Vomer · 138, 172-176, 260, 262

Vomeronasal nerve · 134, 138, 140, 172-178, 292, 294, 448, 516, 518

Vomeronasal organ · 46, 106-110, 134, 138, 172-178, 260

---

**W**

Whisker (vibrissa) follicle · 120-124, 162-166, 170, 172-178, 188, 192, 256, 258, 262-270

White layer of superior colliculus · 304, 432-444

White matter (of cortex) · 280, 284-292, 304, 316-340, 376, 378, 382, 390, 434, 454-462, 466, 502-506

---

**Z**

Zona incerta · 14-18, 28-32, 50-54, 90, 92, 132, 134, 138, 148, 152, 188-194, 244-250, 294, 296, 308, 310, 342-350, 354, 388, 392, 426-430, 438-442, 474-482, 510-516

Zona incerta, dorsal part · 352

Zona incerta, ventral part · 294, 352, 394

---

**I - XII**

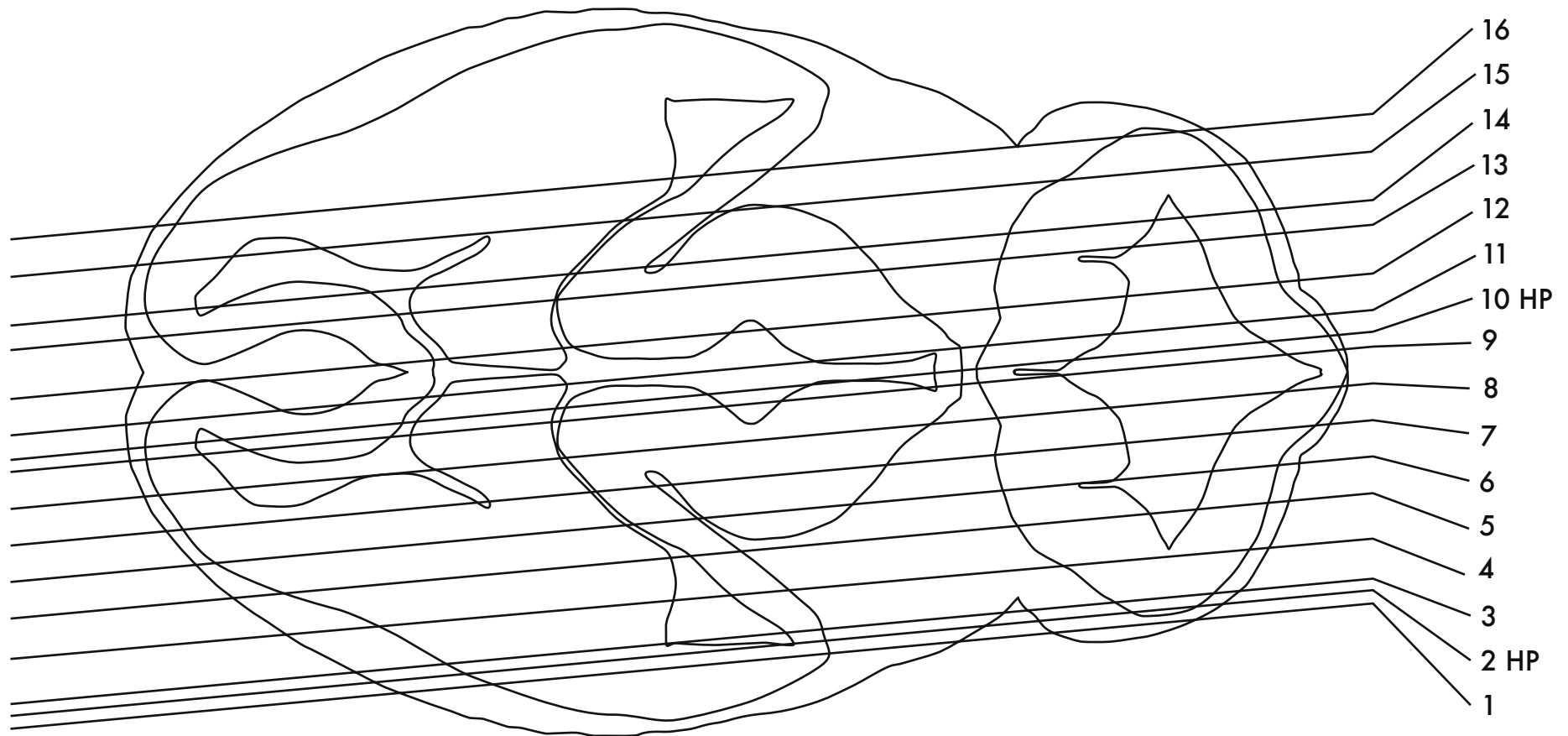
I (Olfactory nerve) · 10, 14-18, 24-30, 38-44, 96, 100, 102, 128, 130-134, 140-148, 152, 168-176, 246, 250-254, 316, 406, 448-452, 522, 524

II (Optic nerve) · 100, 126-134, 138, 154-158, 182, 184-190, 258, 280-284, 288, 290, 294, 428, 434, 436, 466-472, 528, 530

III (Oculomotor nerve) · 10, 12, 30, 32, 50, 54, 56, 90-96, 106, 128, 130, 154, 158, 182-190

IV (Trochlear nerve) · 6, 8, 62, 66, 68, 72, 74, 92, 94, 126-134, 156

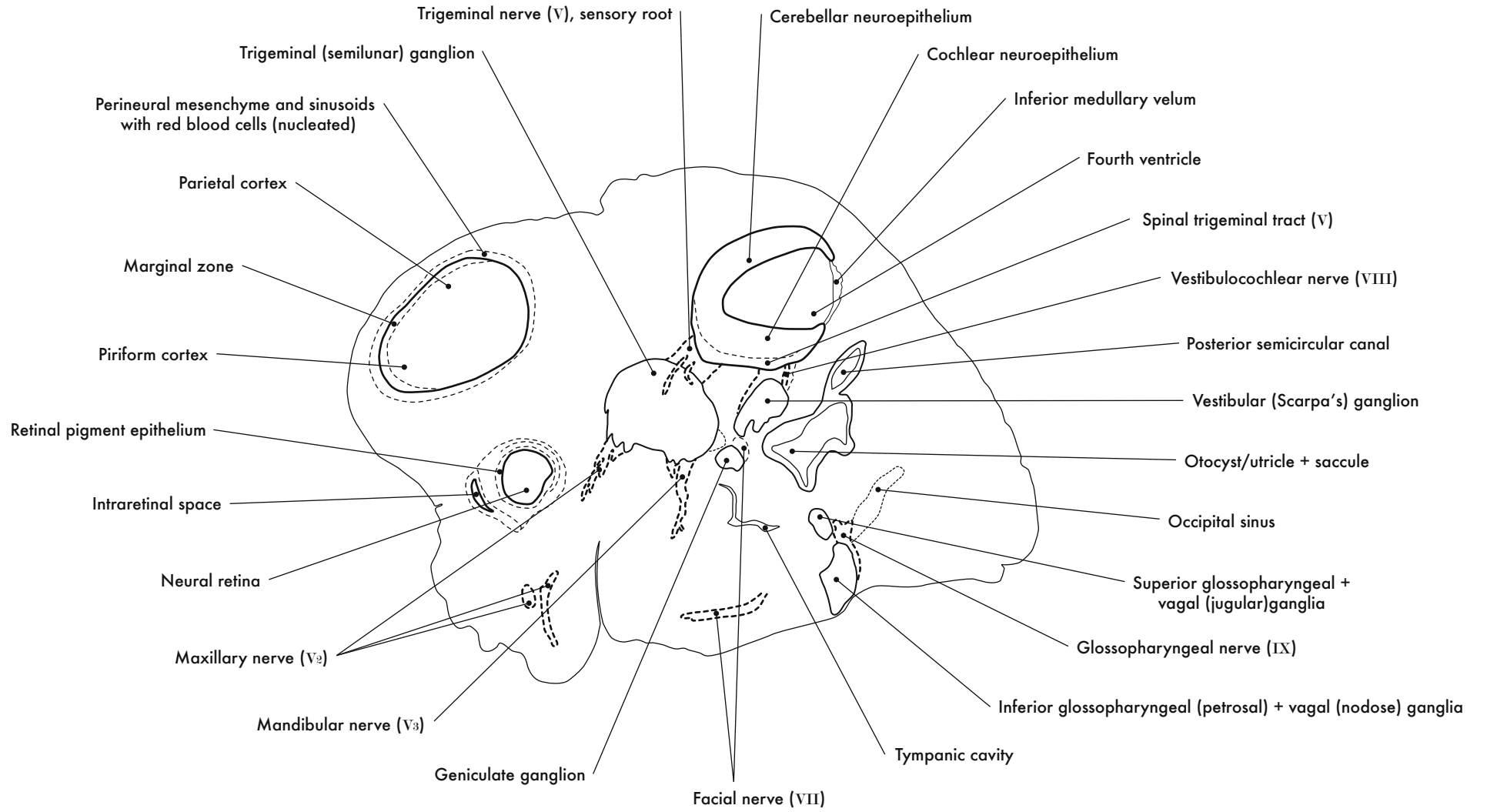
- V (Mesencephalic trigeminal tract) · 96, 290, 294, 298-302, 376, 378, 504
- V (Spinal trigeminal tract) · 2-8, 30, 32, 58-62, 68-78, 96, 100-116, 132-148, 152, 154, 200-226, 258-262, 266-276, 364, 366-372, 396, 398, 414-420, 440, 444, 490-498, 516-520
- V (Trigeminal nerve, motor root) · 8, 32, 56, 66, 102-108, 132-138, 198, 204, 364, 486, 488, 518, 524
- V (Trigeminal nerve, sensory root) · 2-8, 32, 56-60, 66, 100, 102, 106, 110, 112, 132-136, 158, 198-202, 258, 260, 288, 360, 396, 444, 488, 524
- V<sub>1</sub> (Ophthalmic nerve) · 6, 8, 52, 100, 108, 110, 132, 134, 138, 156, 158, 260, 262
- V<sub>2</sub> (Maxillary nerve) · 2, 6-10, 44-52, 102-106, 112, 116, 124-134, 138, 154, 156, 176-182, 186, 188, 190, 260, 262
- V<sub>3</sub> (Inferior alveolar nerve) · 194
- V<sub>3</sub> (Lingual nerve) · 194
- V<sub>3</sub> (Mandibular nerve) · 2-10, 52, 54, 106, 110-116, 126, 130-134, 154-158, 194-198, 266, 268
- VI (Abducens nerve) · 52, 126-130, 156, 188, 190, 262
- VII (Facial nerve) · 2-10, 26-32, 60-68, 108-116, 128, 130, 136, 142, 144, 147, 148, 156, 158, 200-214, 262, 264, 268, 288, 290, 294, 296, 310, 364, 366, 396, 416, 418, 426, 438, 488, 490, 518, 520
- VII (Facial nerve, genu) · 60-64, 112, 152, 154, 206, 208, 262, 264, 298, 308, 366, 434, 492
- VIII (Cochlear nerve) · 4, 28, 62, 68, 108, 114, 116, 144, 266, 268
- VIII (Vestibular nerve) · 4, 30, 62, 68, 112-116, 268, 270
- VIII (Vestibulocochlear nerve) · 2, 6, 30, 32, 68, 70, 72, 106-110, 134-140, 206-216, 264, 366, 368, 414, 416, 490, 492, 494
- IX (Glossopharyngeal nerve) · 2-6, 26, 30, 68-72, 114, 142, 144, 212, 214, 266, 268, 496
- X (Vagus nerve) · 4-8, 26-30, 74, 76, 114, 116, 142, 212-220, 266, 268, 370, 496
- XI (Accessory nerve) · 216, 496
- XII (Hypoglossal nerve) · 6, 8, 12, 14, 22-28, 32, 76, 132, 138, 142, 144, 147, 148, 152, 194

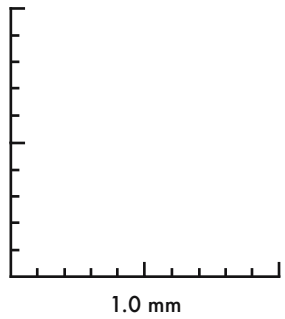
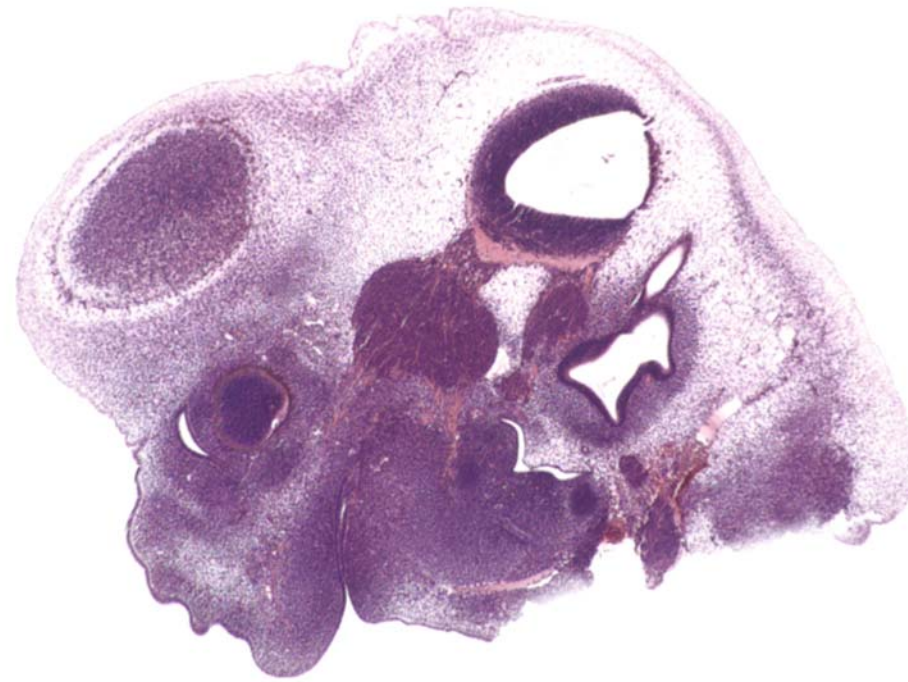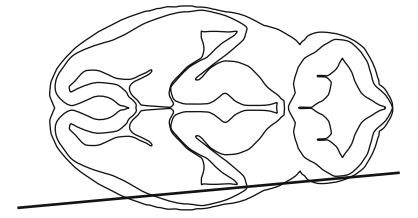


HP denotes image enlargement

## GESTATIONAL DAY 12 (GD 12) SAGITTAL SECTIONS

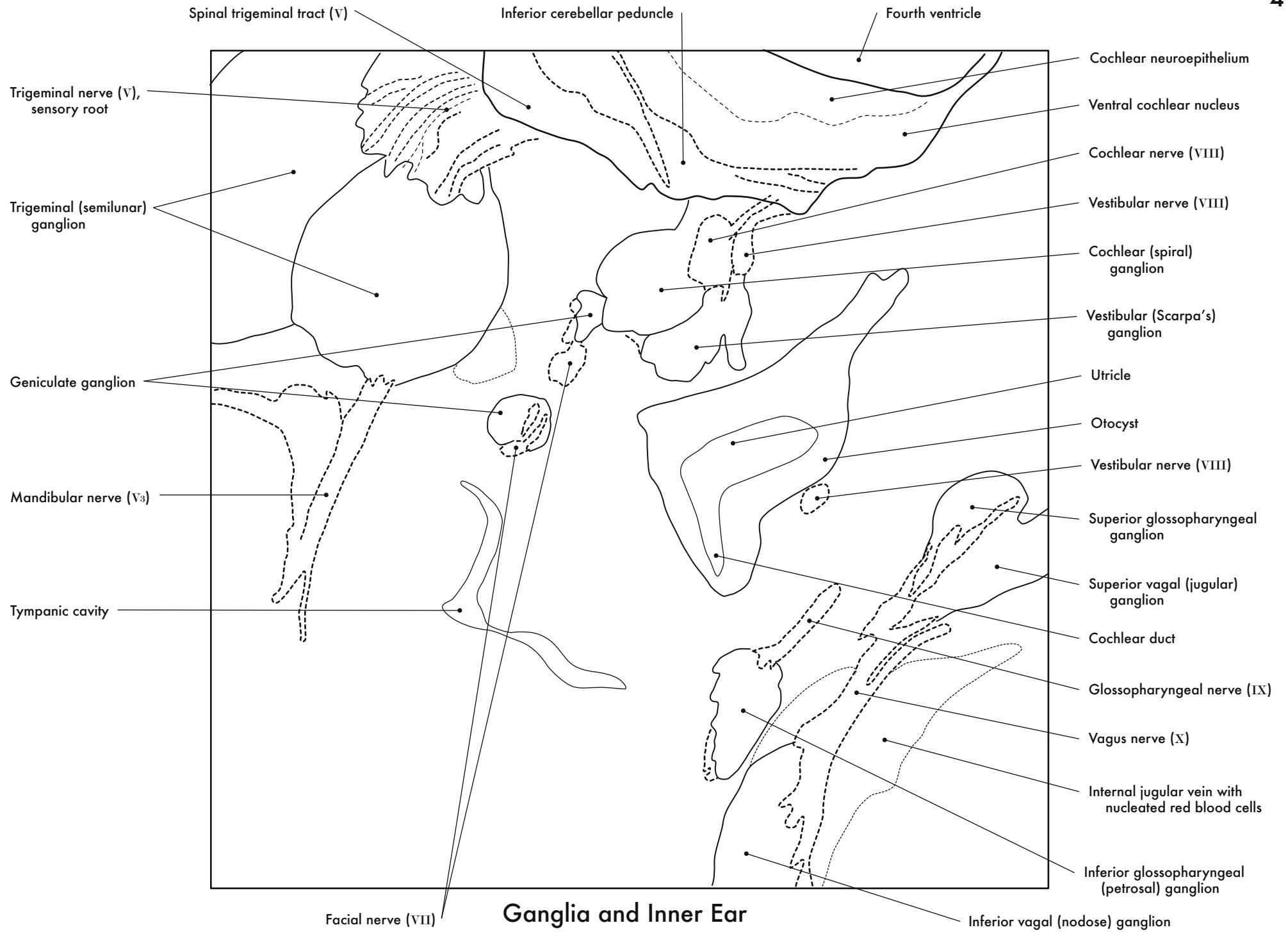


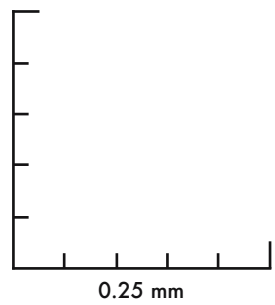
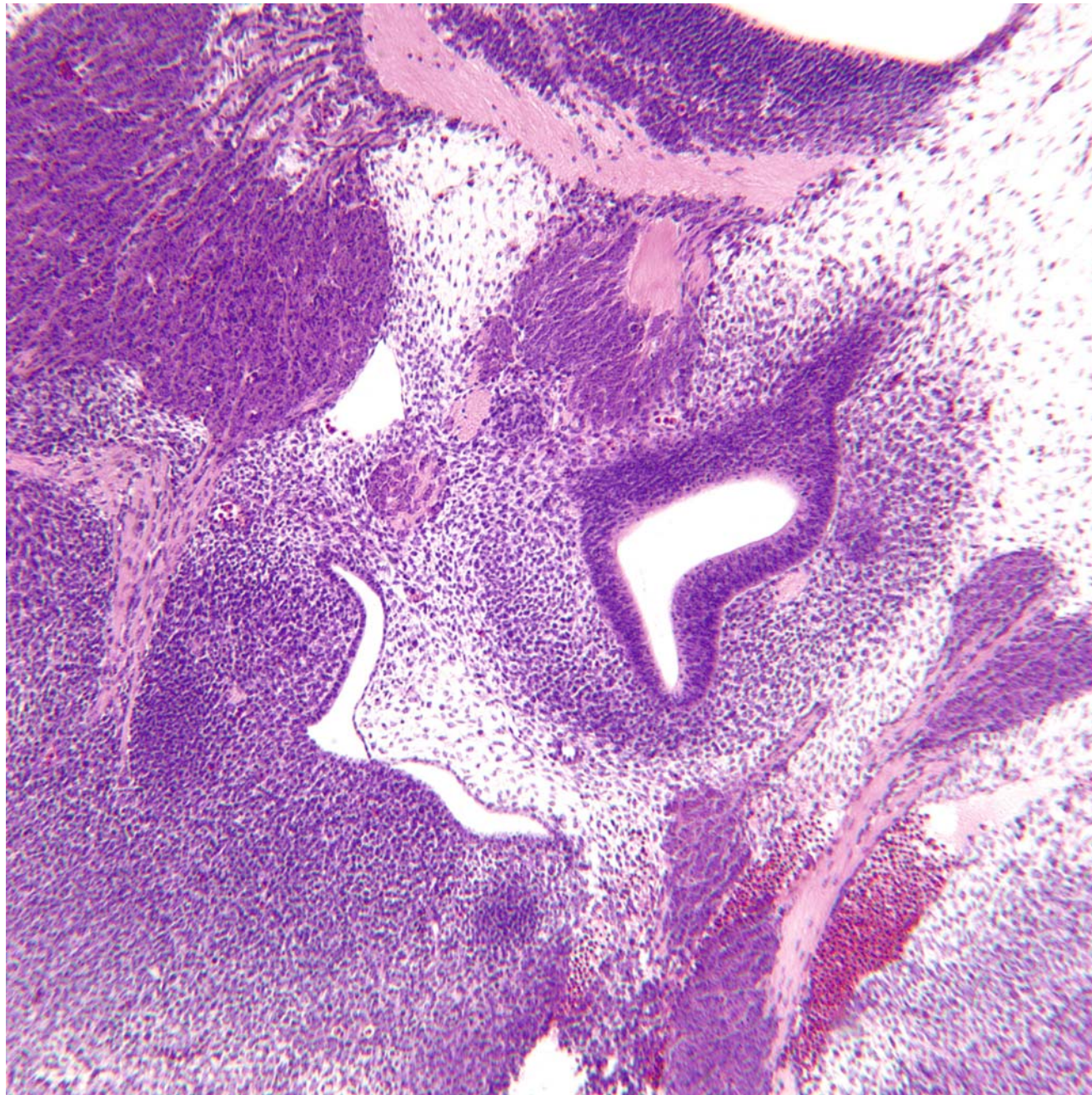
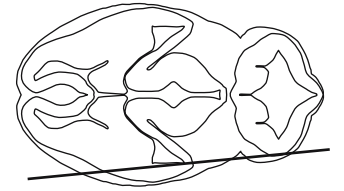
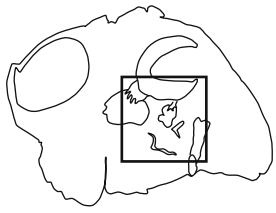




GD 12 SAGITTAL 1

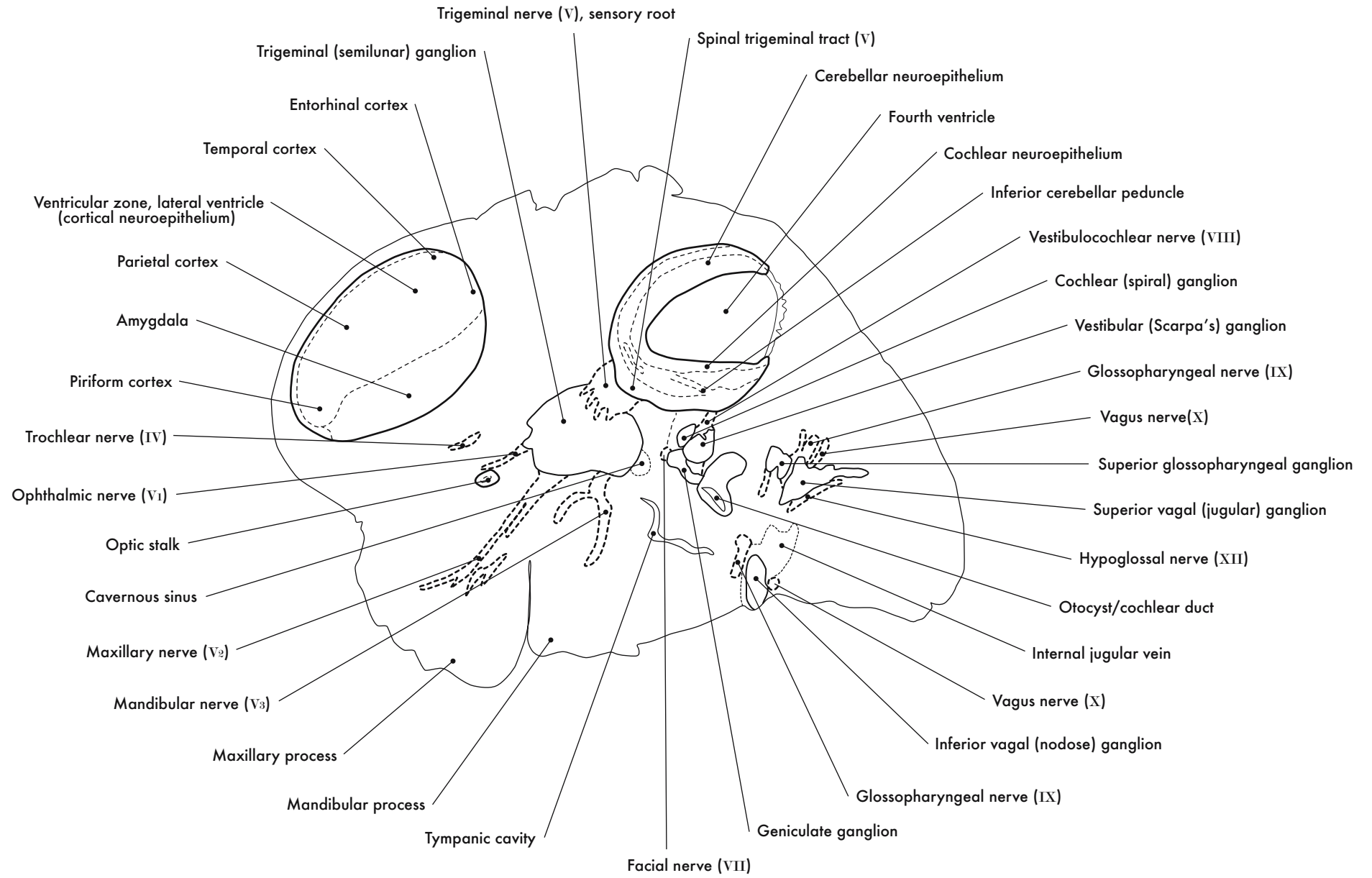


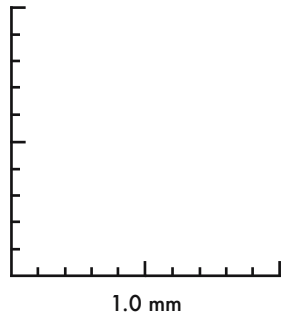
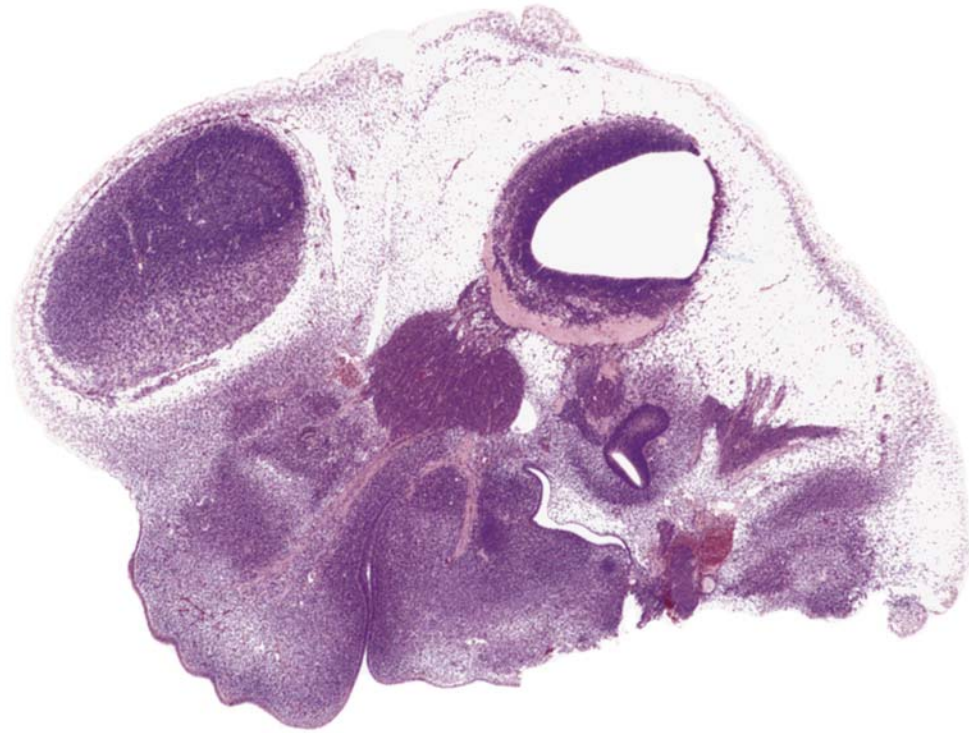
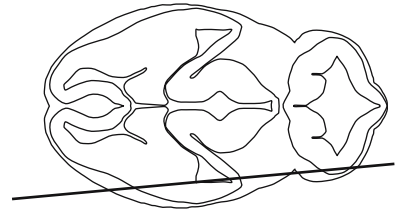




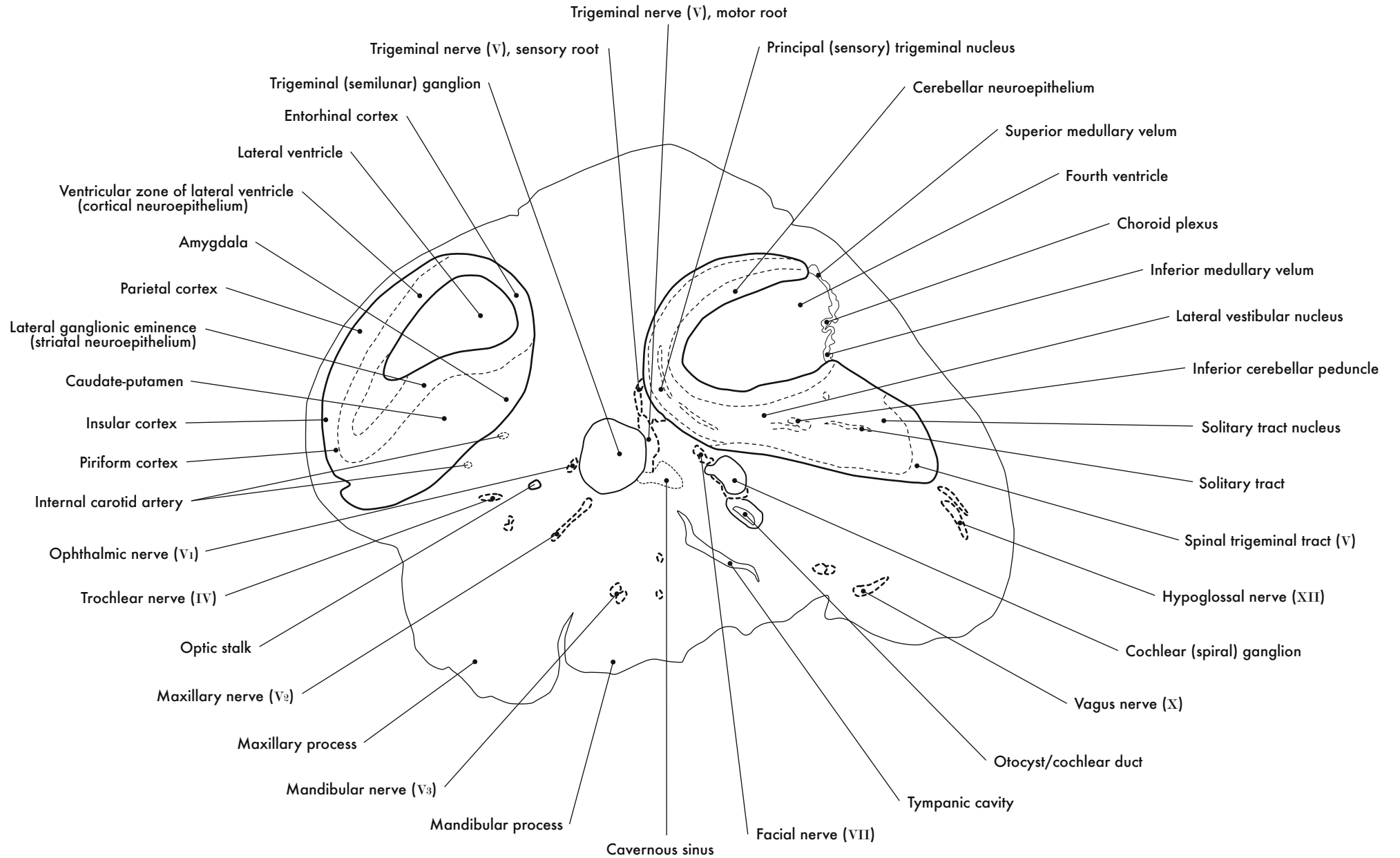
GD 12 SAGITTAL 2

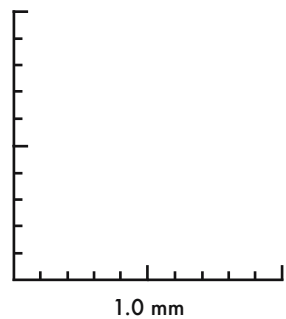
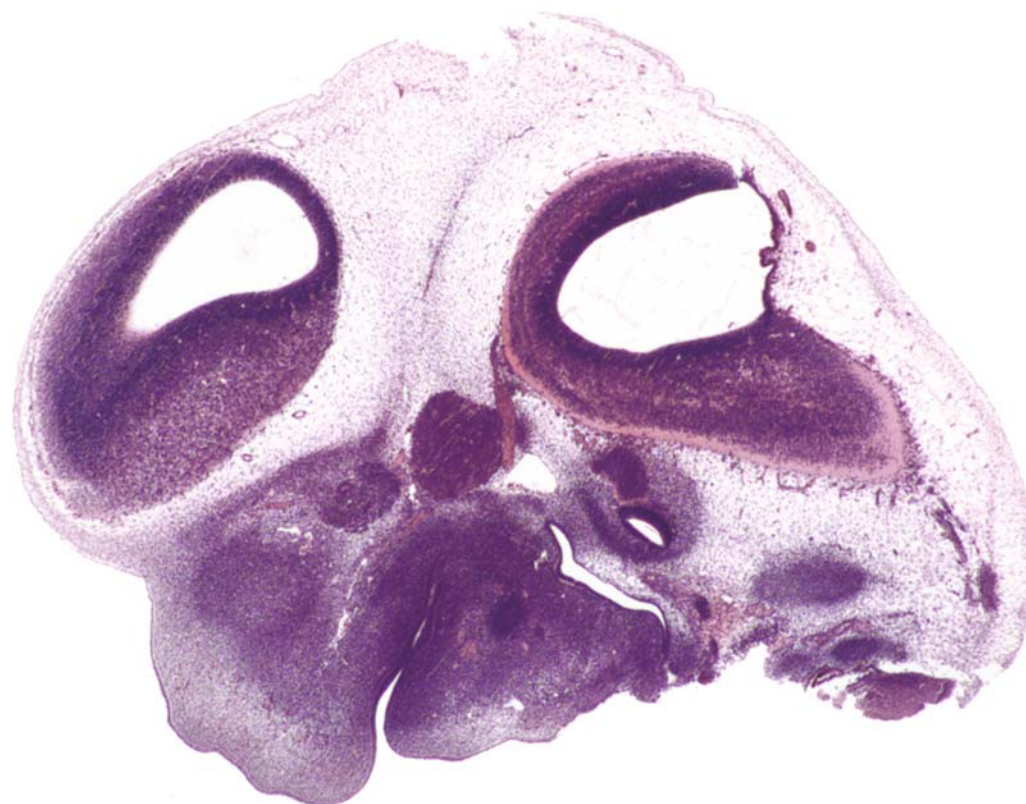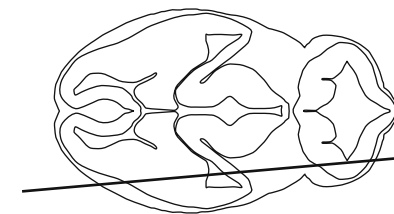






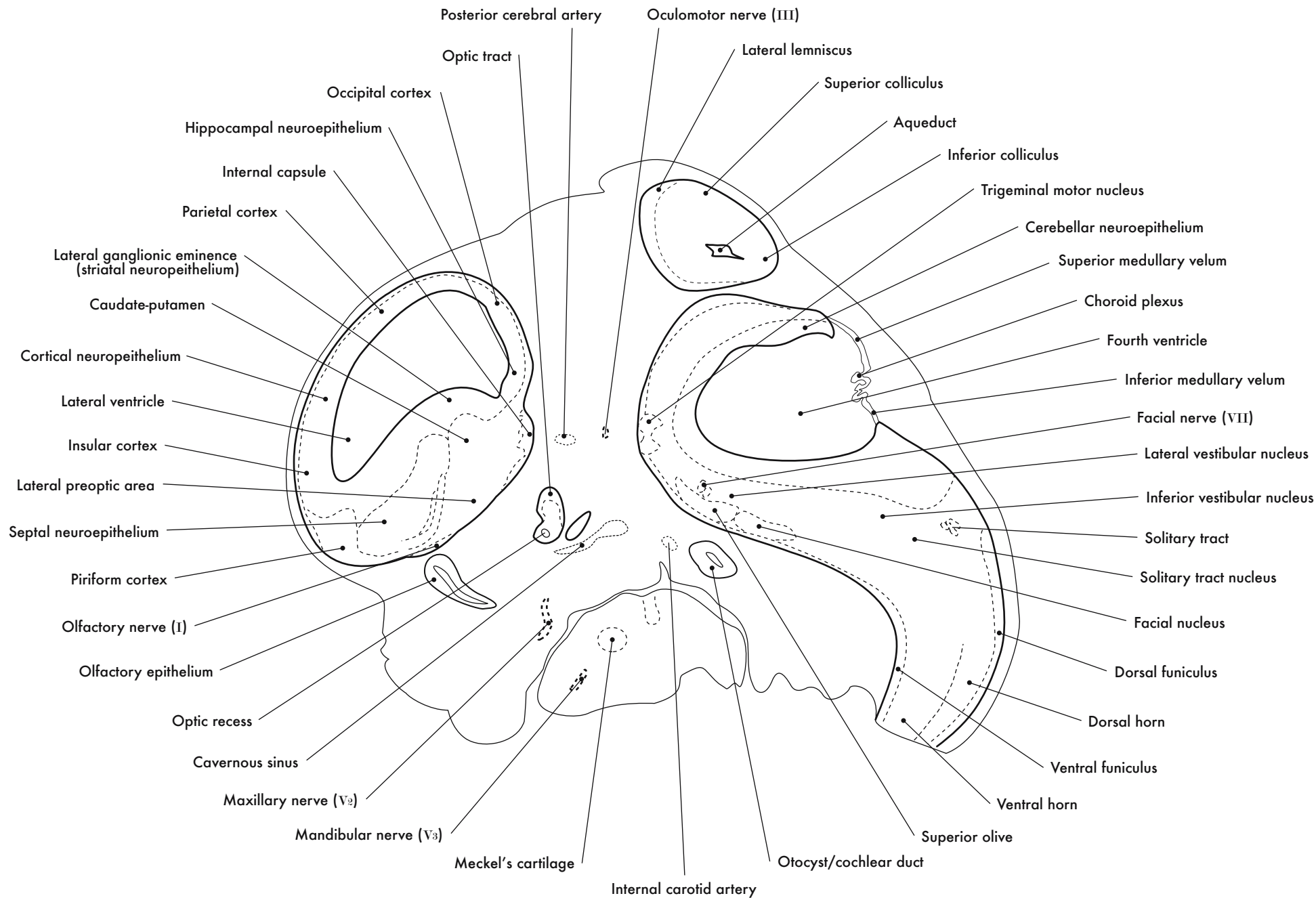
GD 12 SAGITTAL 3

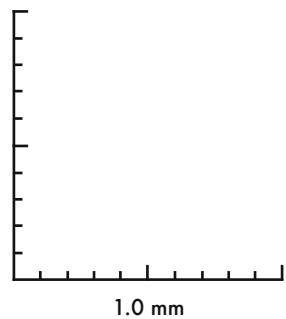
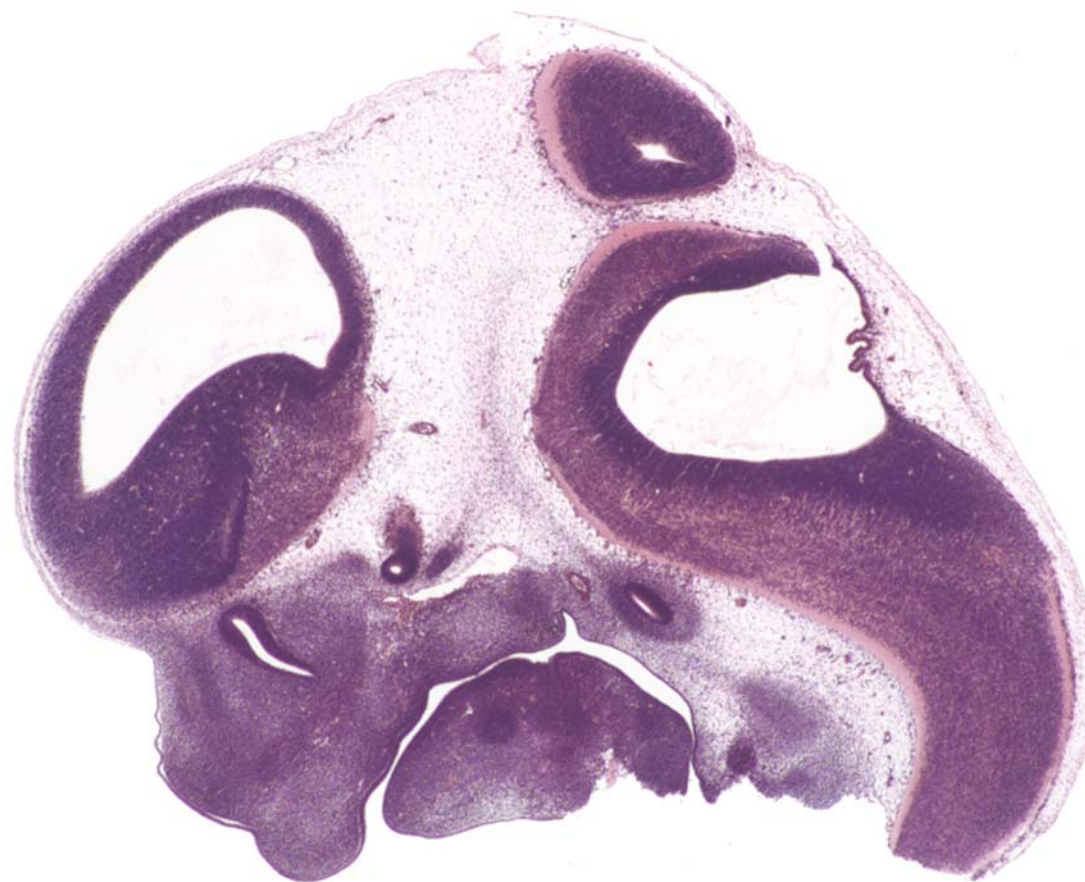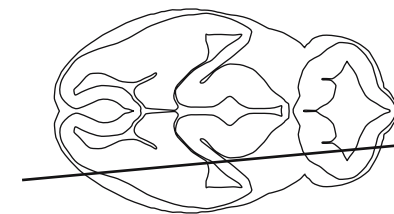




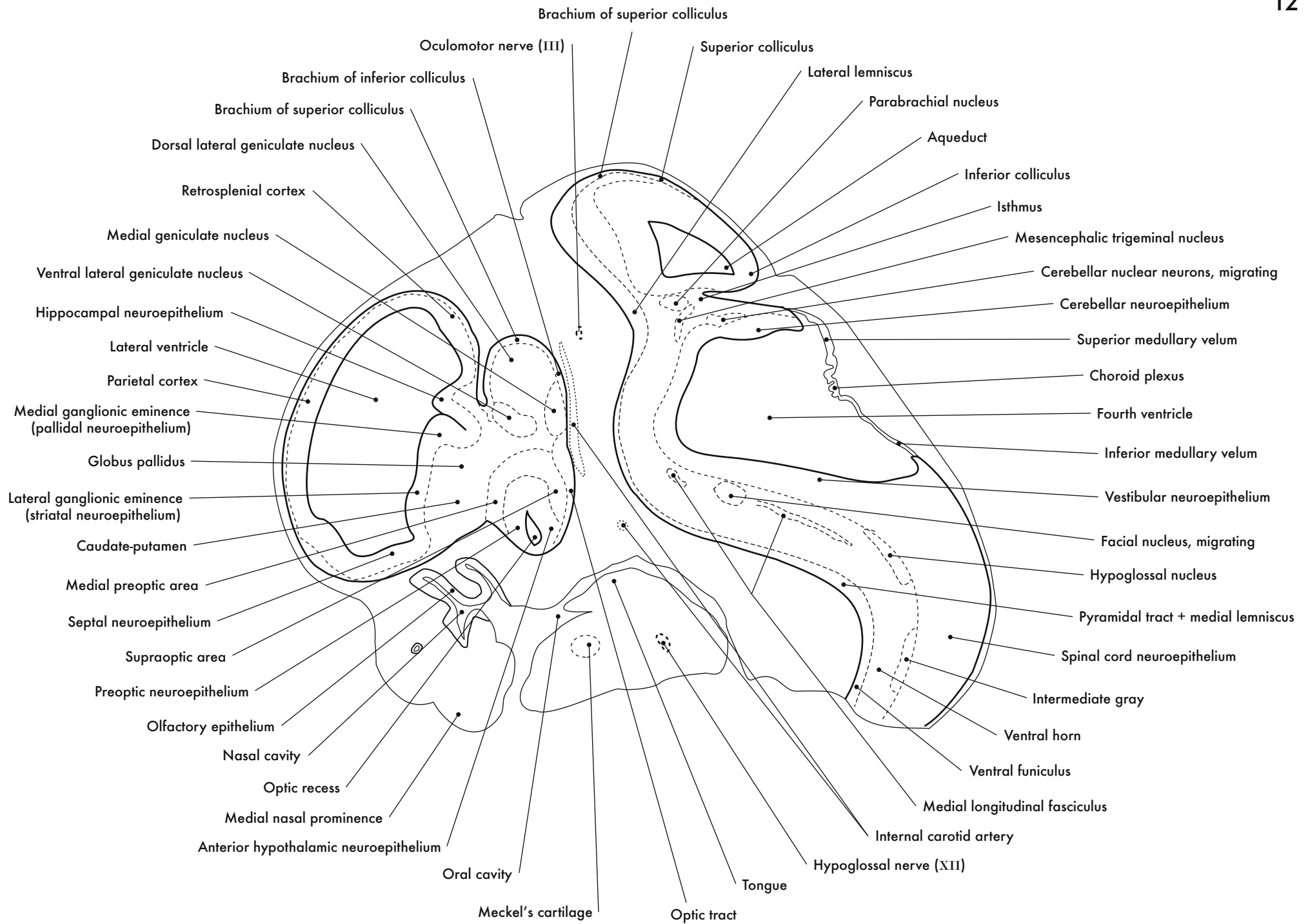
GD 12 SAGITTAL 4

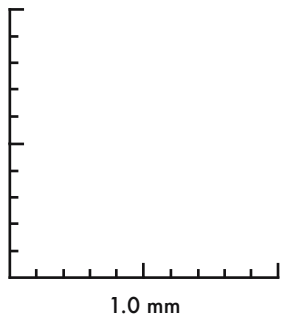
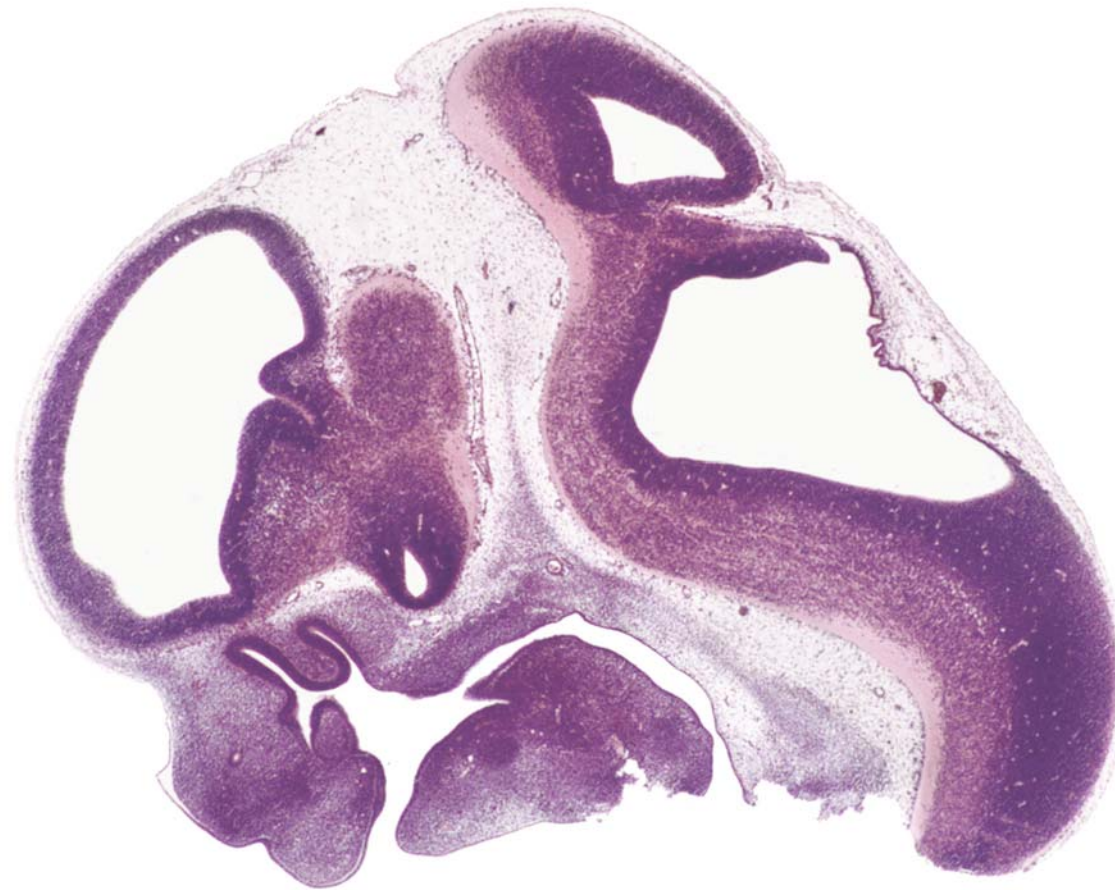
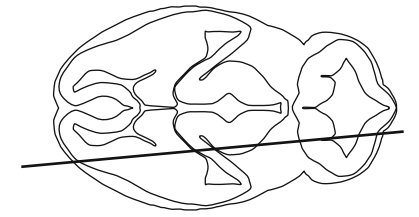




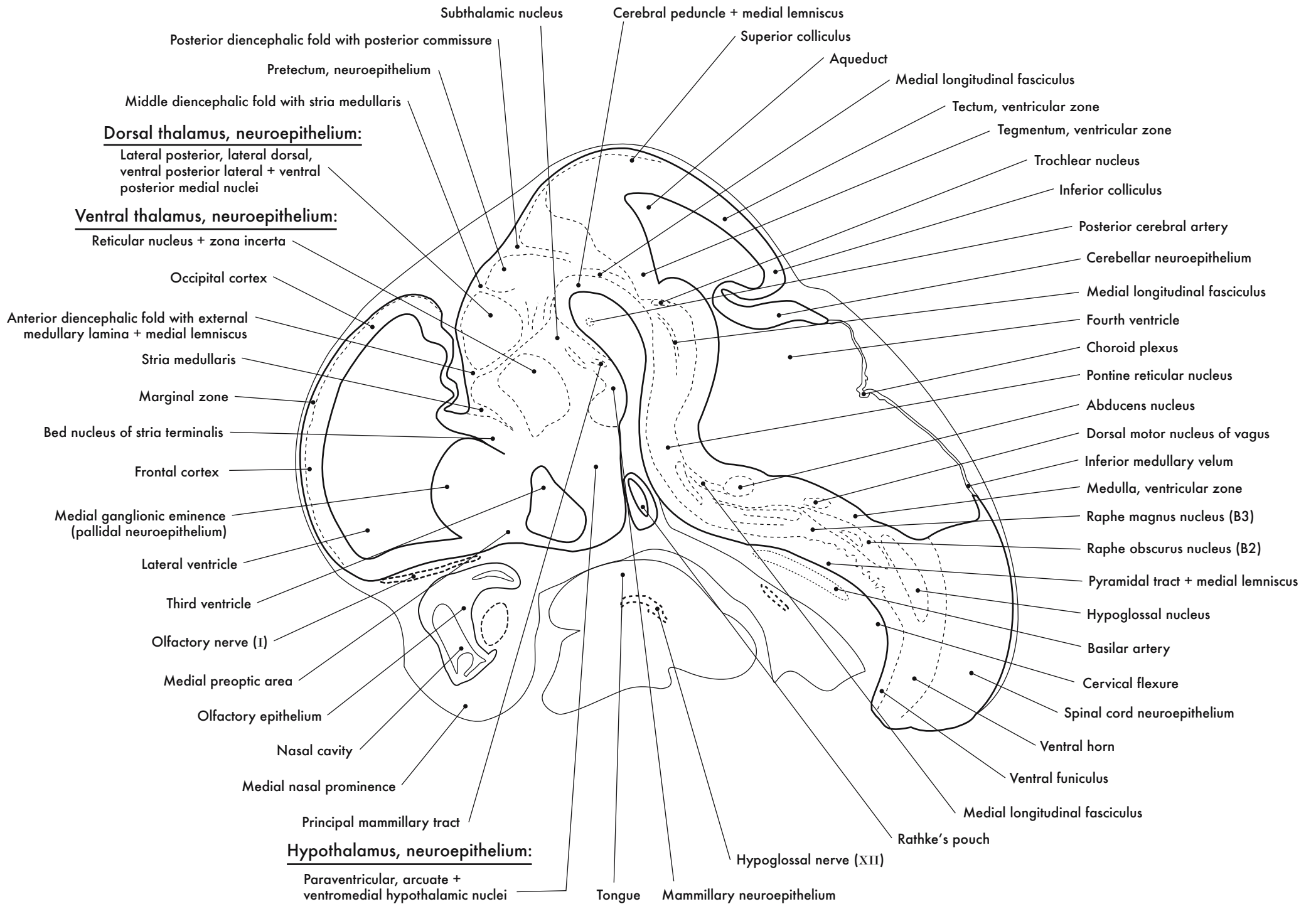


GD 12 SAGITTAL 5

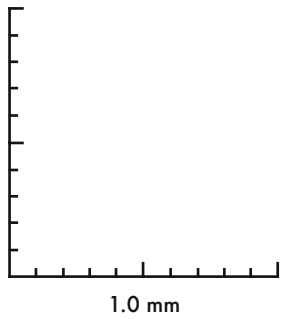
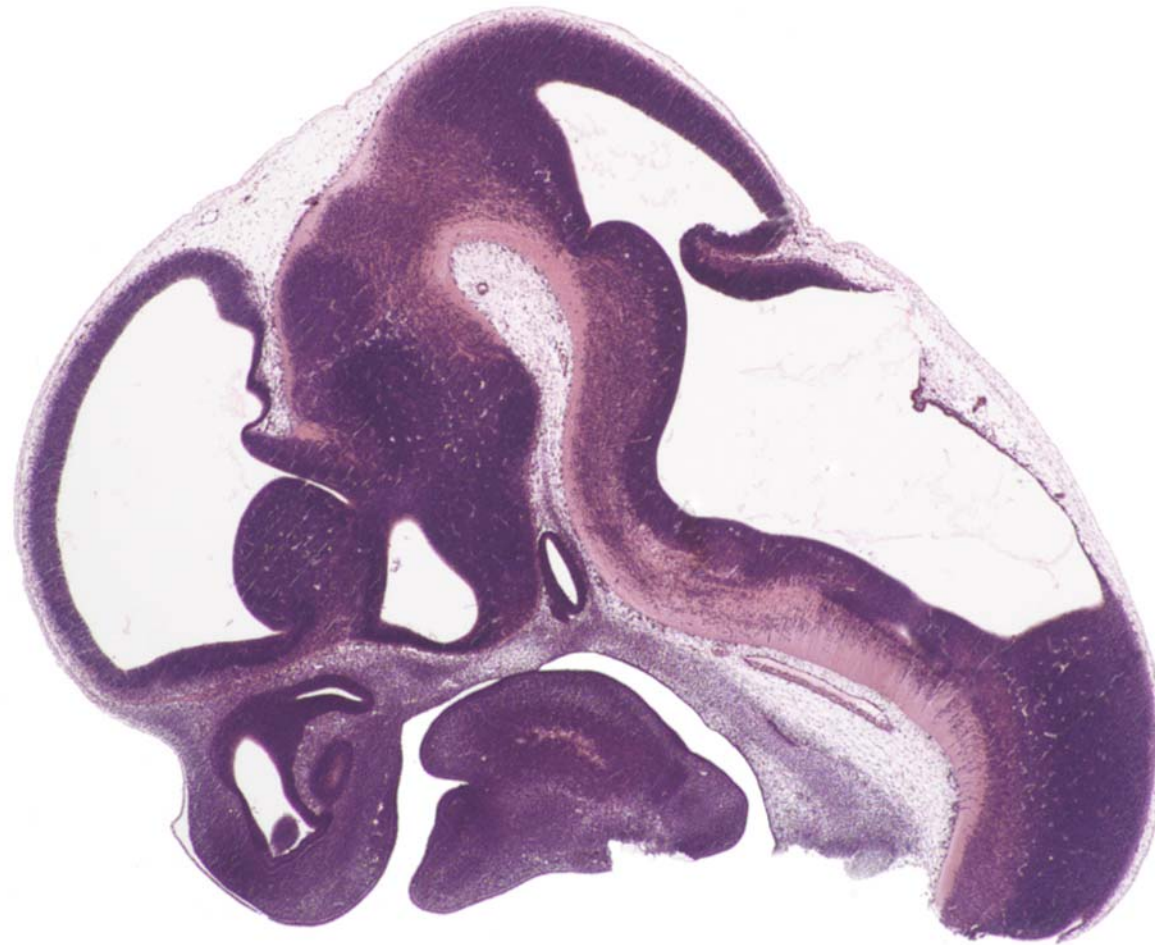
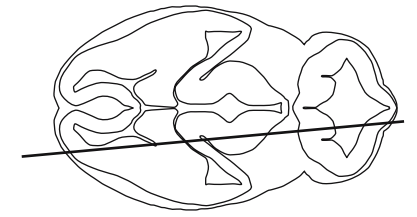




GD 12 SAGITTAL 6

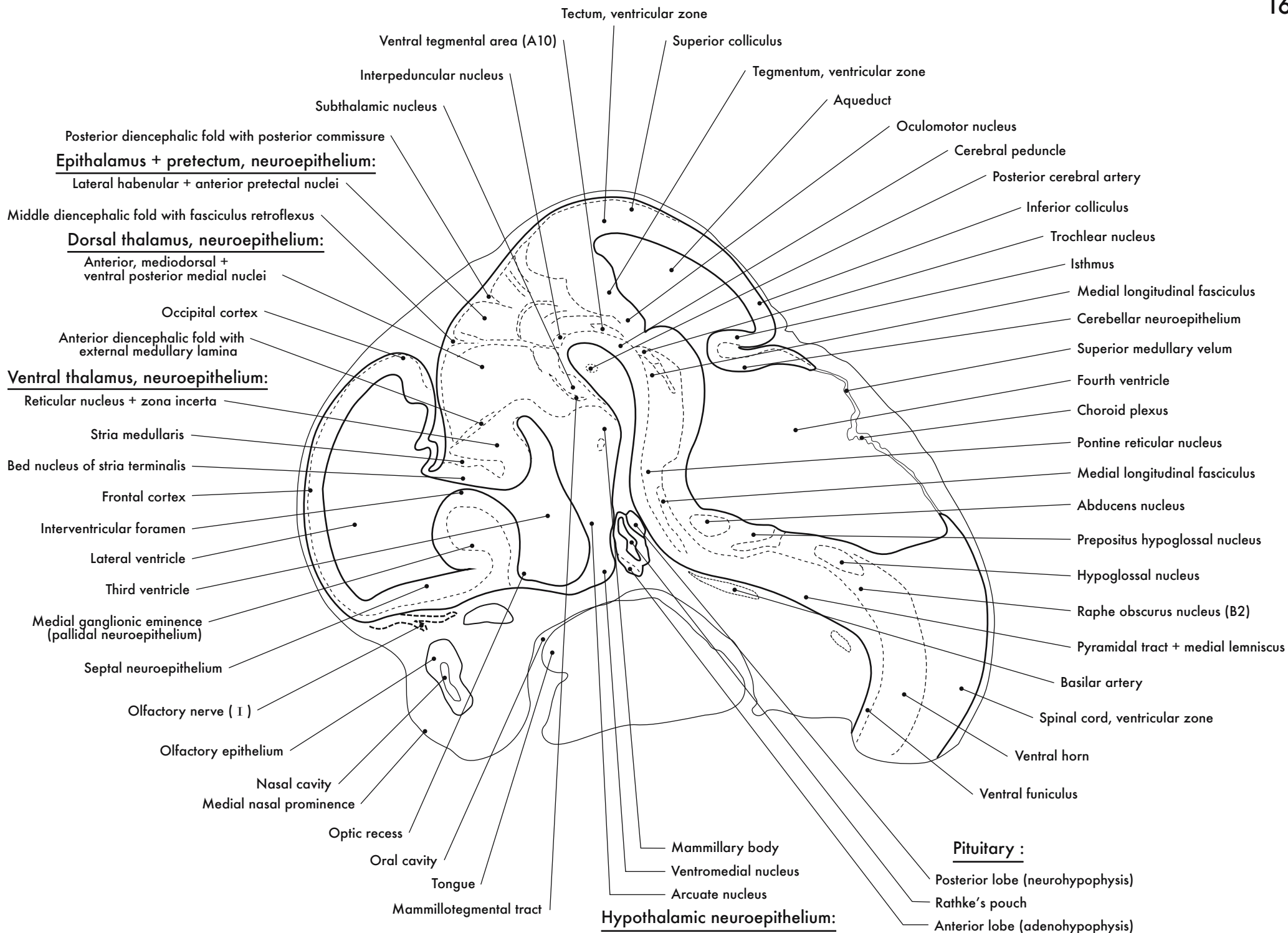


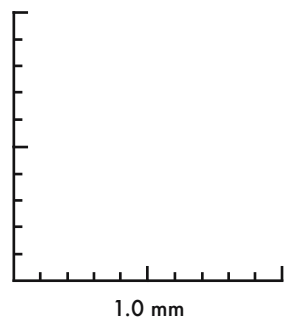
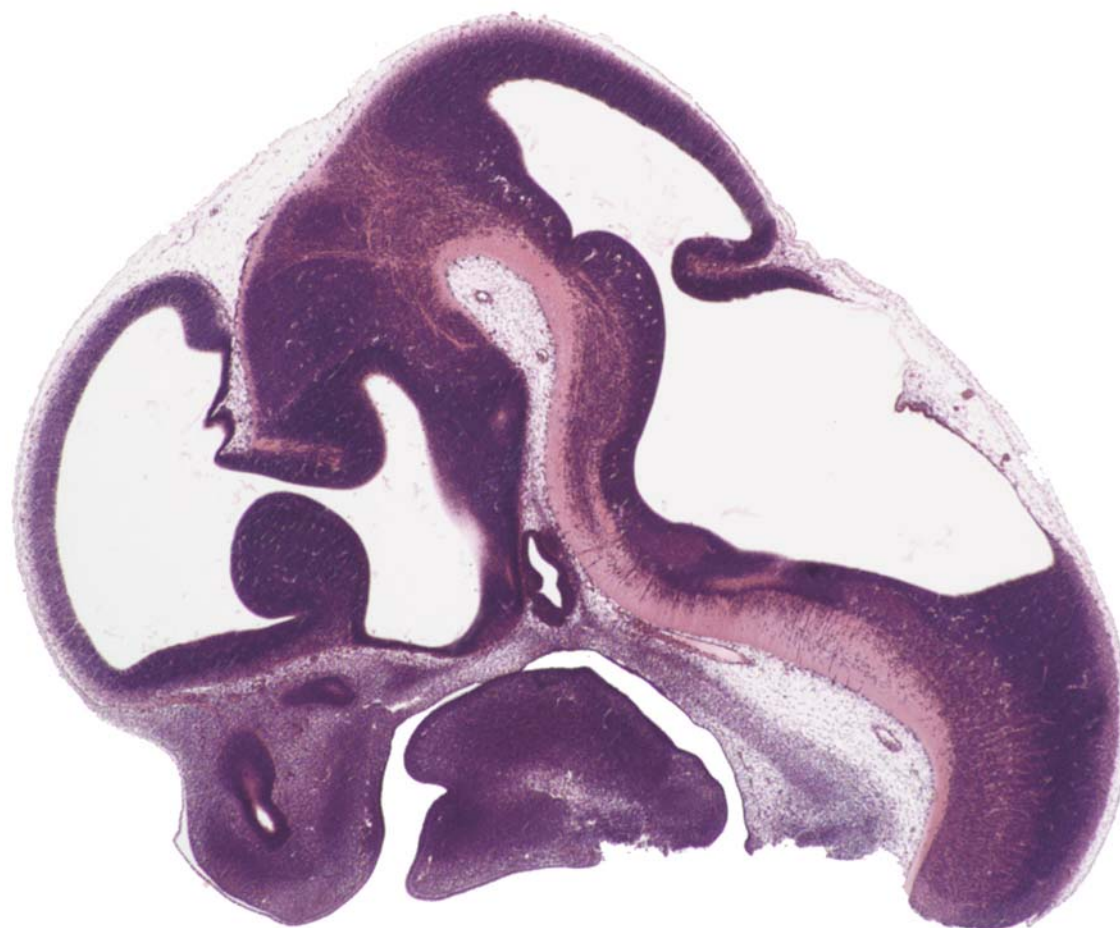
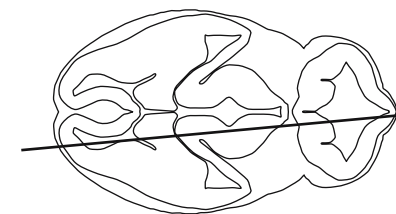




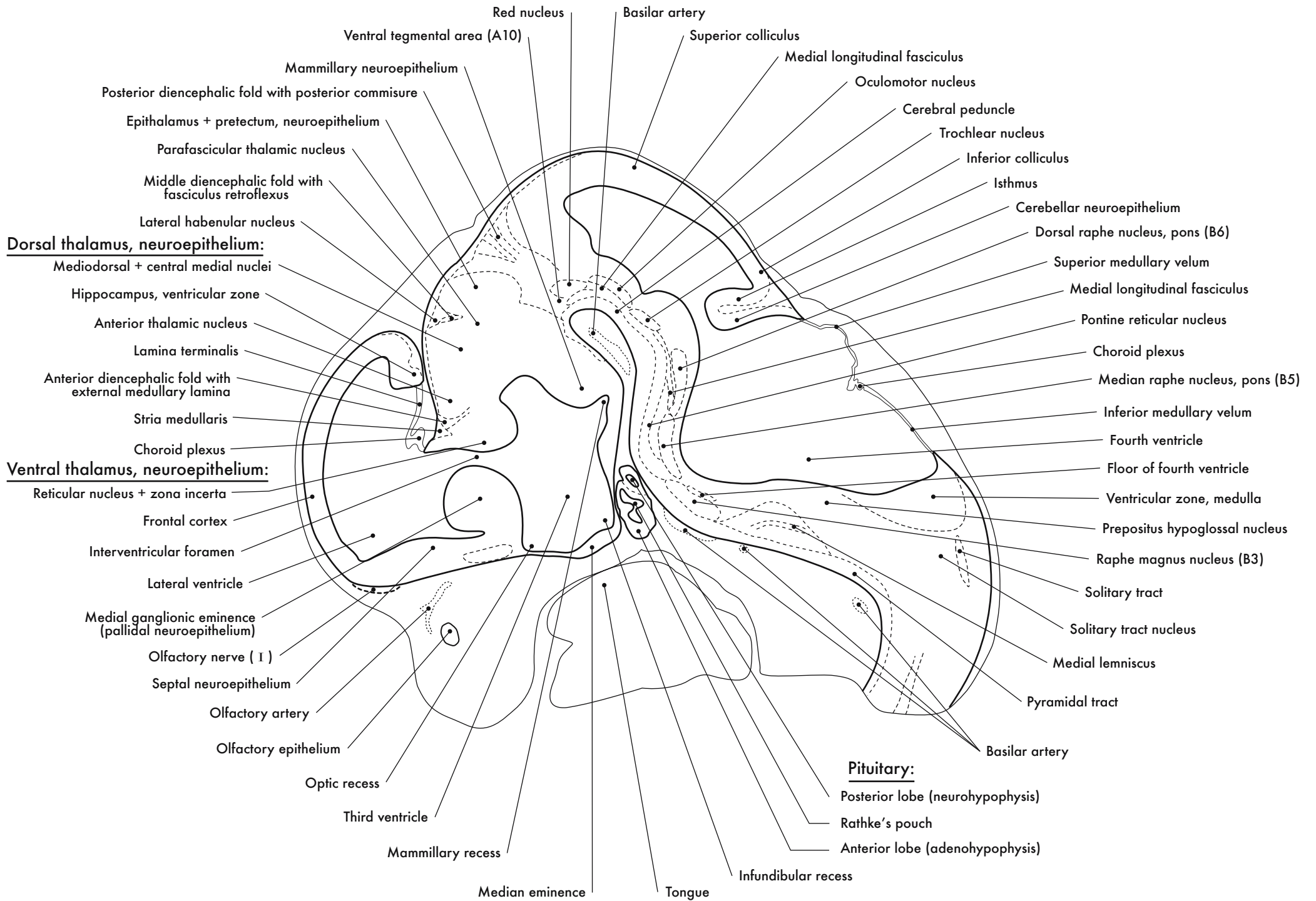
GD 12 SAGITTAL 7

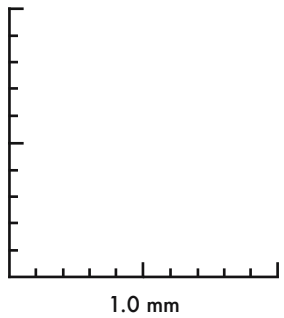
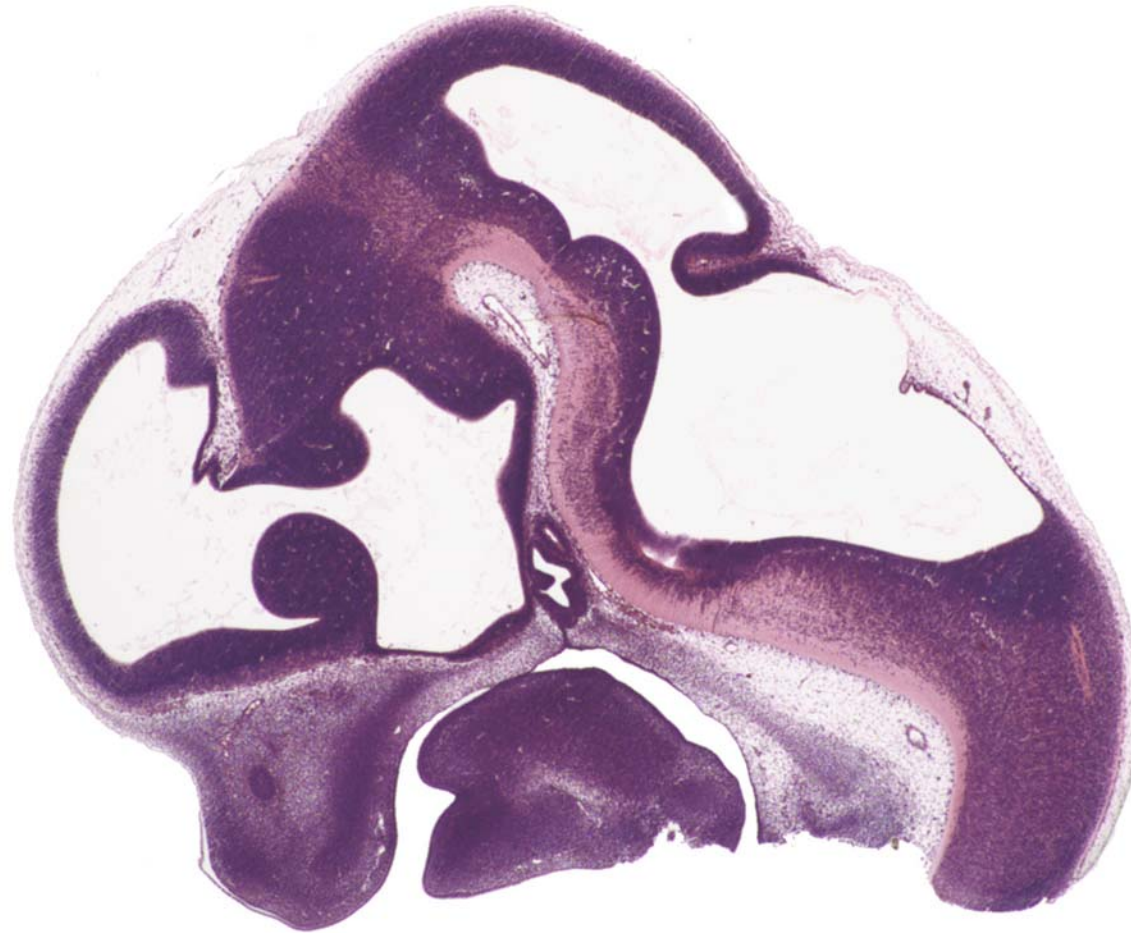
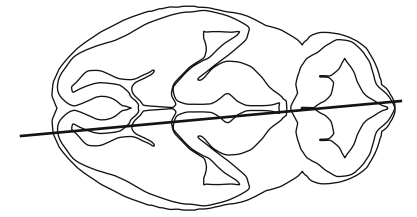




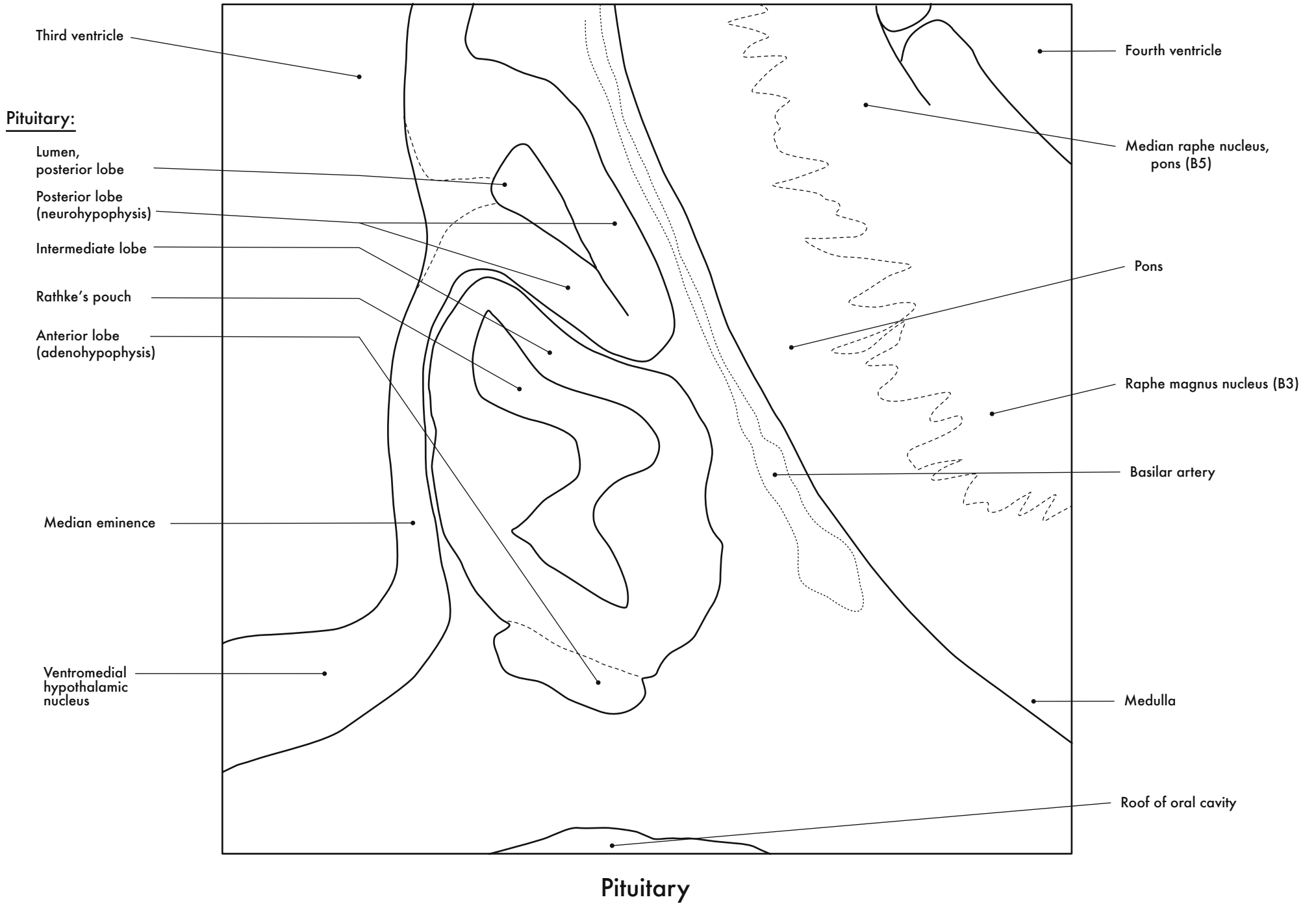


GD 12 SAGITTAL 8

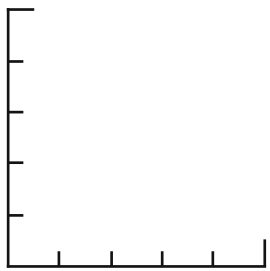
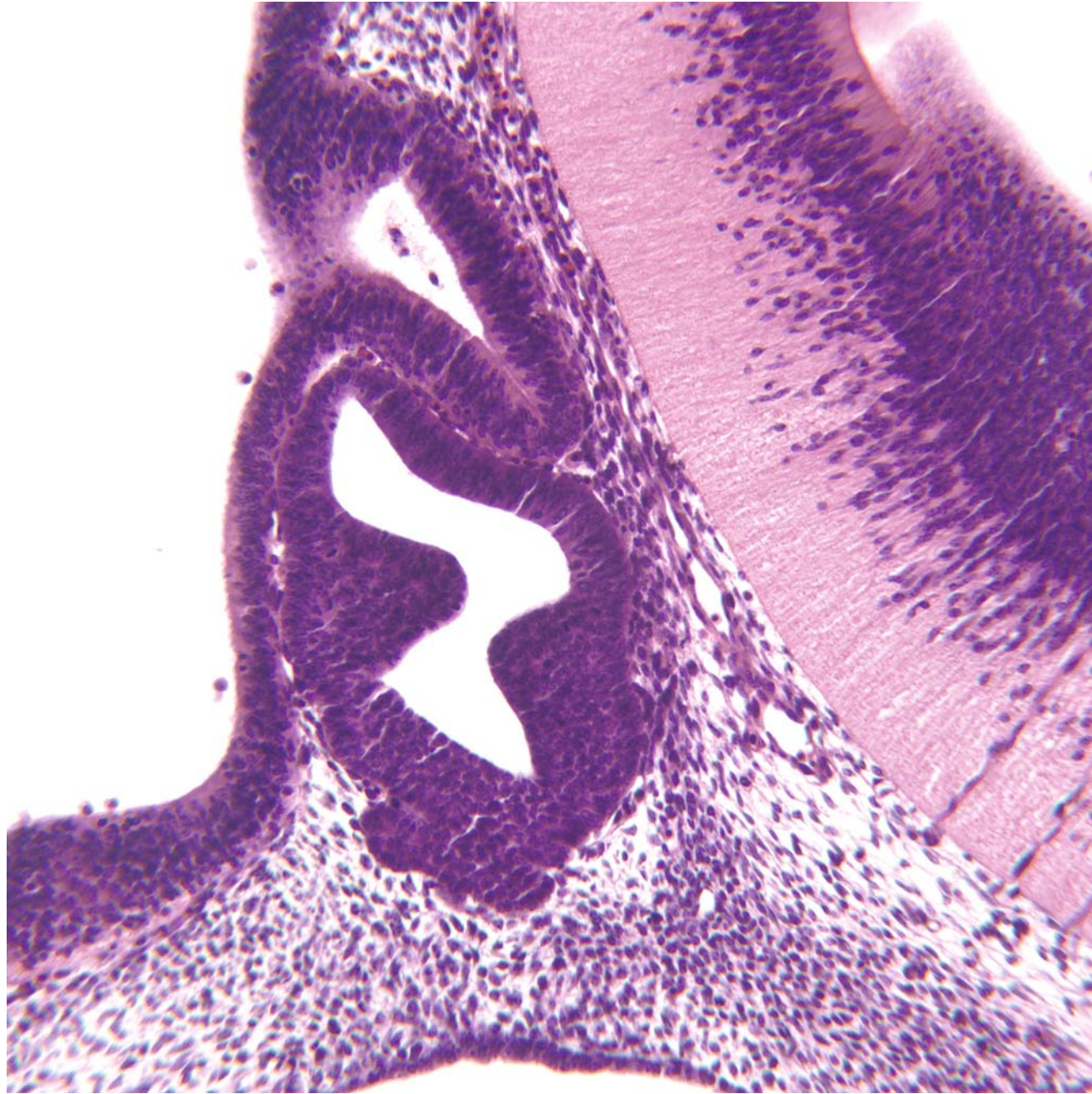
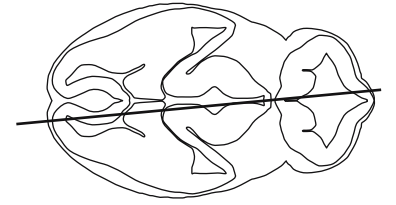
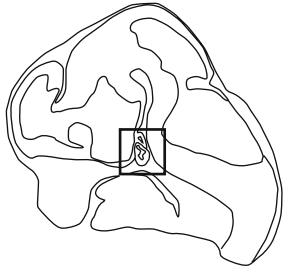




GD 12 SAGITTAL 9



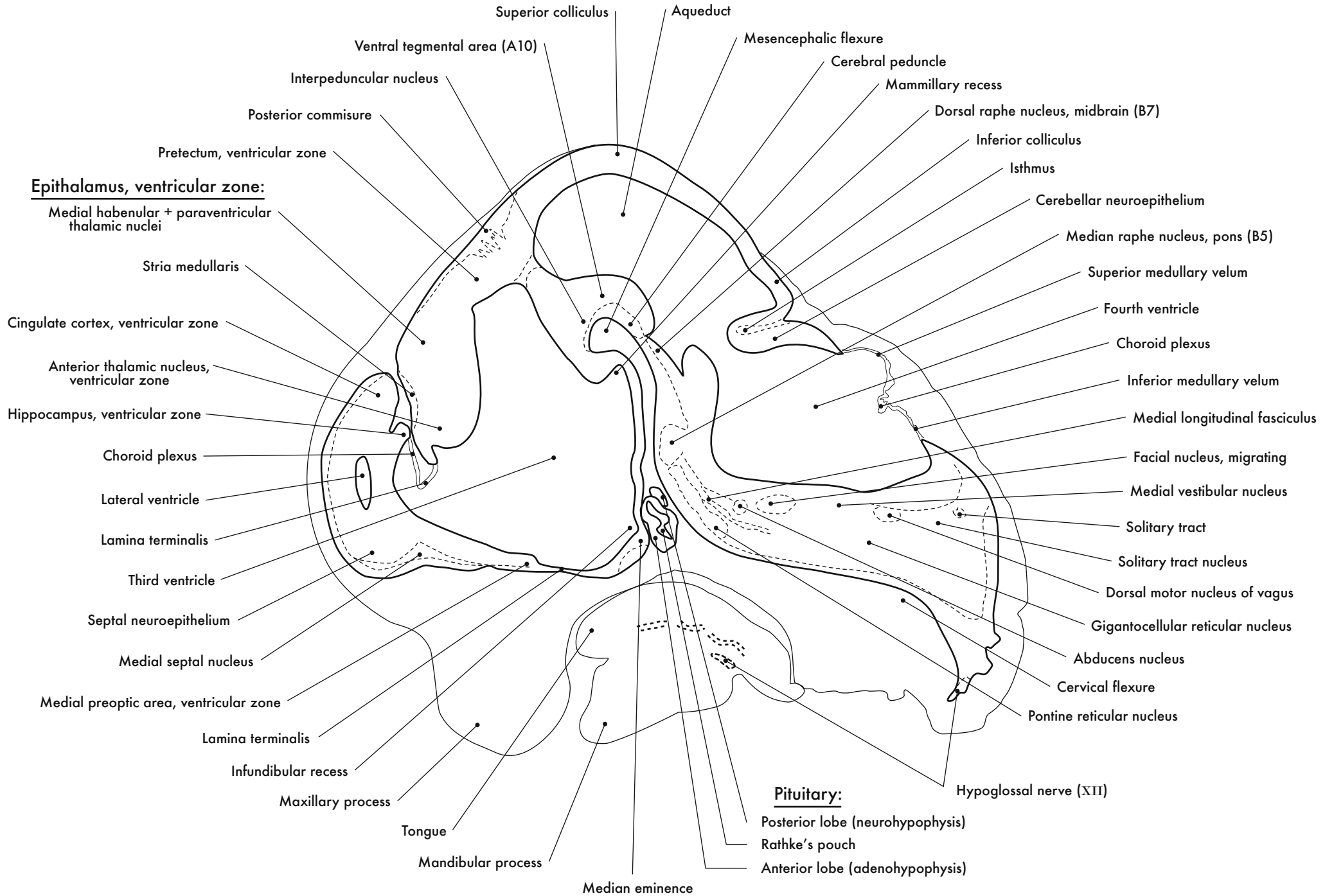


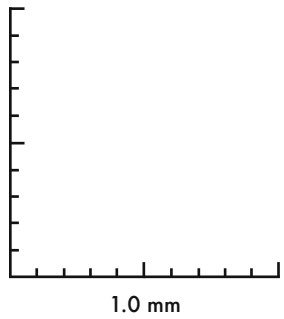
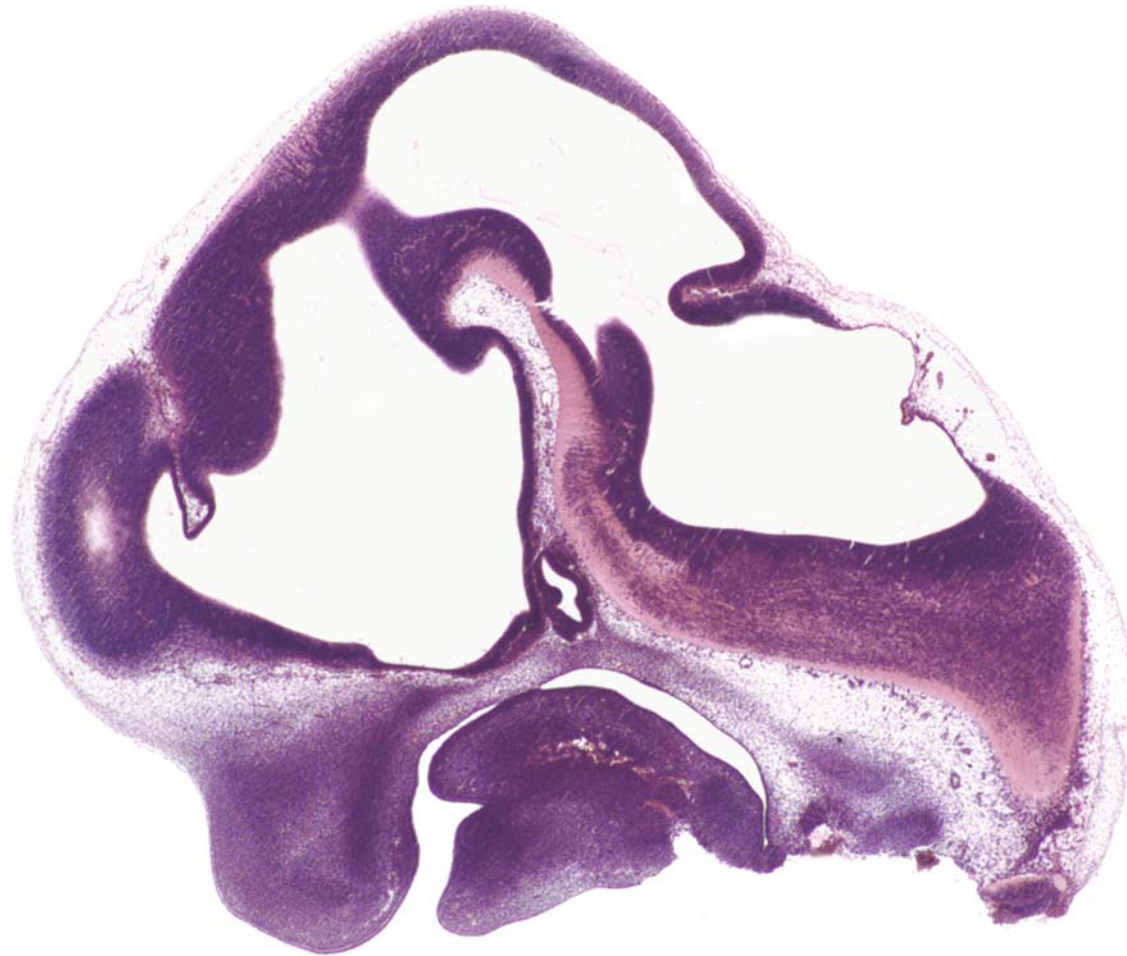
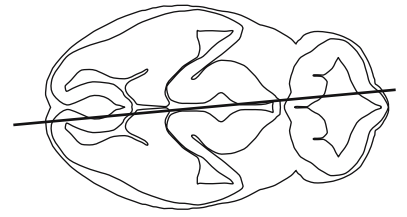


0.5 mm

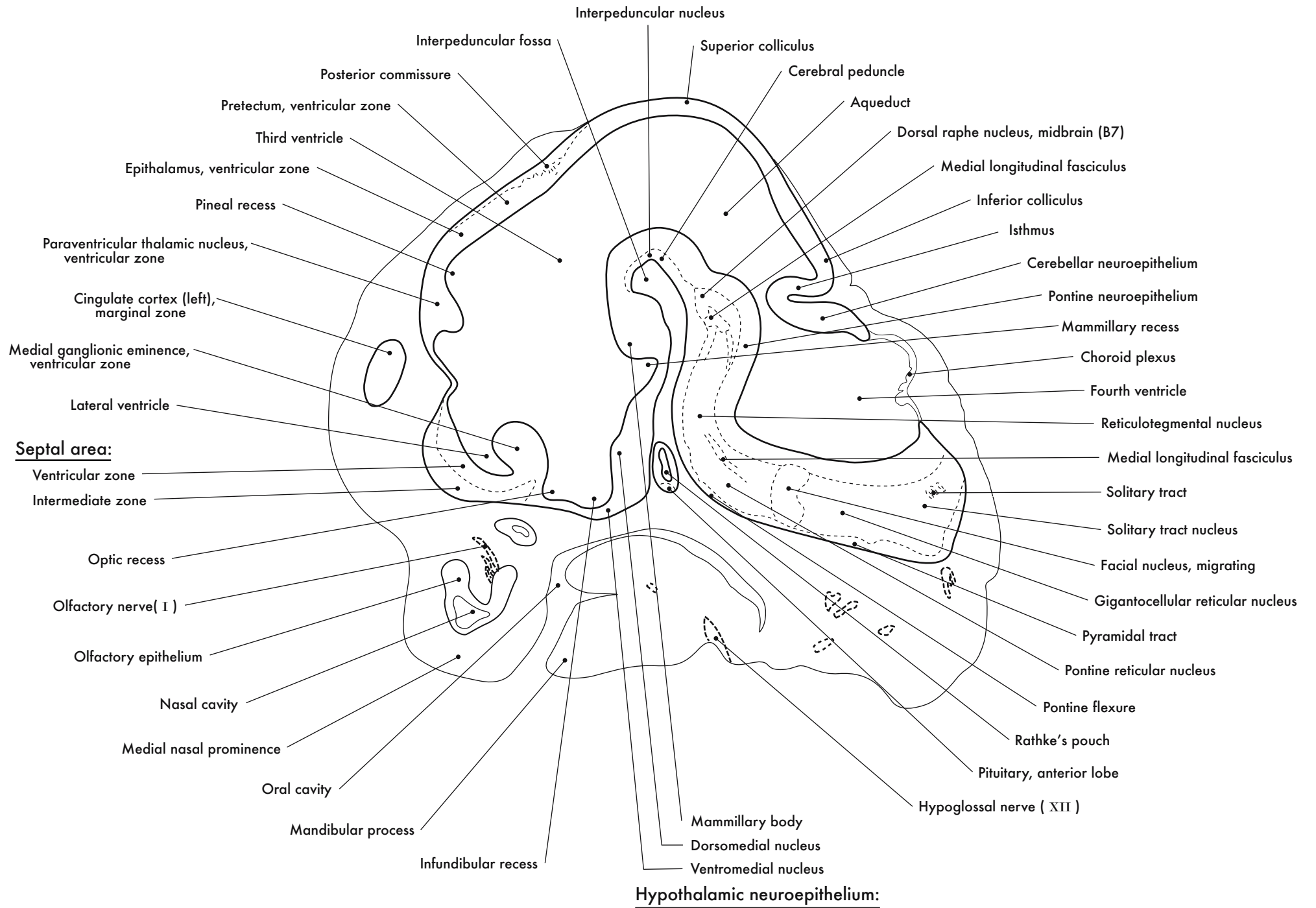
GD 12 SAGITTAL 10

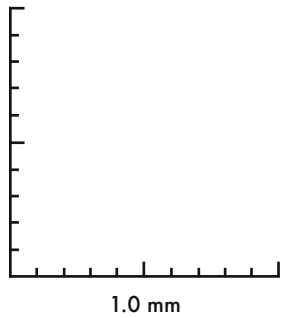
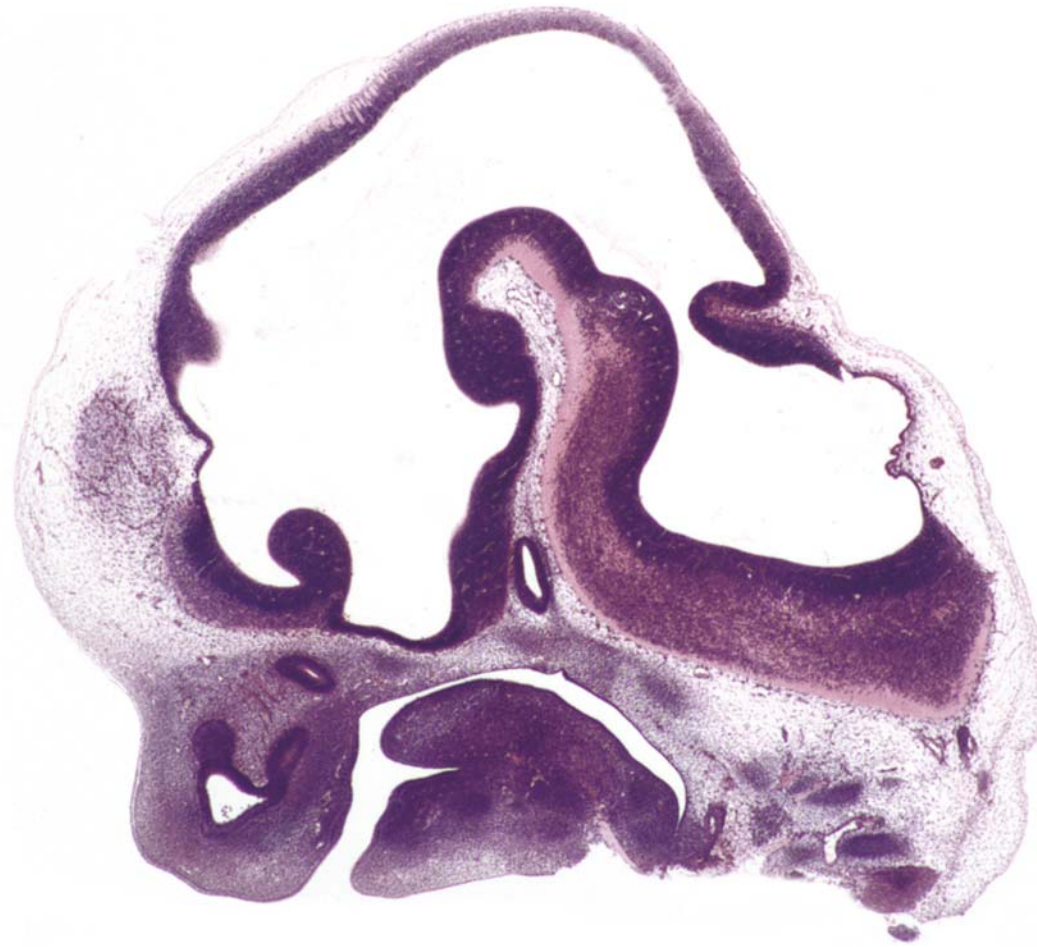
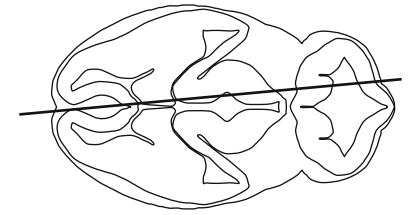




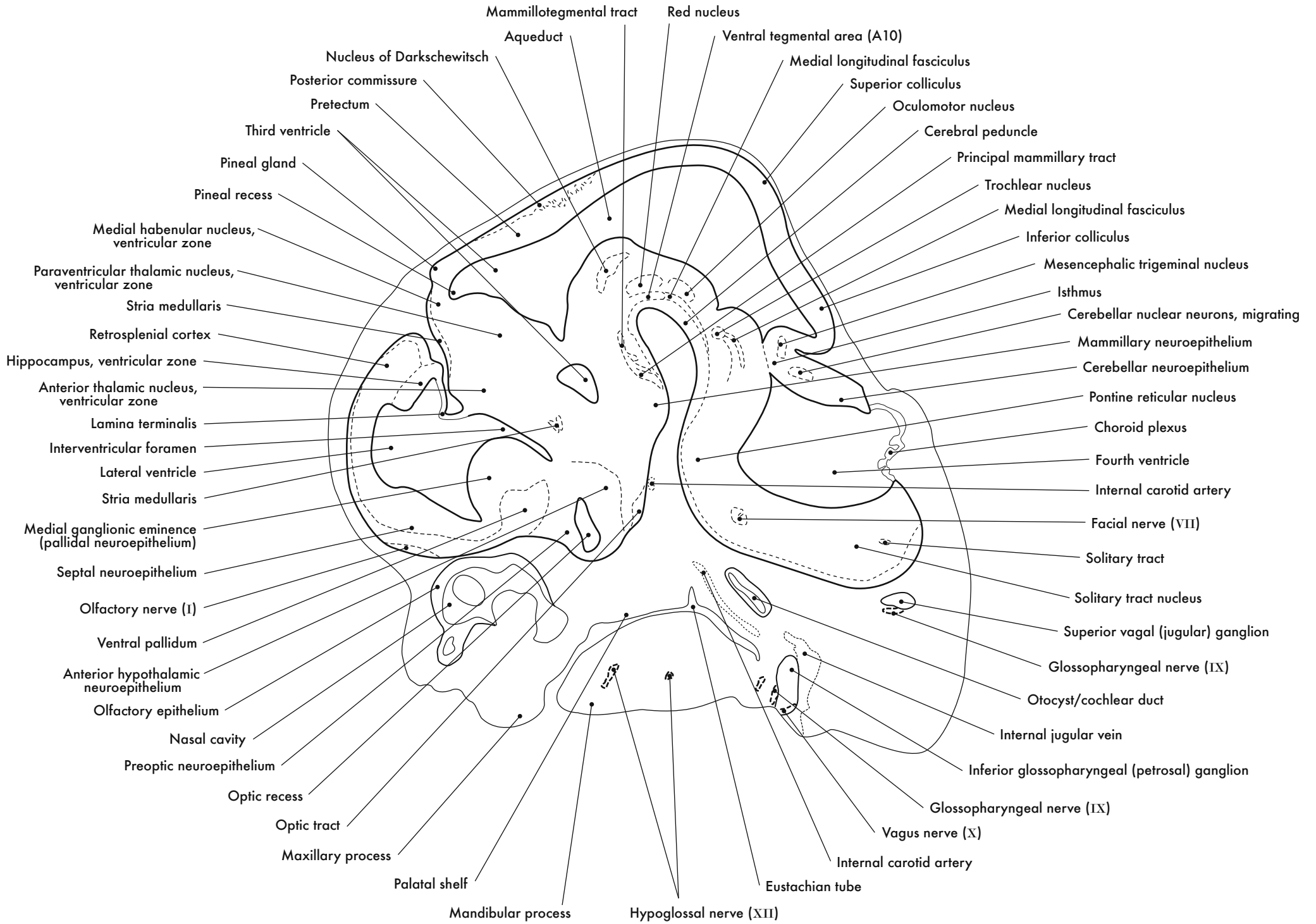


GD 12 SAGITTAL 11

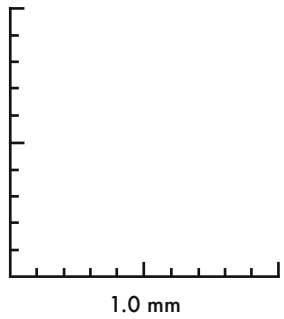
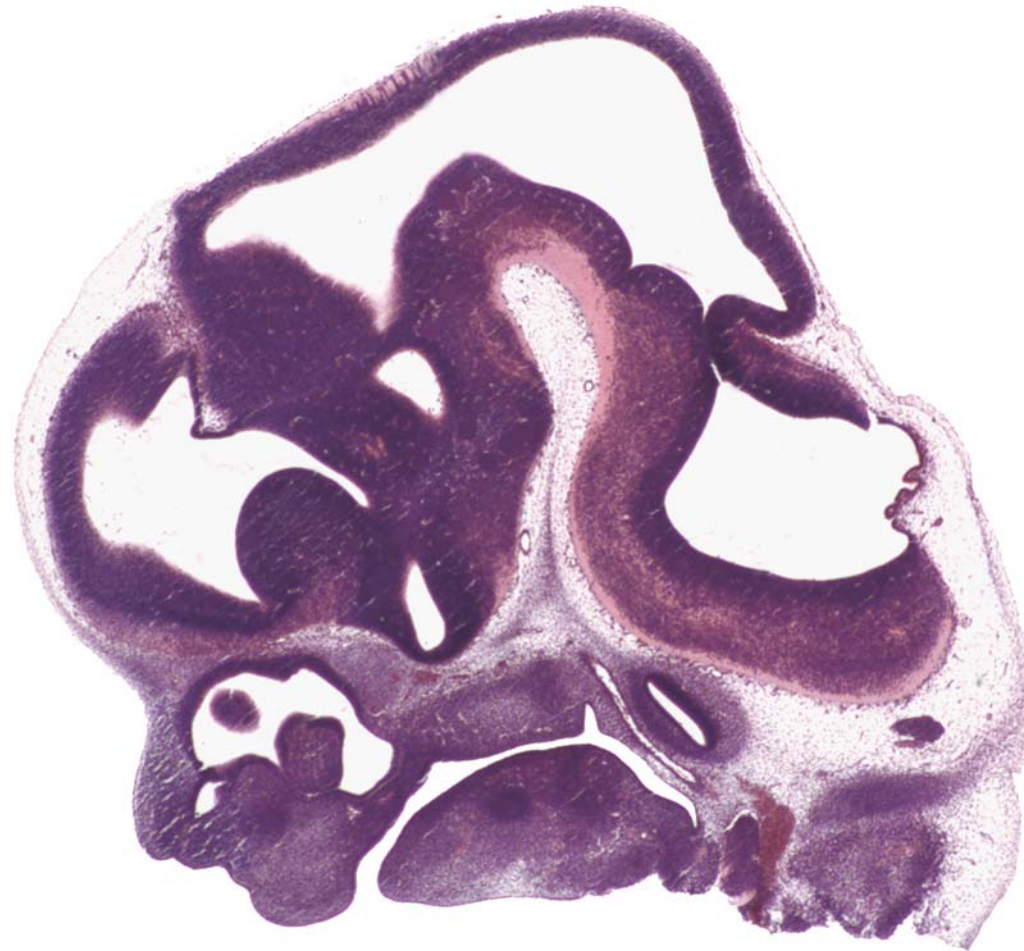
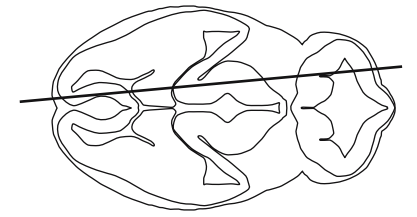




GD 12 SAGITTAL 12

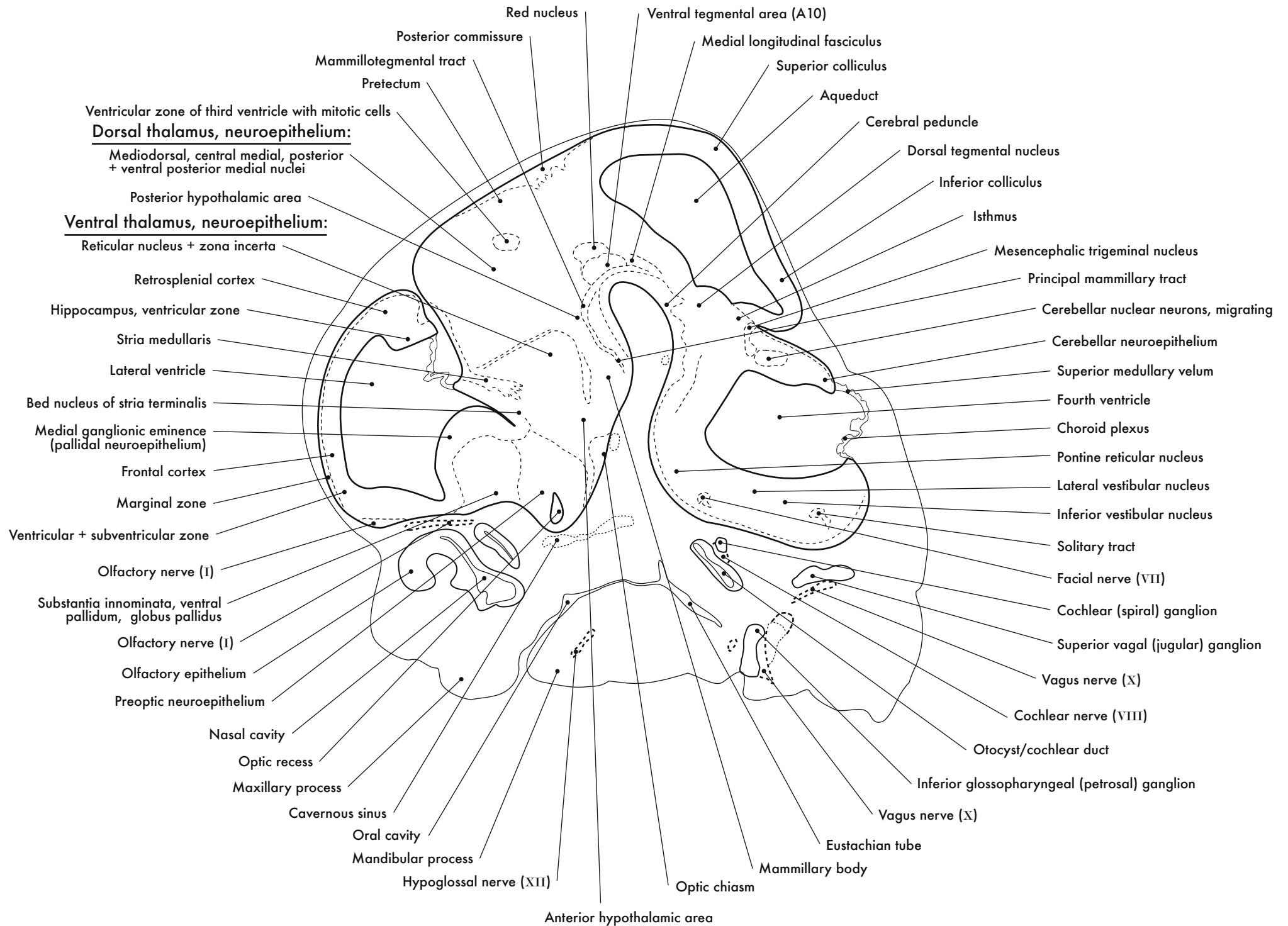


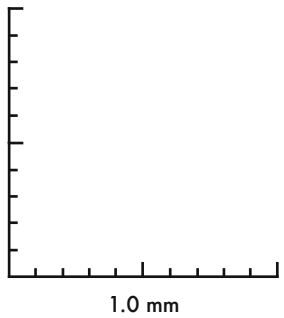
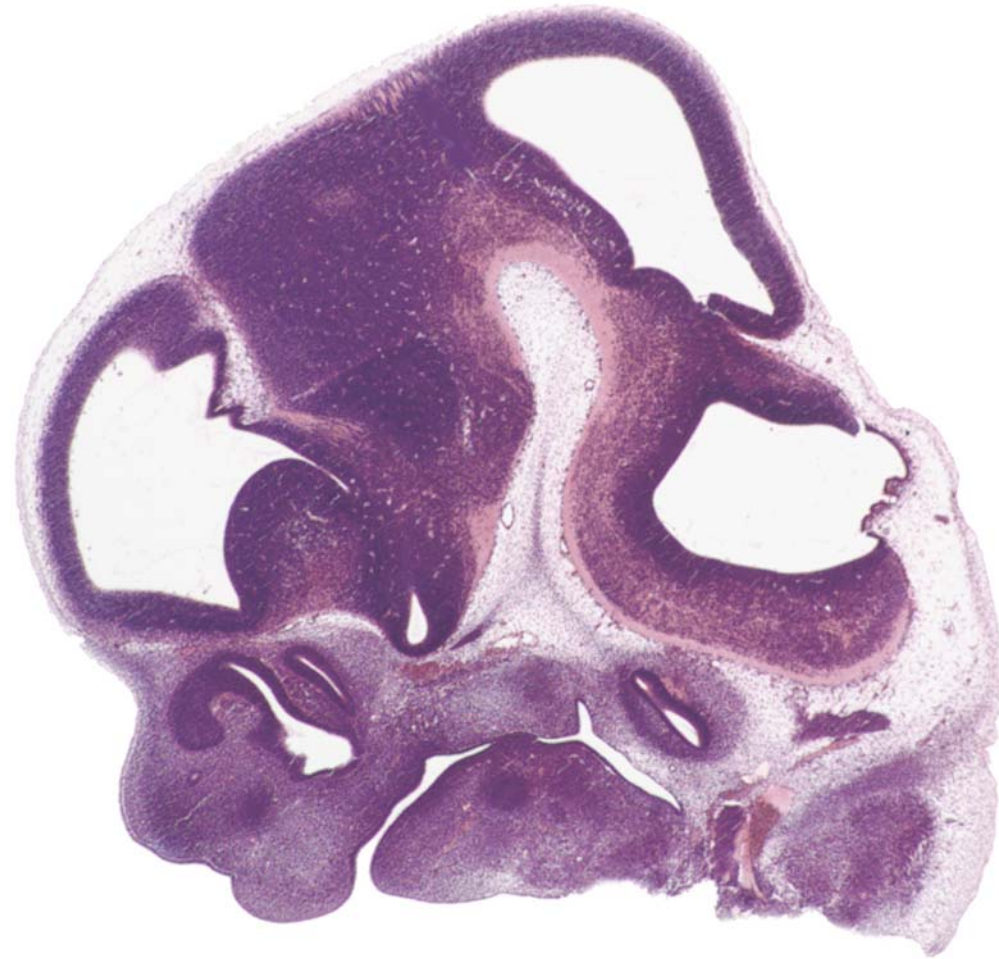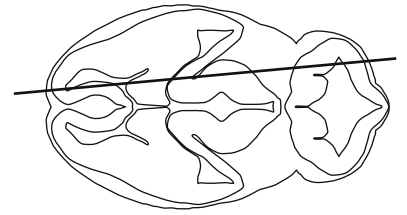




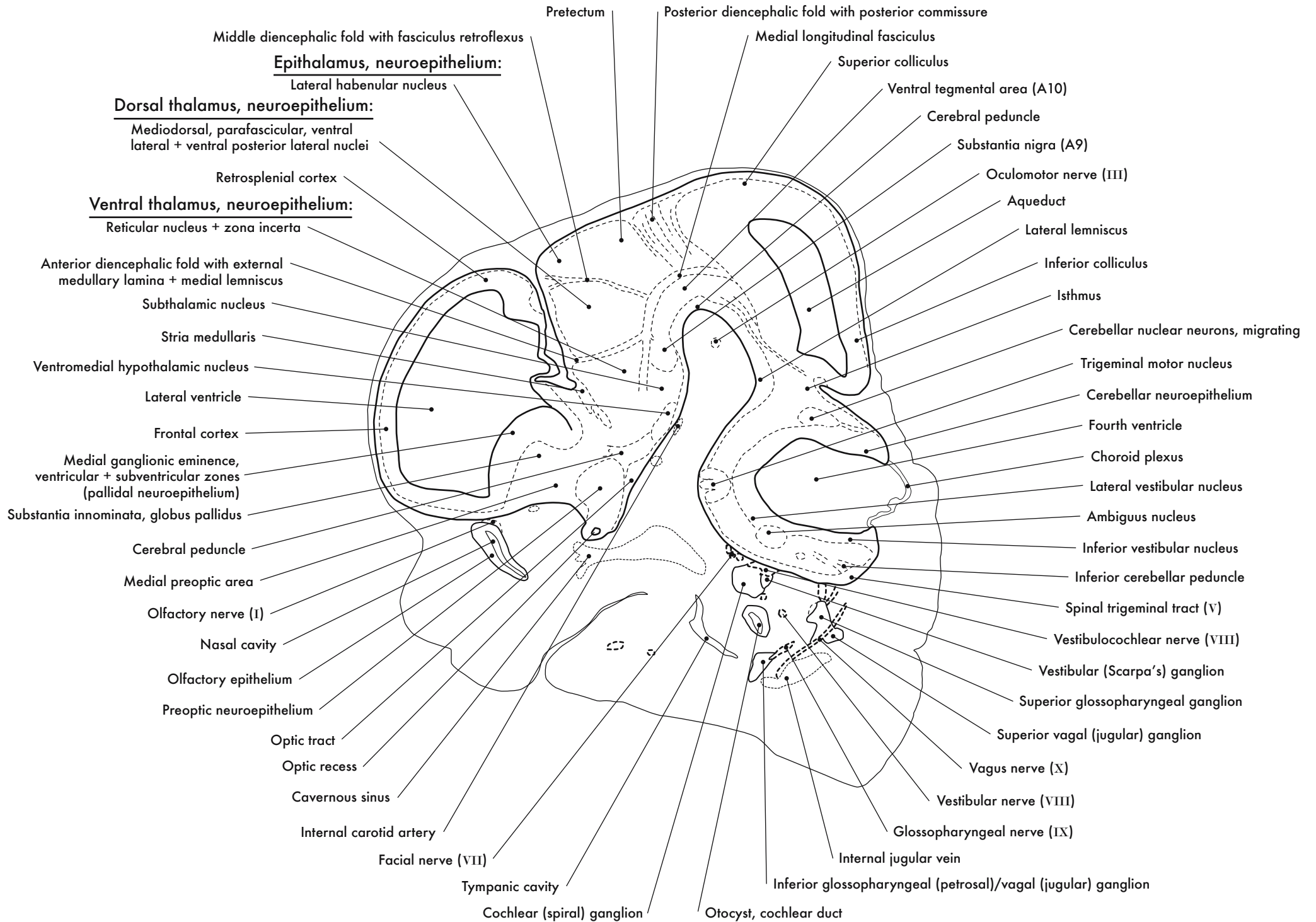
GD 12 SAGITTAL 13

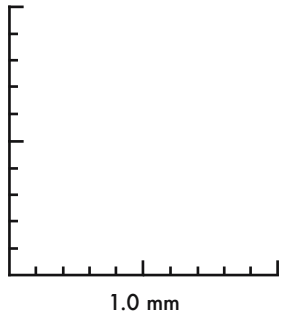
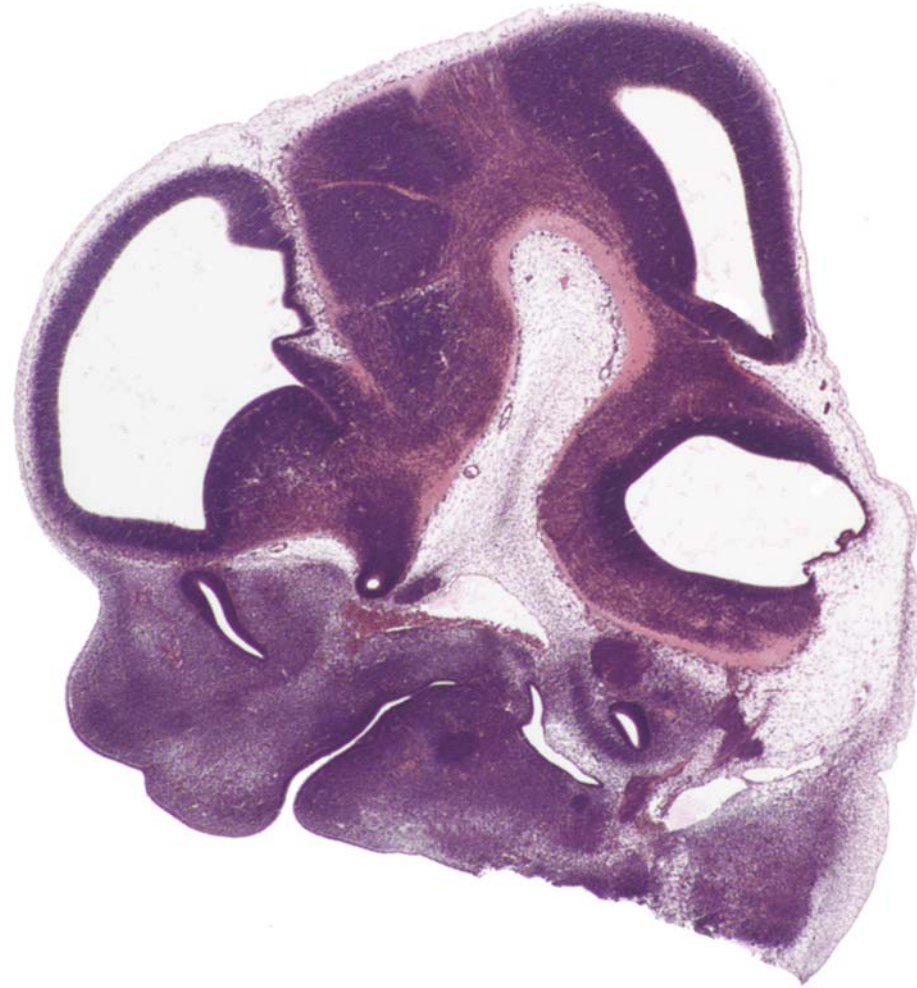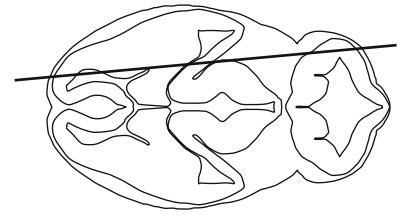




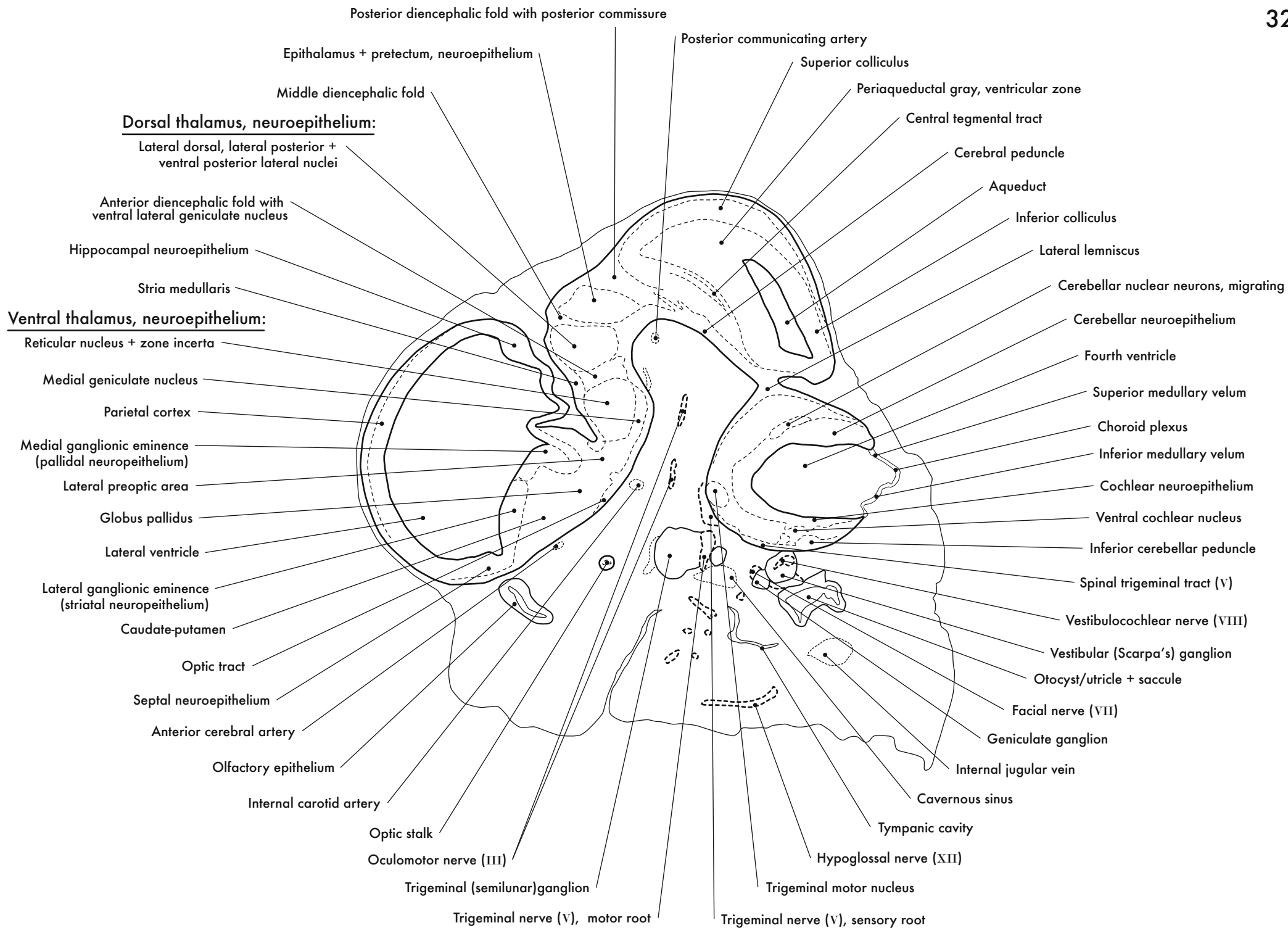


GD 12 SAGITTAL 14

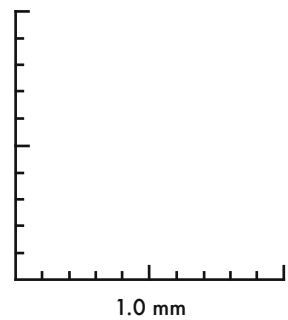
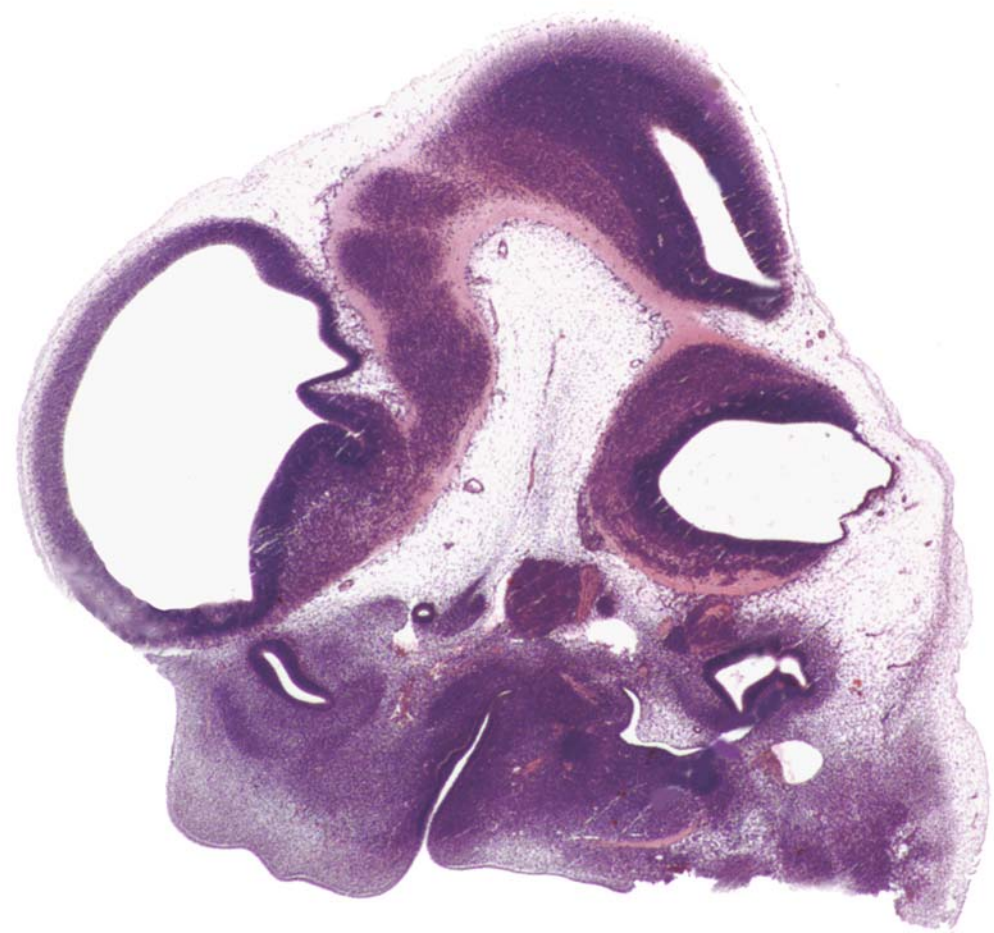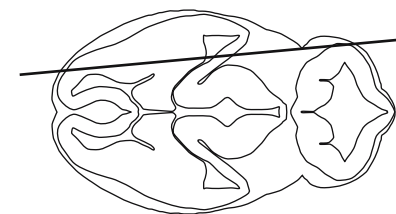




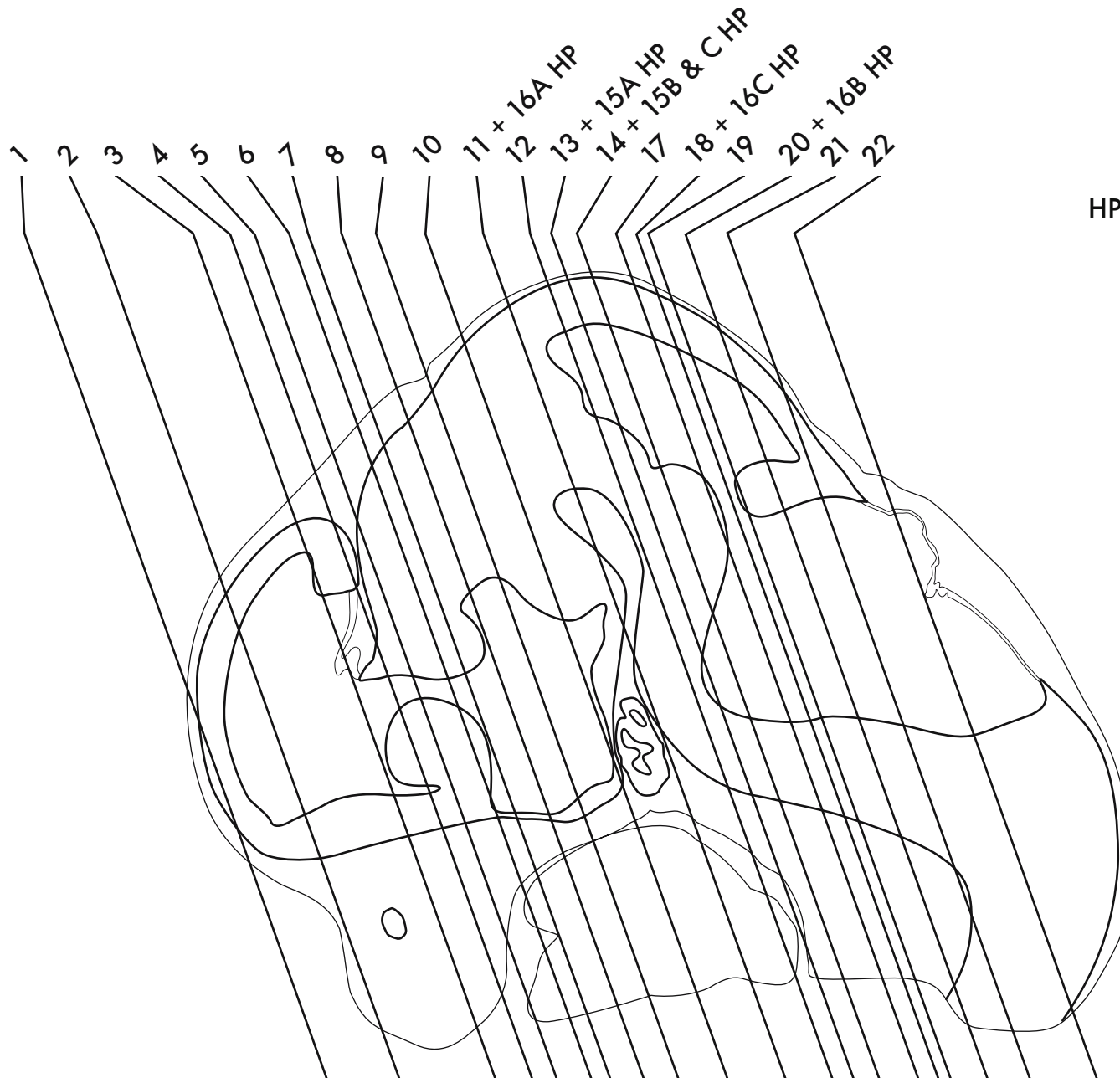
GD 12 SAGITTAL 15





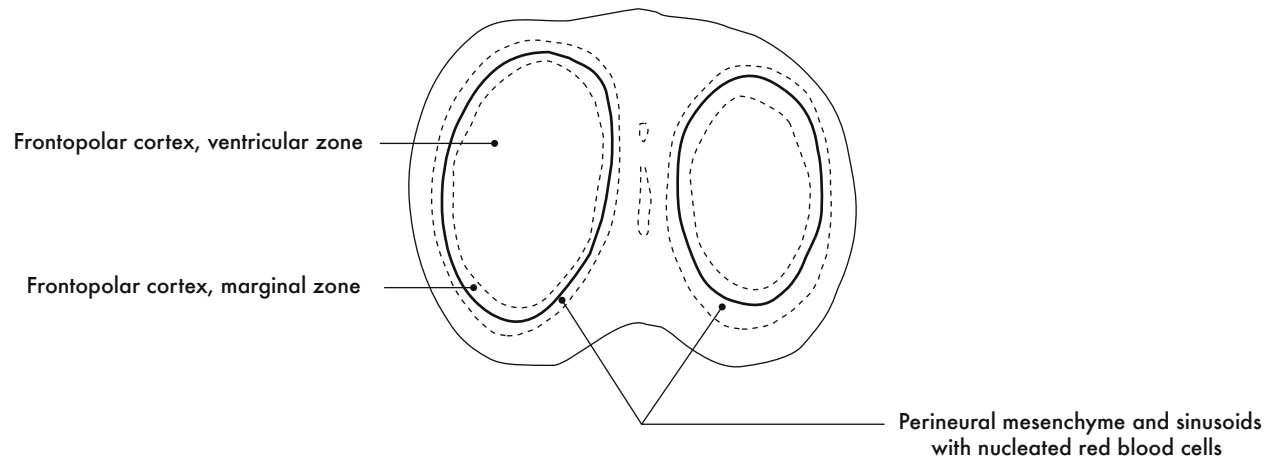


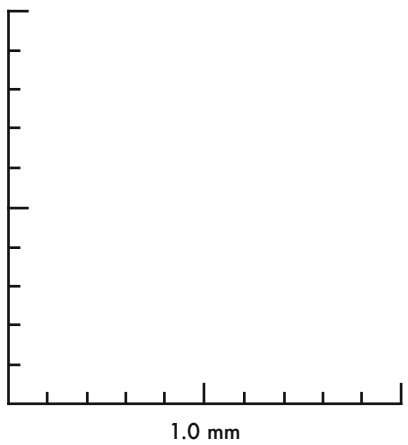
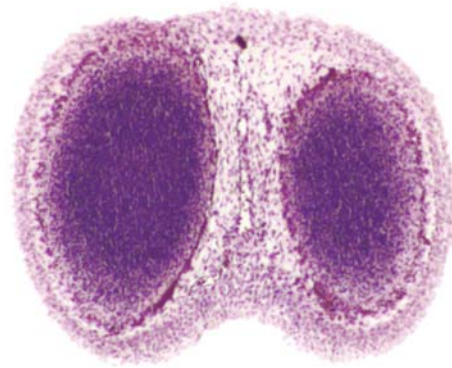
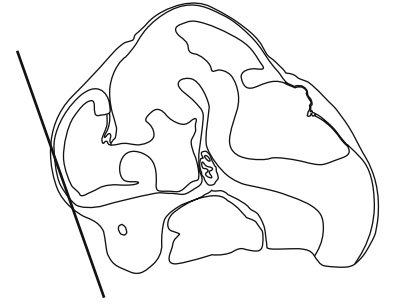GD 12 SAGITTAL 16



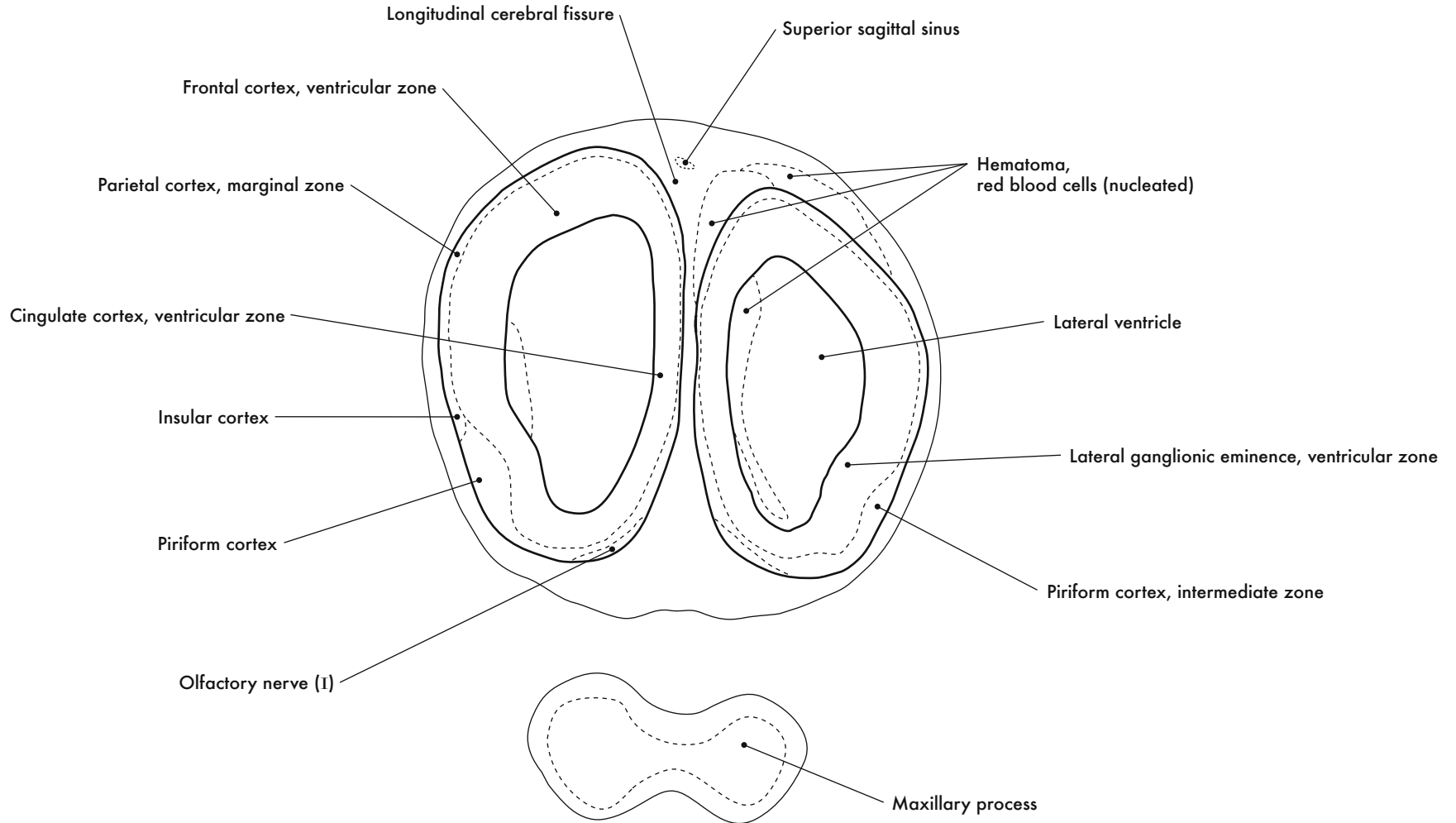
HP denotes image enlargement

**GESTATIONAL DAY 12 (GD 12)  
CORONAL SECTIONS**

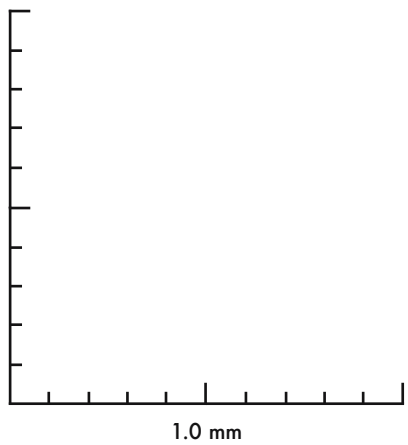
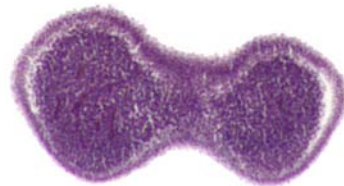
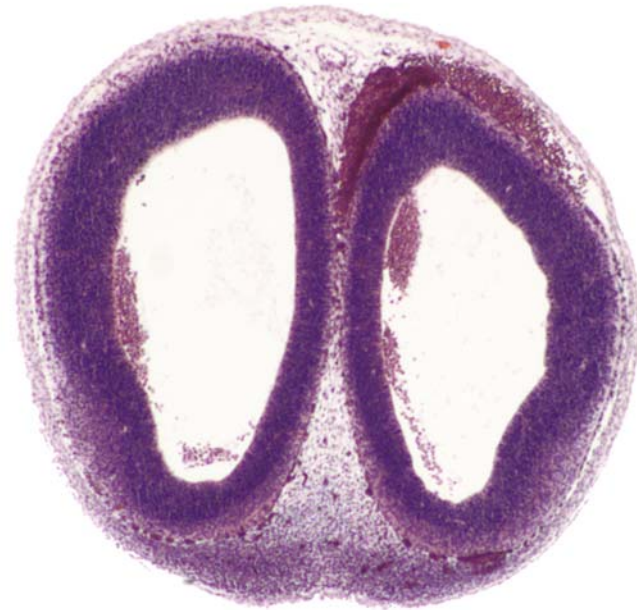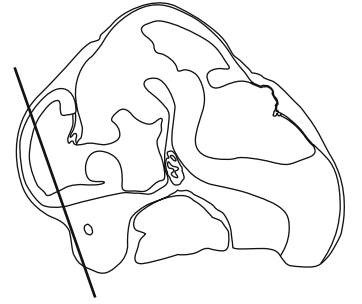




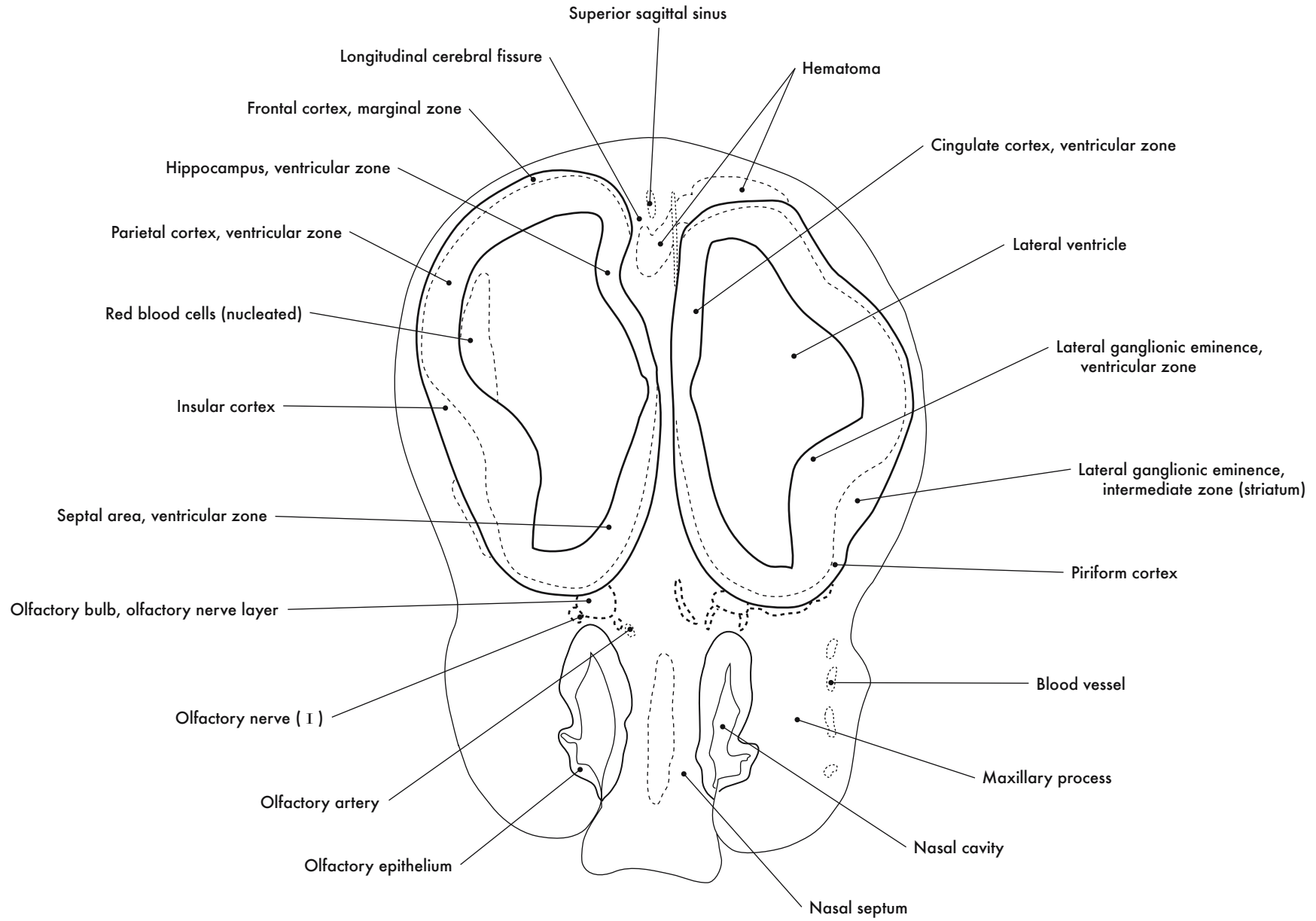
GD 12 CORONAL 1

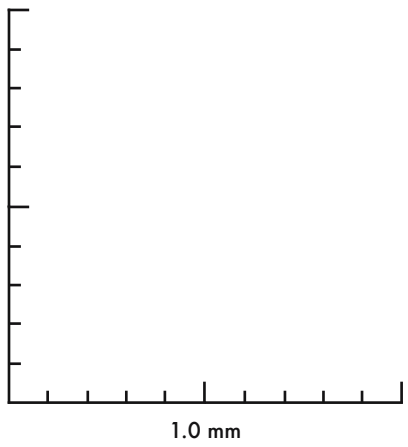
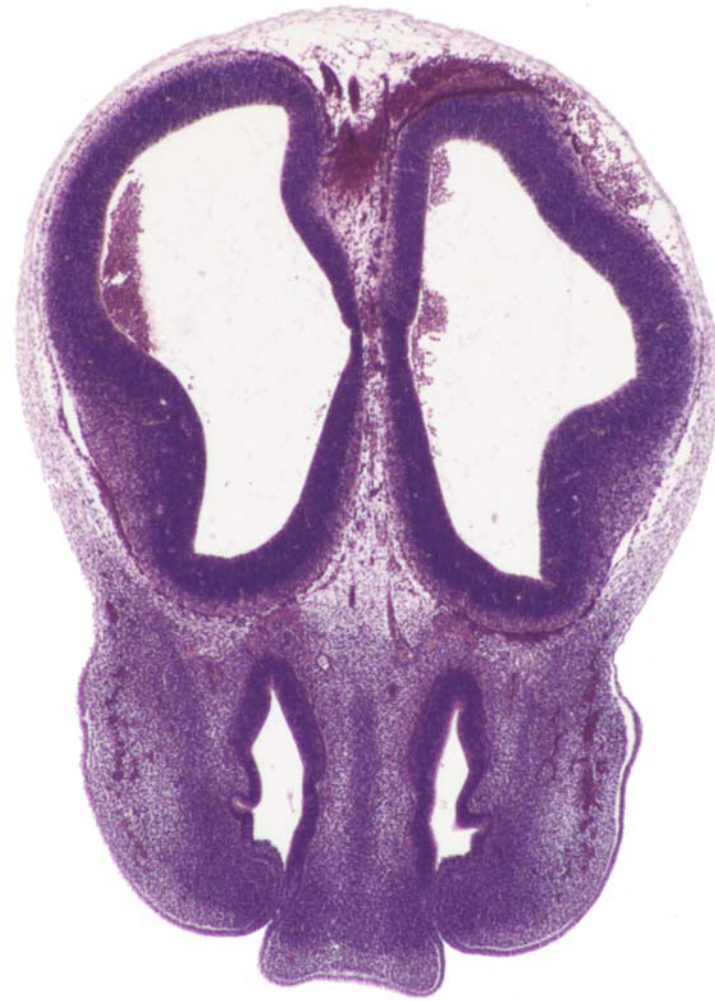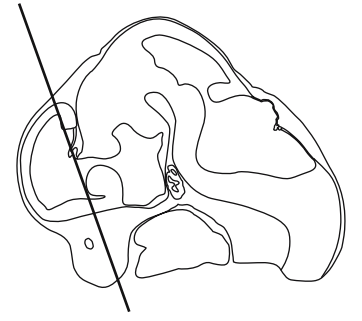




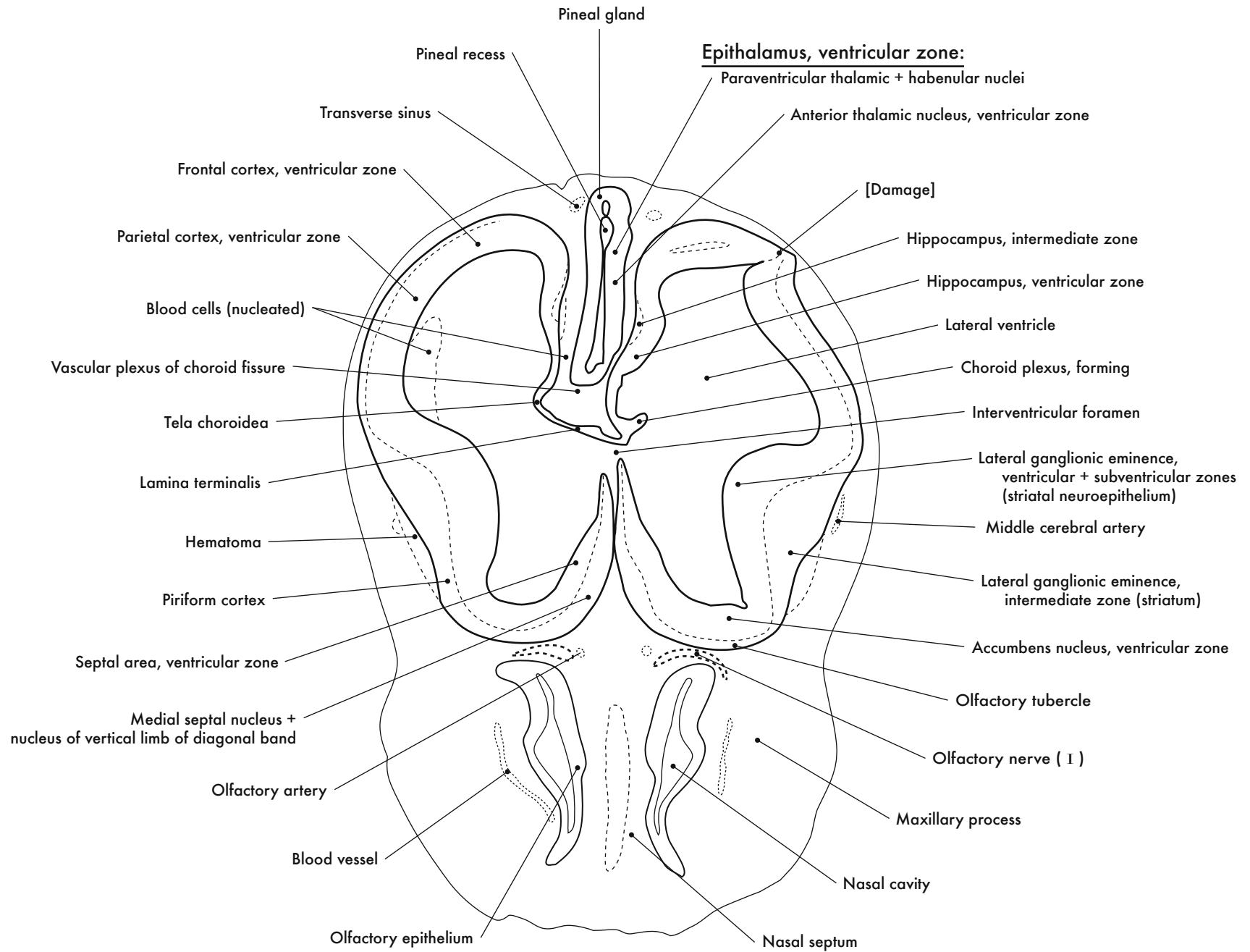


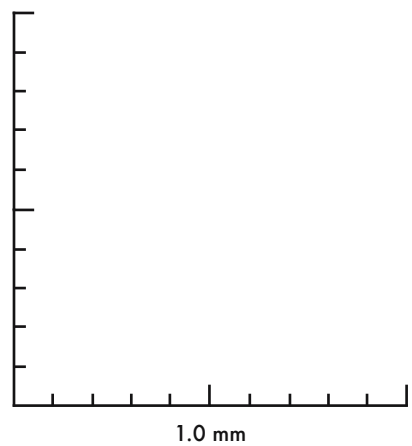
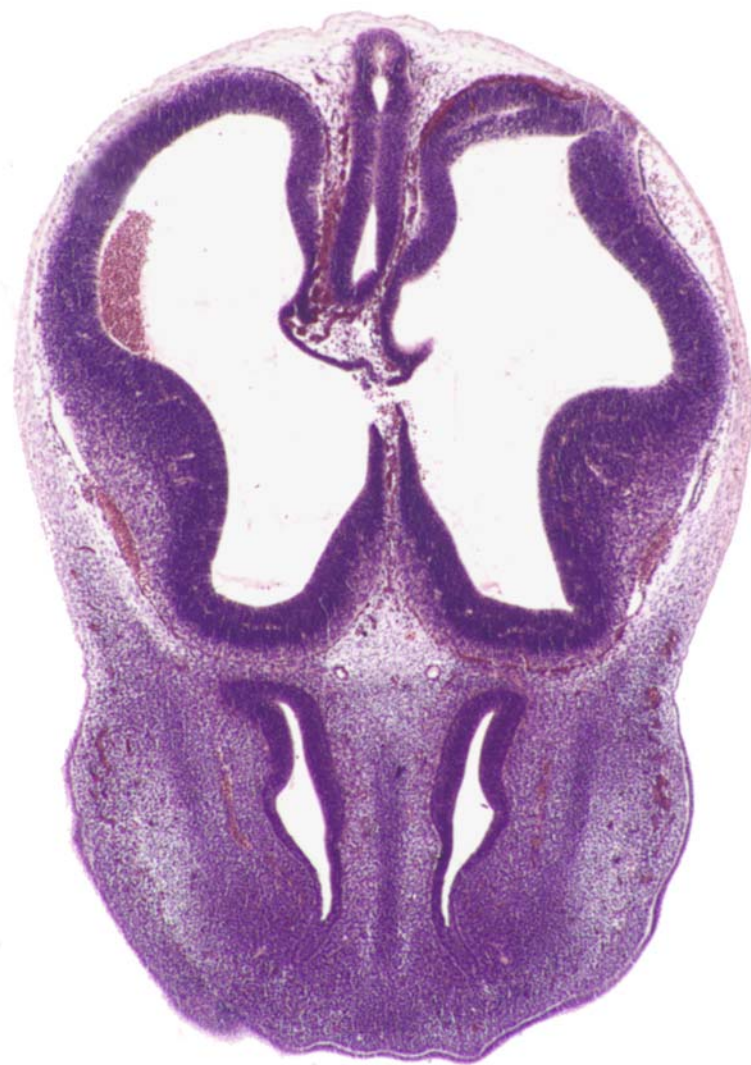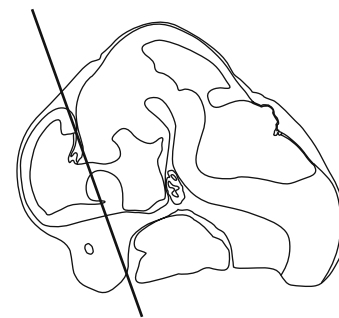
GD 12 CORONAL 2





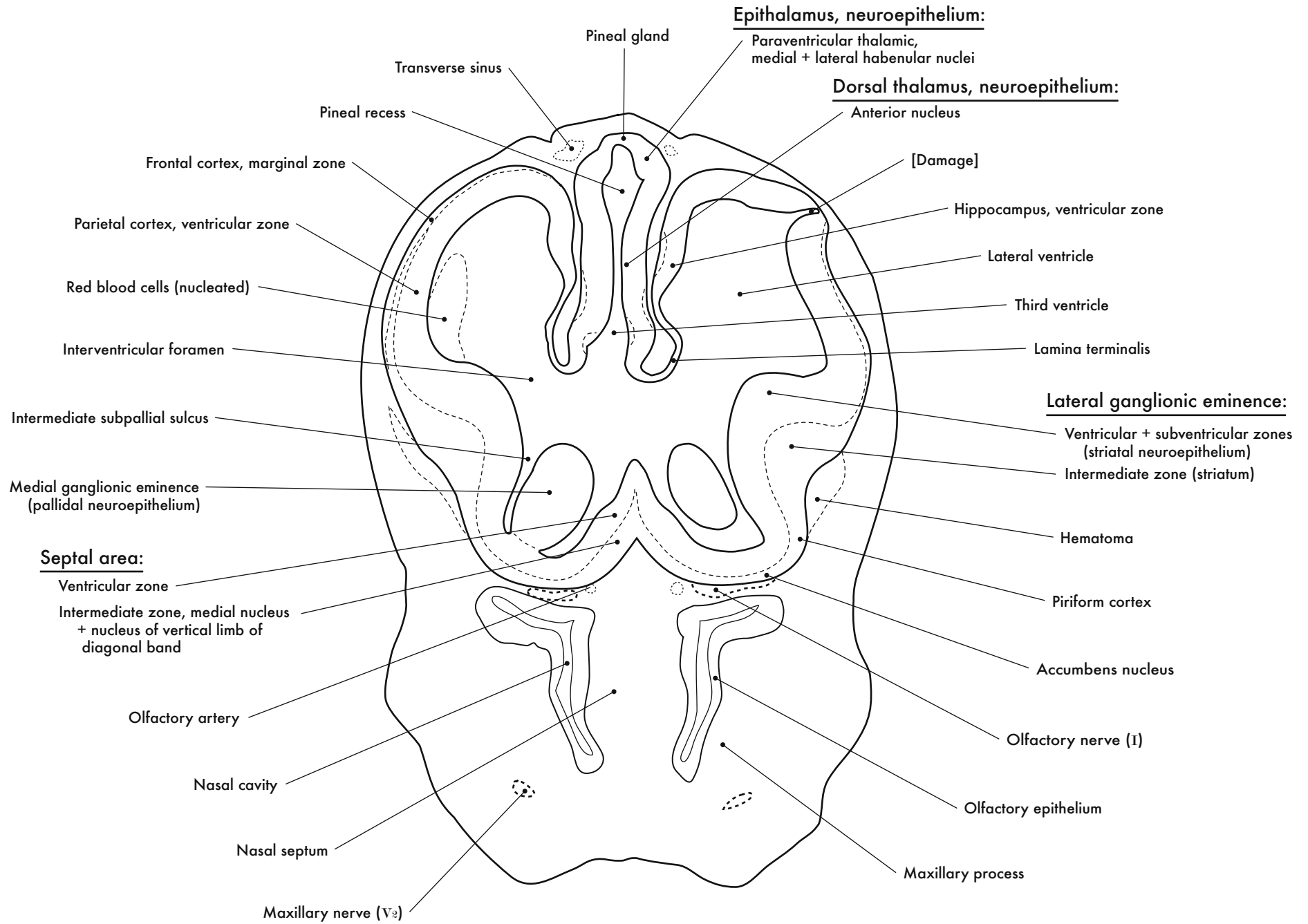
GD 12 CORONAL 3

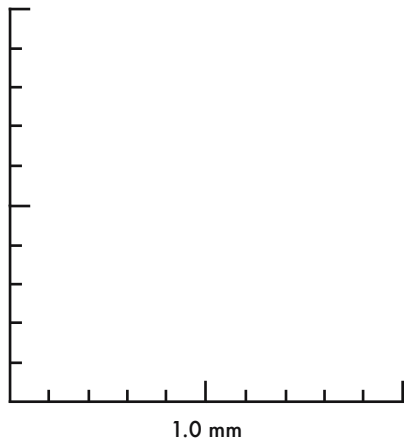
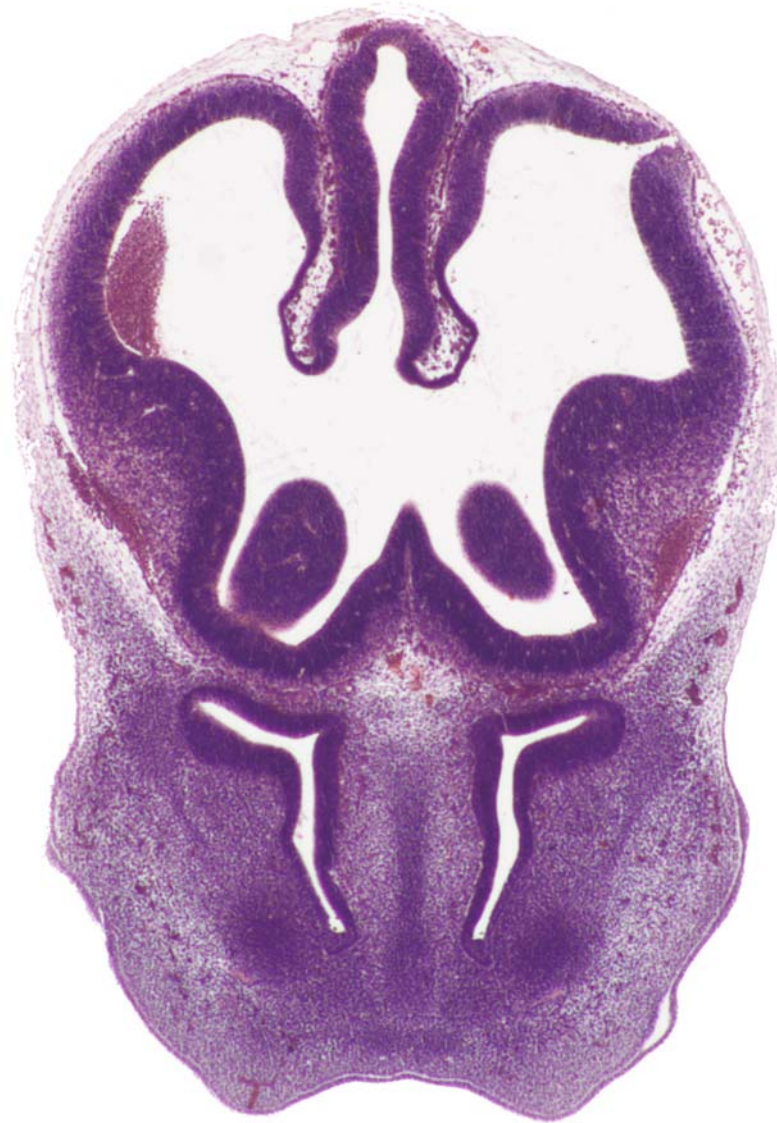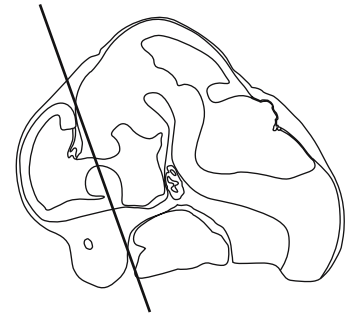




GD 12 CORONAL 4



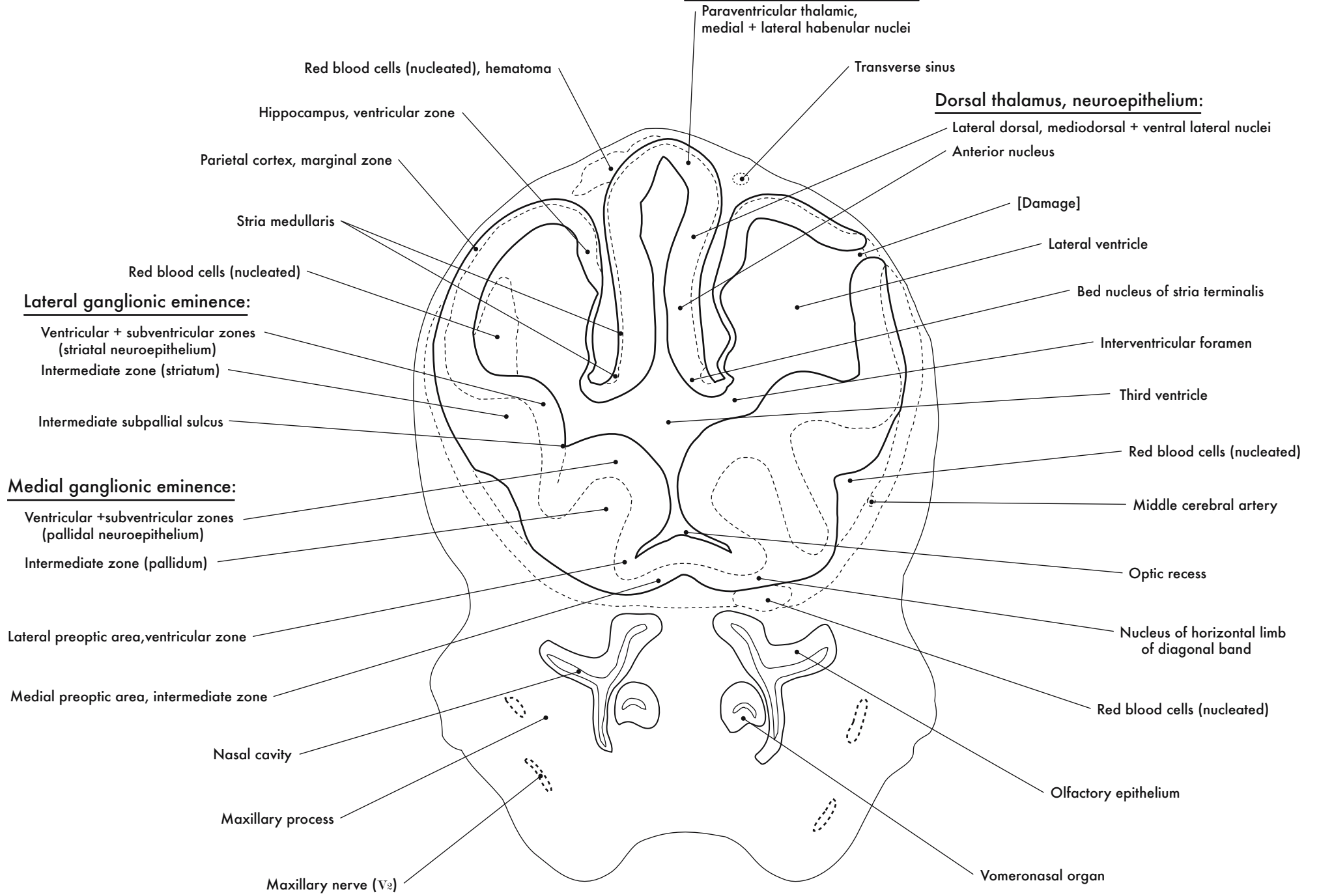


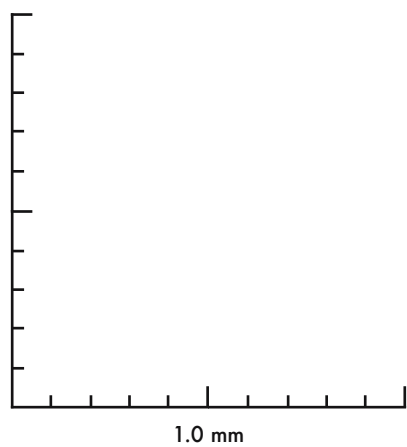
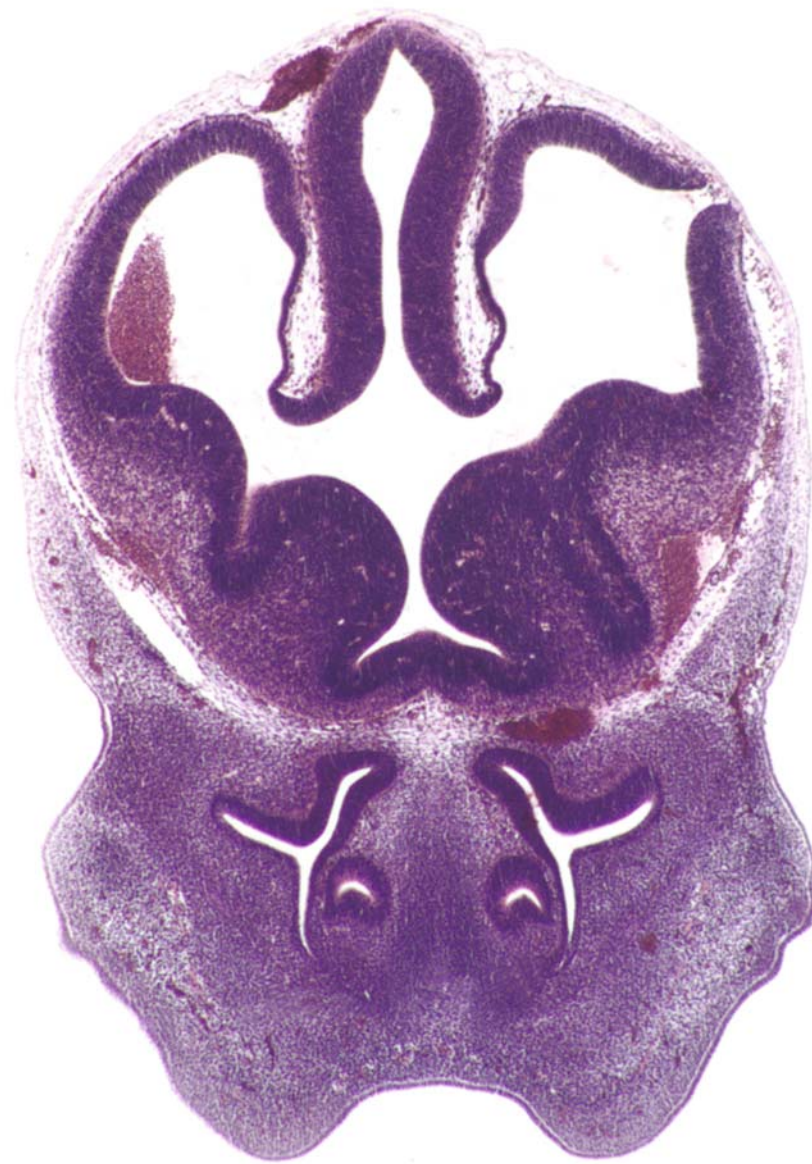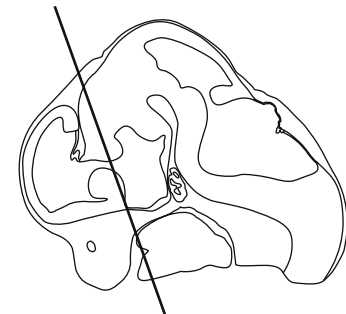


GD 12 CORONAL 5

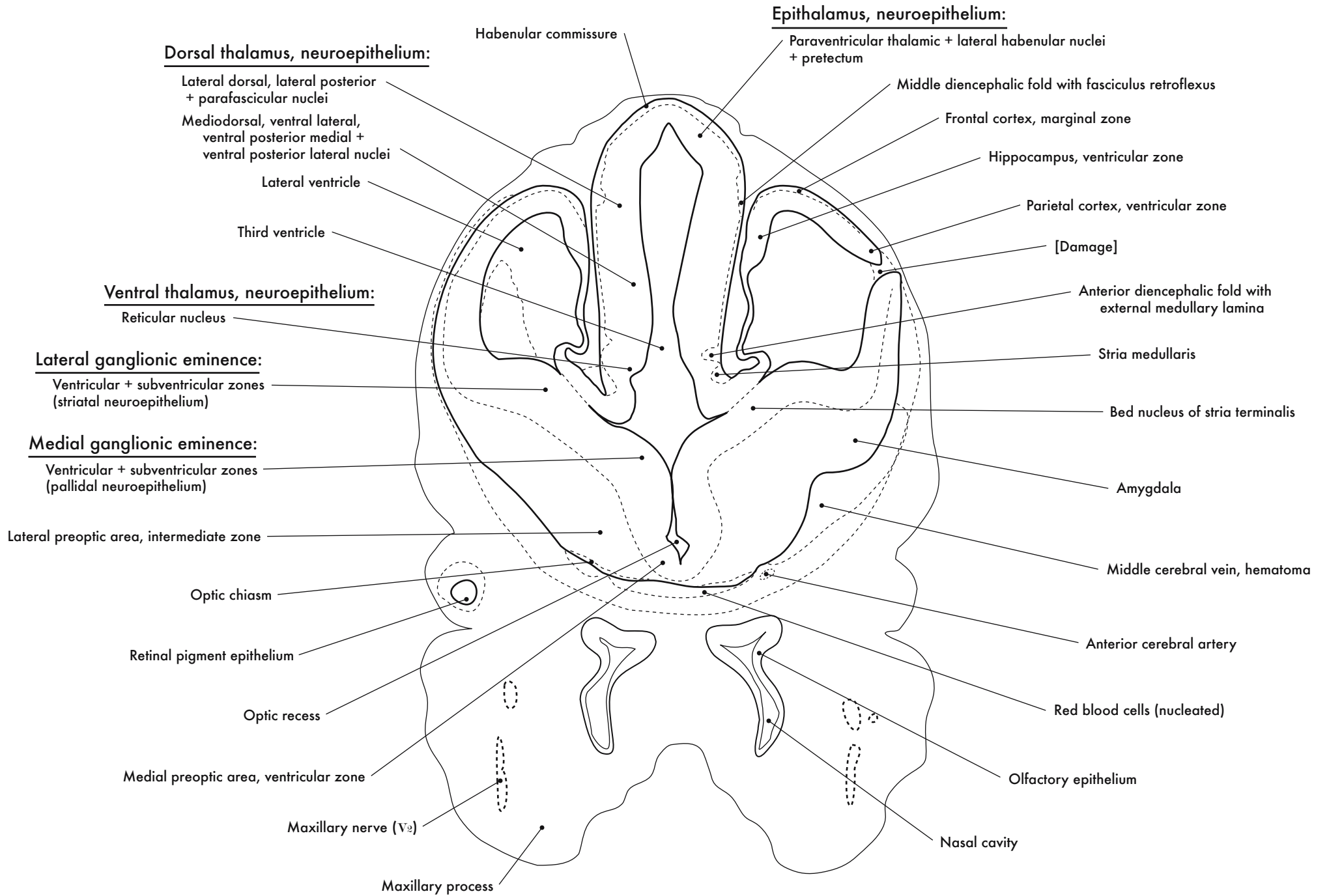
Epithalamus, neuroepithelium:

Dorsal thalamus, neuroepithelium:

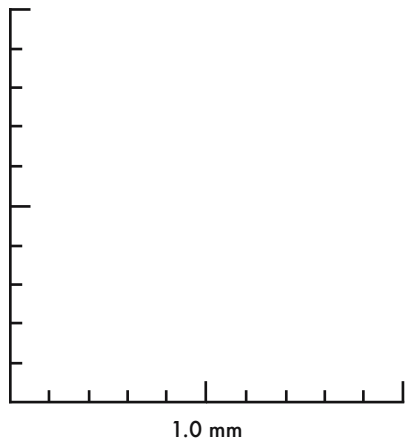
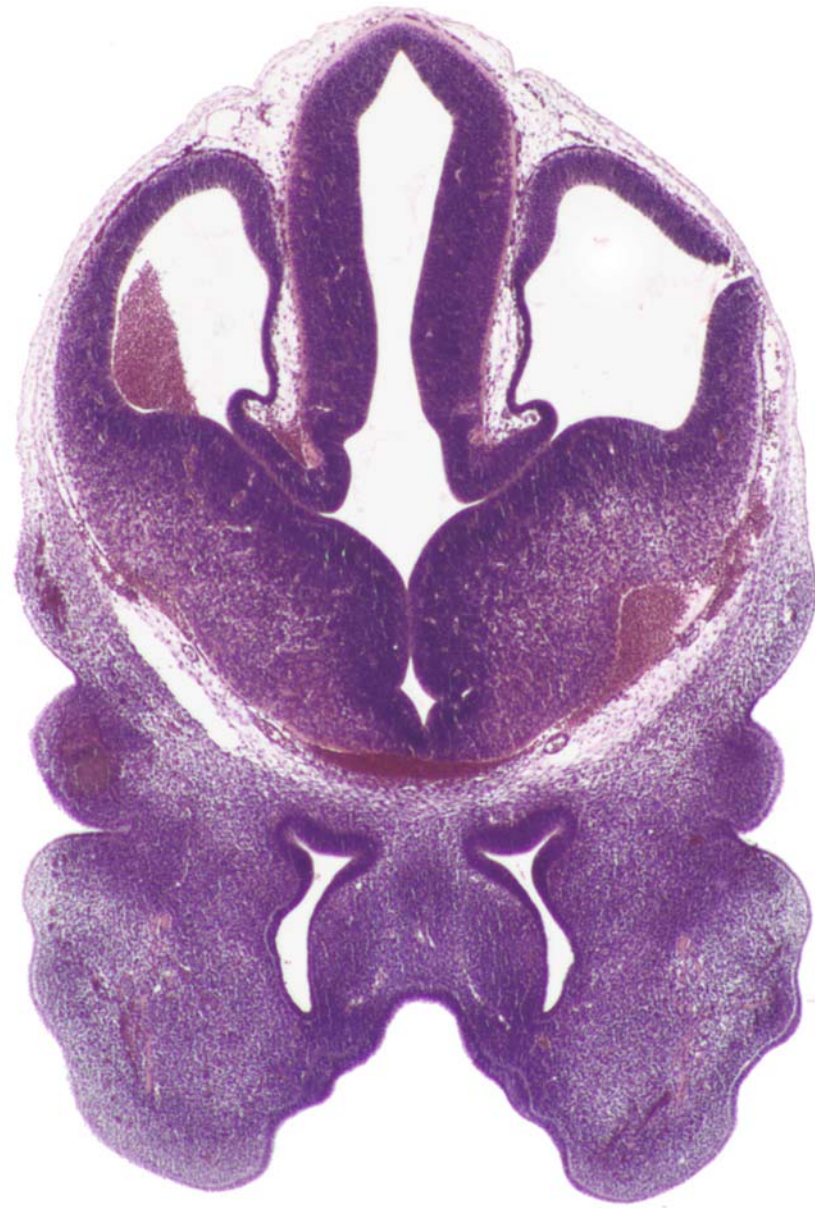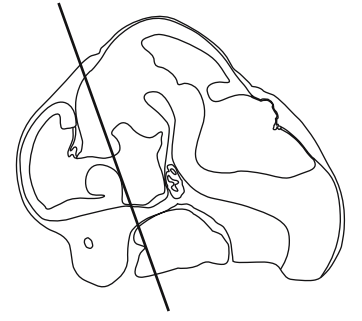




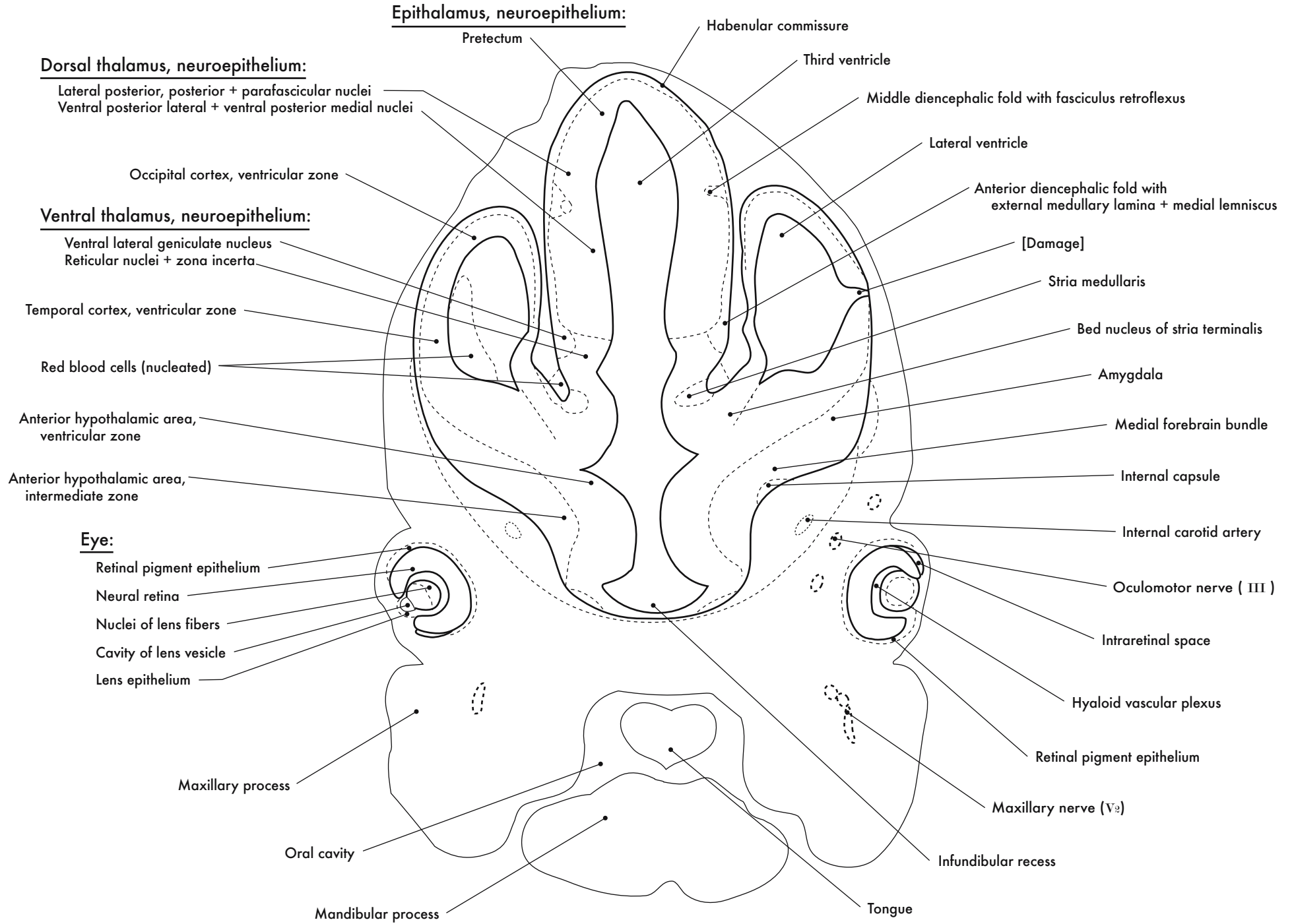
GD 12 CORONAL 6

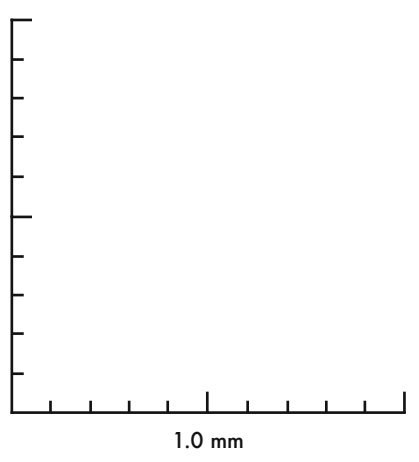
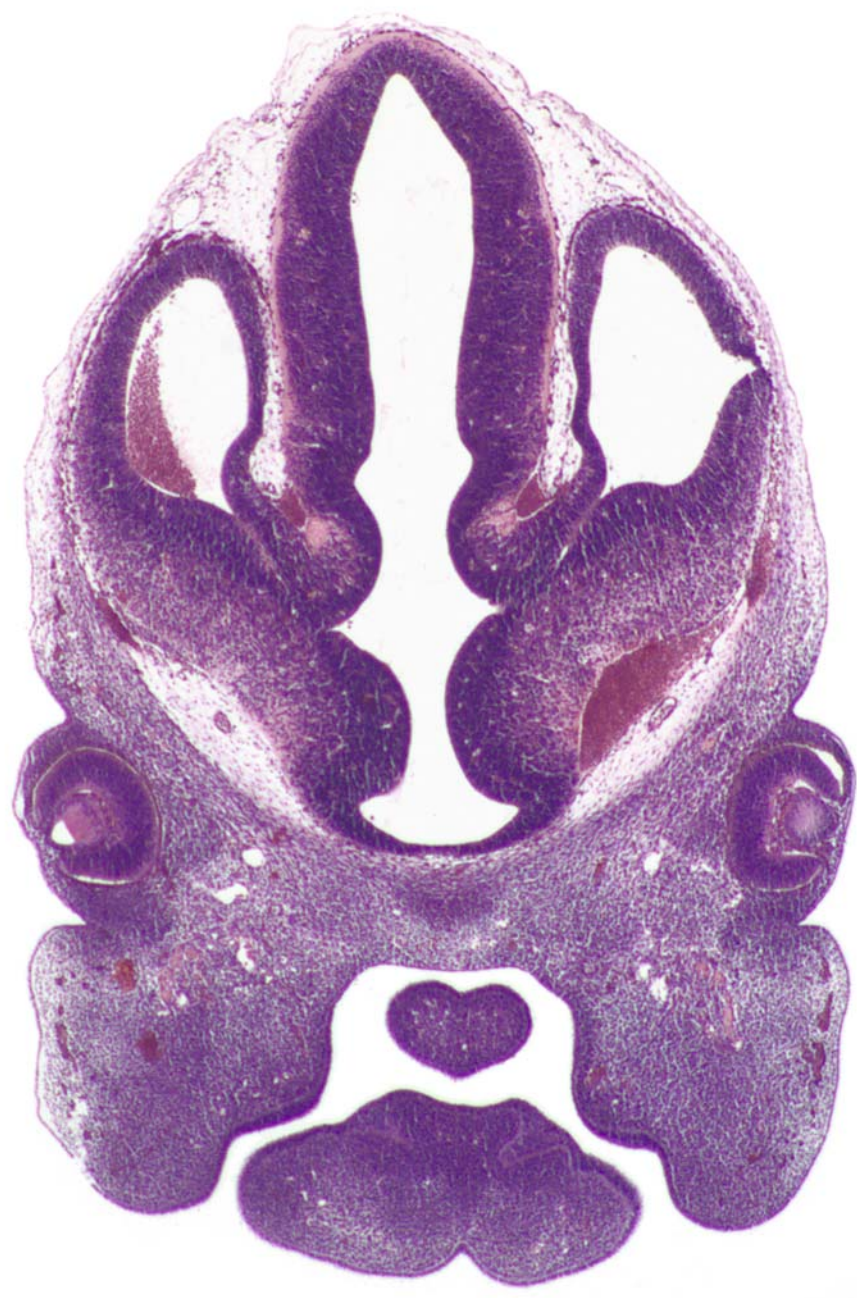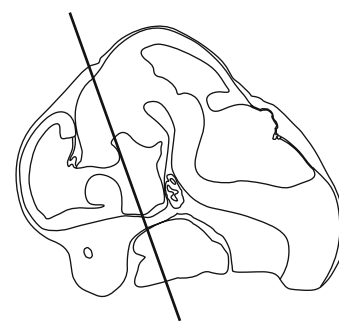




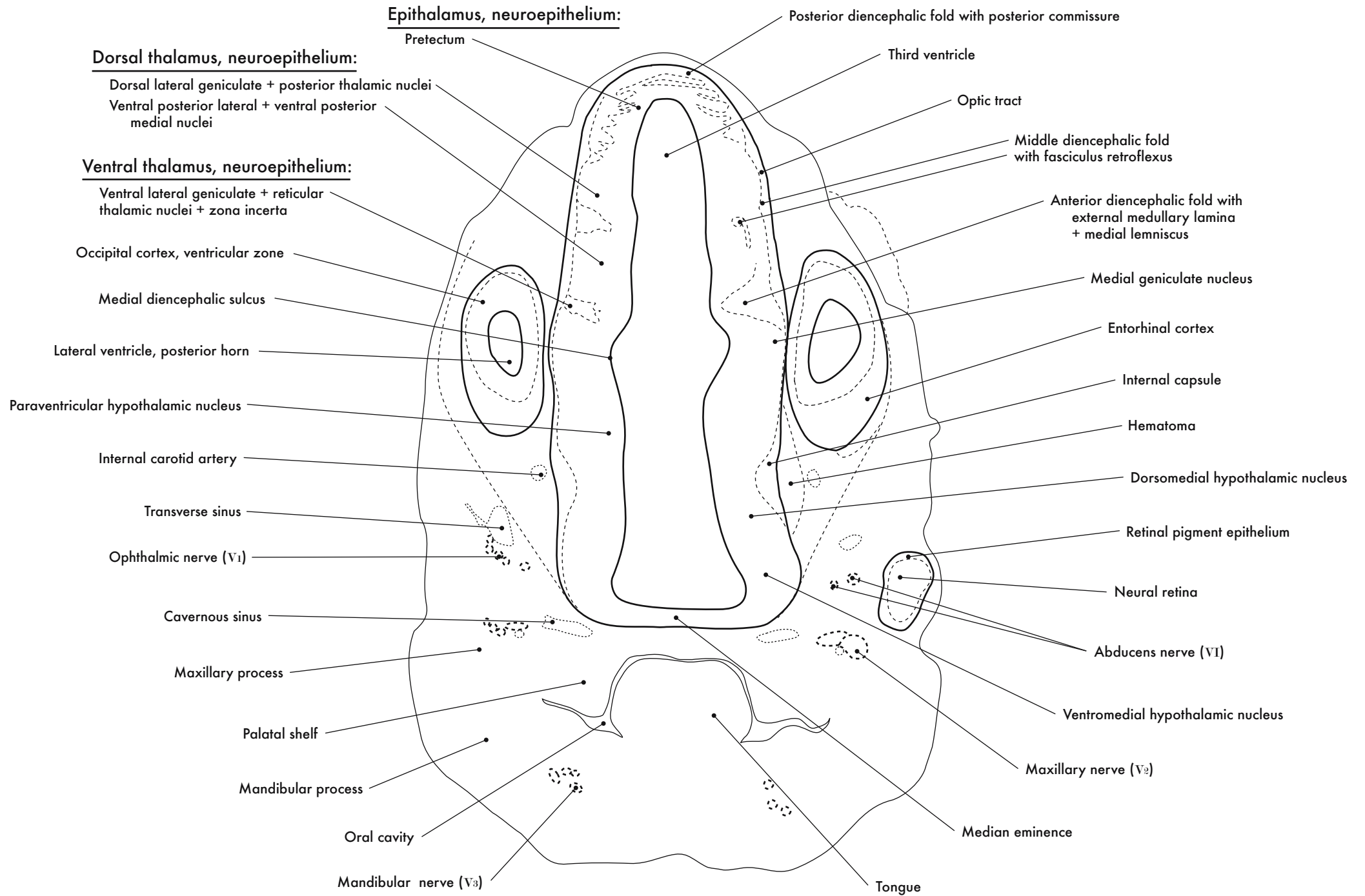


GD 12 CORONAL 7

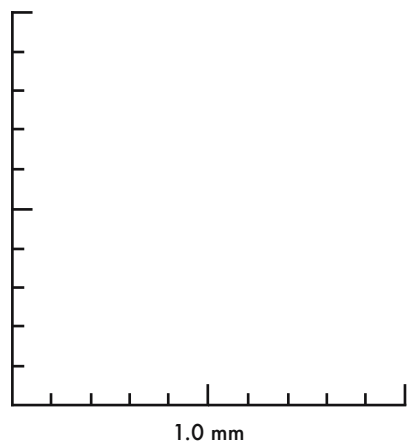
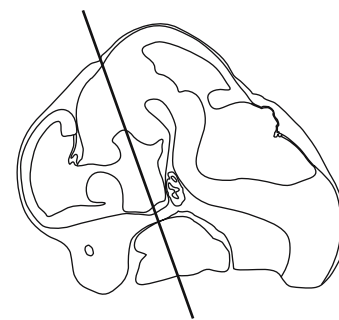
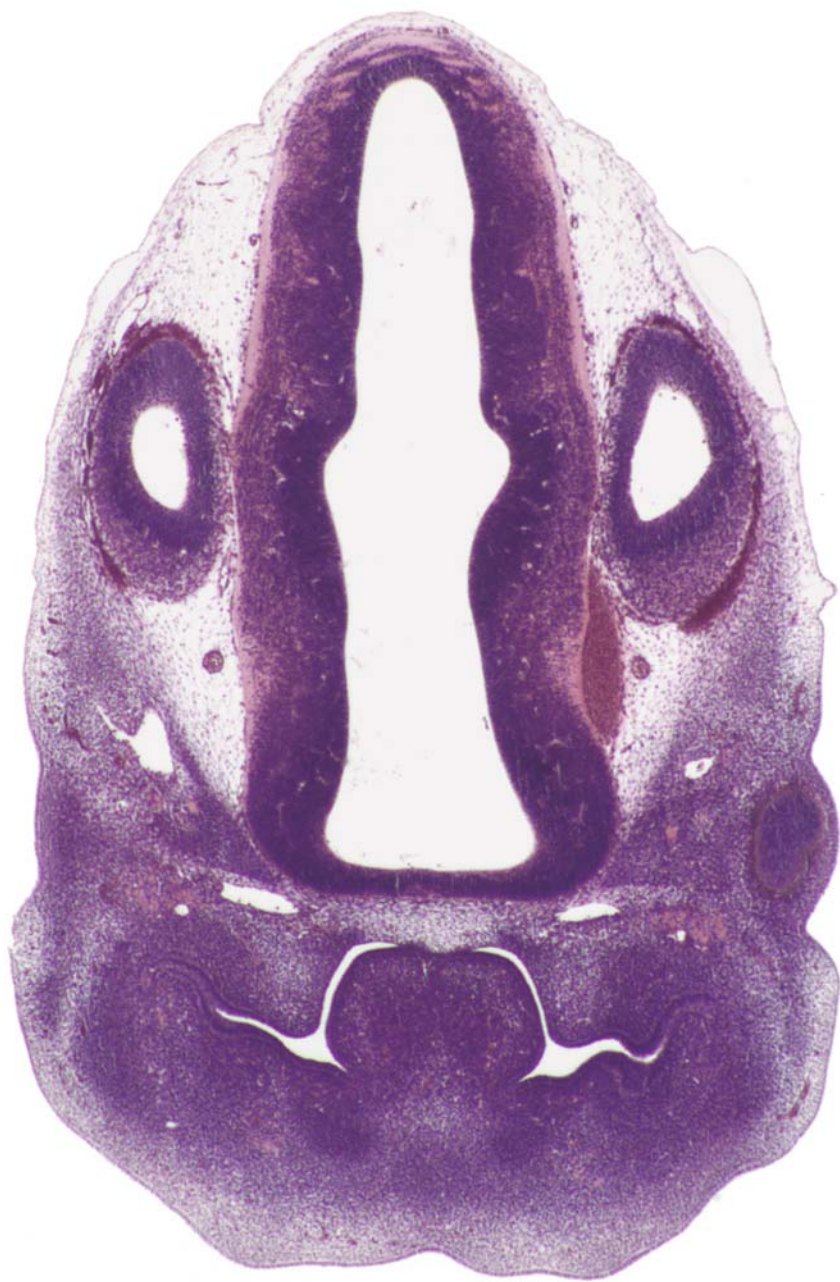



GD 12 CORONAL 8

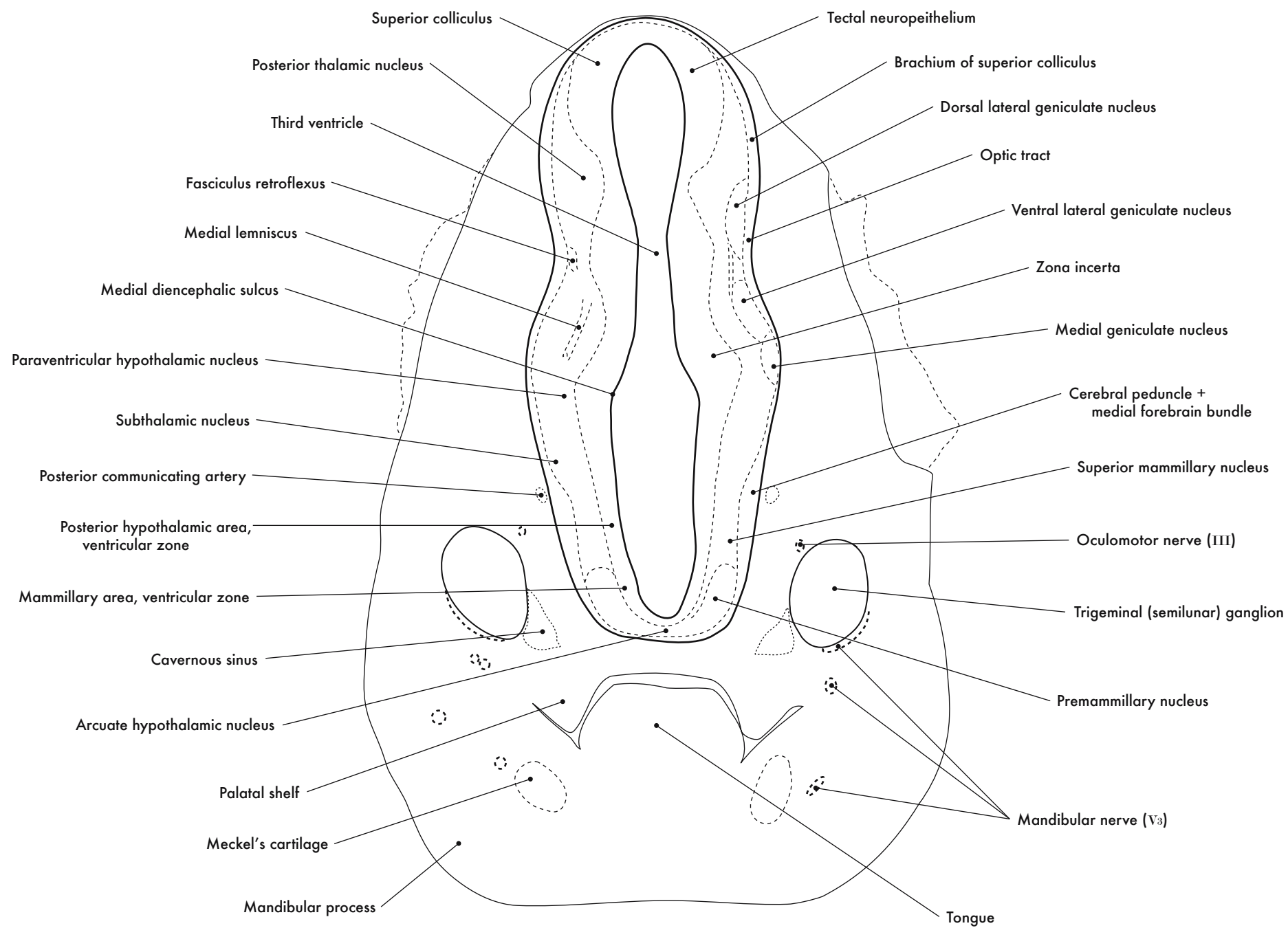


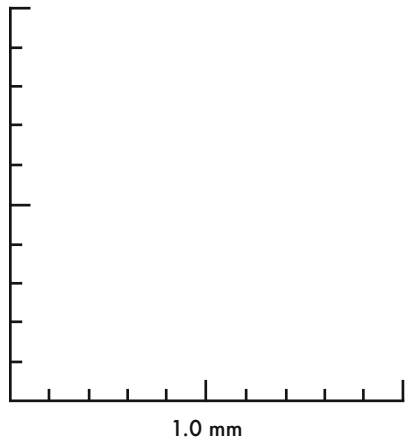
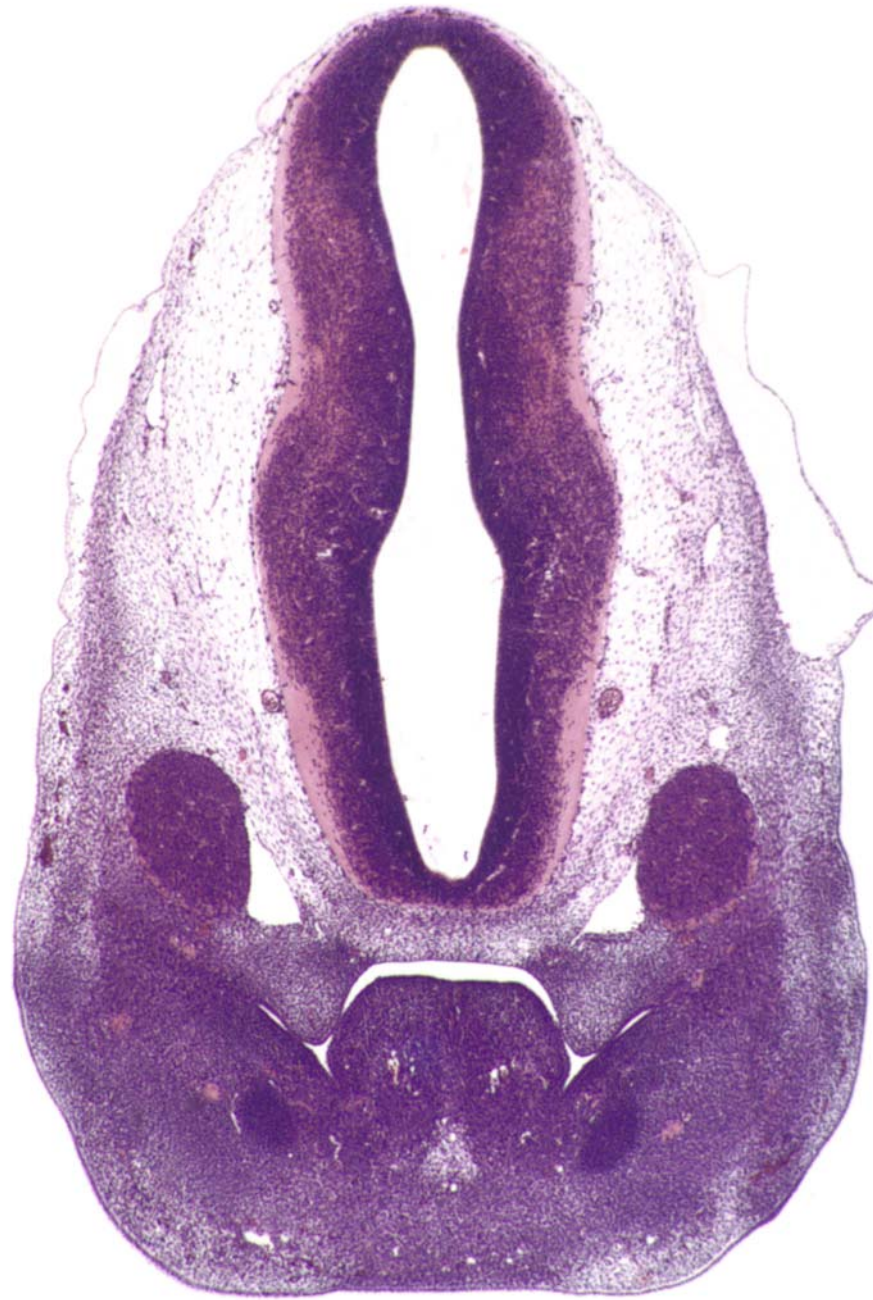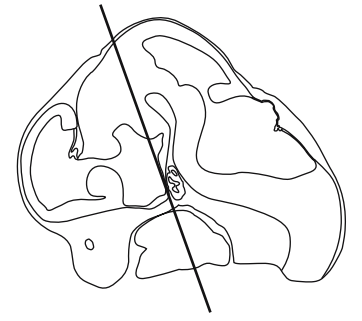




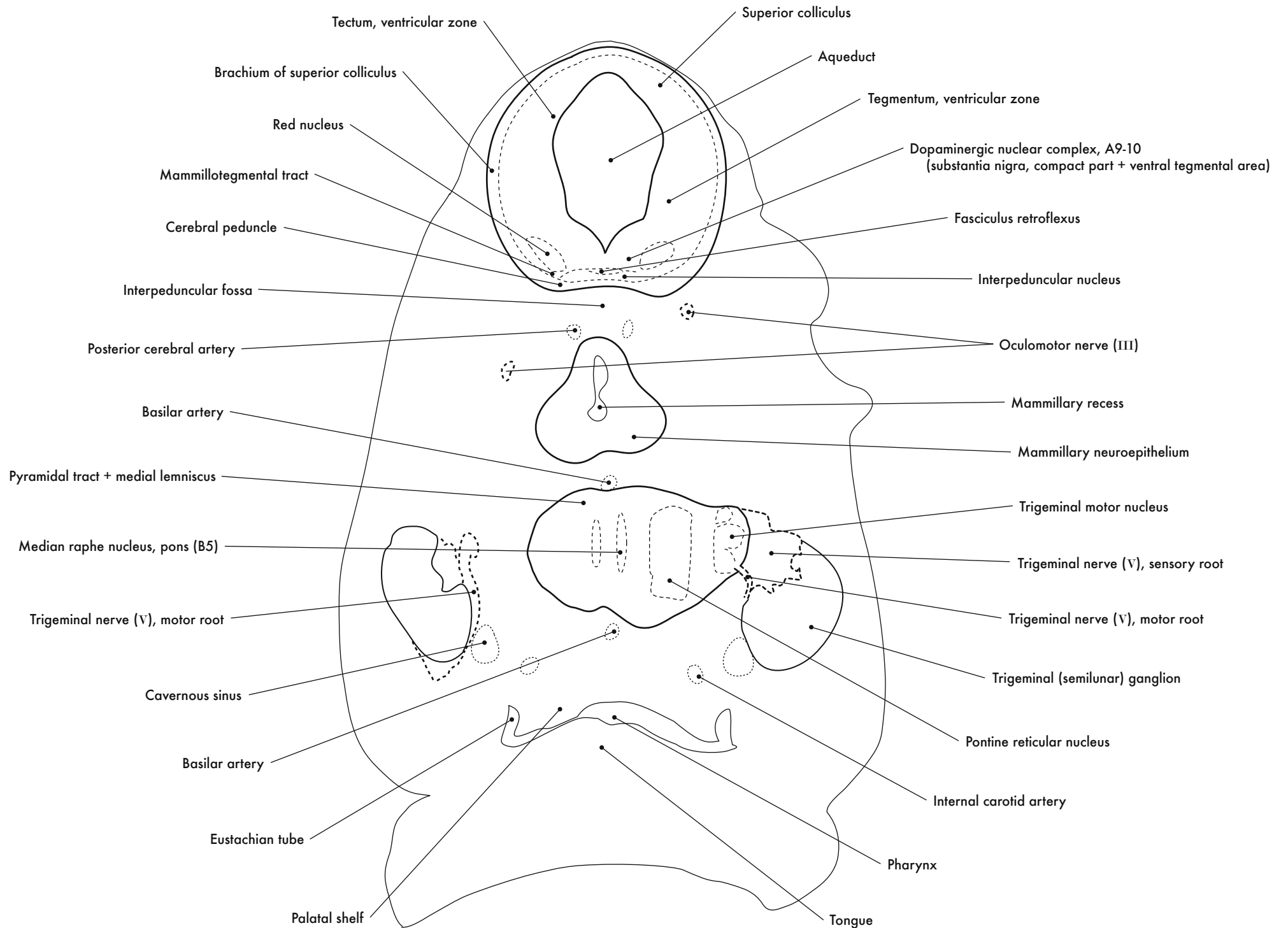
GD 12 CORONAL 9

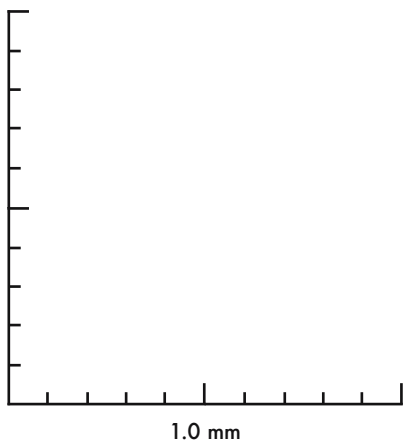
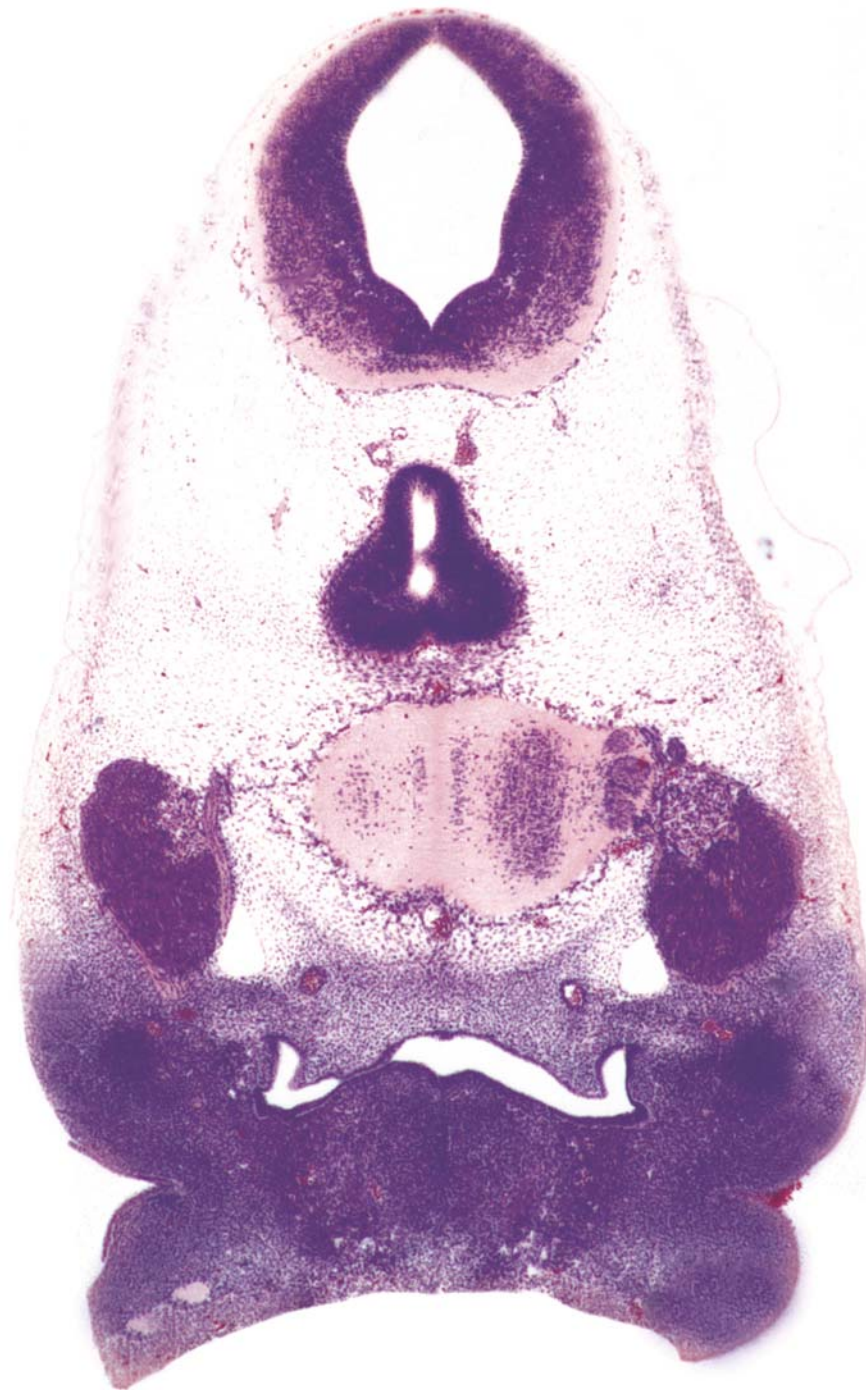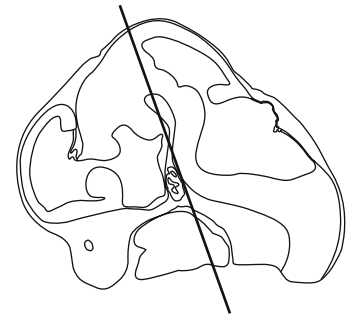




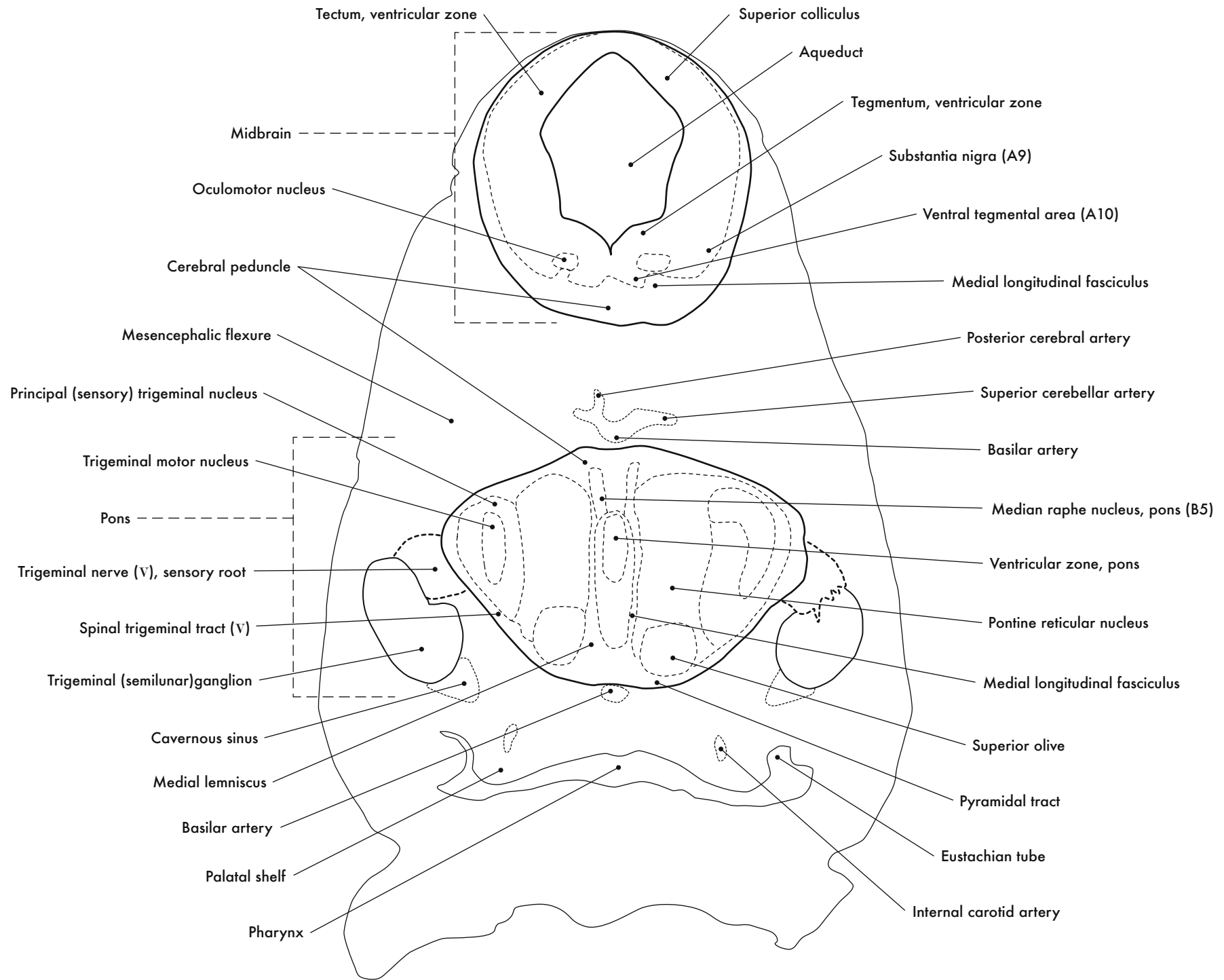


GD 12 CORONAL 10

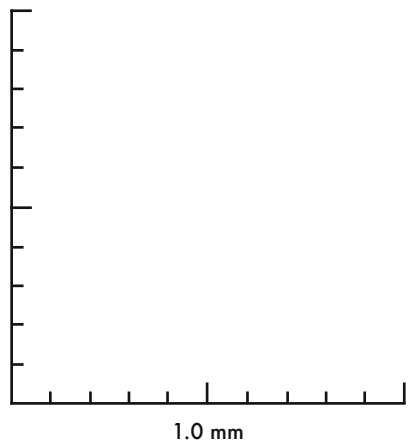
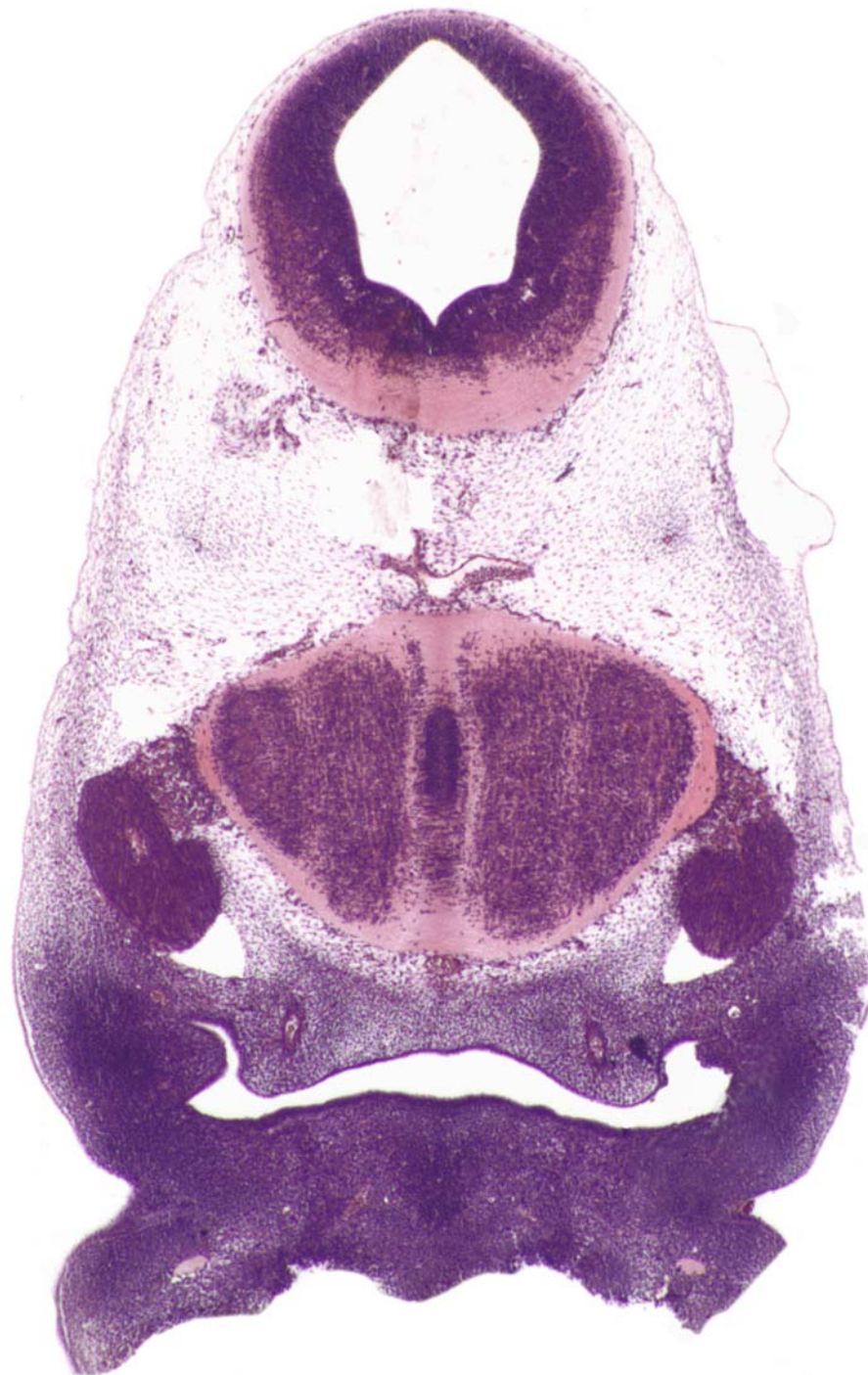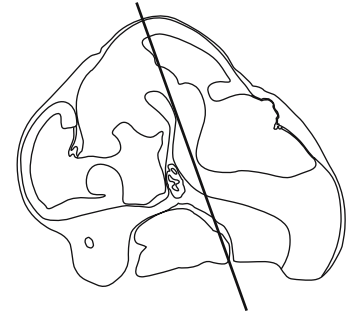




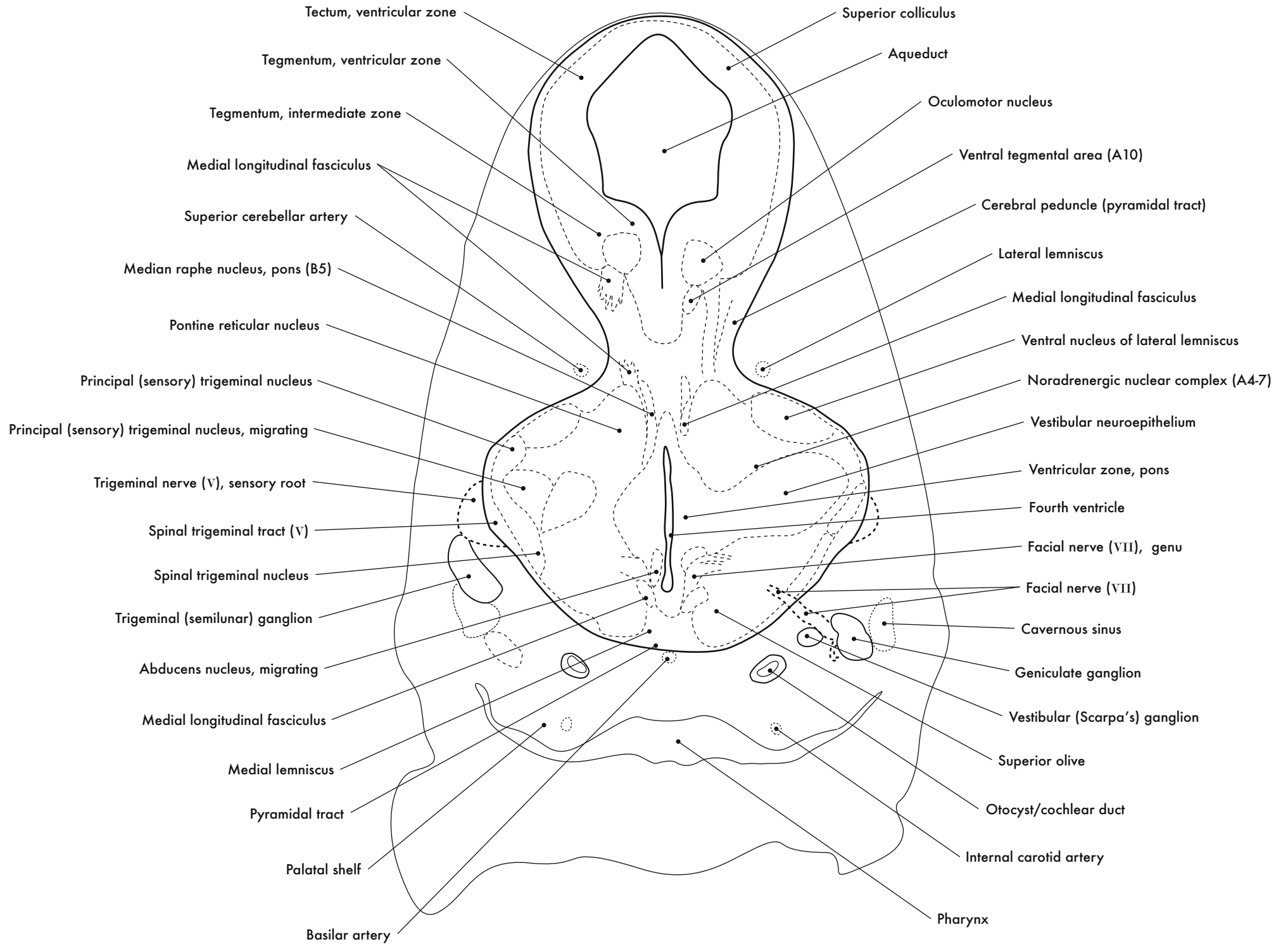
GD 12 CORONAL 11

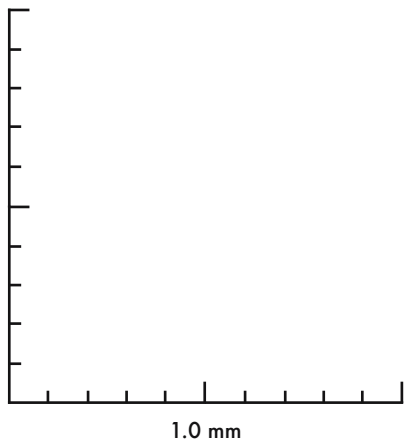
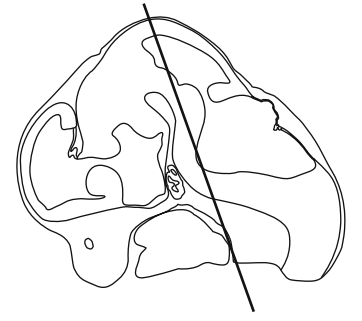
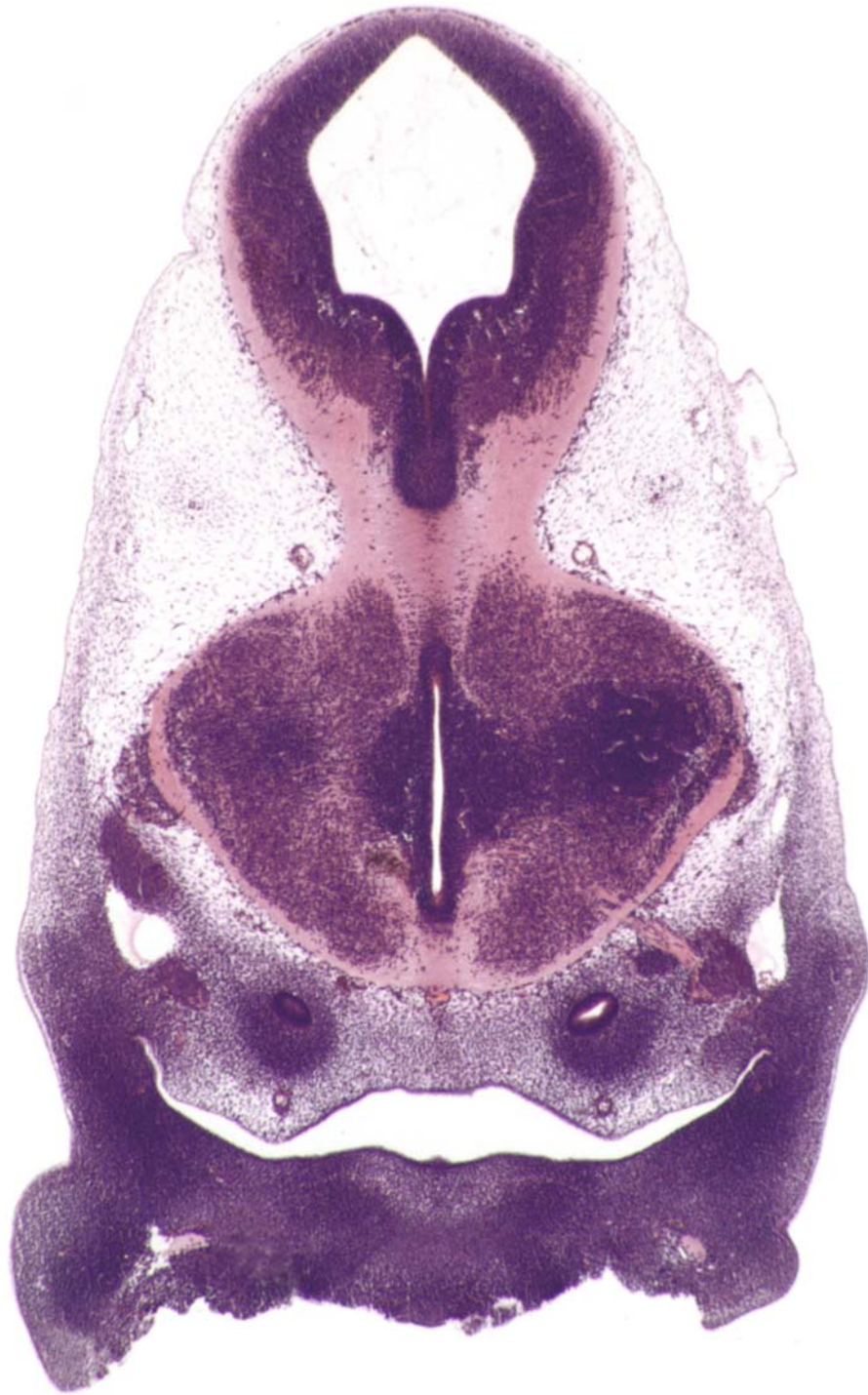



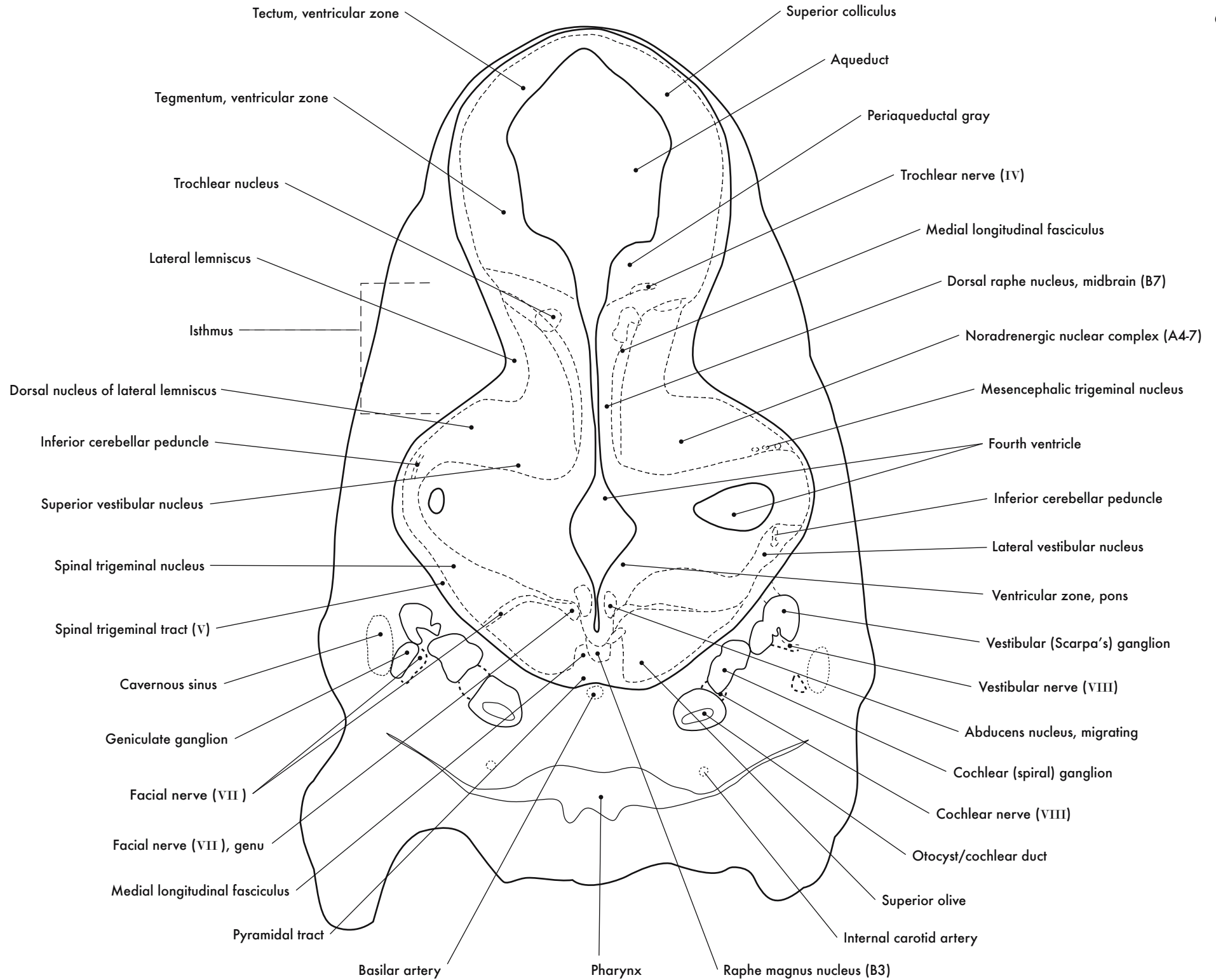


GD 12 CORONAL 12

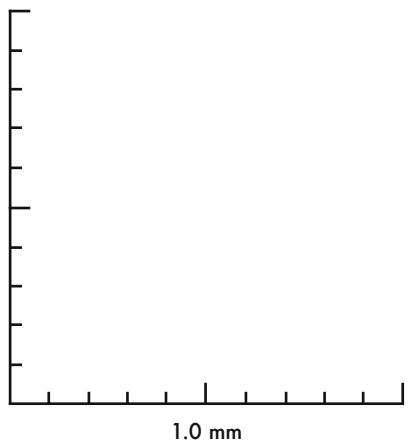
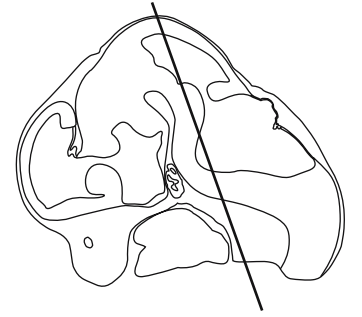
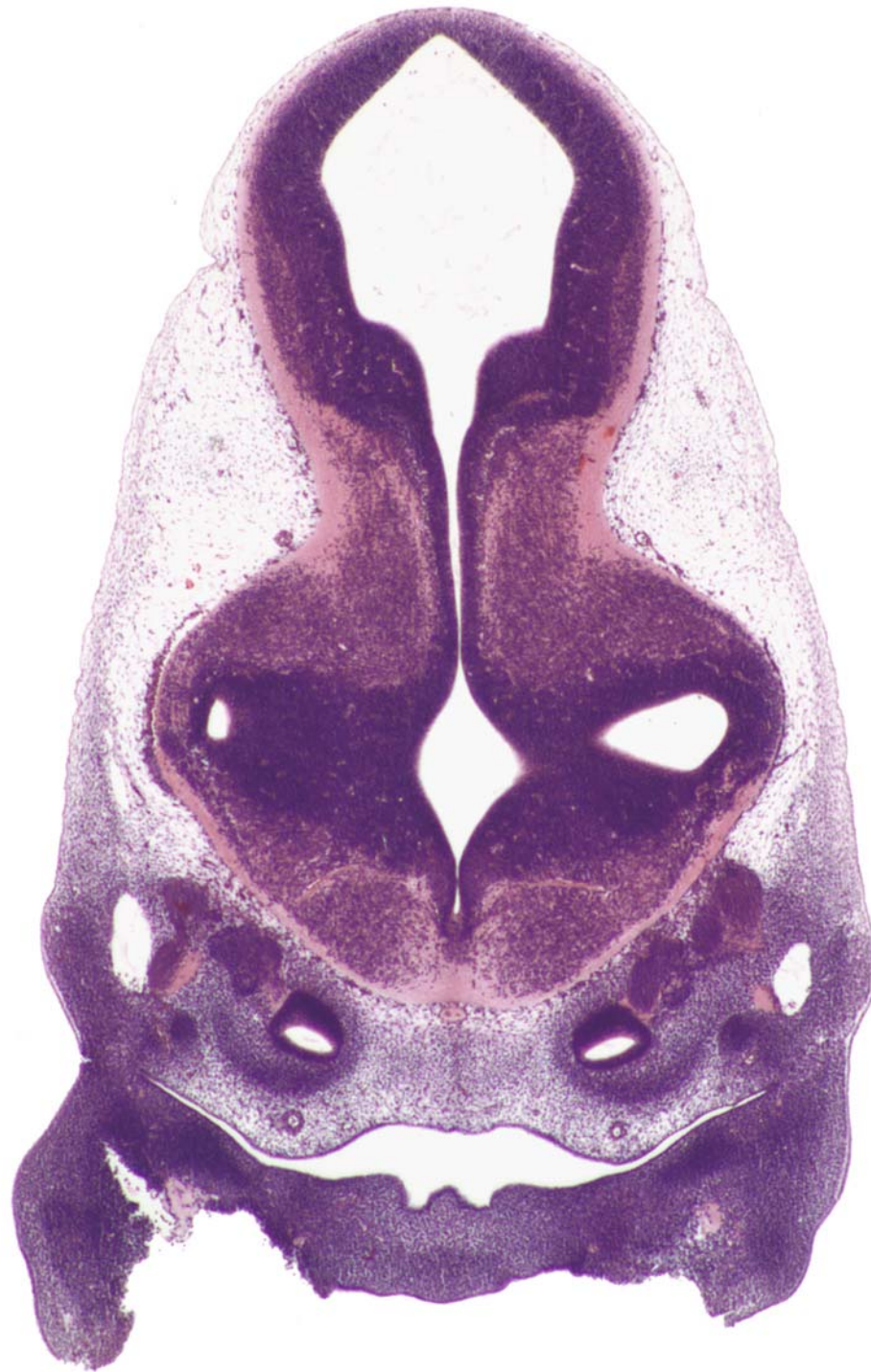



GD 12 CORONAL 13

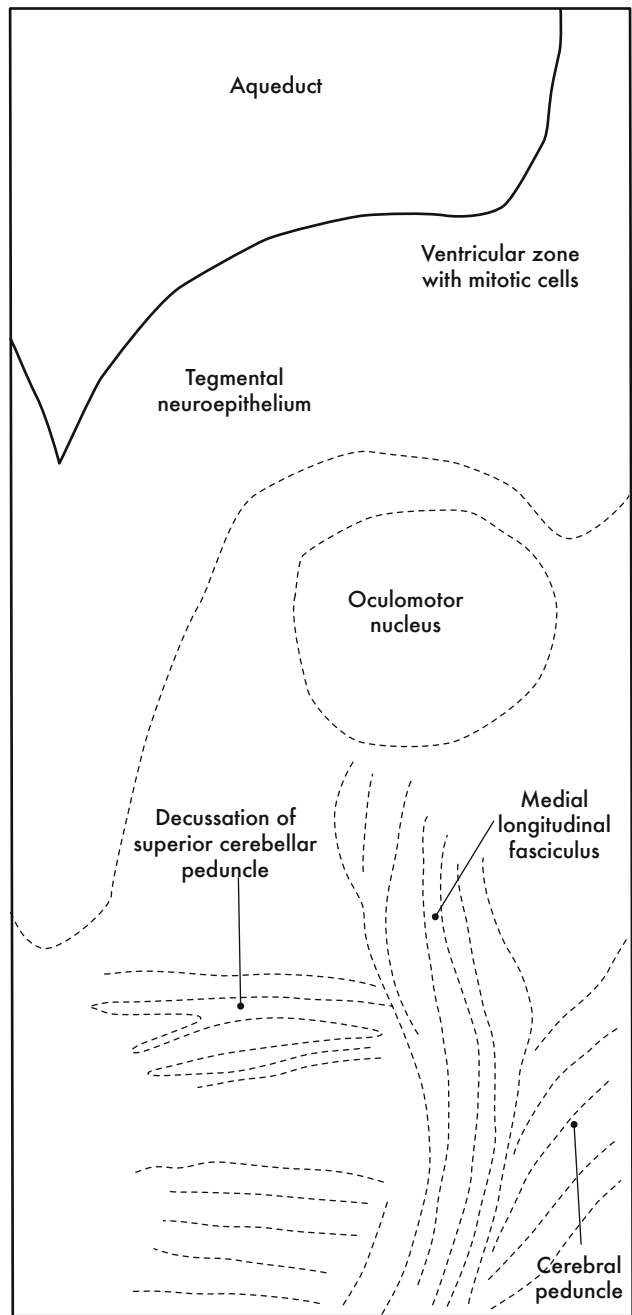




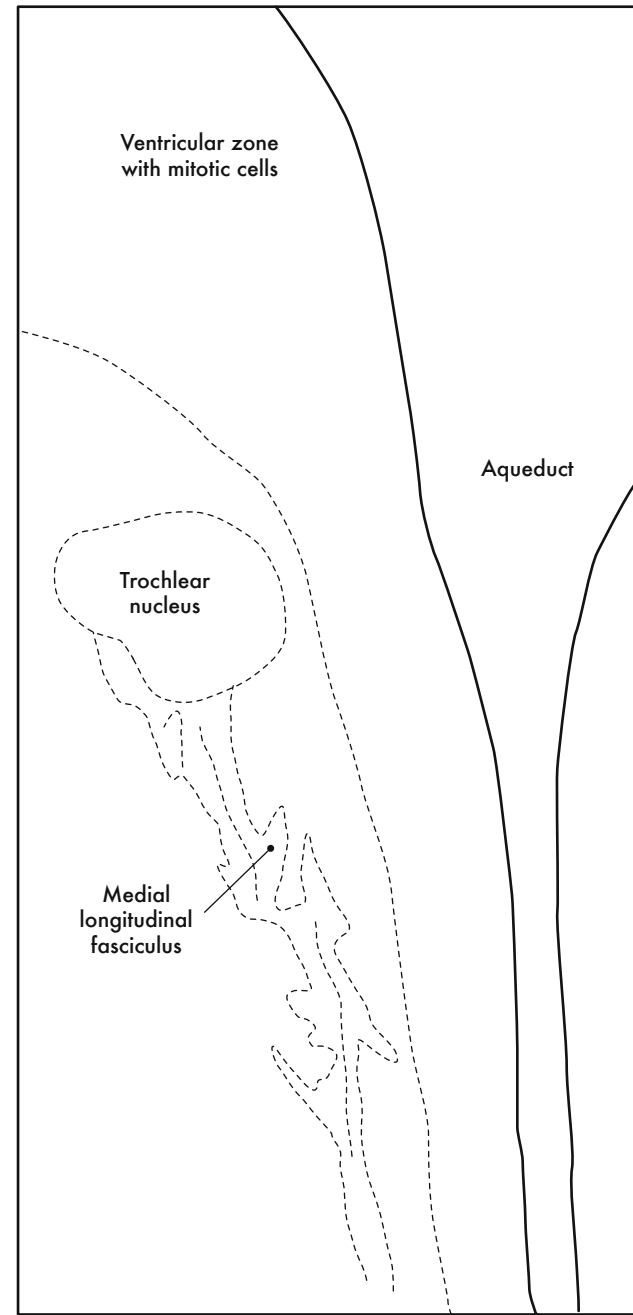


GD 12 CORONAL 14

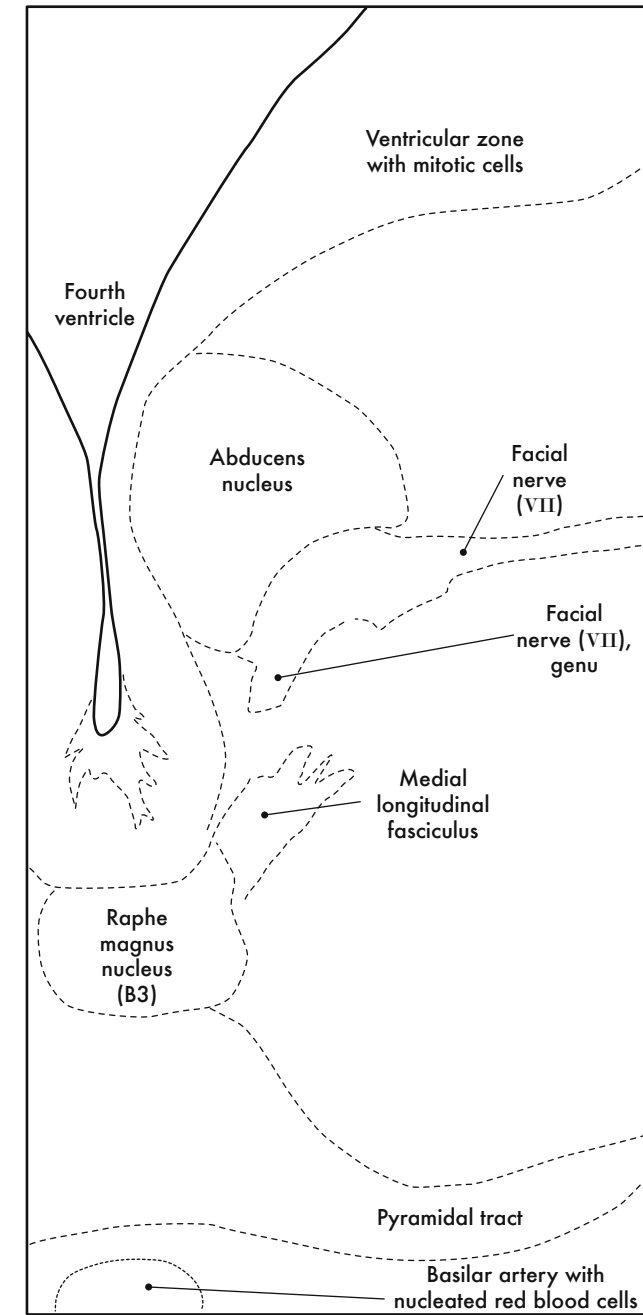




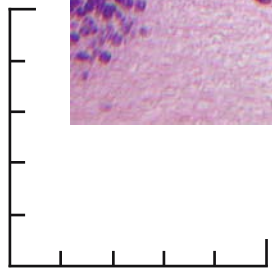
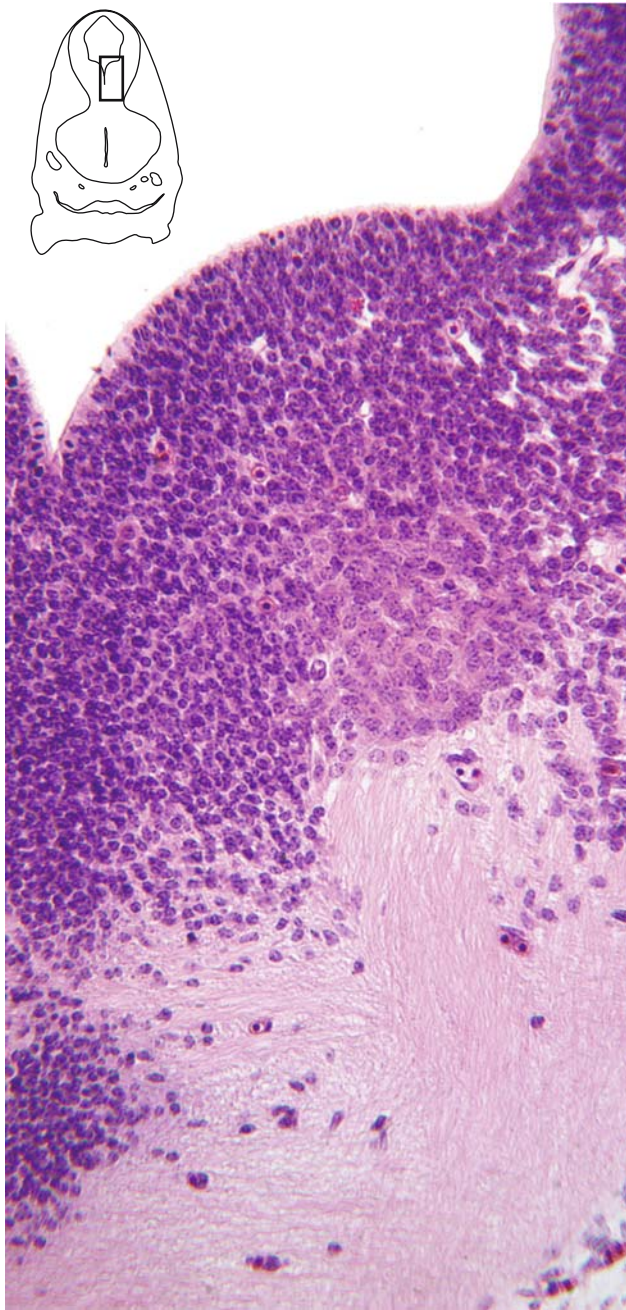
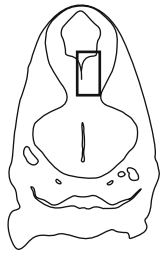
A. Oculomotor nucleus



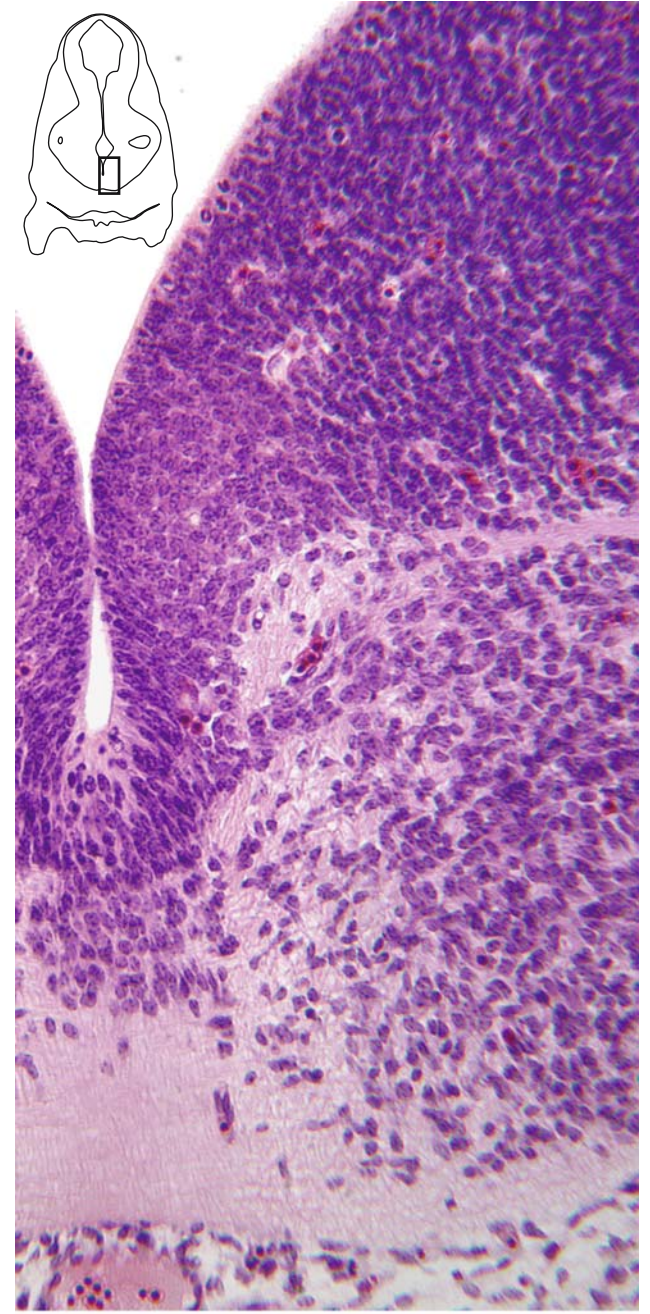
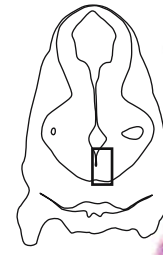
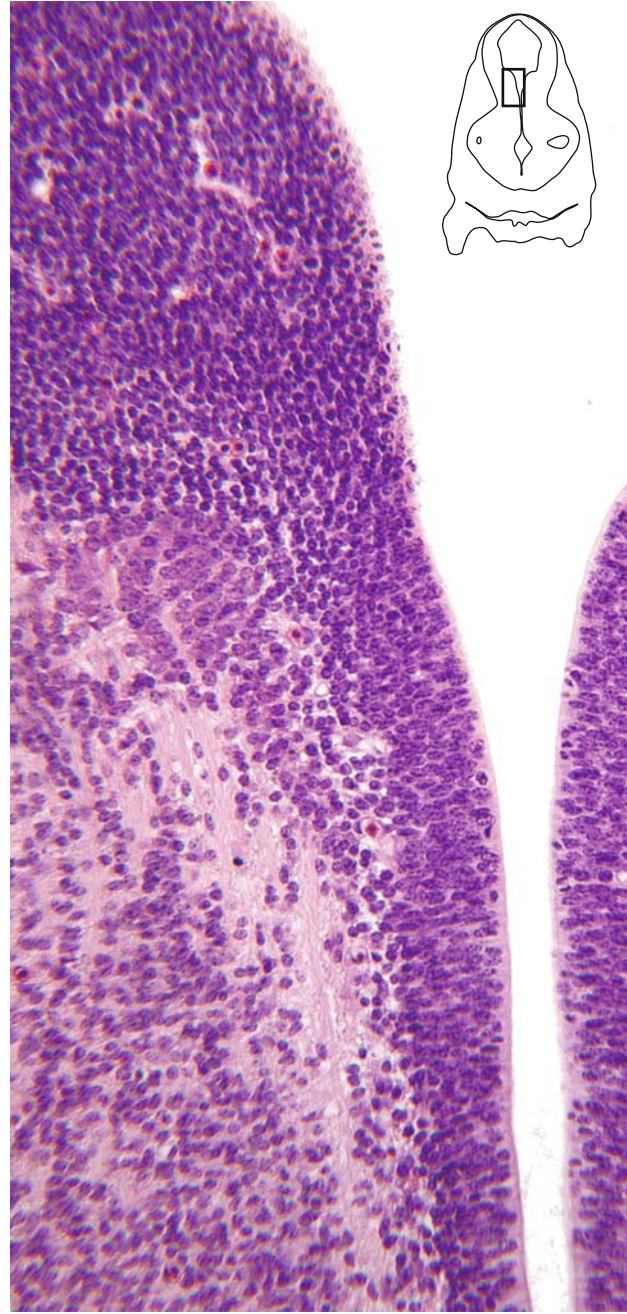
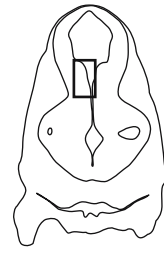
B. Trochlear nucleus



C. Abducens nucleus

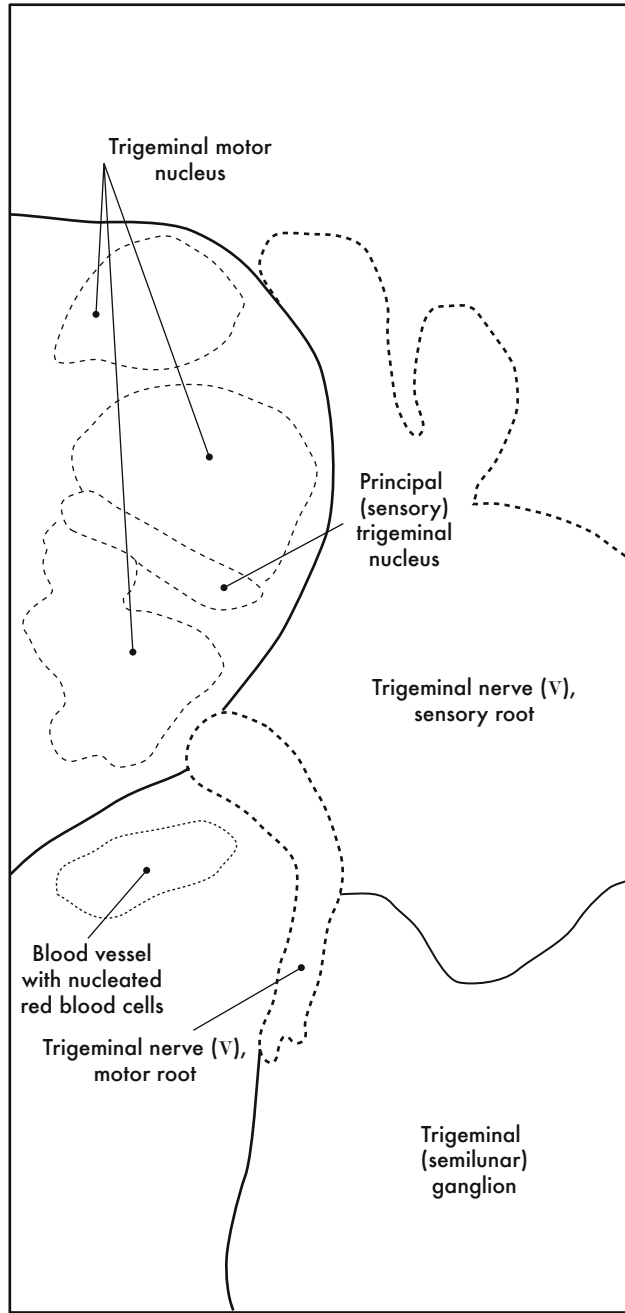


0.5 mm

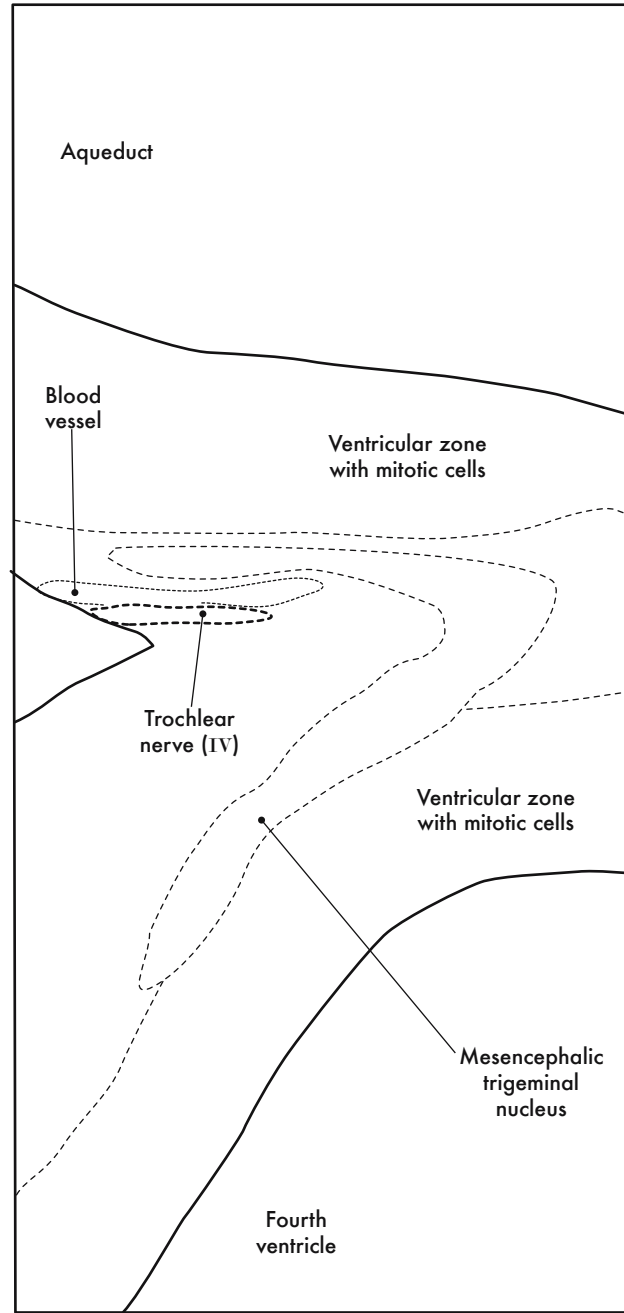


GD 12 CORONAL 15

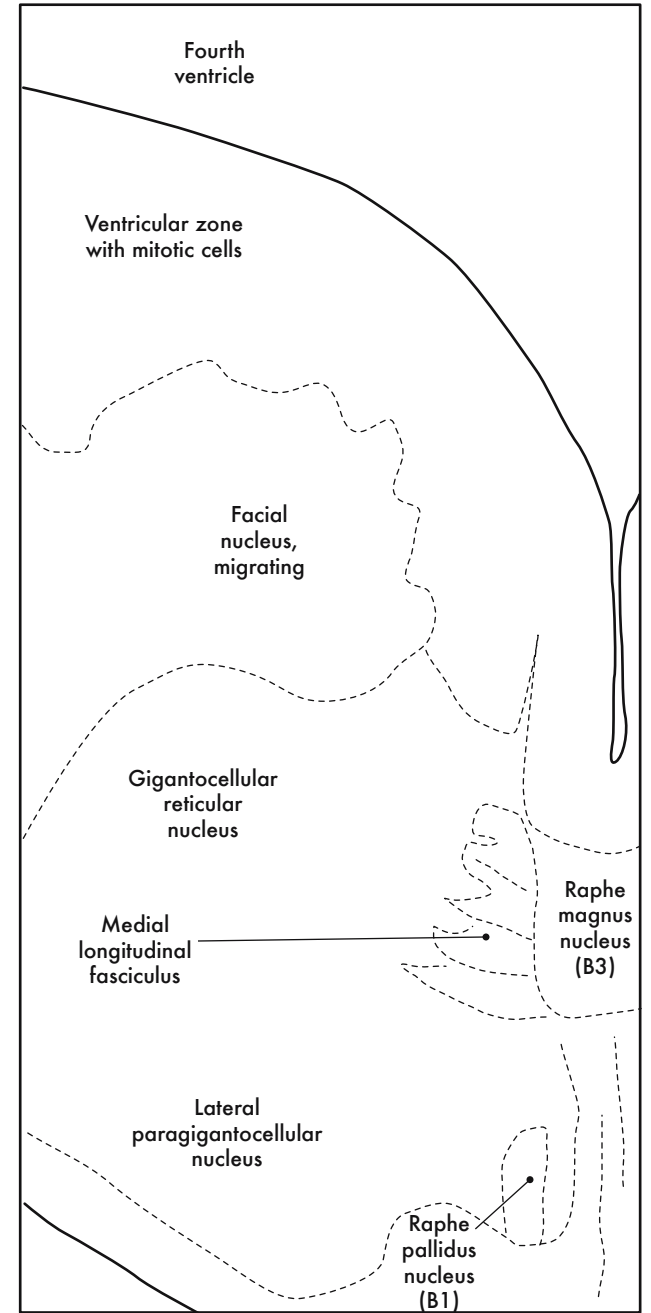




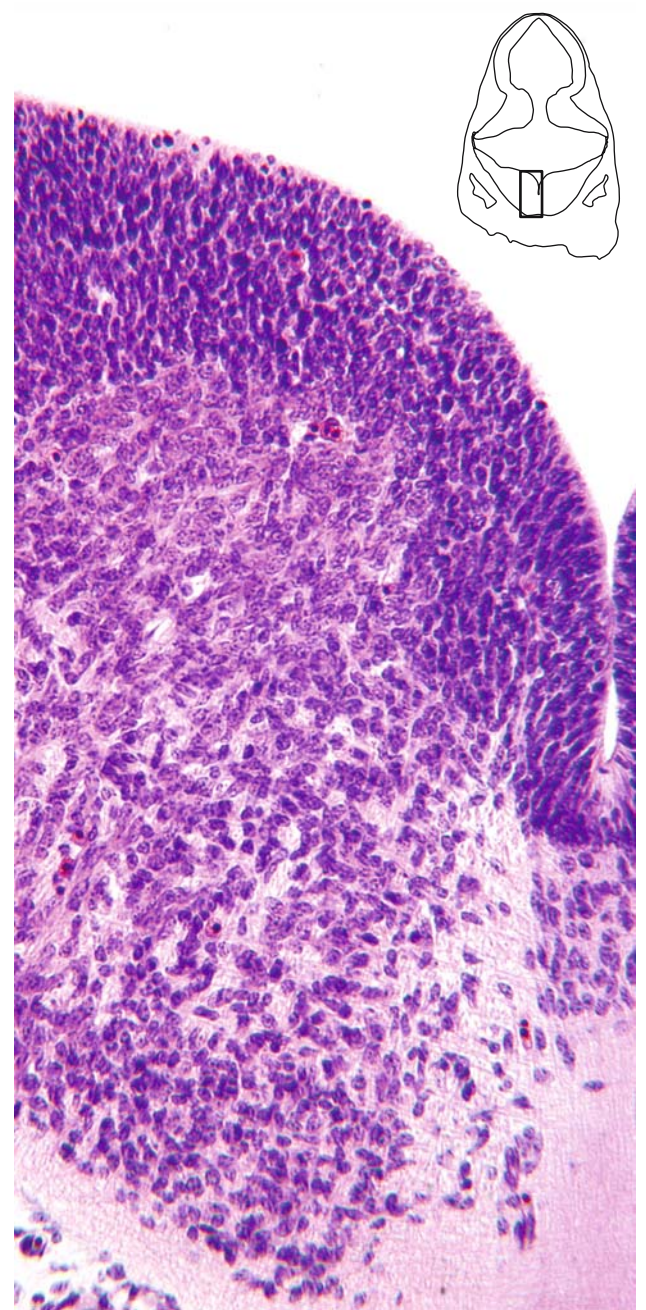
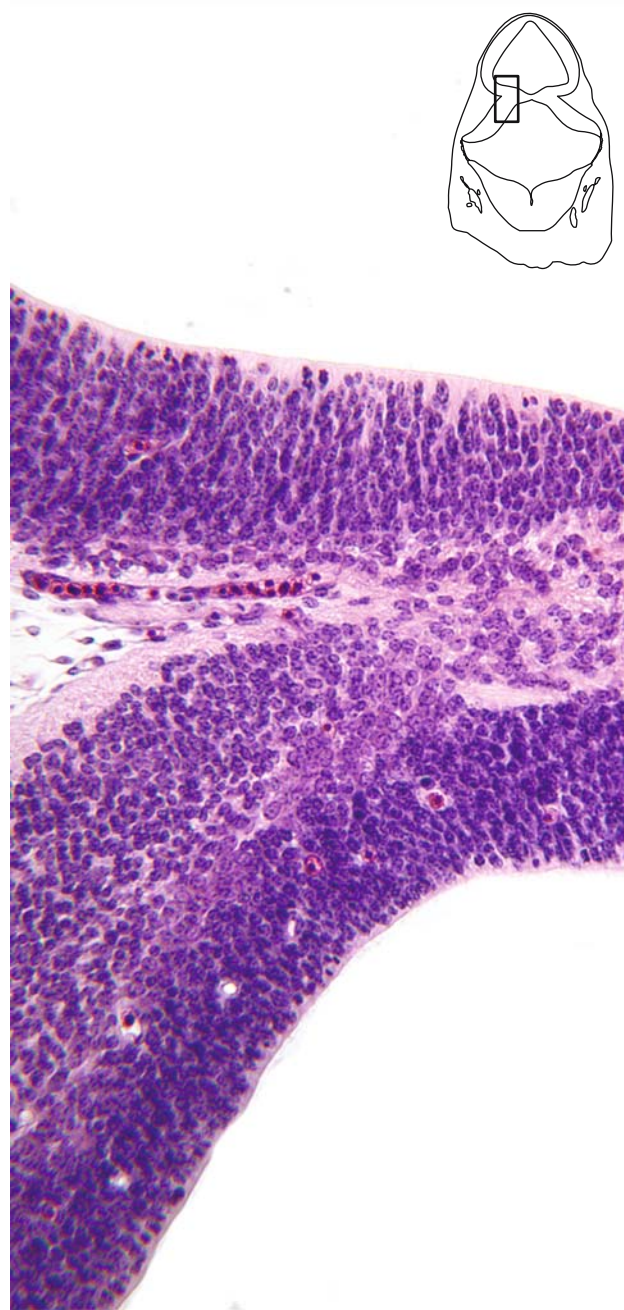
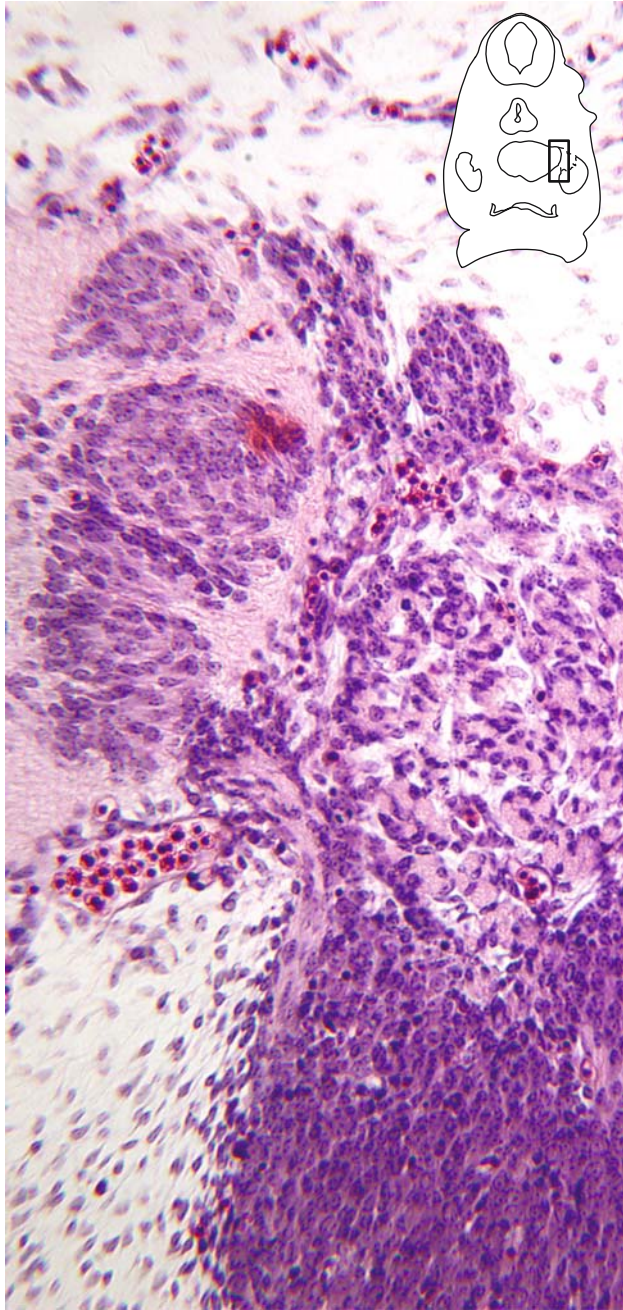
A. Motor + principal (sensory) trigeminal nuclei



B. Mesencephalic trigeminal nucleus



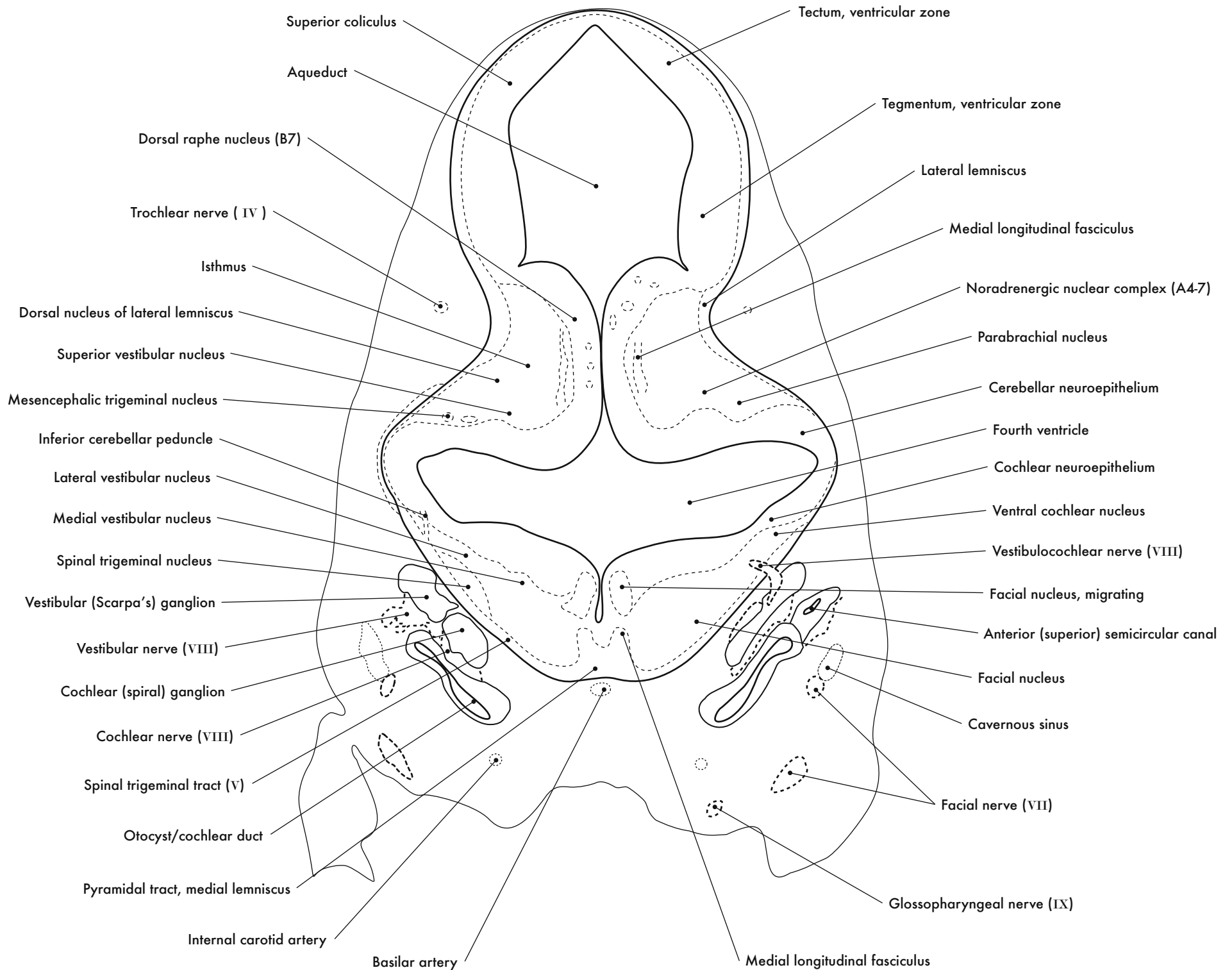
C. Facial nucleus



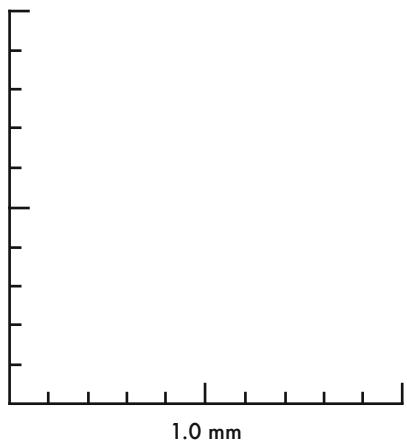
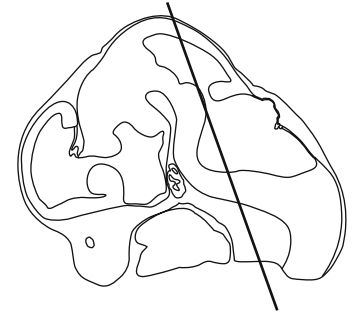
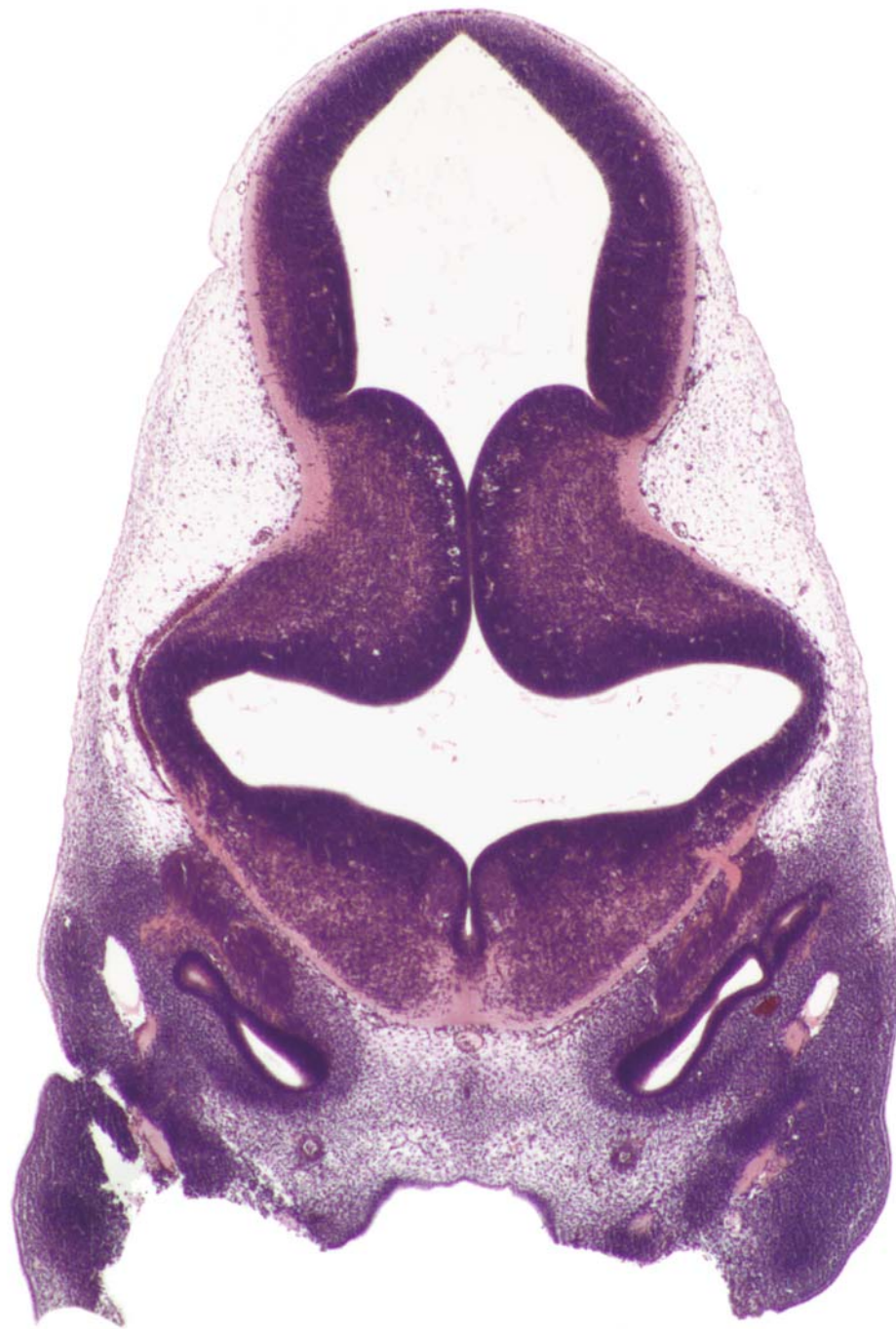0.5 mm

GD 12 CORONAL 16

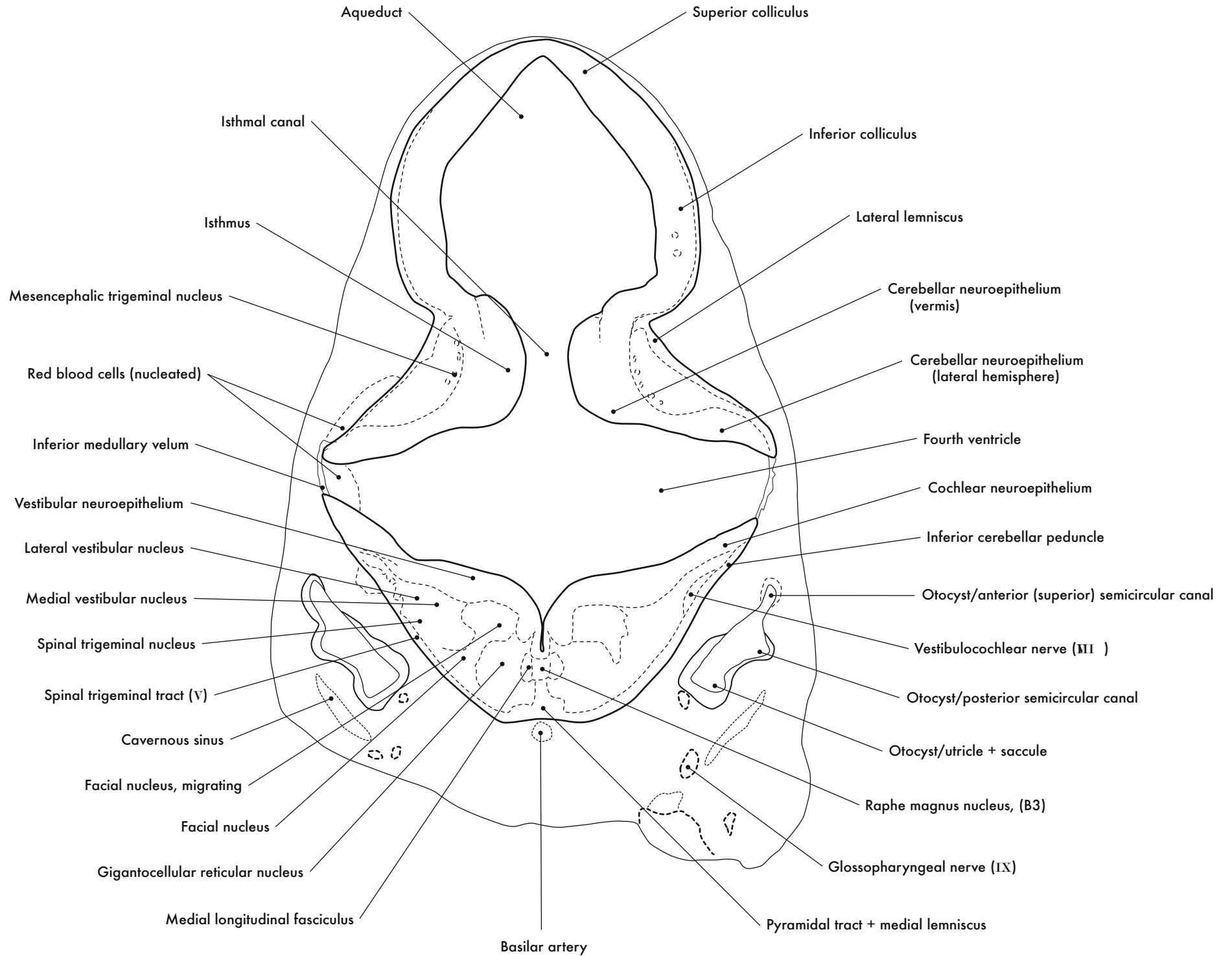


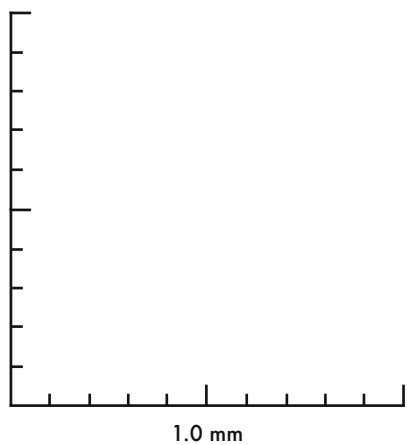
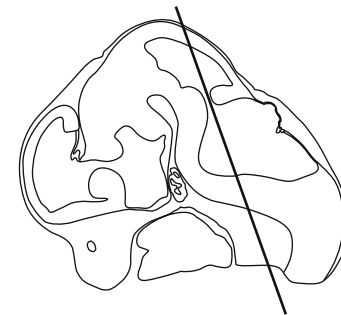
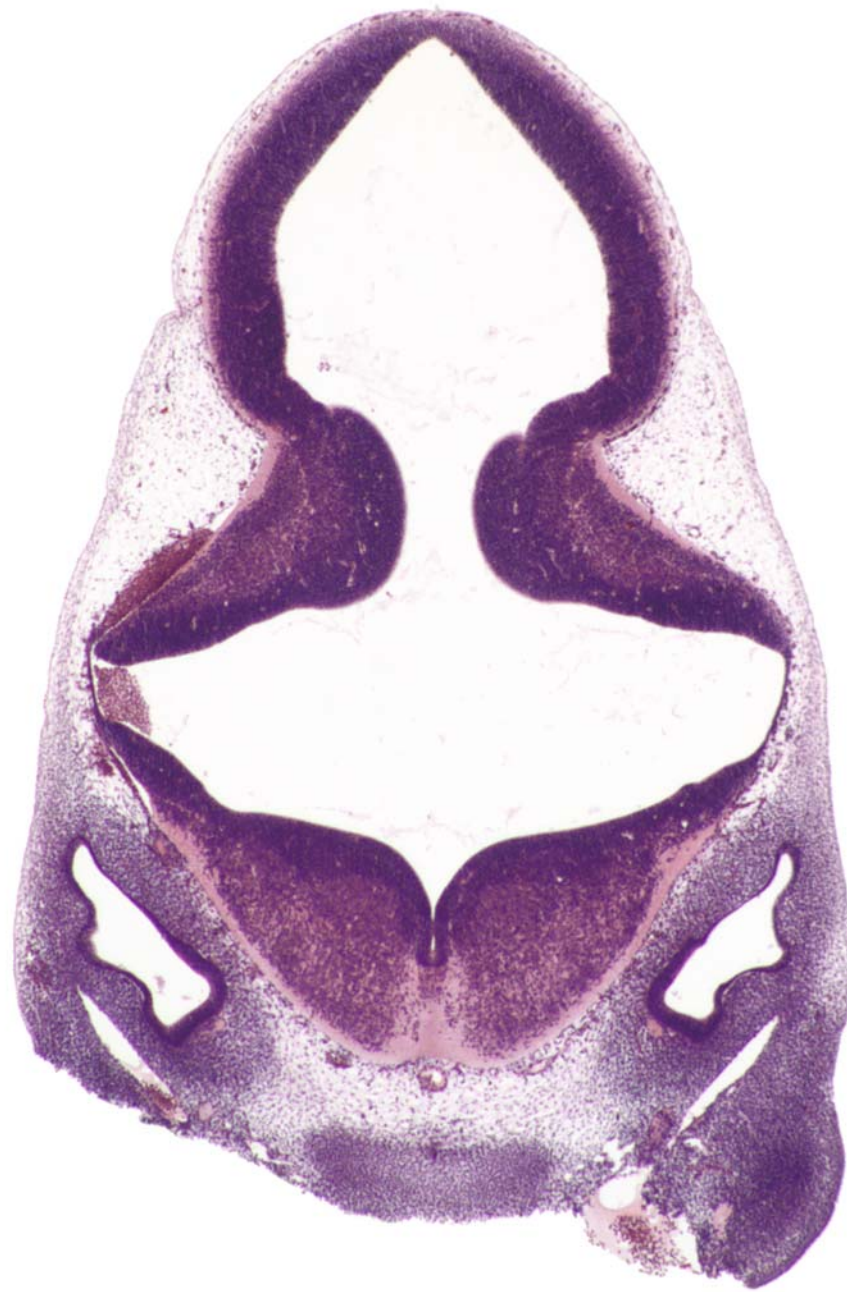



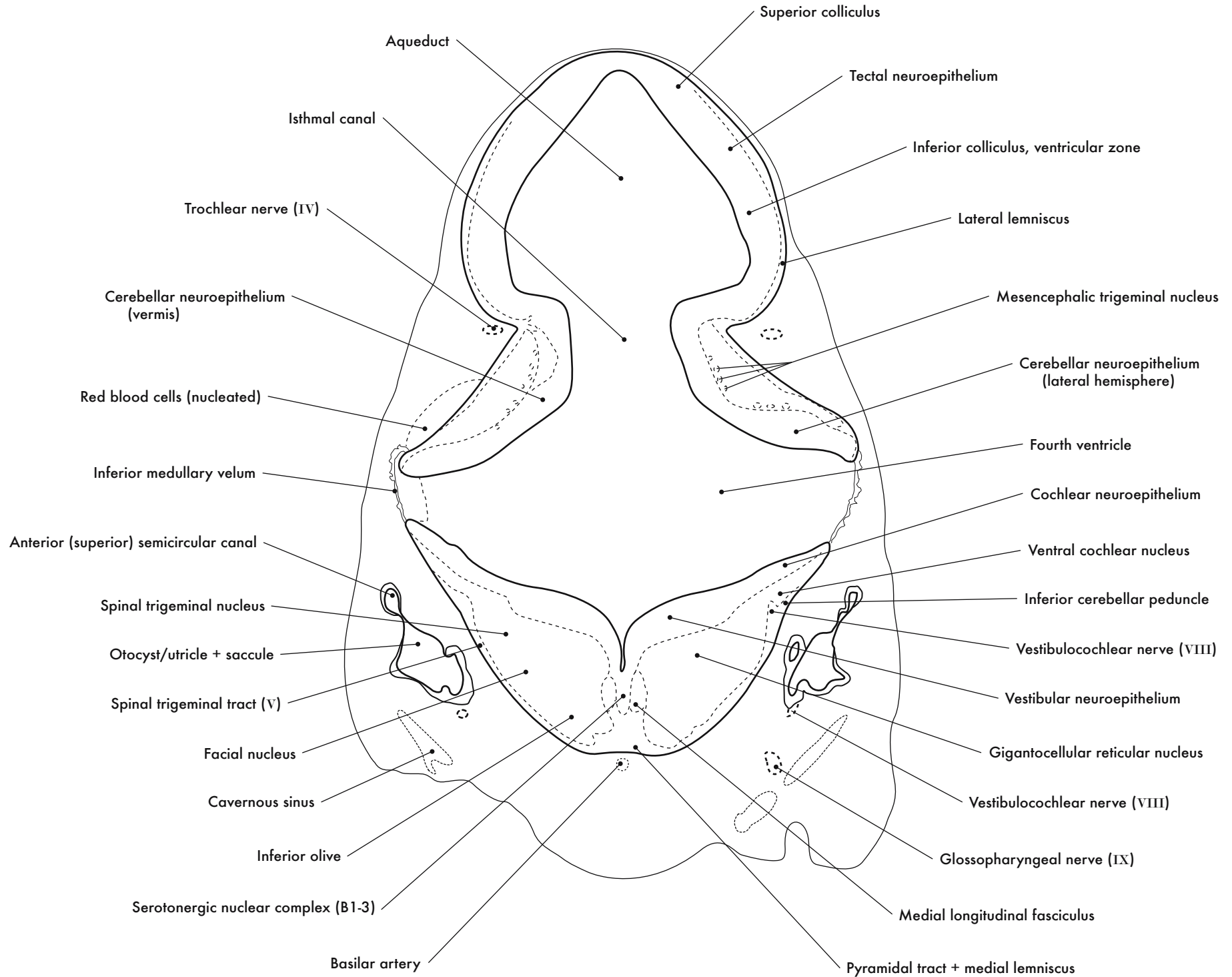


GD 12 CORONAL 17

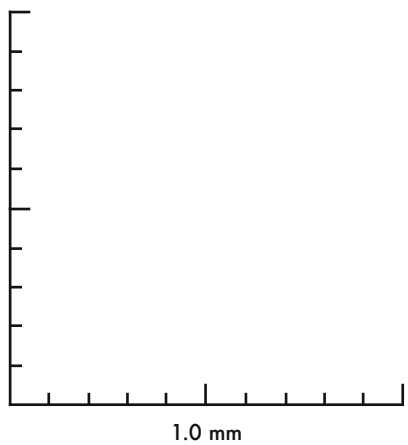
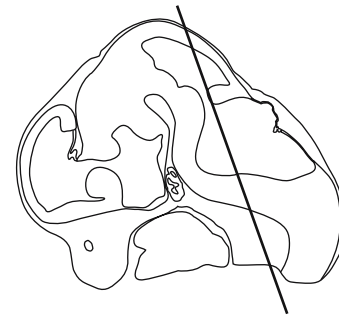
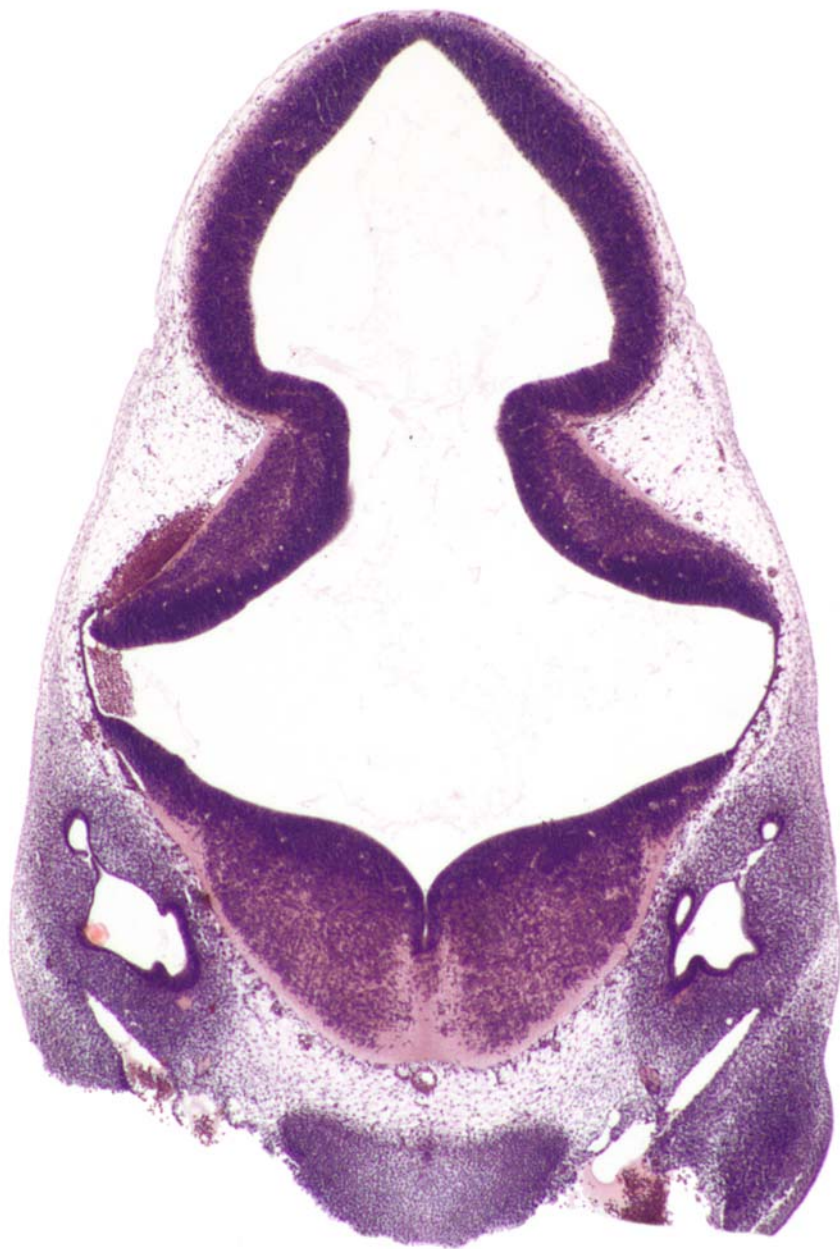



GD 12 CORONAL 18

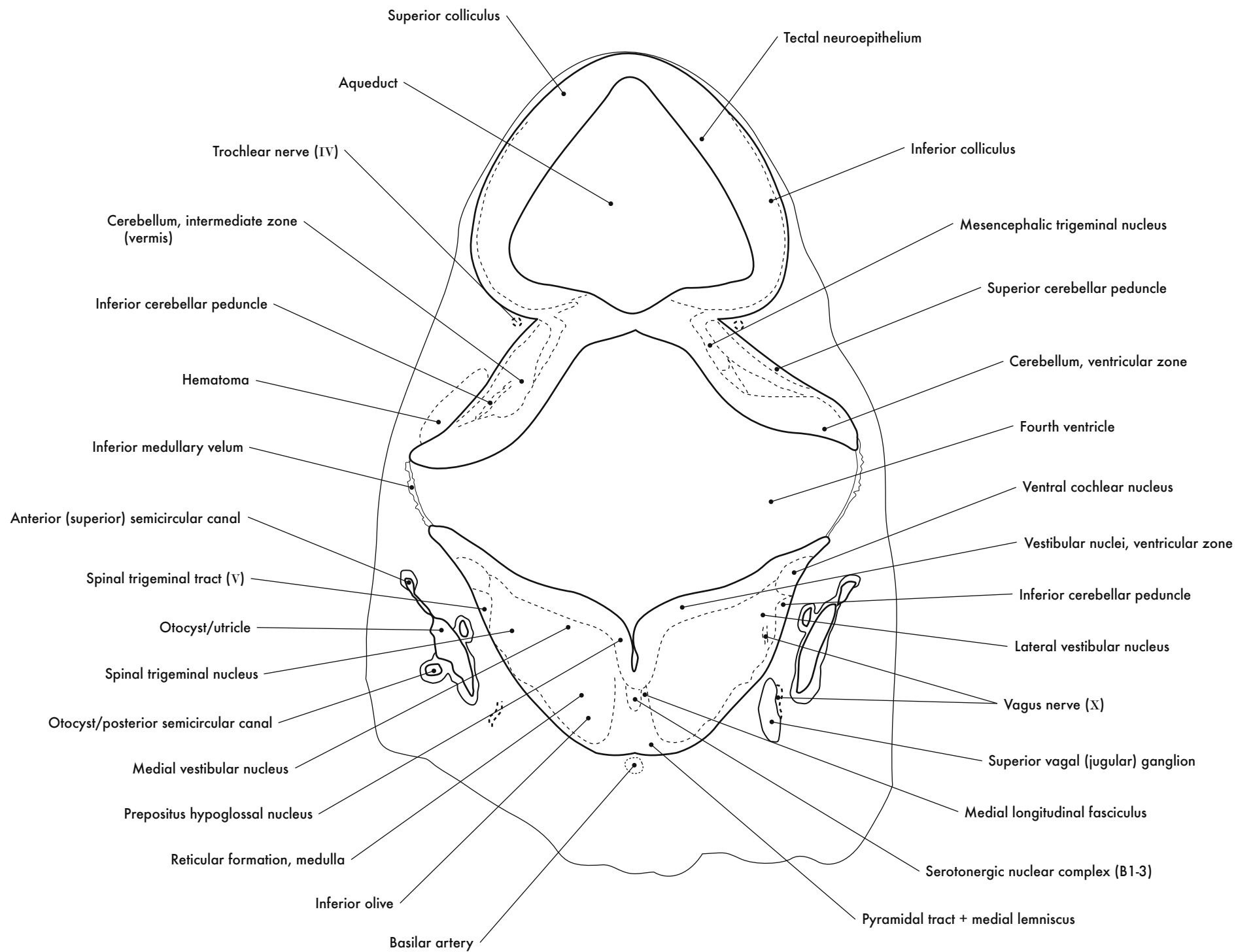


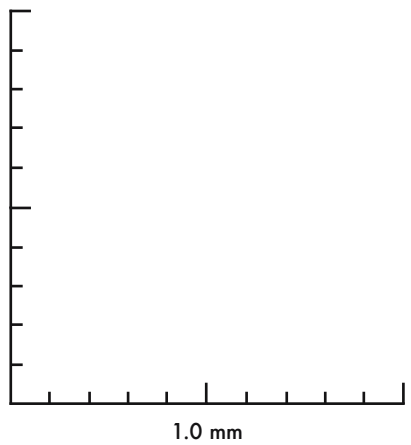
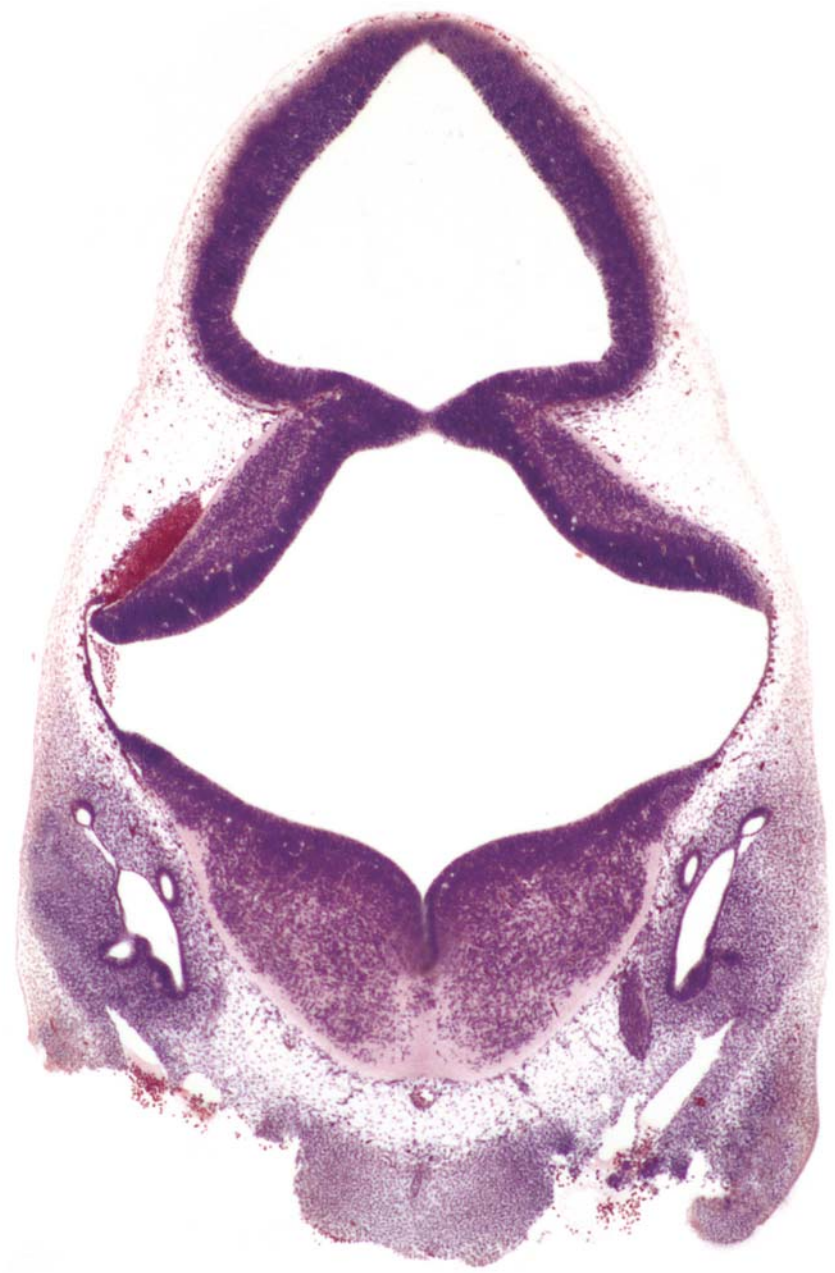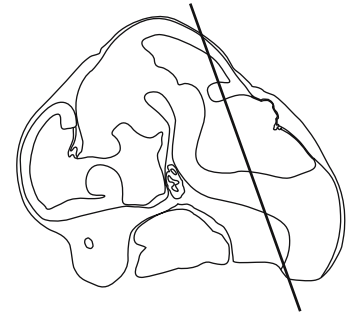




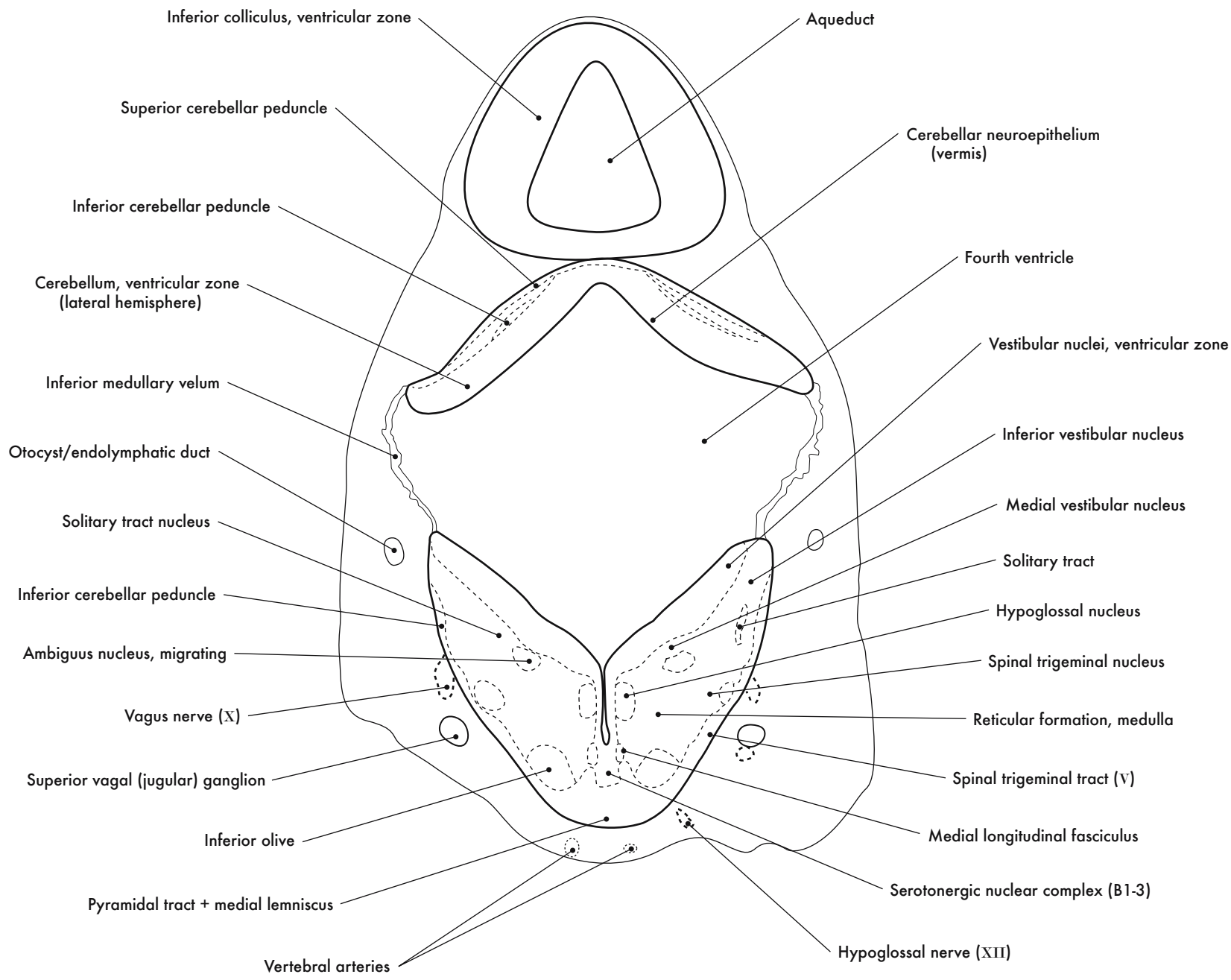
GD 12 CORONAL 19

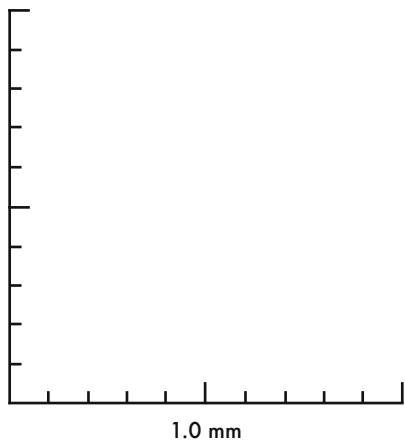
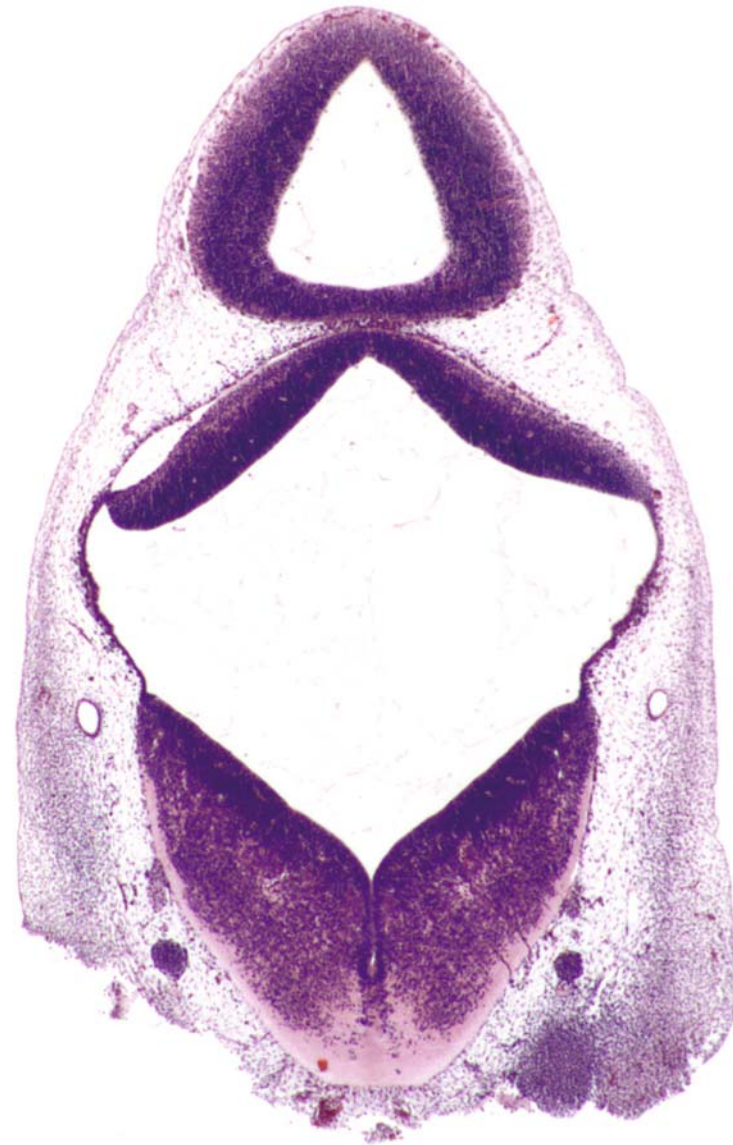
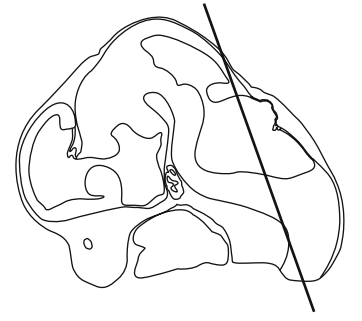




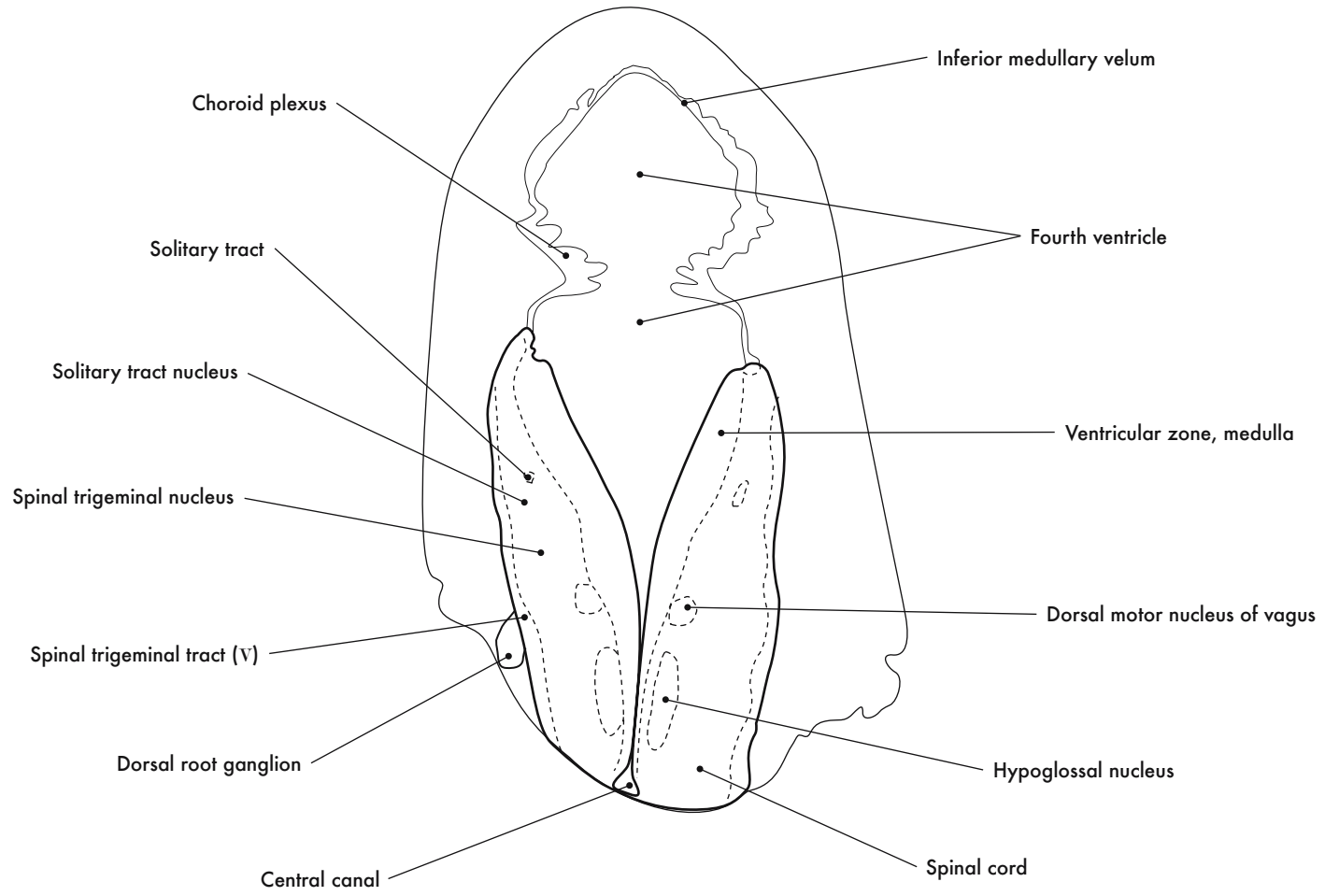


GD 12 CORONAL 20

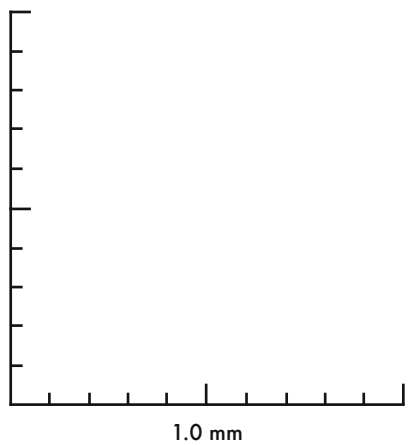
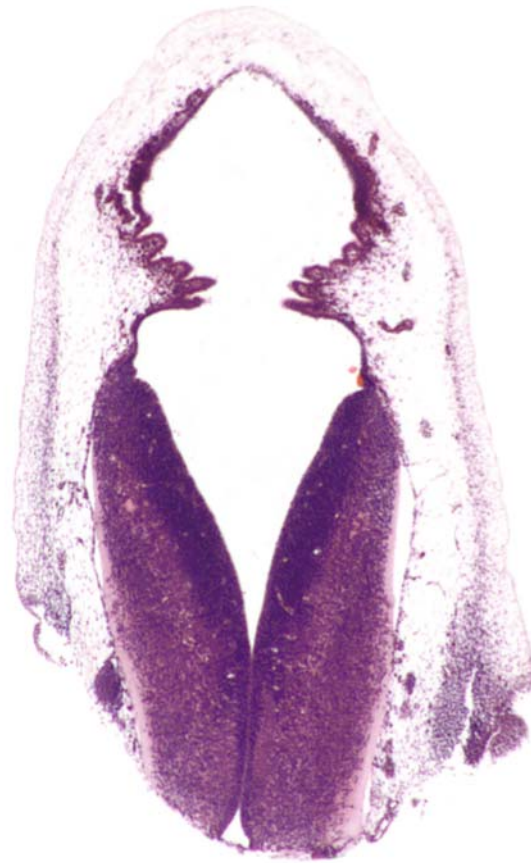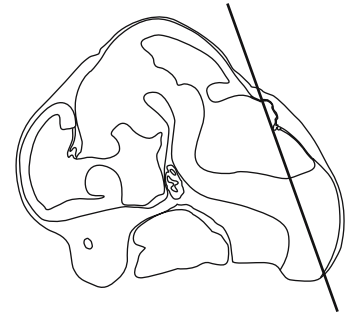




GD12 CORONAL 21

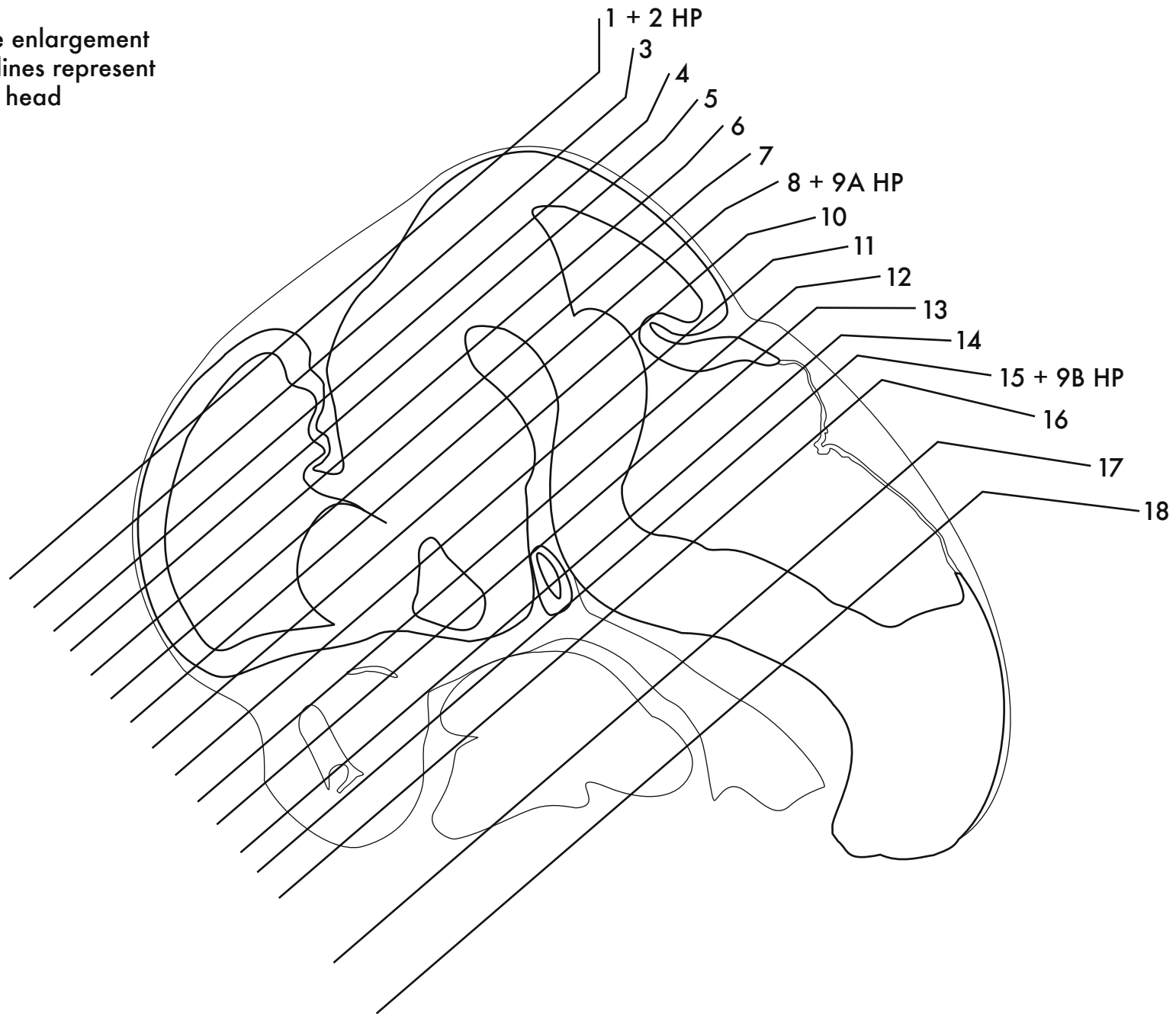




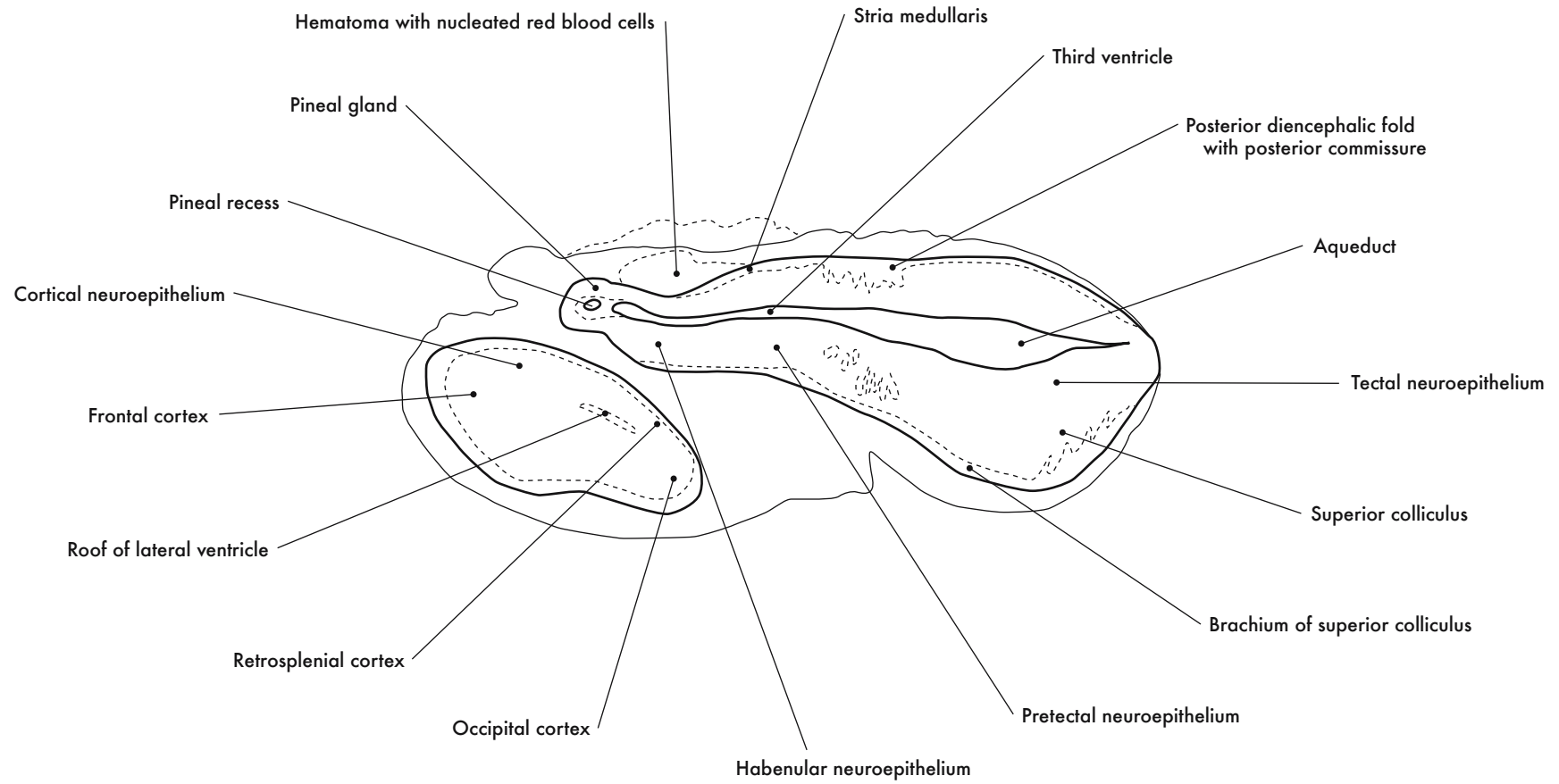


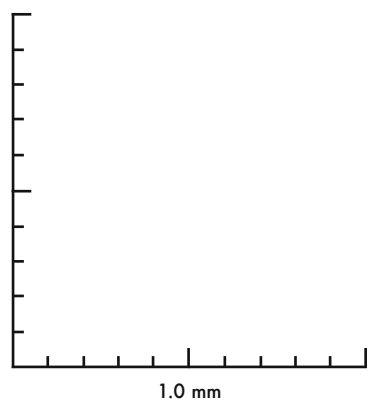
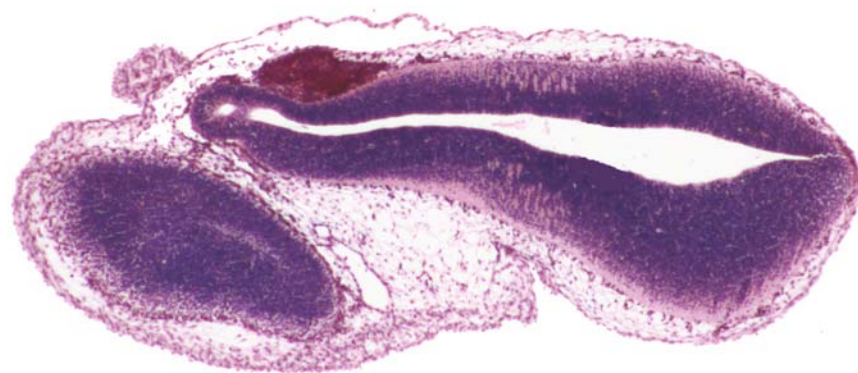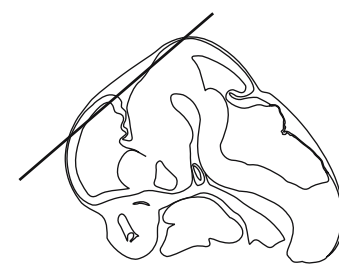GD 12 CORONAL 22

HP denotes image enlargement  
Note: Sectioning lines represent  
the left side of head

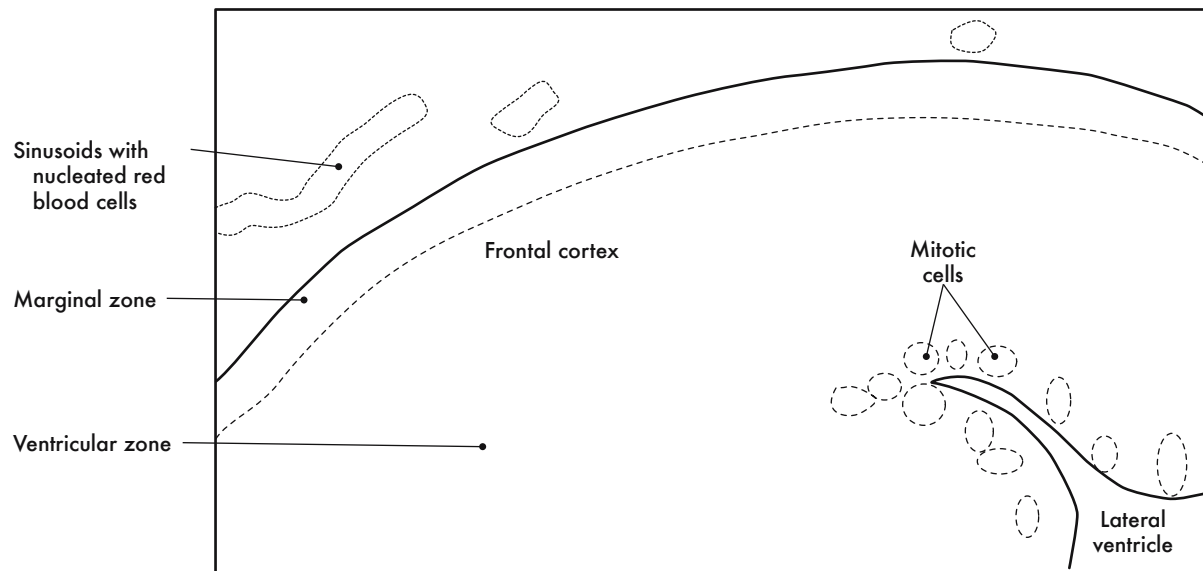


**GESTATIONAL DAY 12 (GD 12)  
HORIZONTAL SECTIONS**

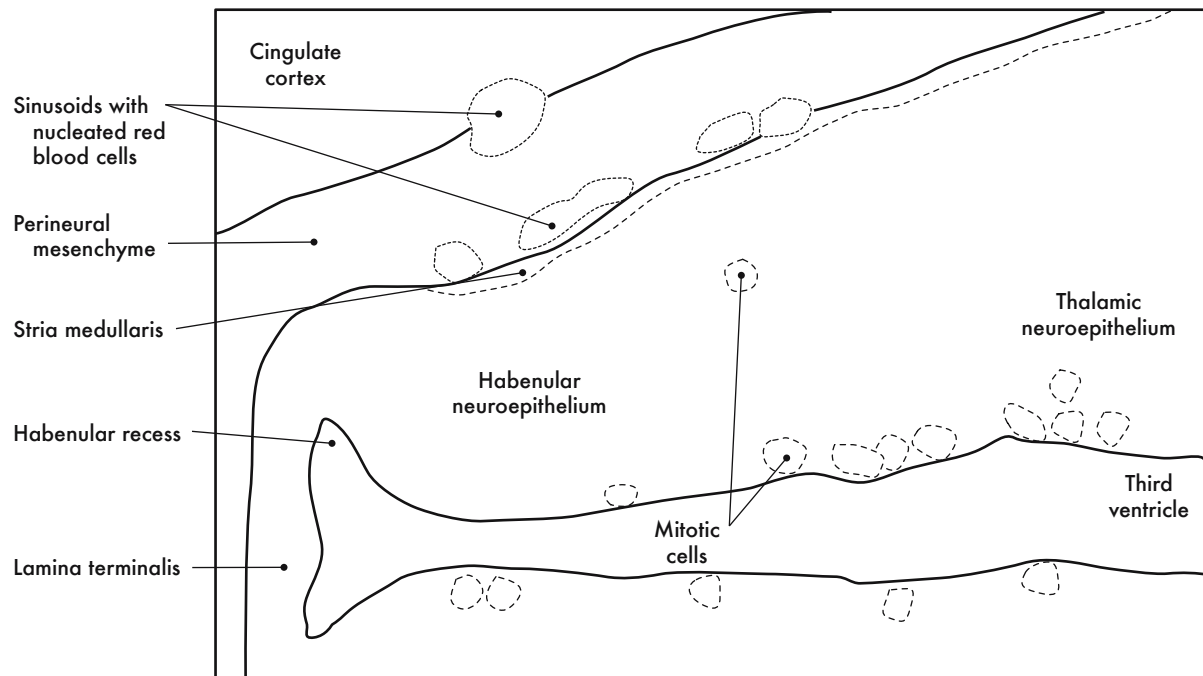




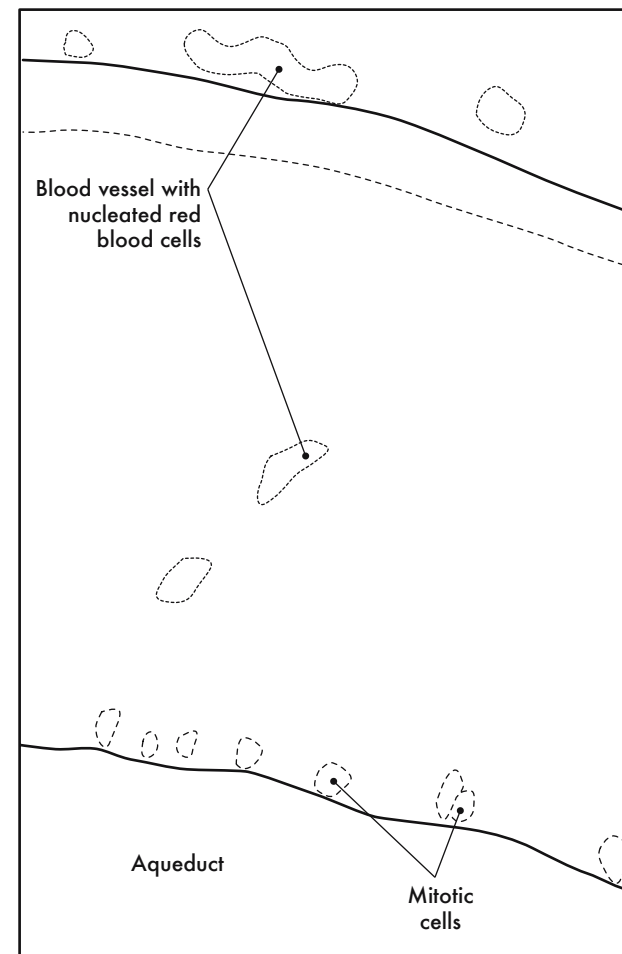
GD 12 HORIZONTAL 1



A. Cortical neuroepithelium

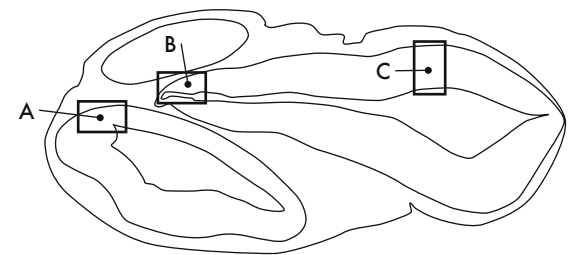
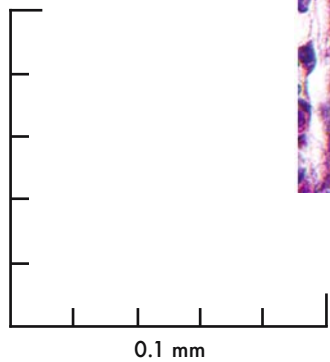
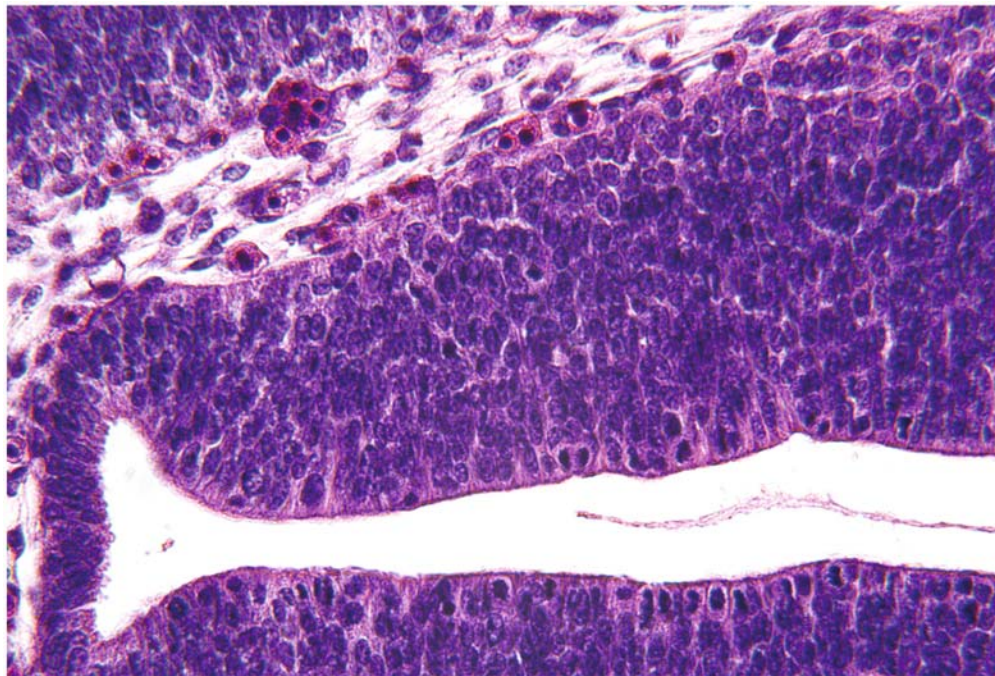
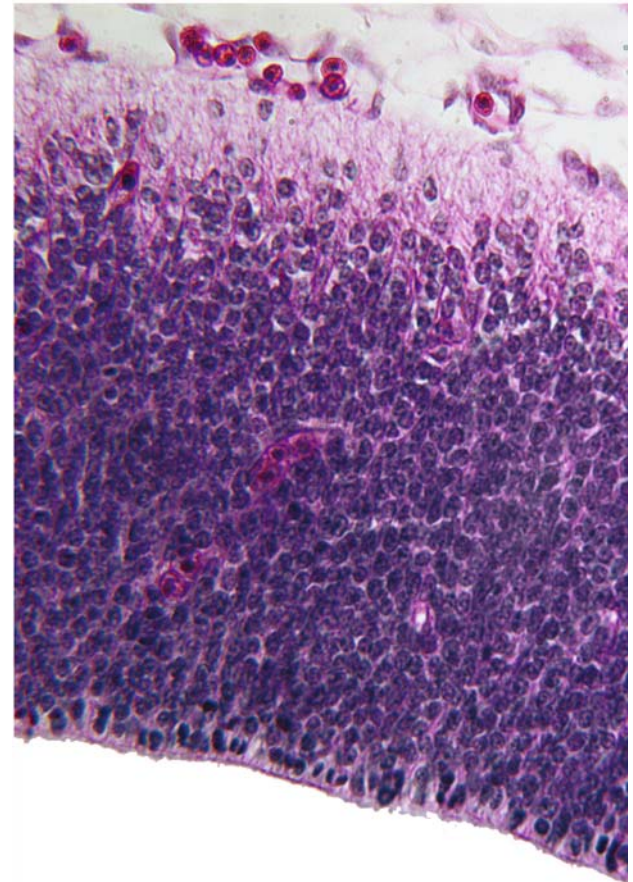
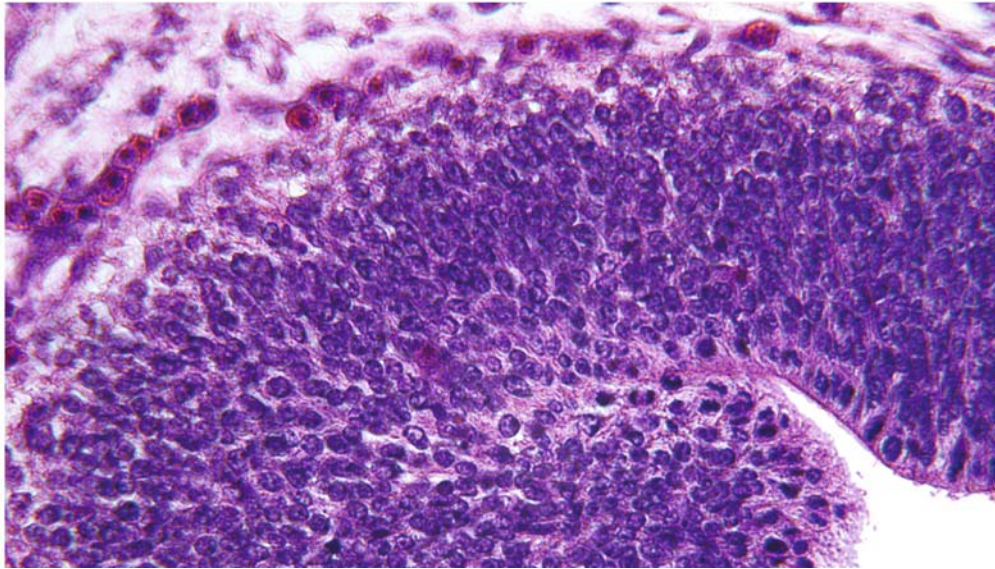


B. Epithalamic and thalamic neuroepithelium

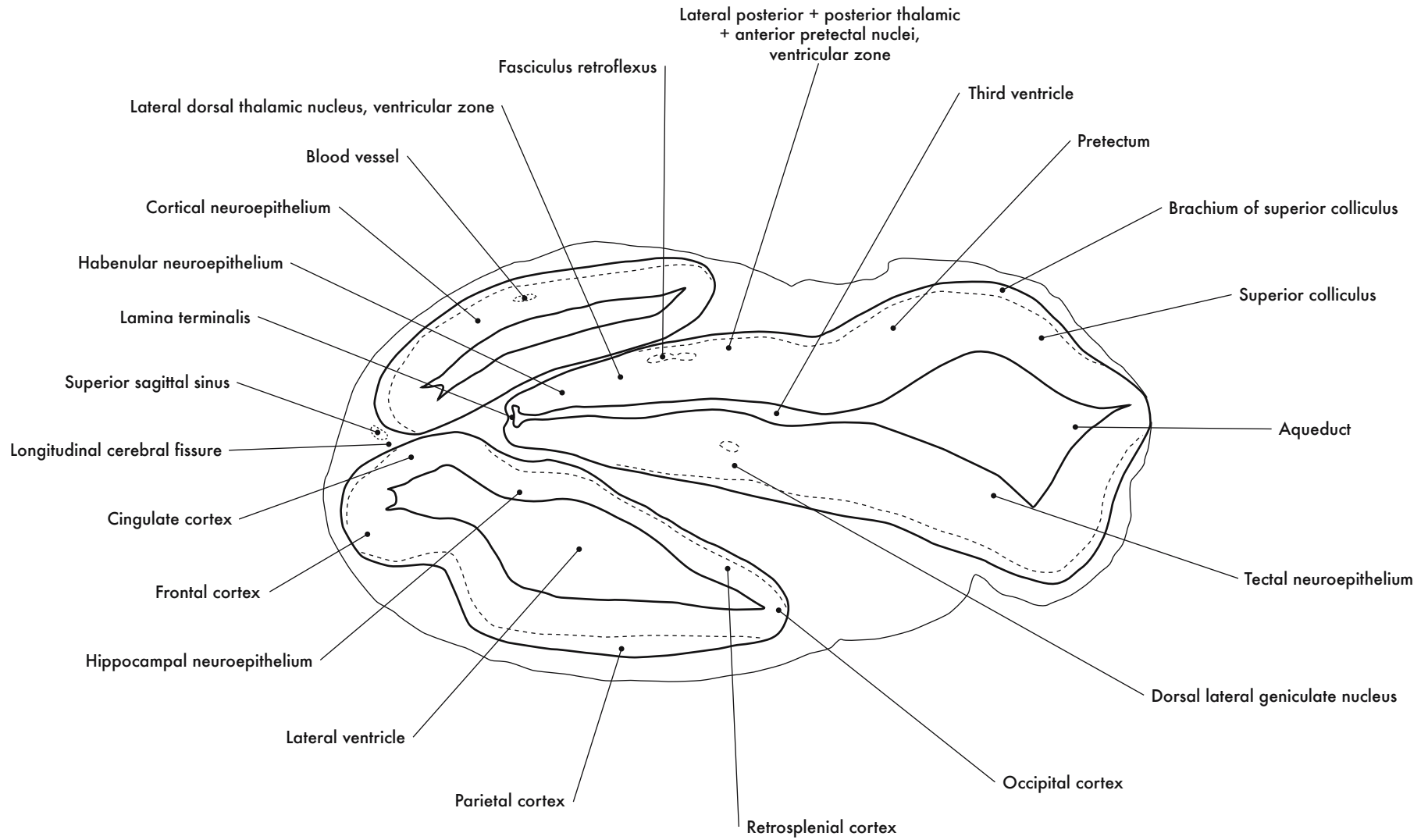


C. Tectal neuroepithelium

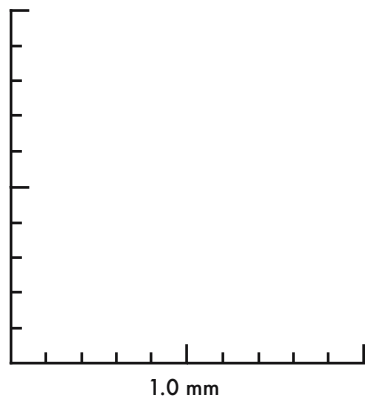
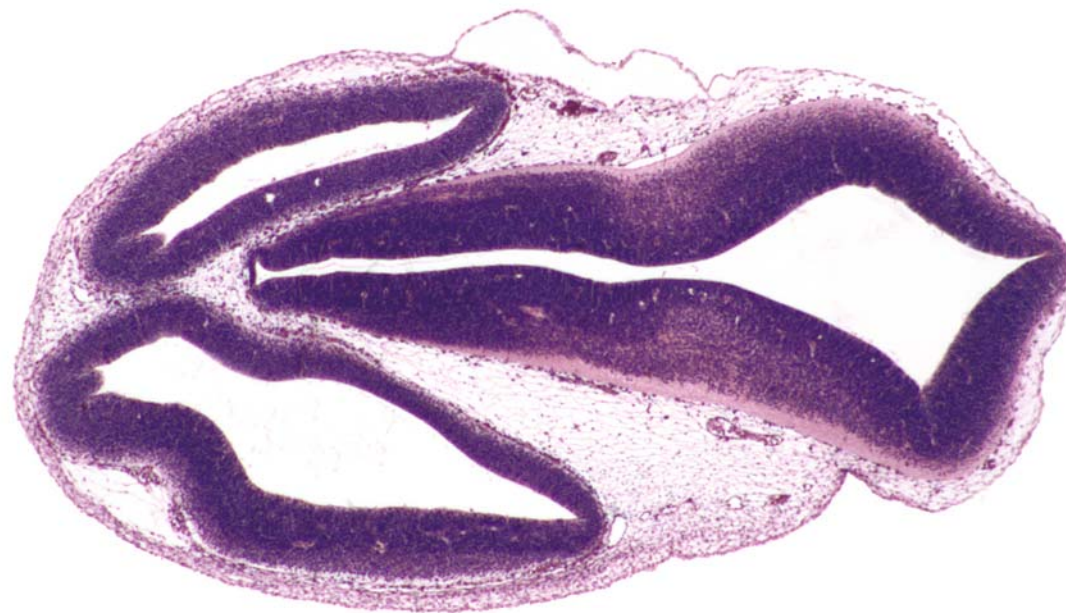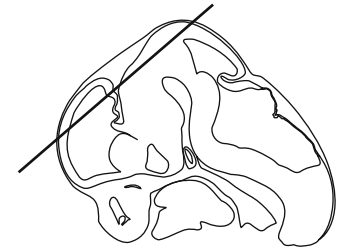




GD 12 HORIZONTAL 2

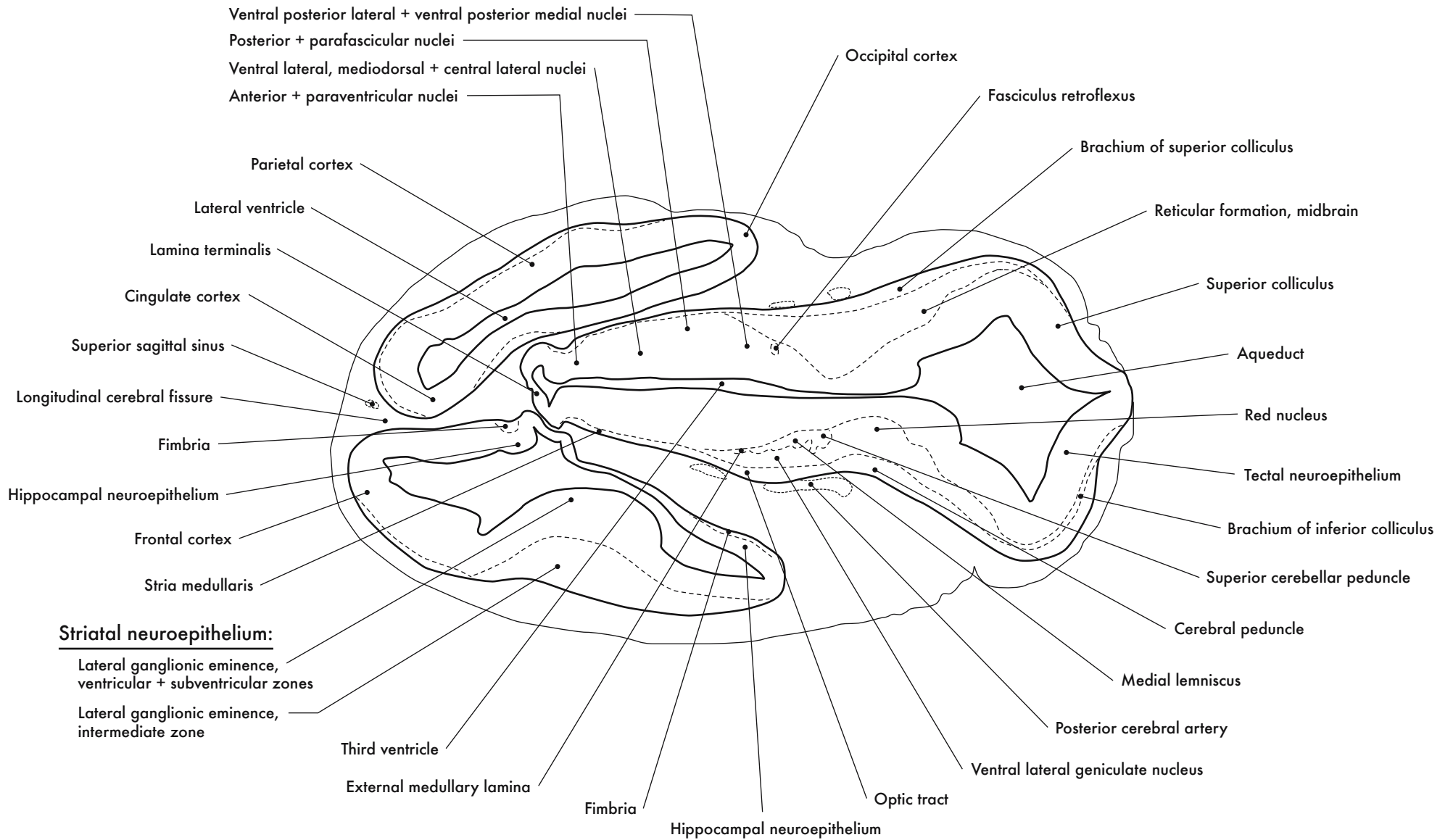


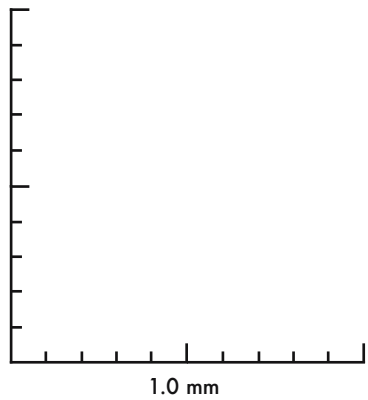
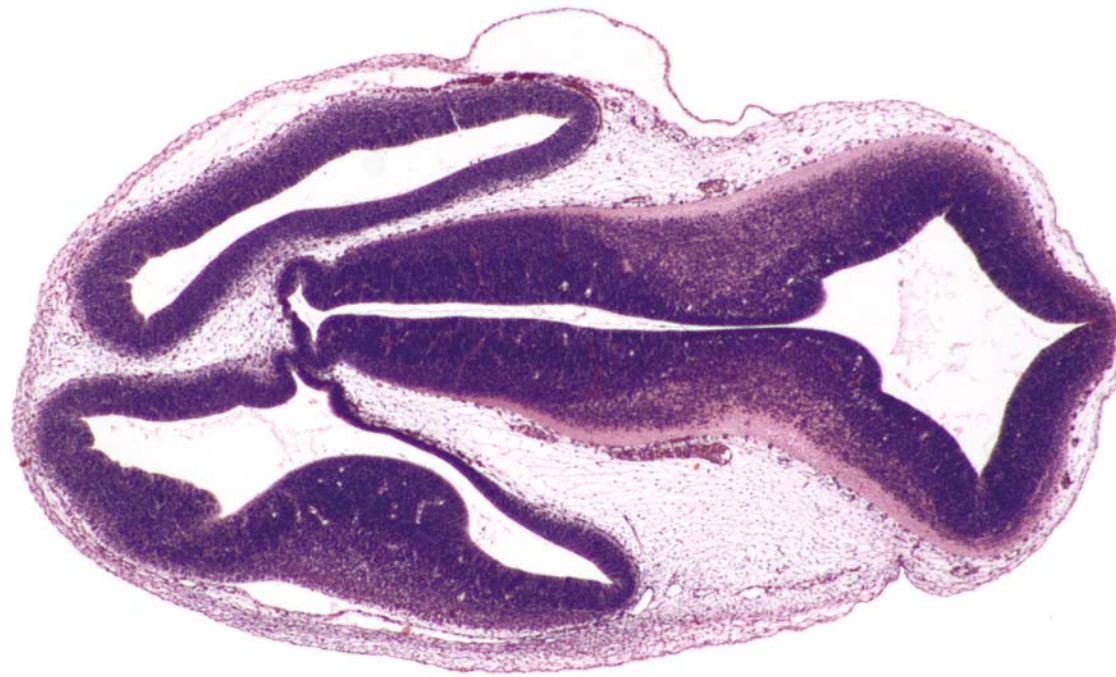
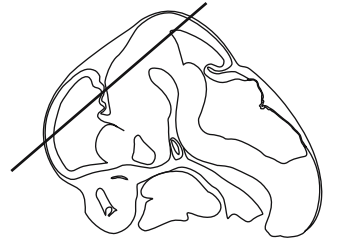


GD 12 HORIZONTAL 3

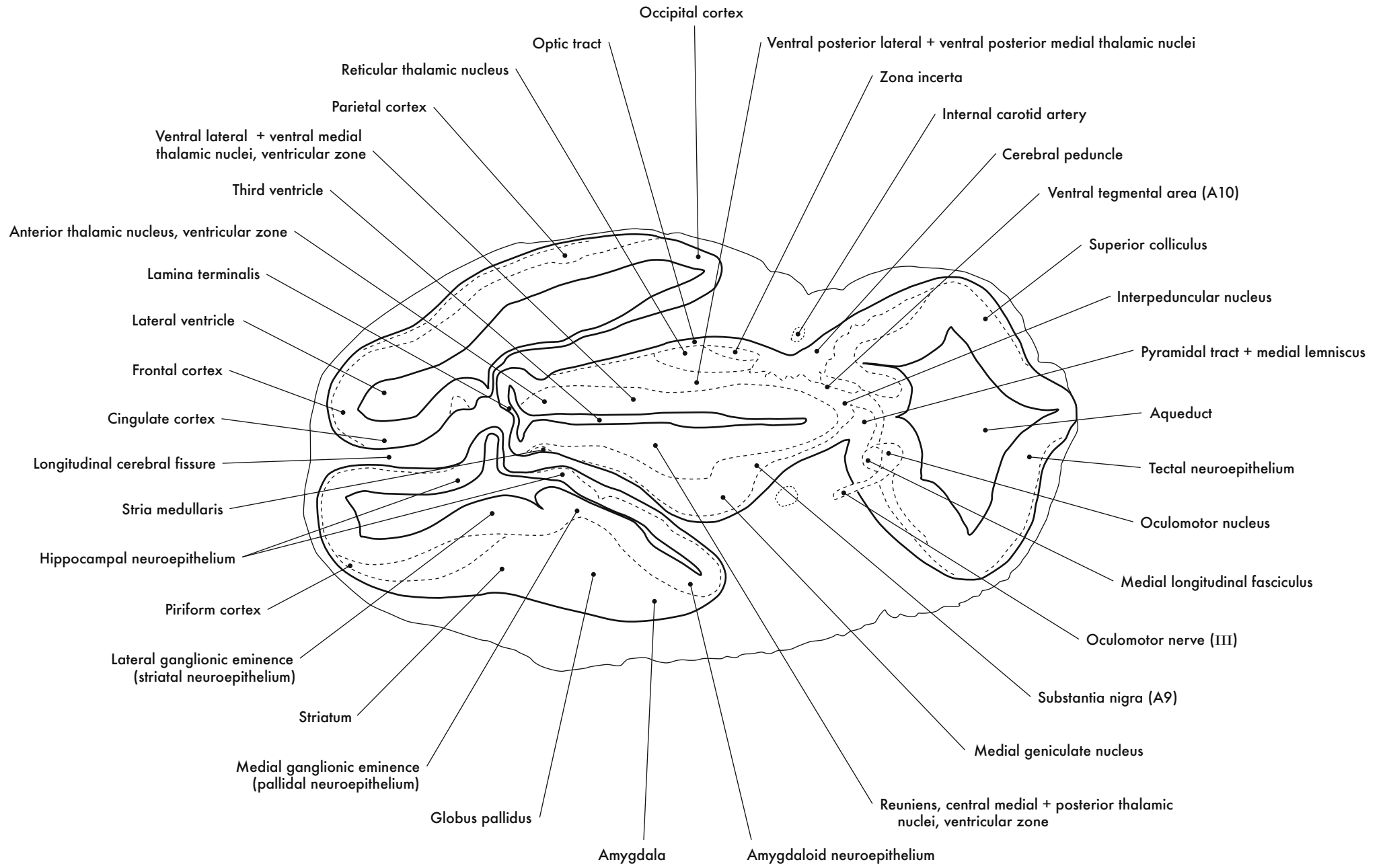
Dorsal thalamus, neuroepithelium:

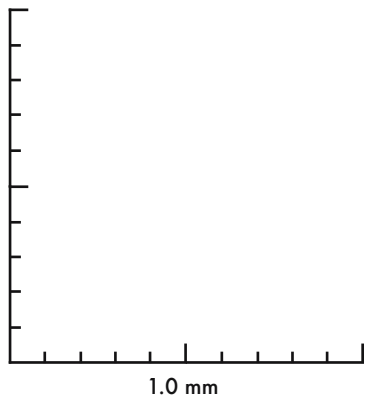
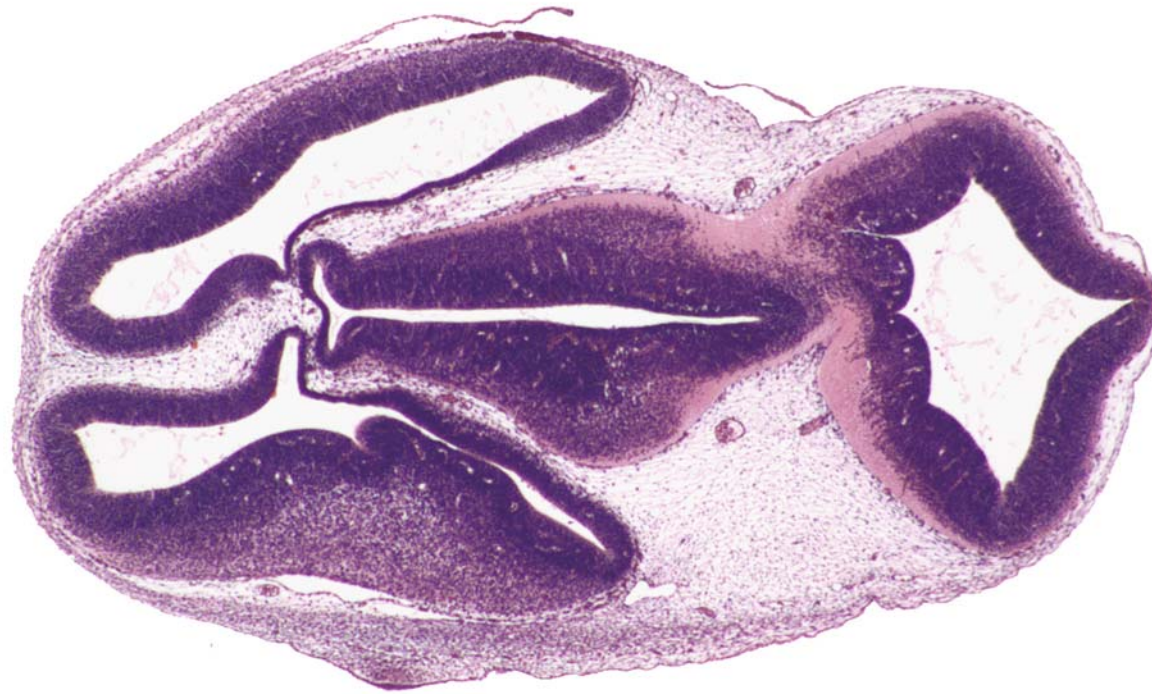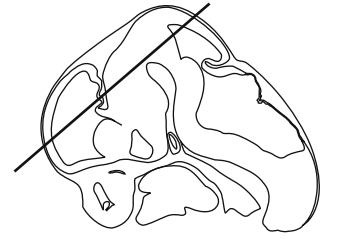




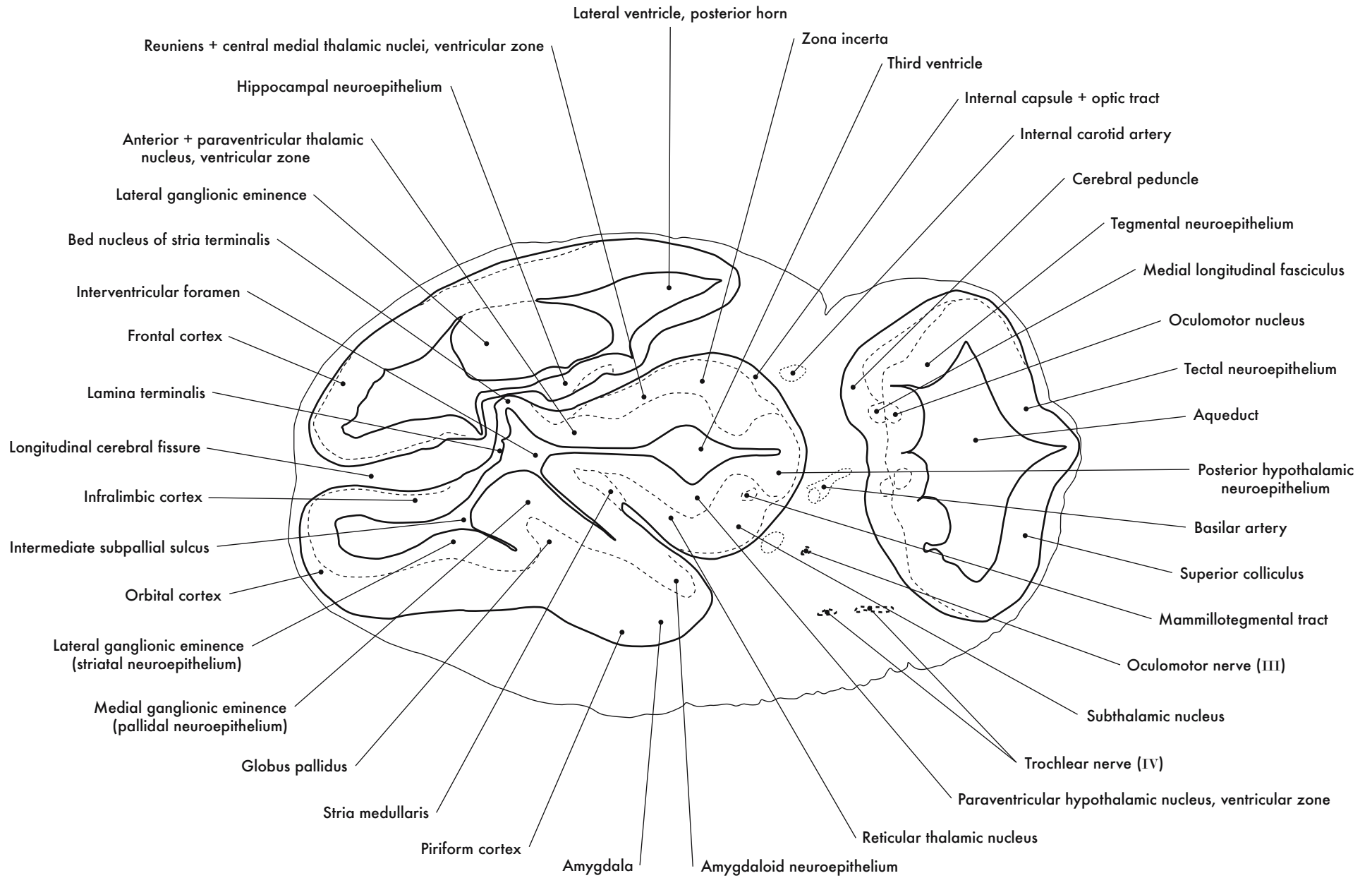
GD 12 HORIZONTAL 4

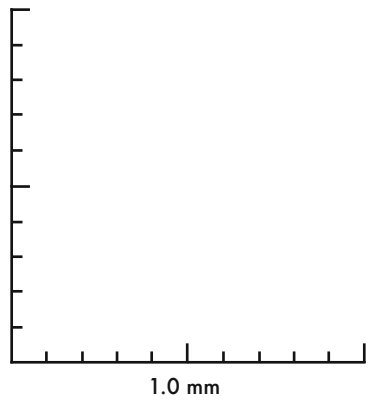
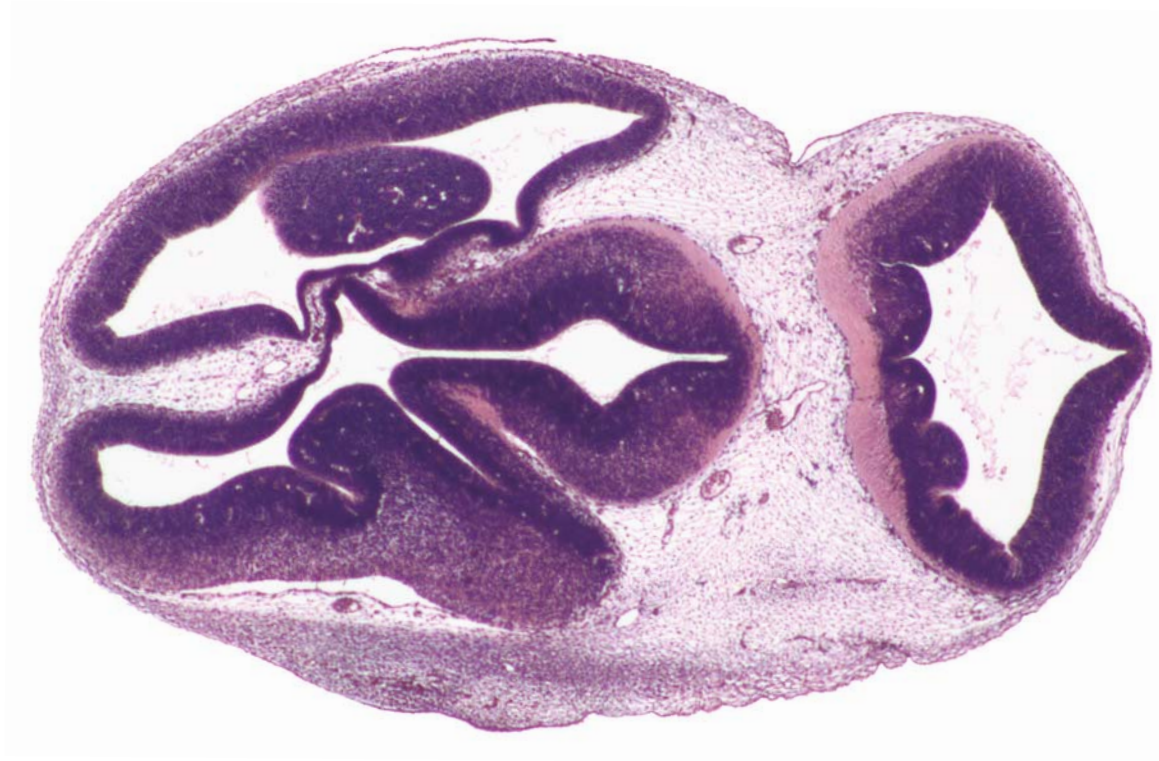
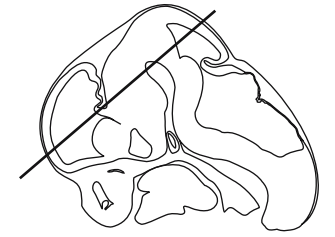


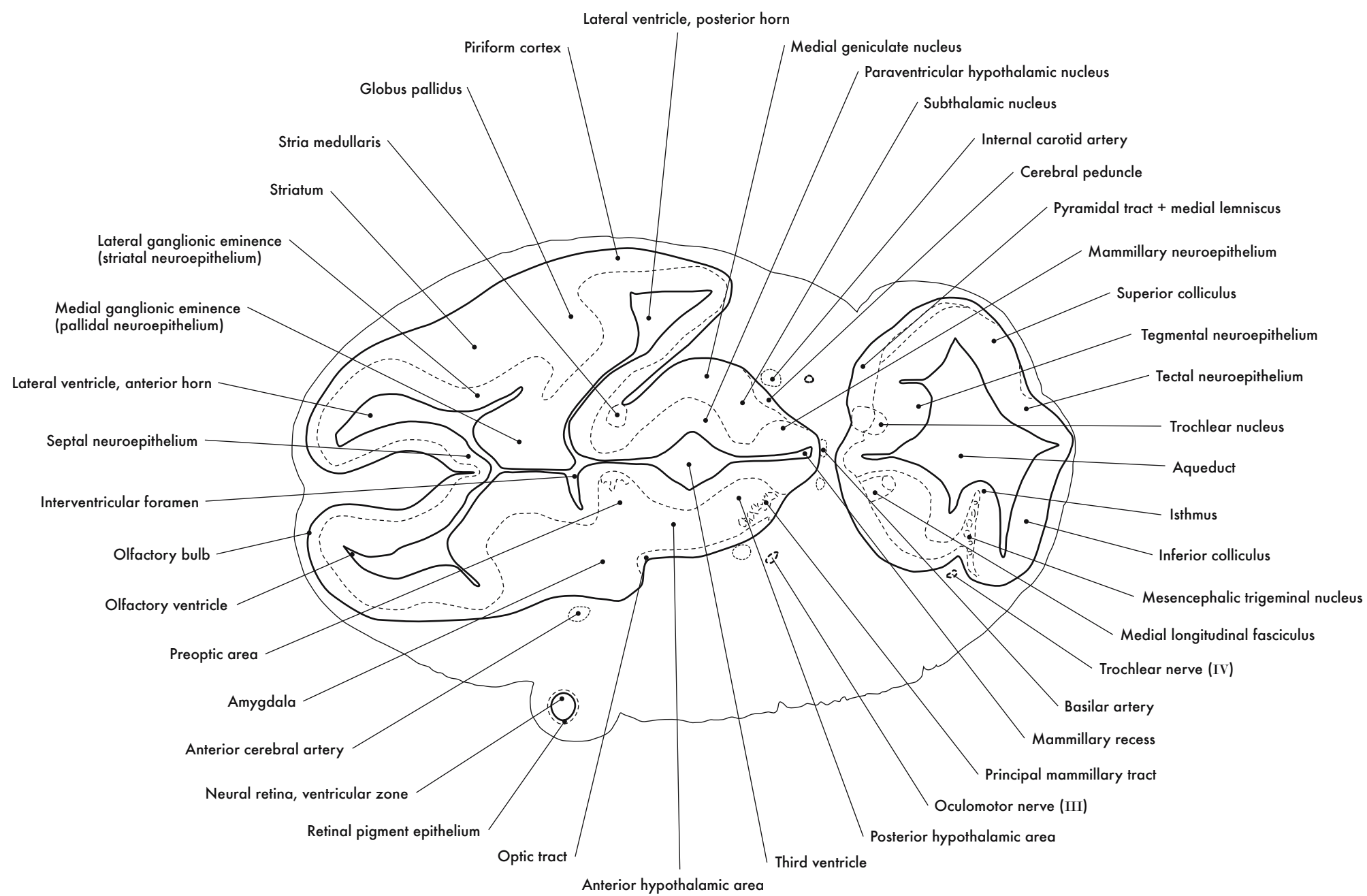


GD 12 HORIZONTAL 5

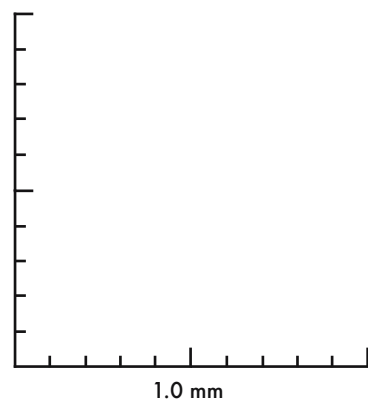
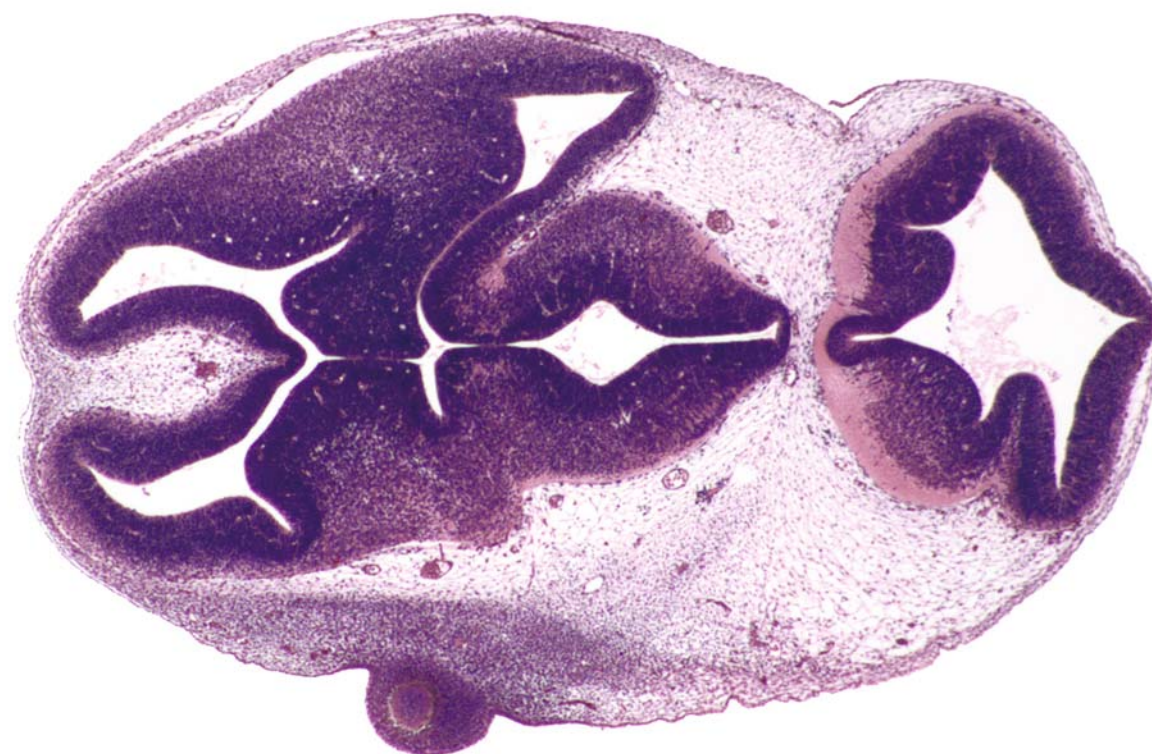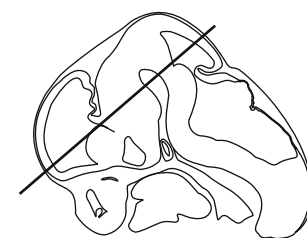




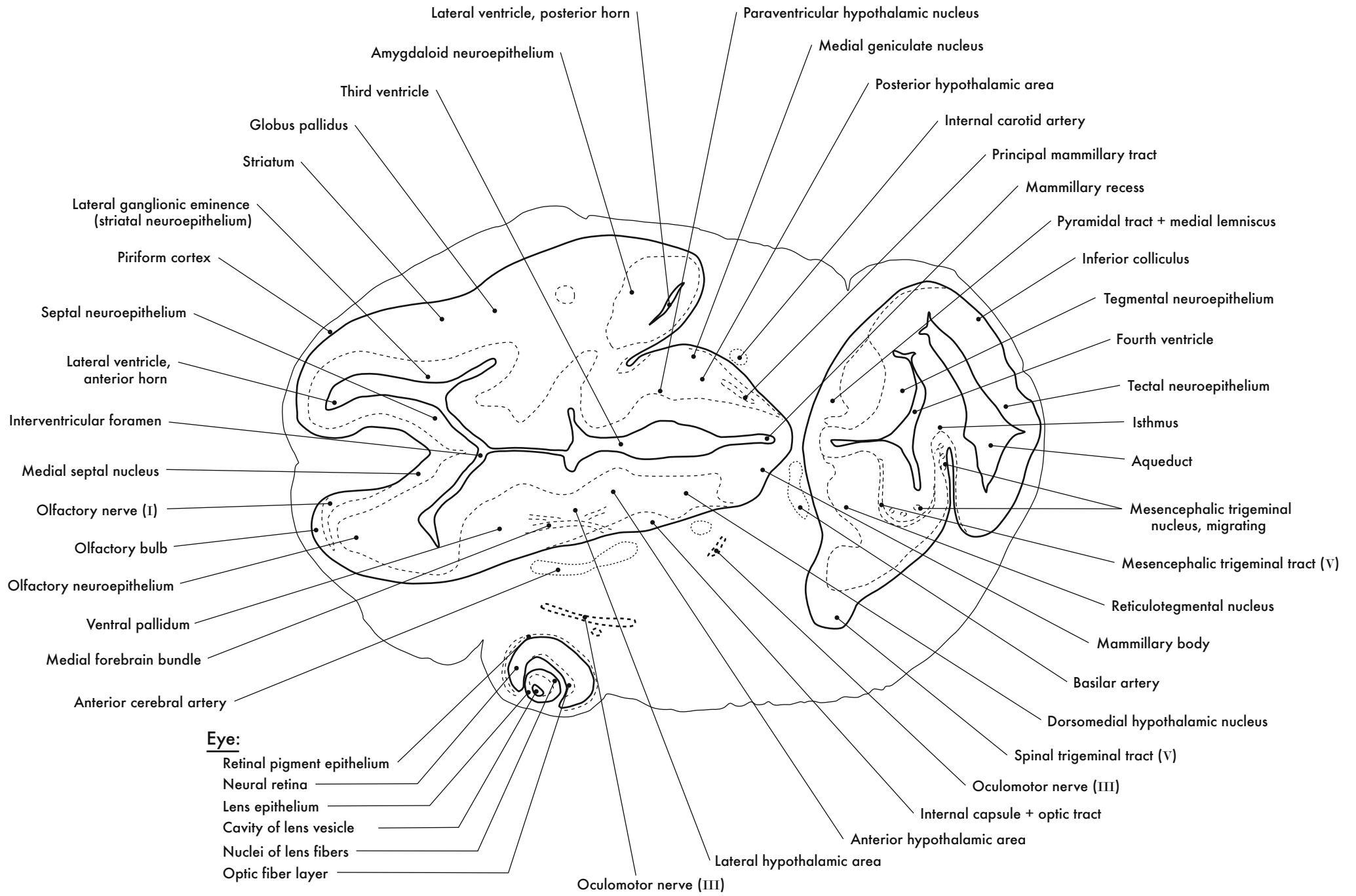
GD 12 HORIZONTAL 6

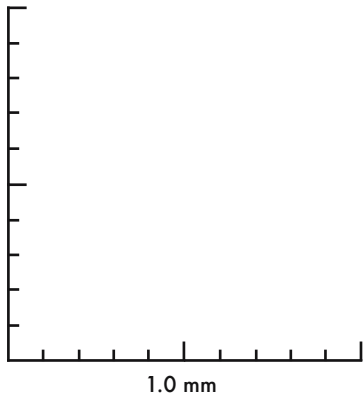
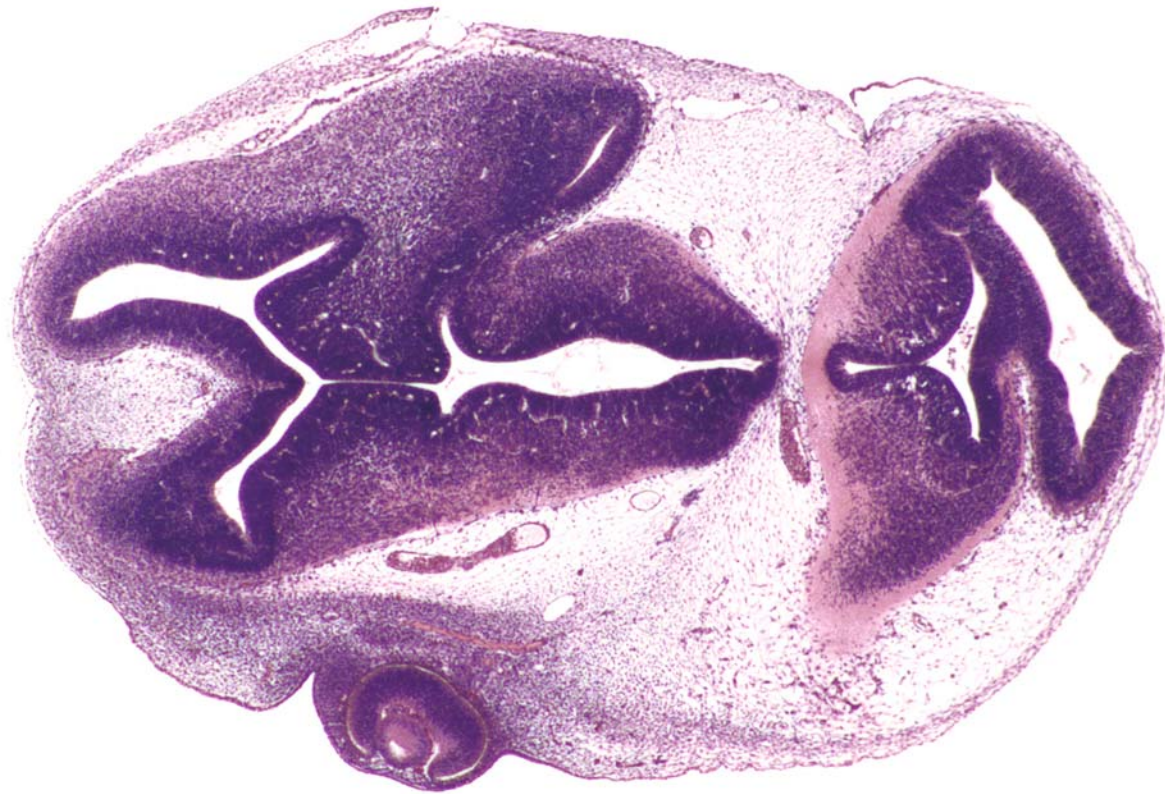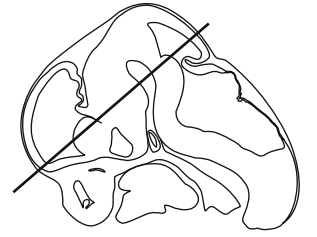




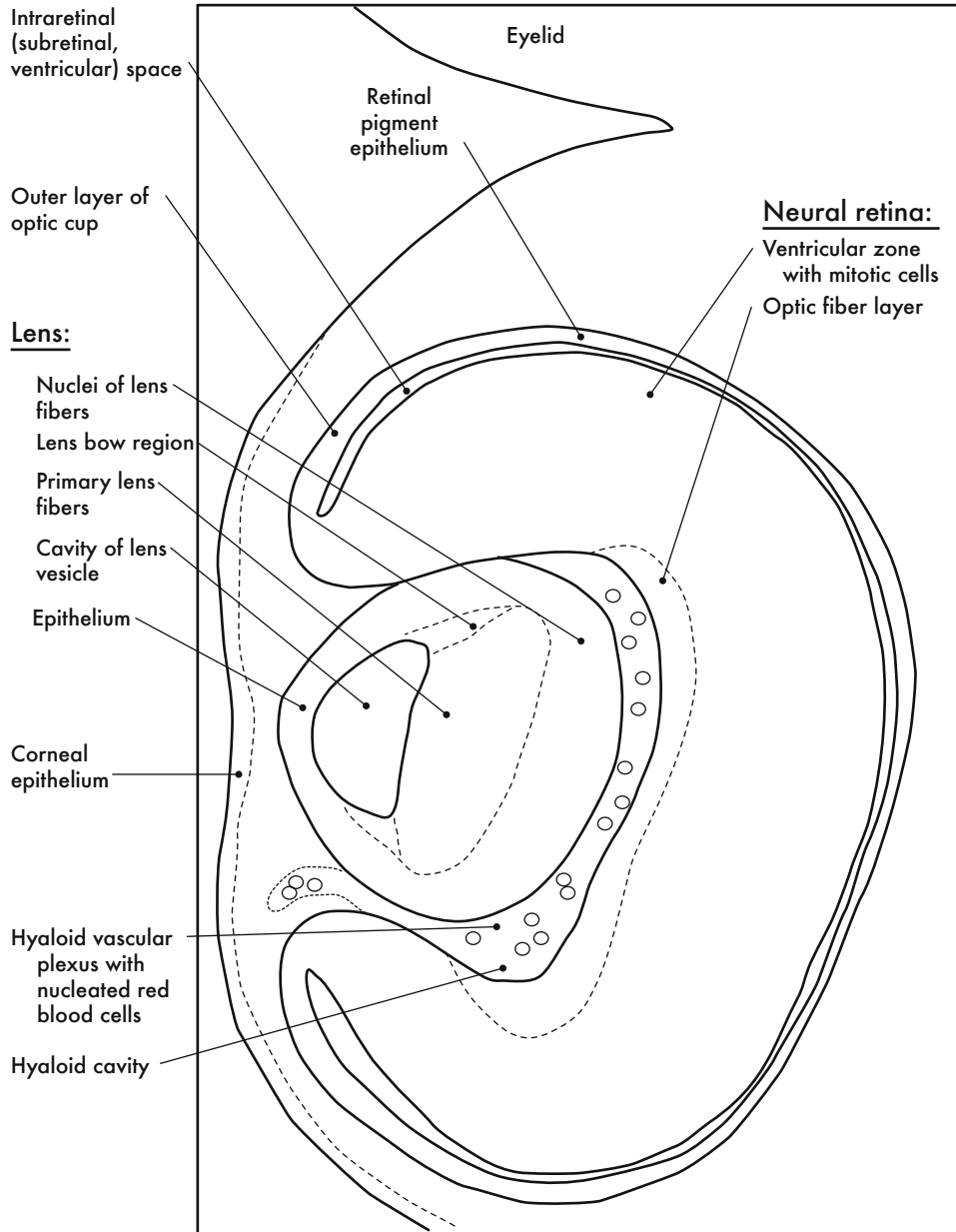


GD 12 HORIZONTAL 7

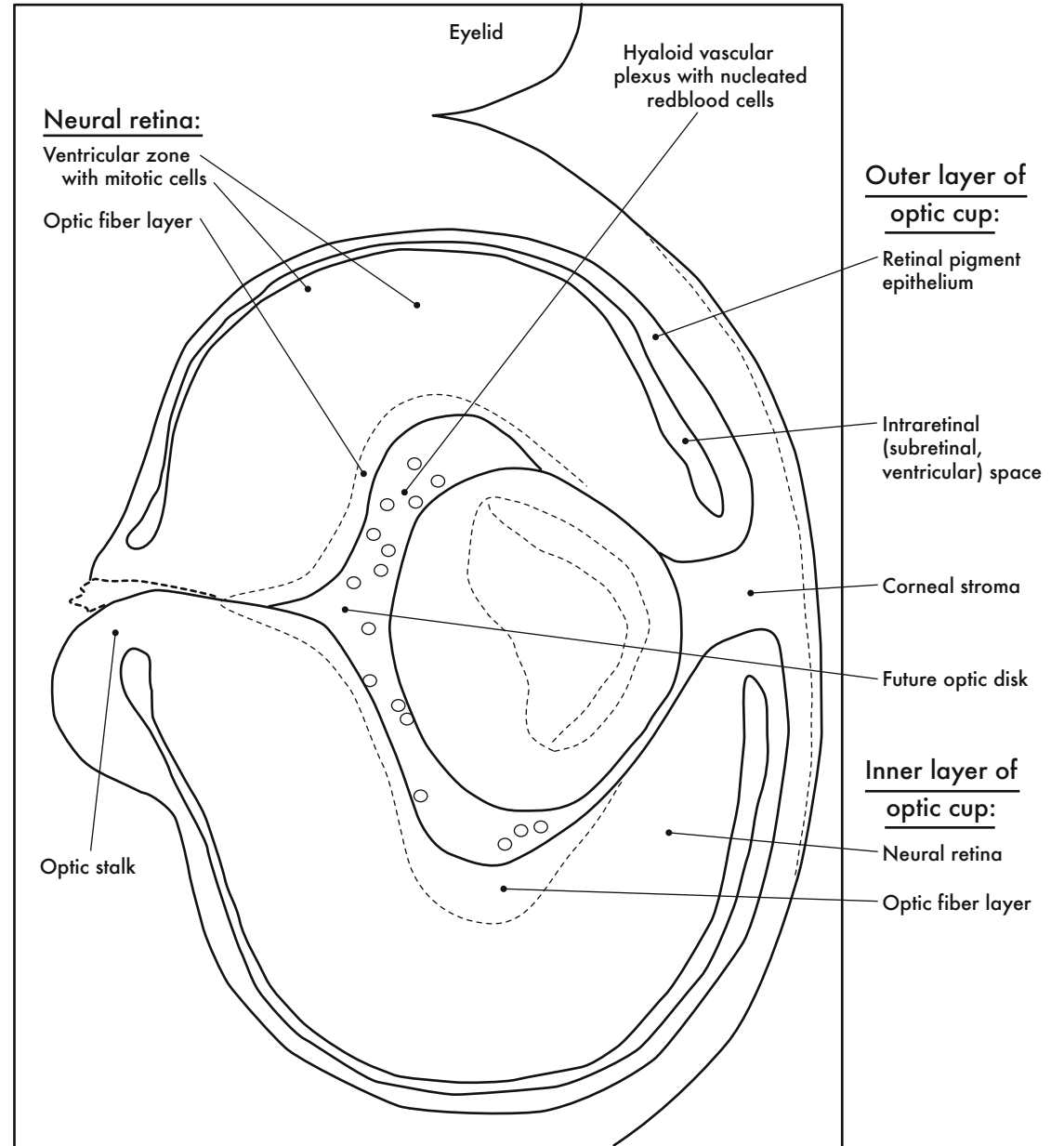




GD 12 HORIZONTAL 8

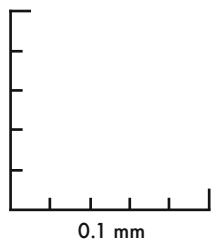
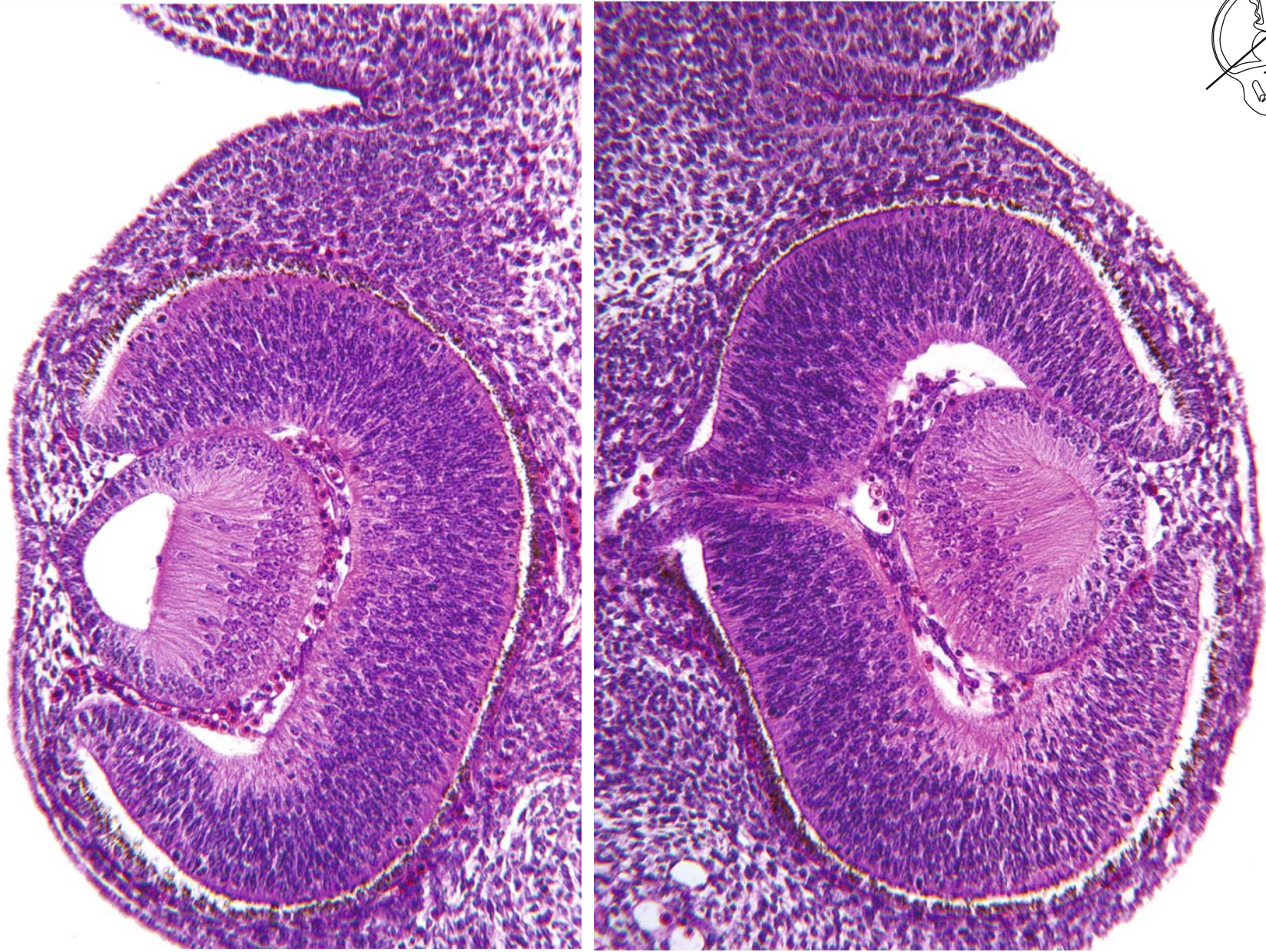
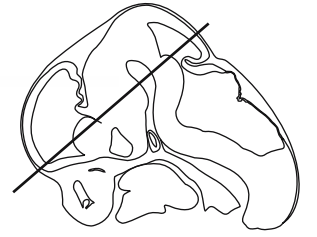


A. Left Eye



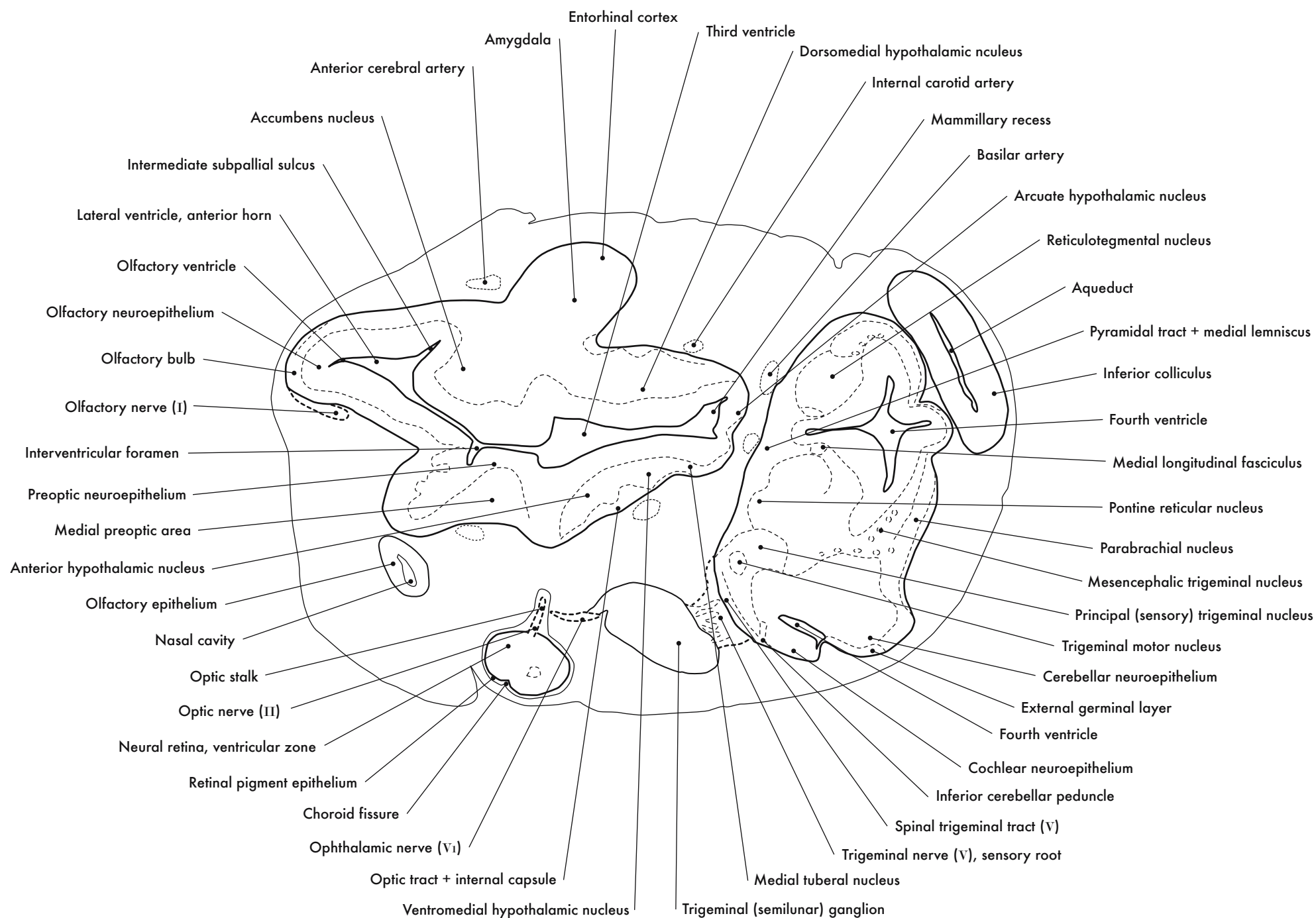
B. Right Eye

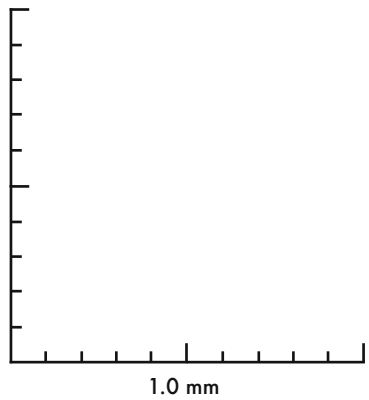
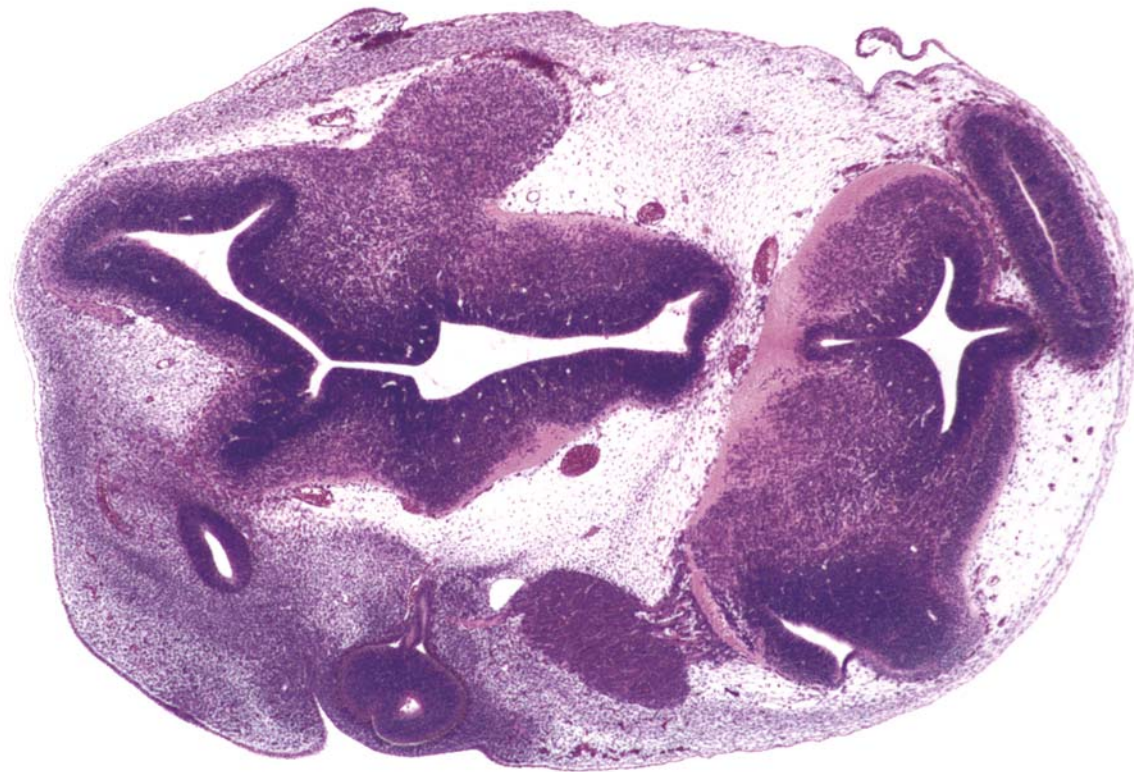
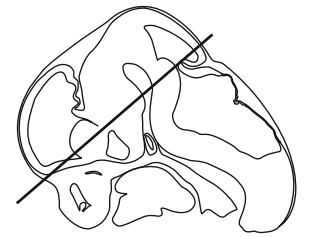




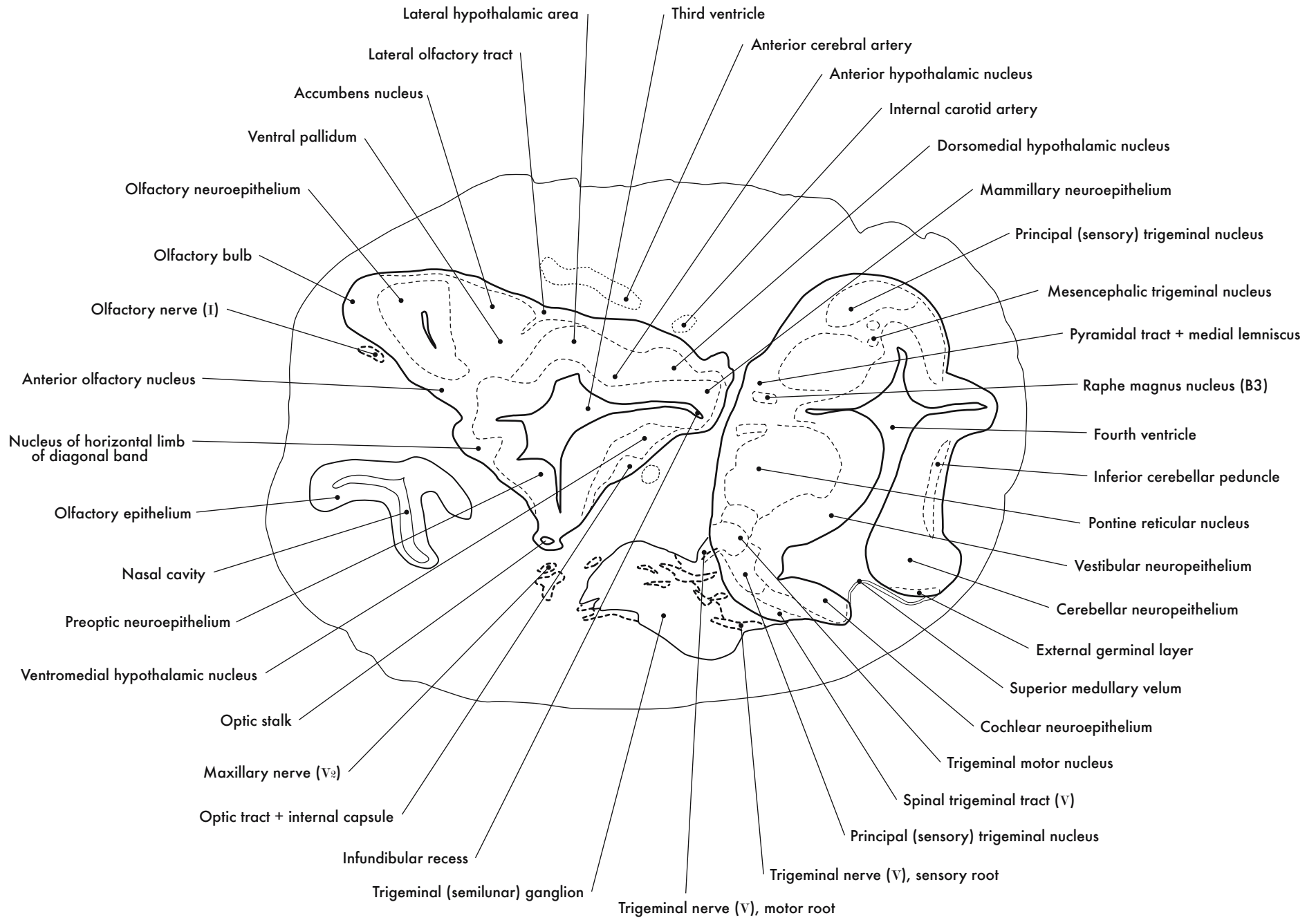
GD 12 HORIZONTAL 9

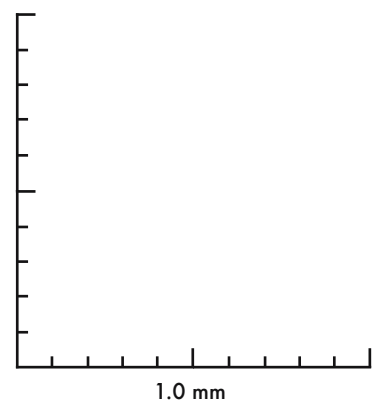
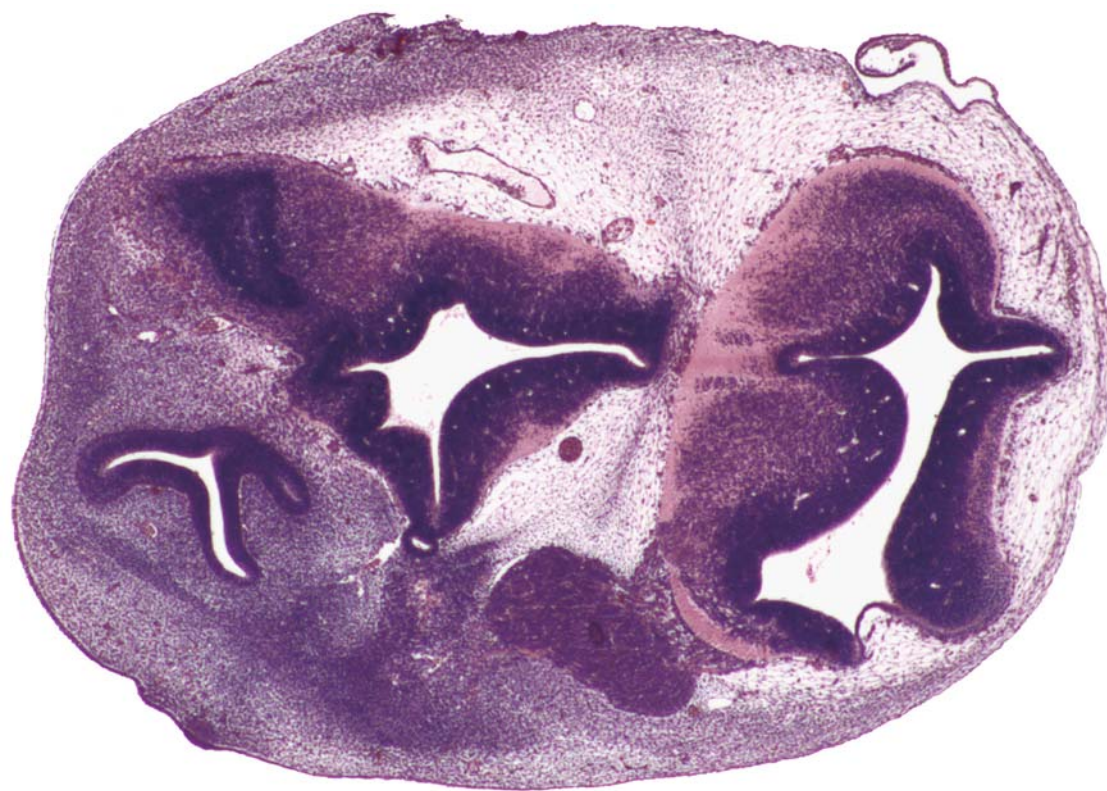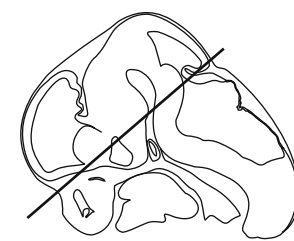






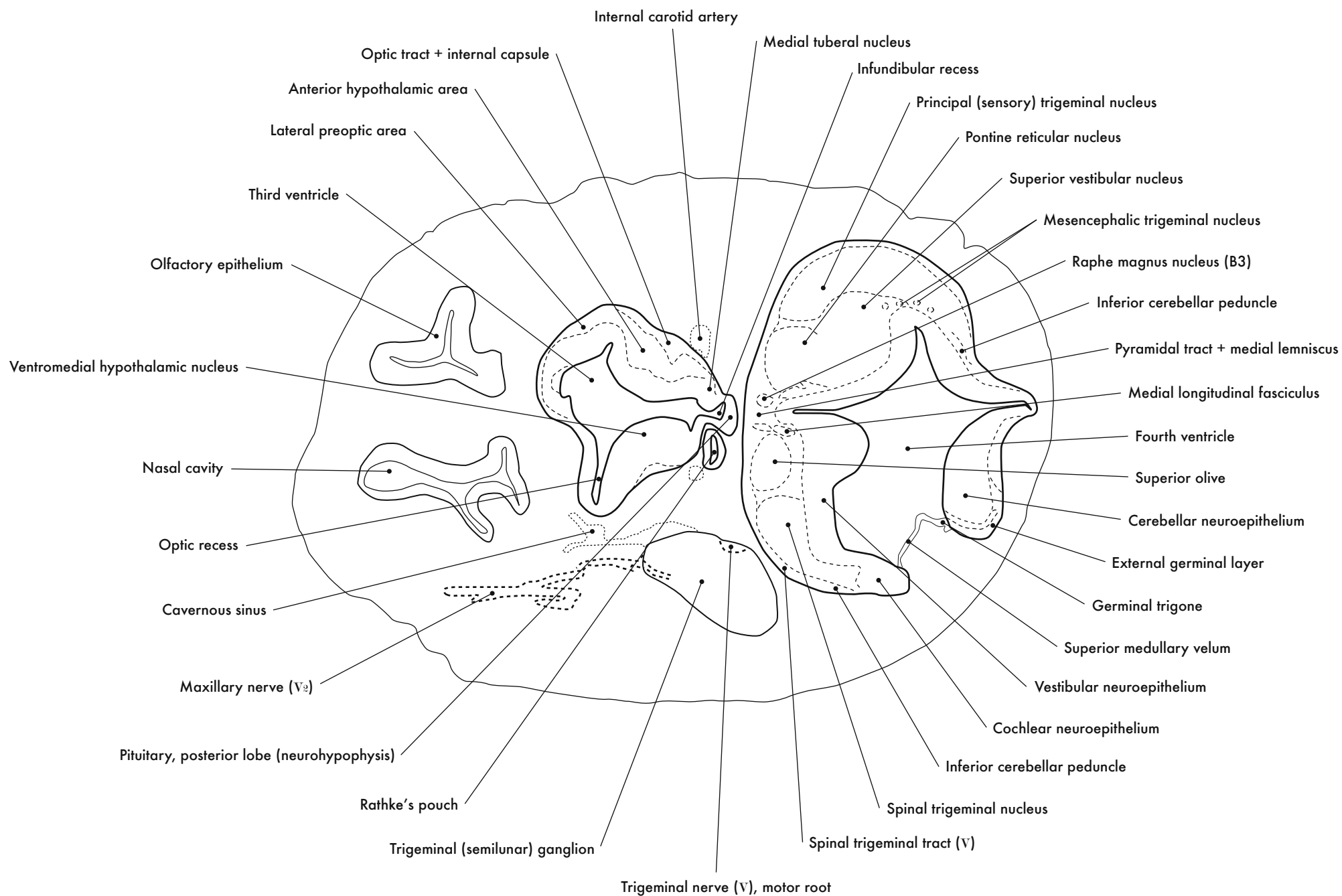
GD 12 HORIZONTAL 10



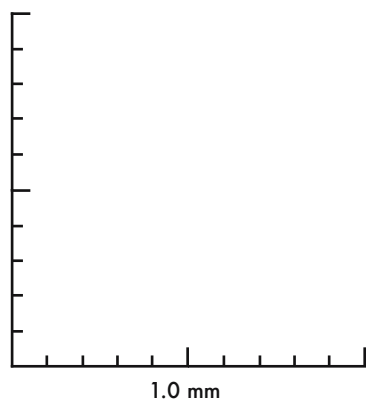
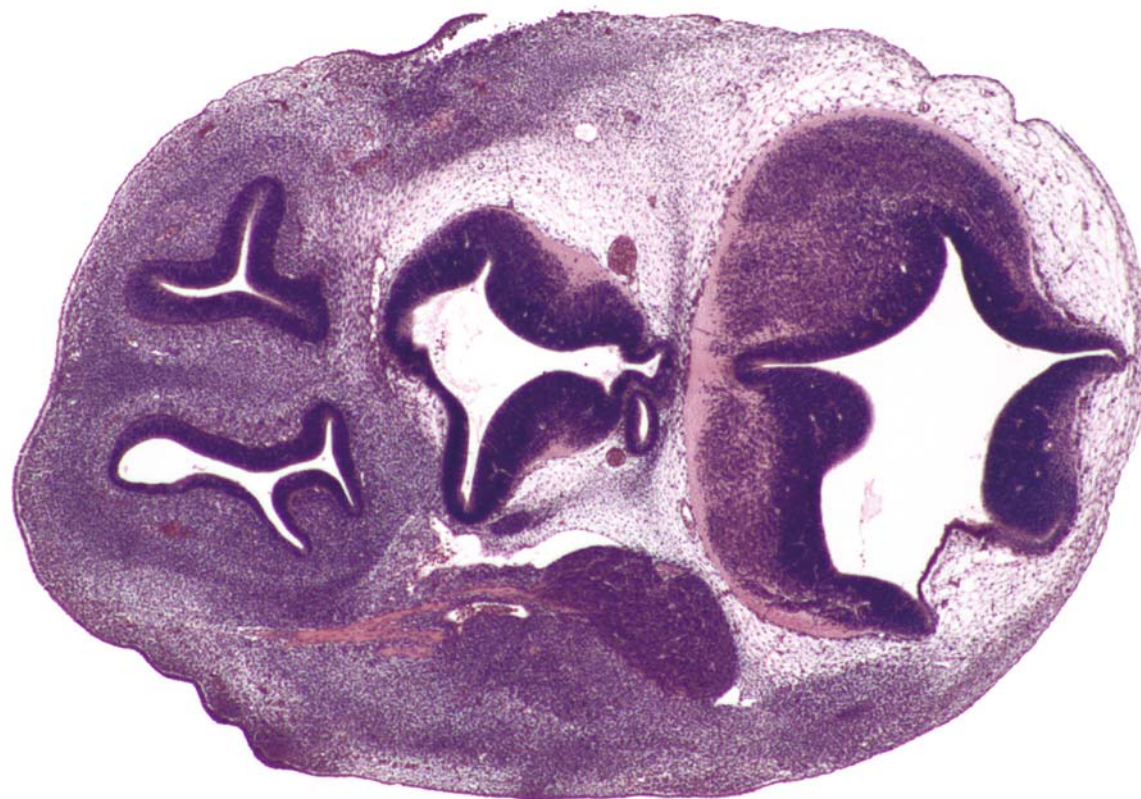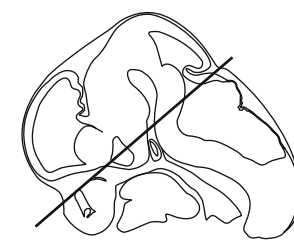


GD 12 HORIZONTAL 11

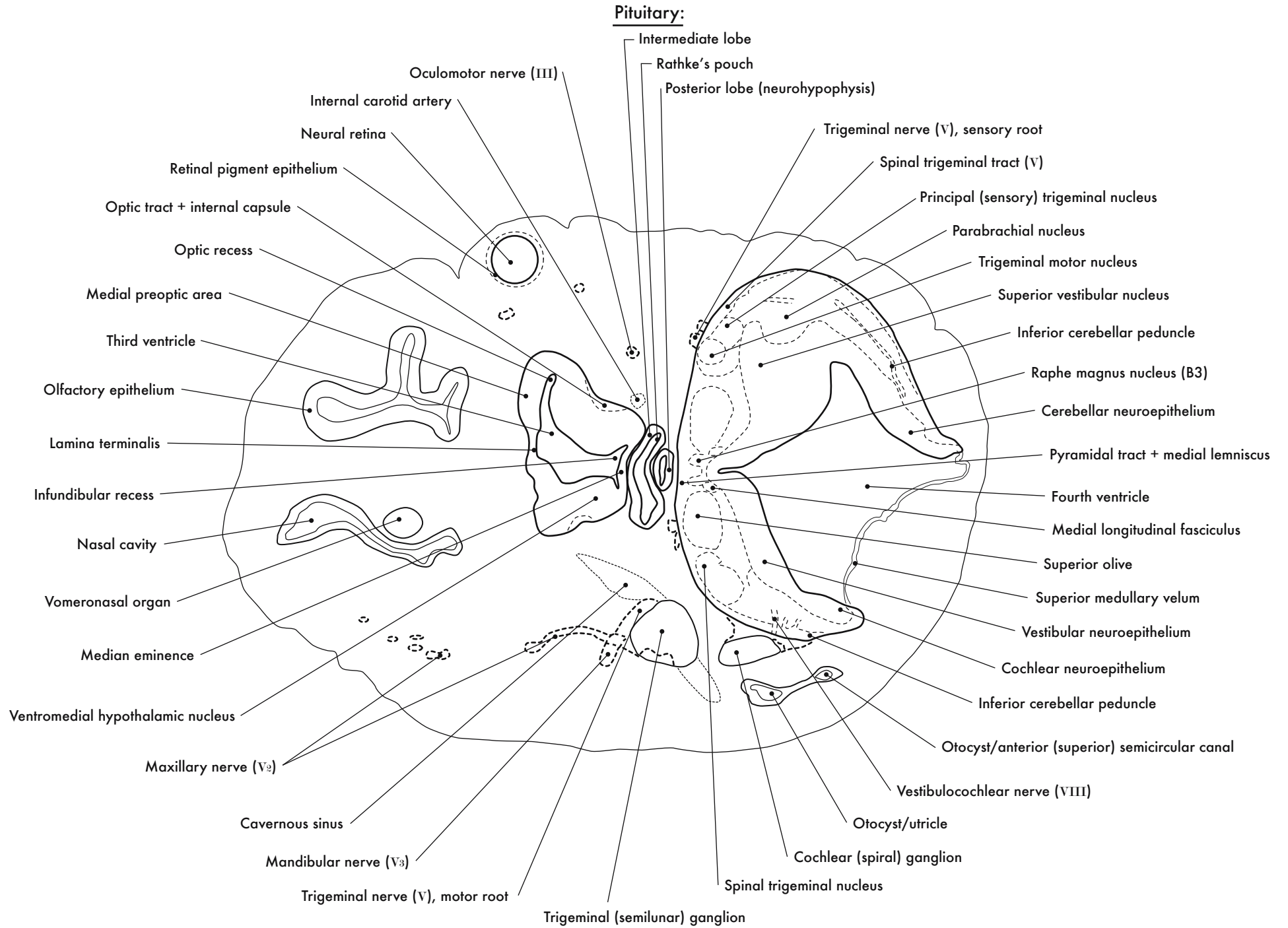


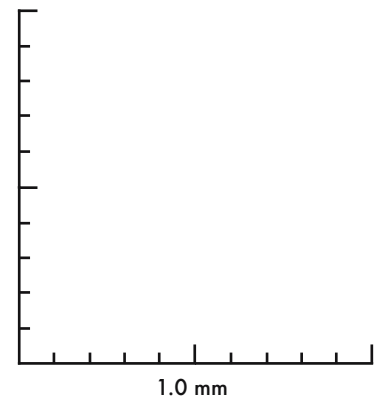
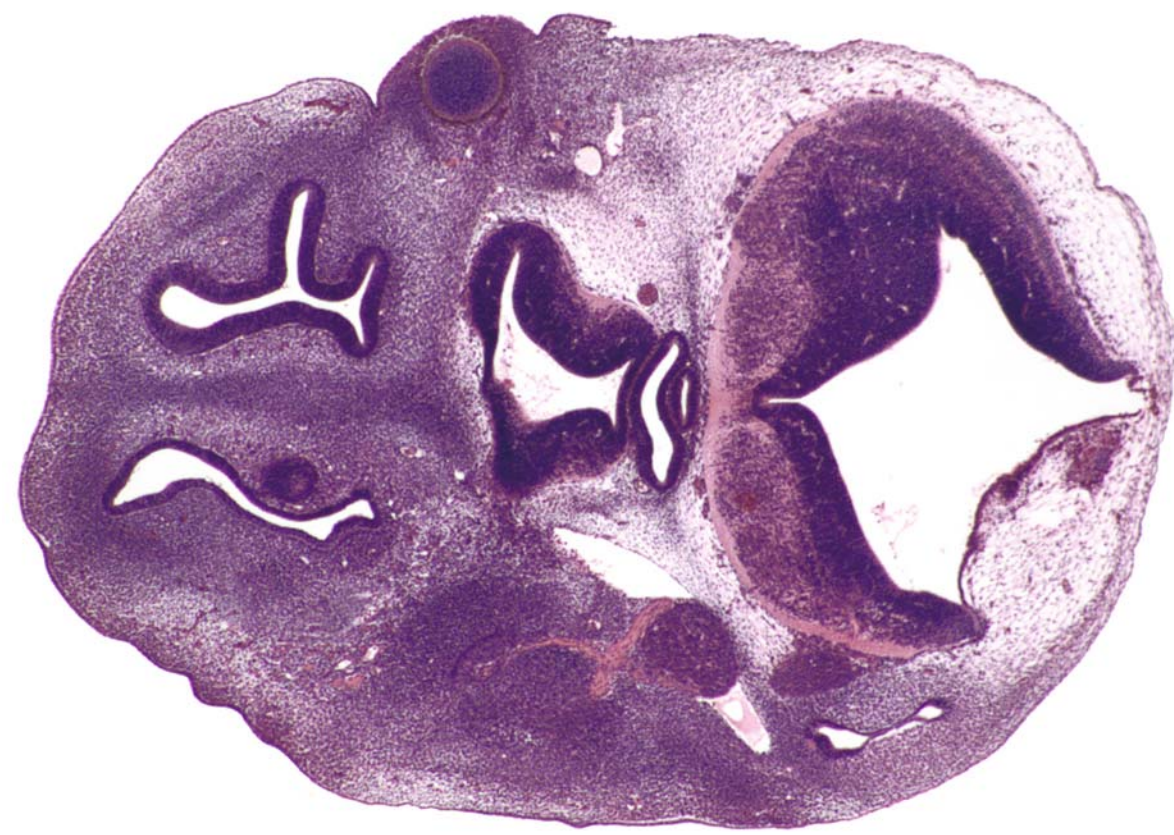
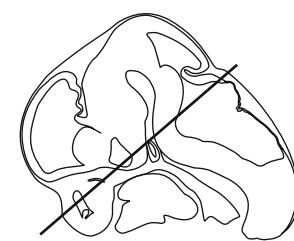




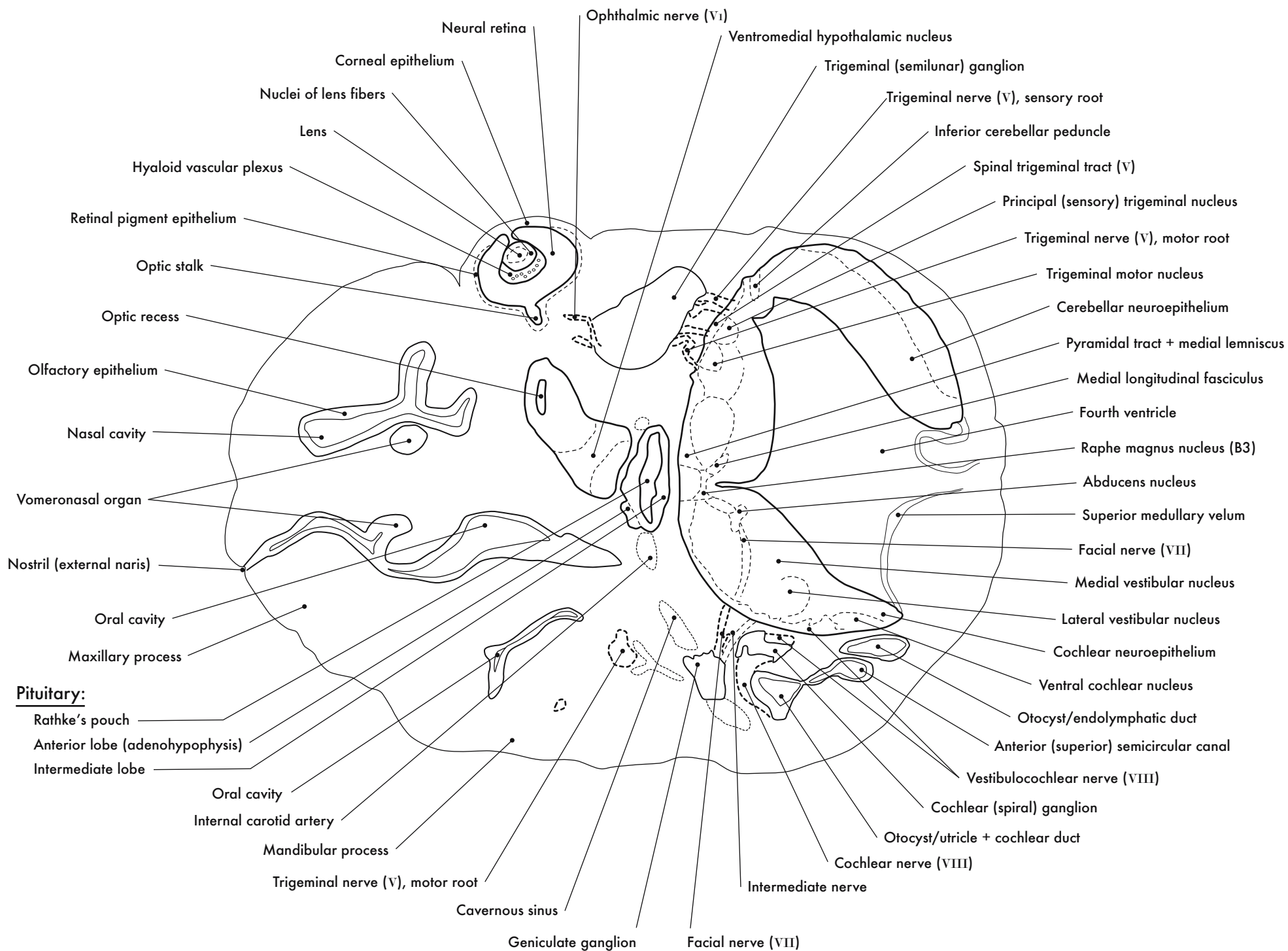


GD 12 HORIZONTAL 12

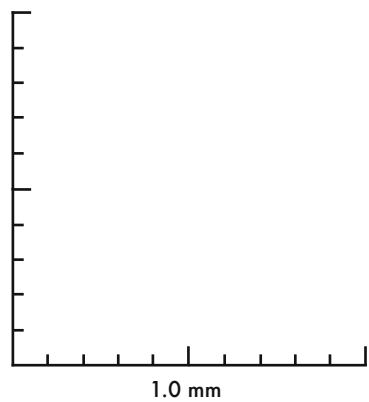
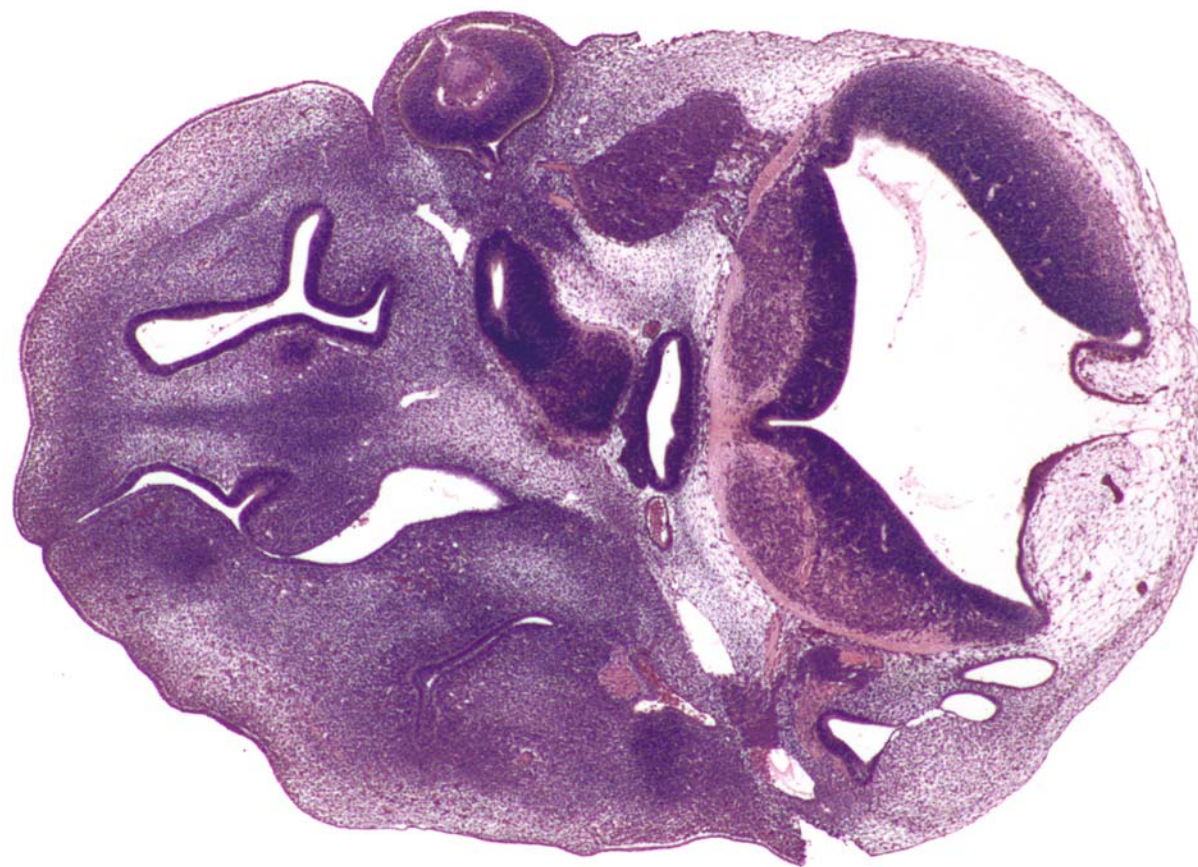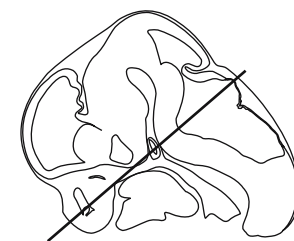




GD 12 HORIZONTAL 13

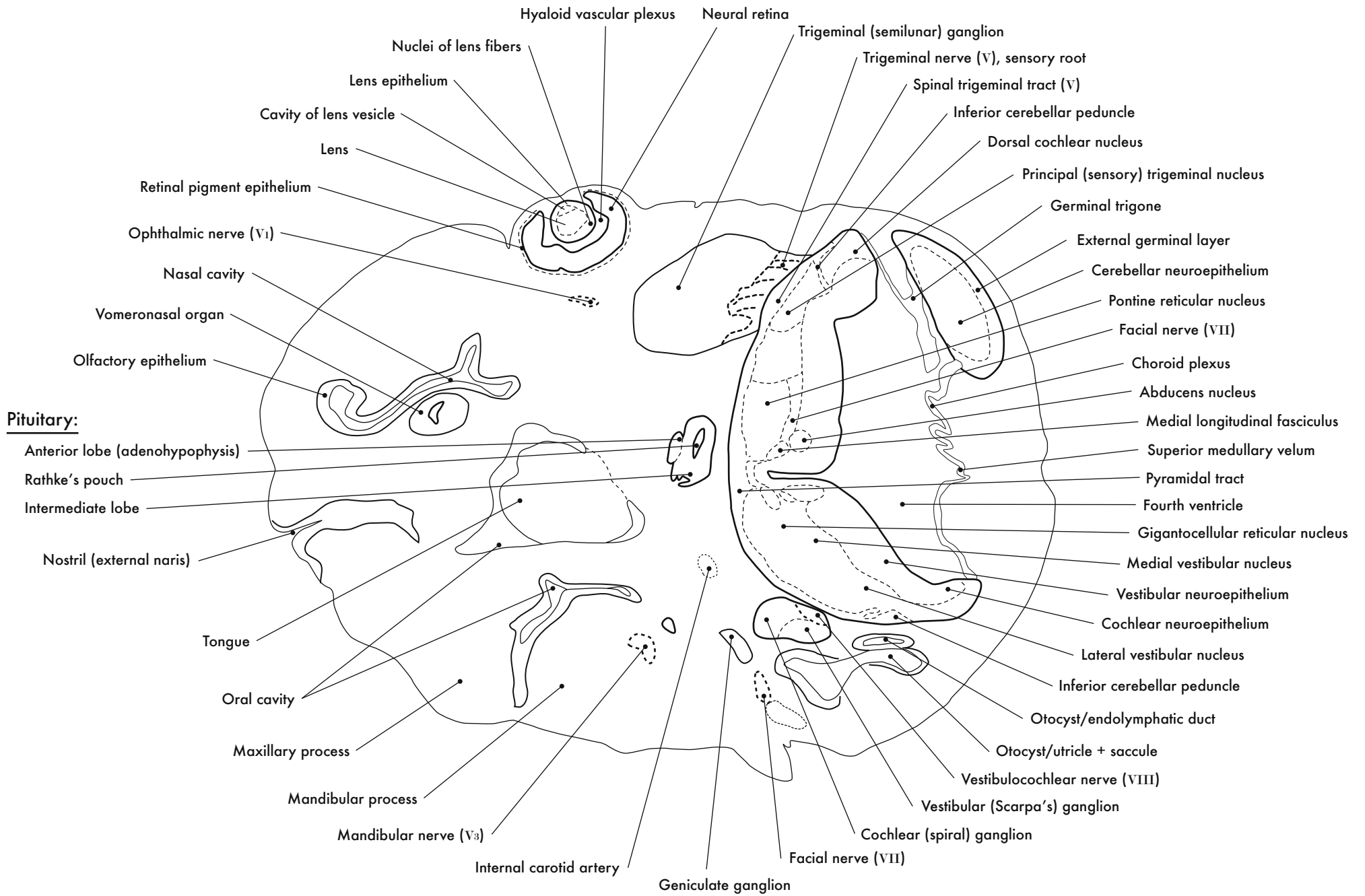


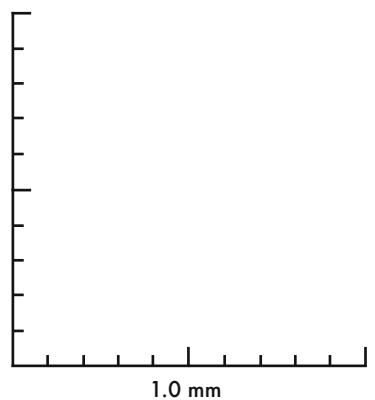
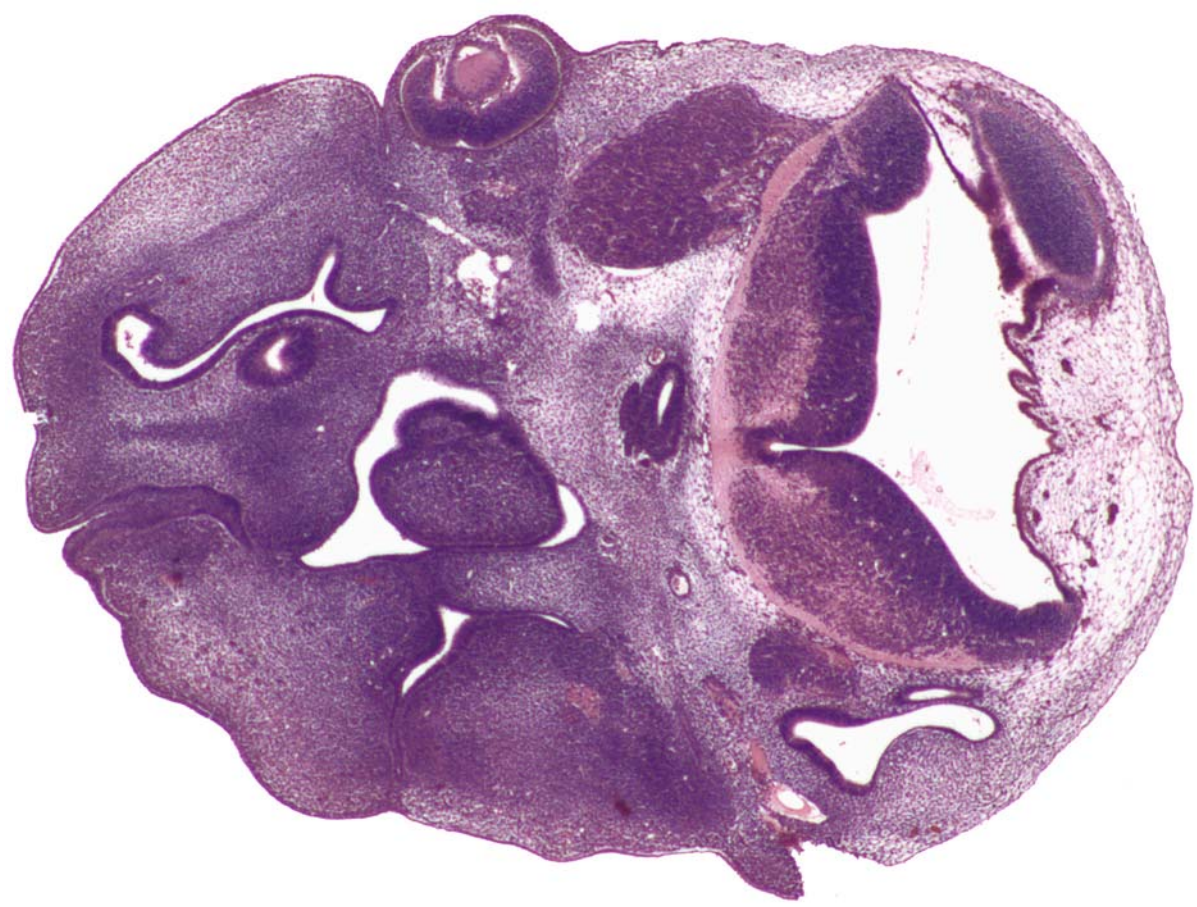
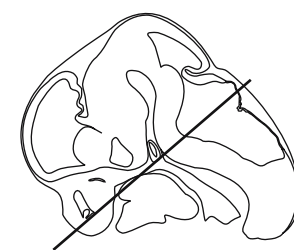



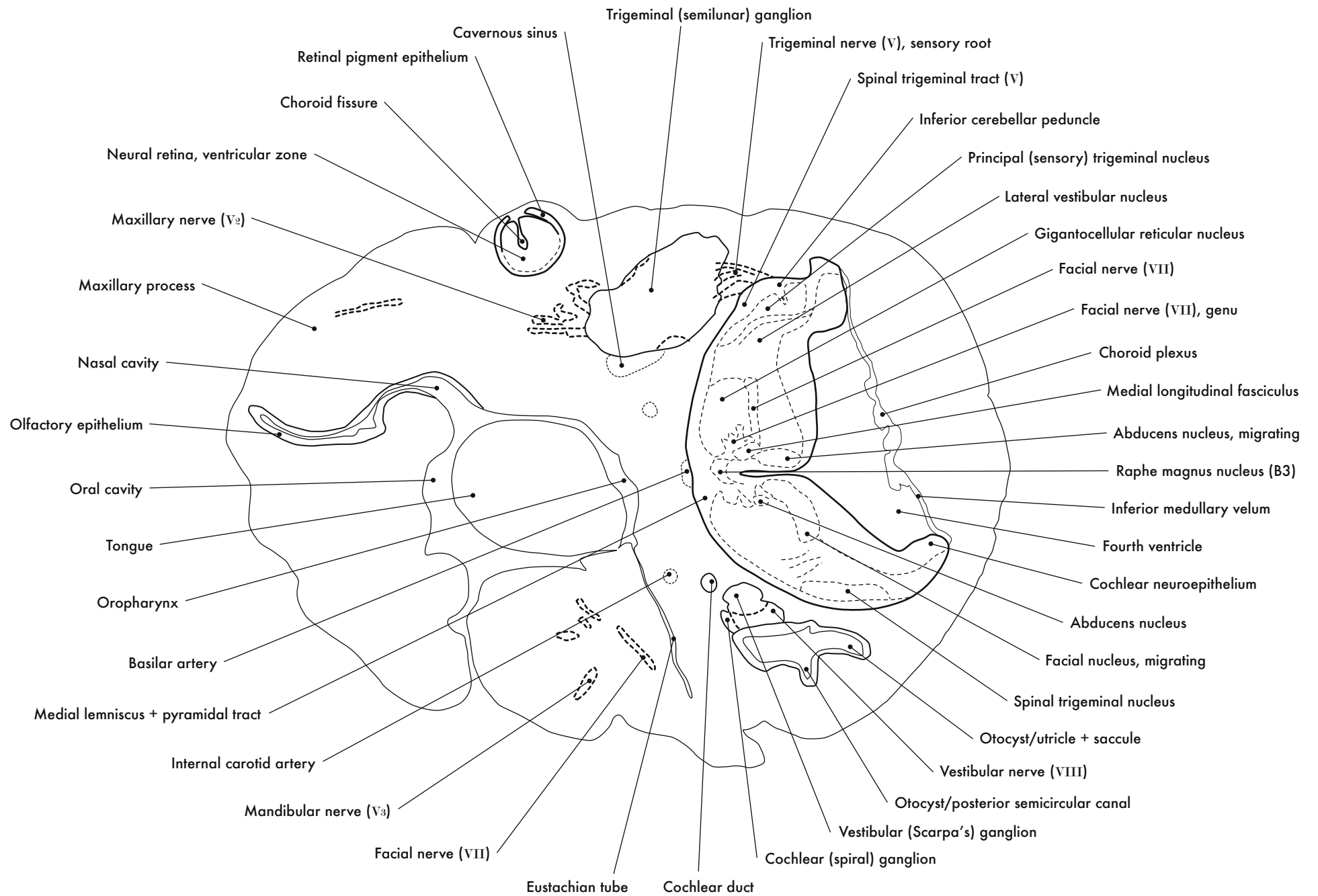
GD 12 HORIZONTAL 14

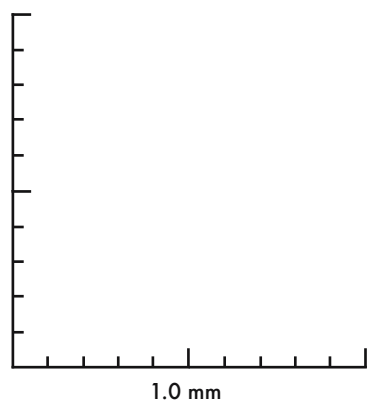
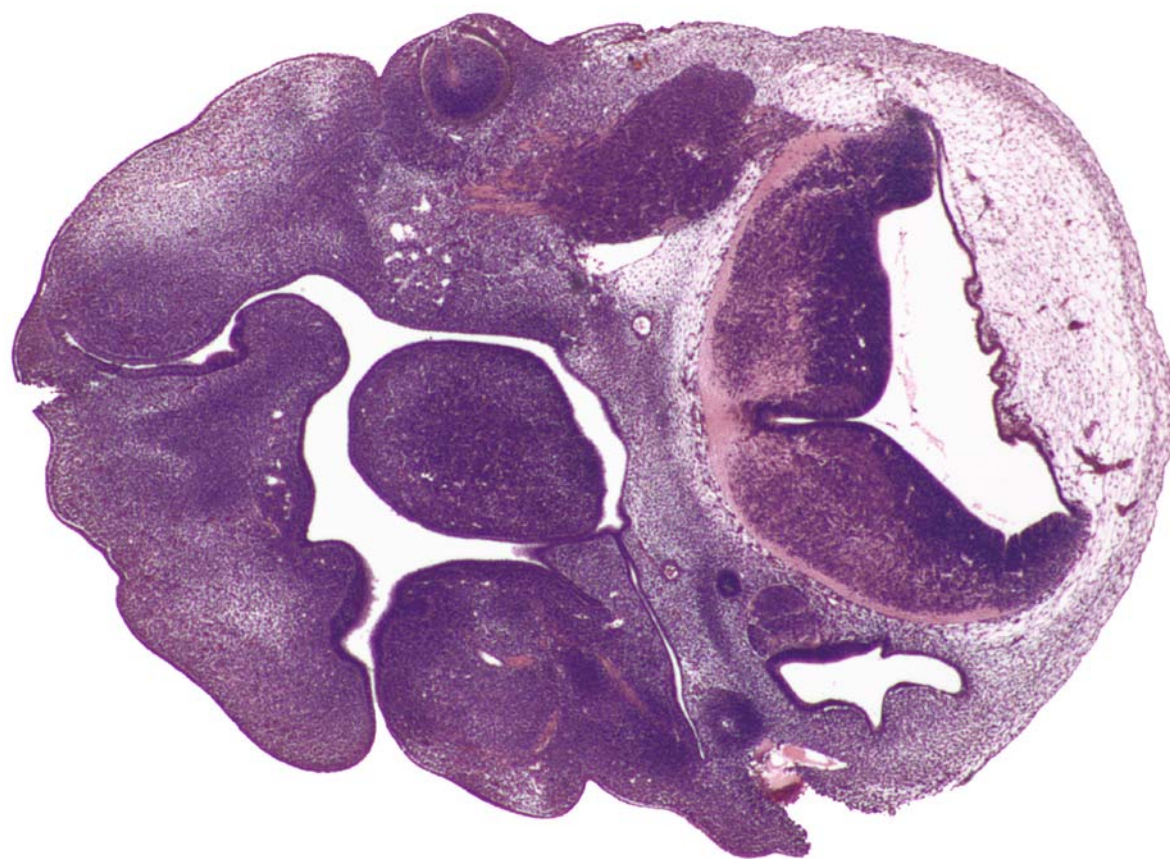
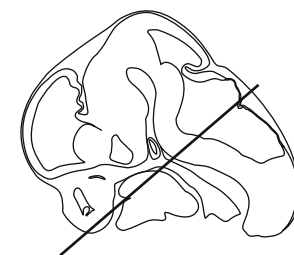






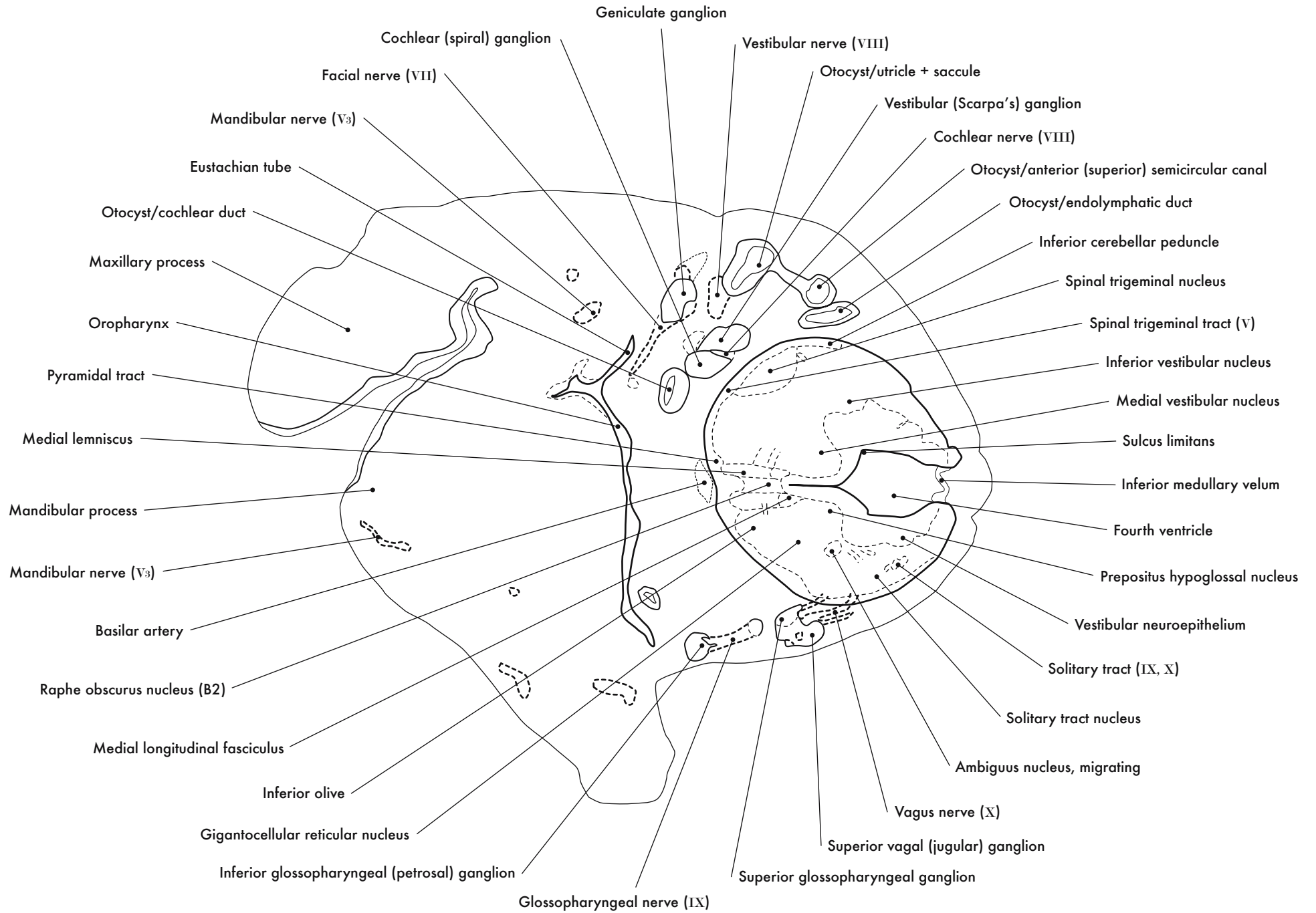
GD 12 HORIZONTAL 15

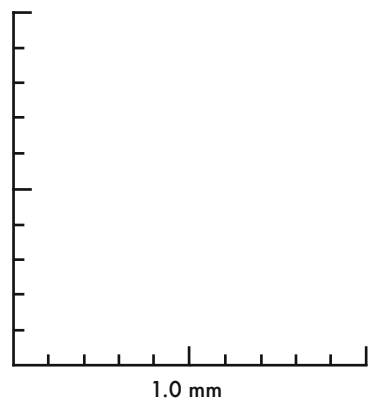
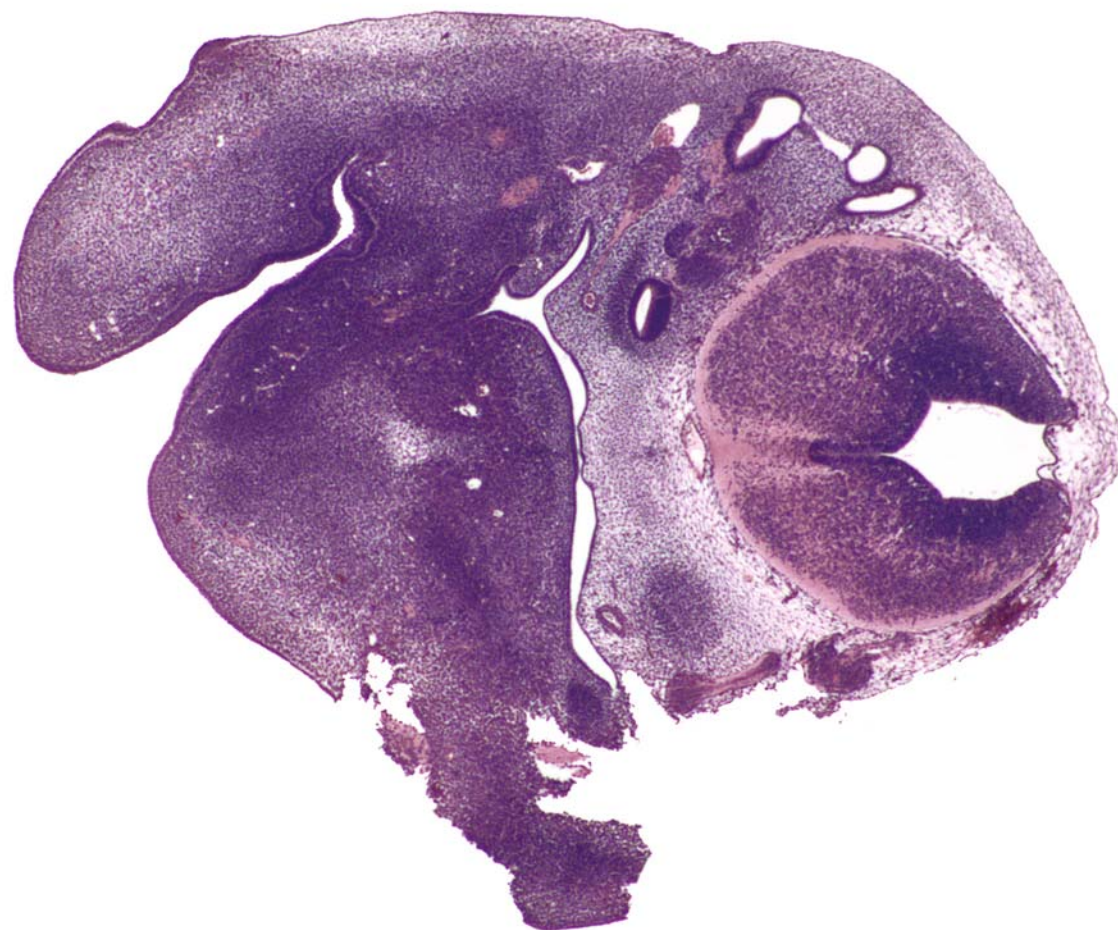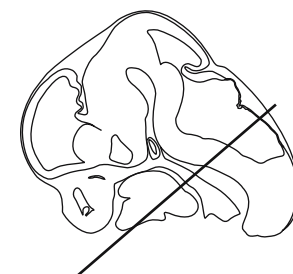




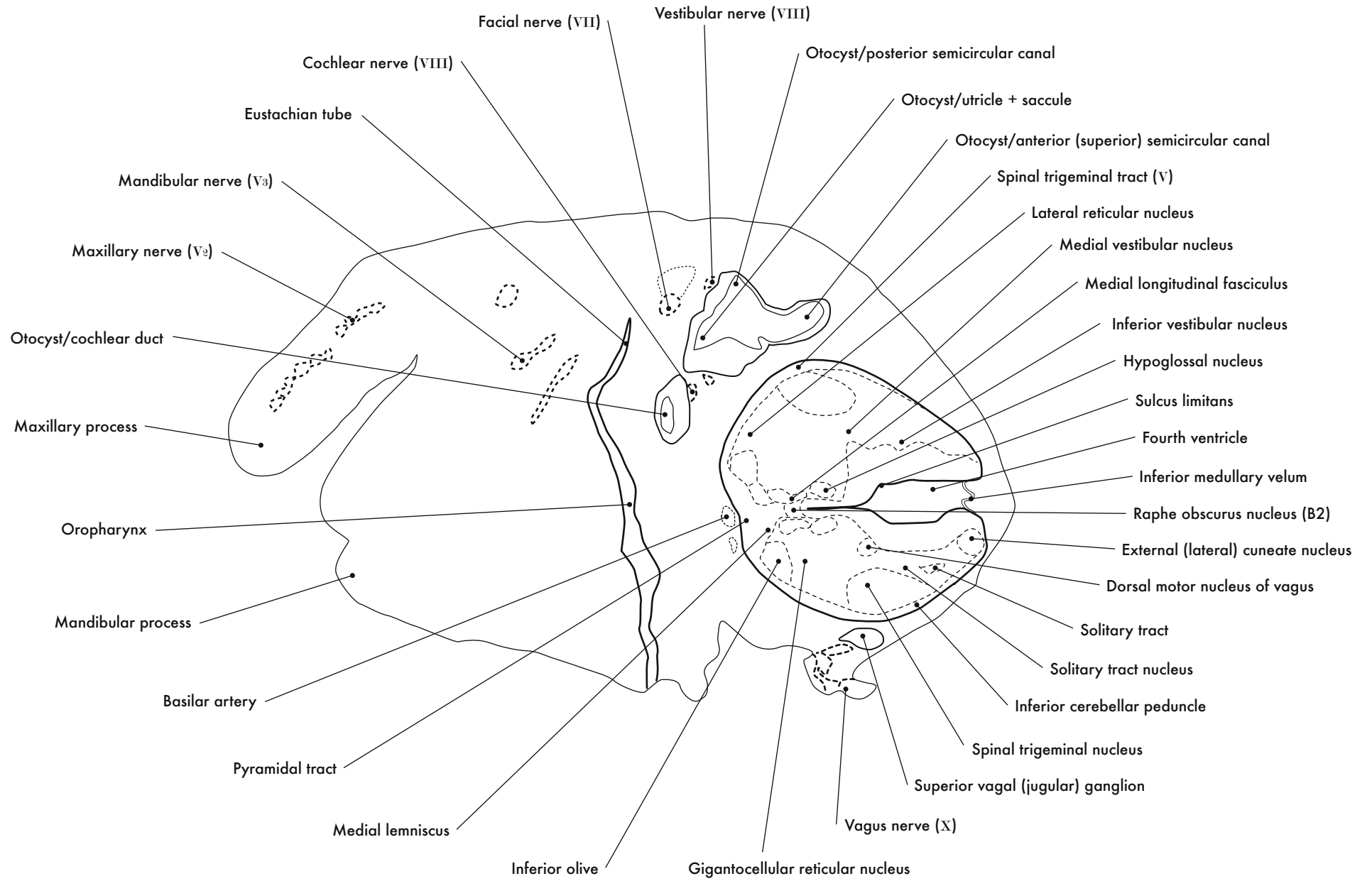
GD 12 HORIZONTAL 16

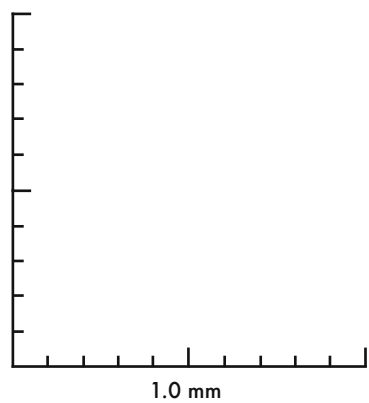
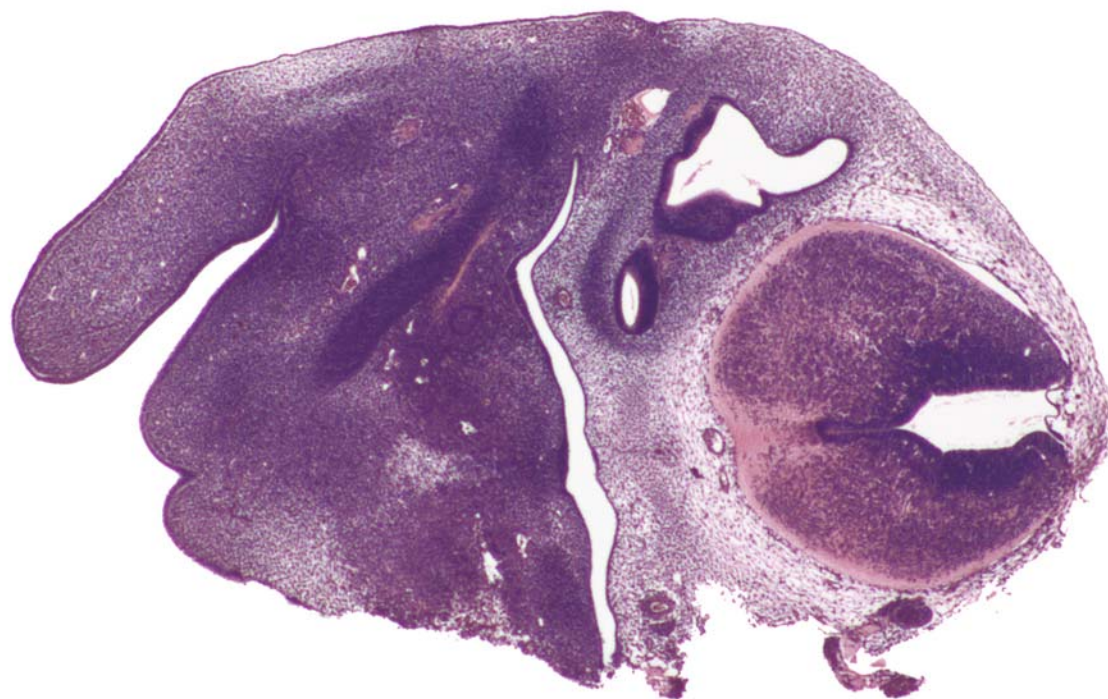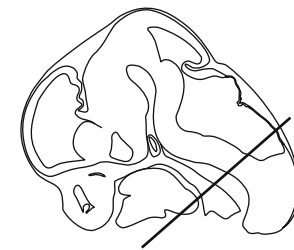






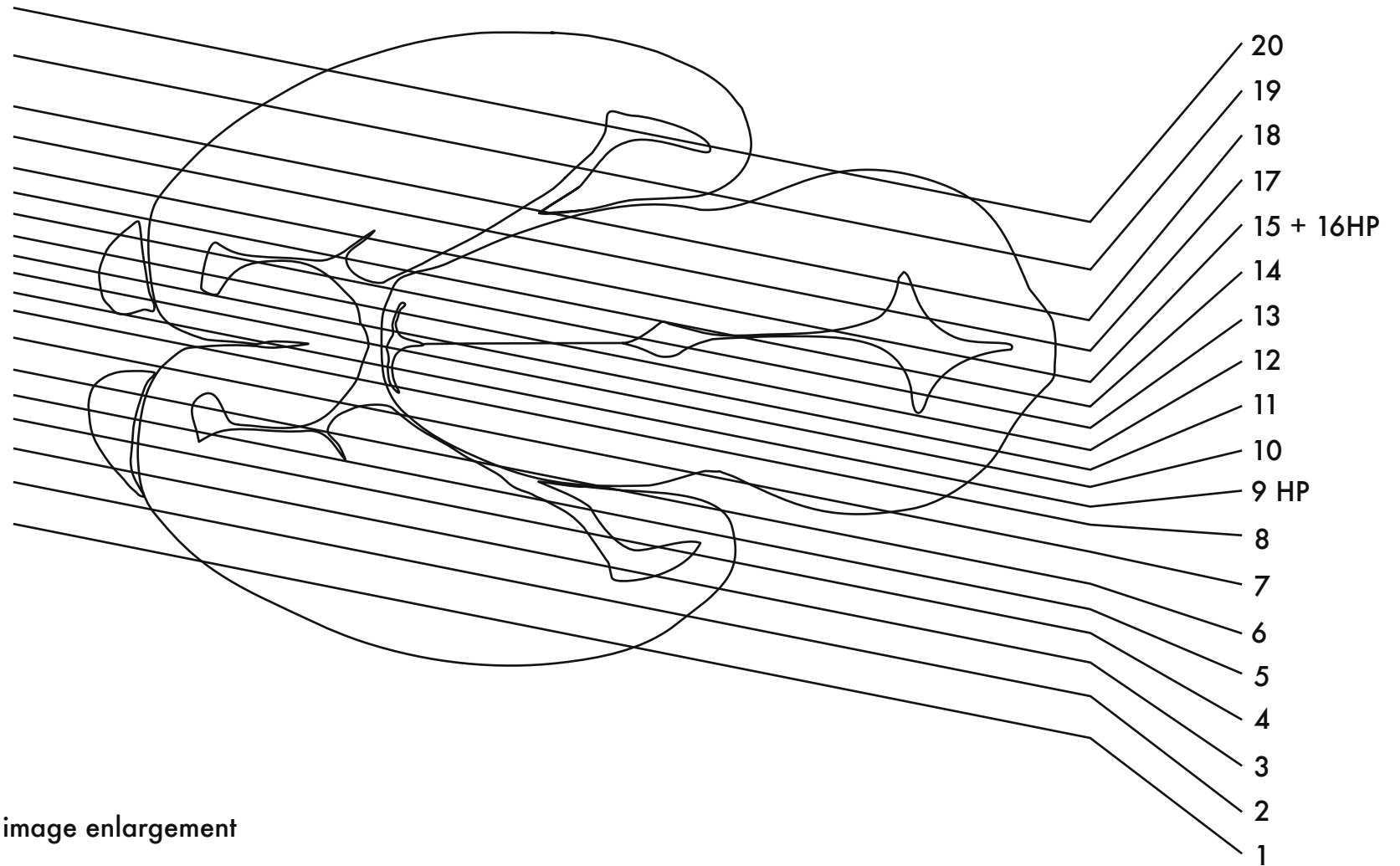
GD 12 HORIZONTAL 17





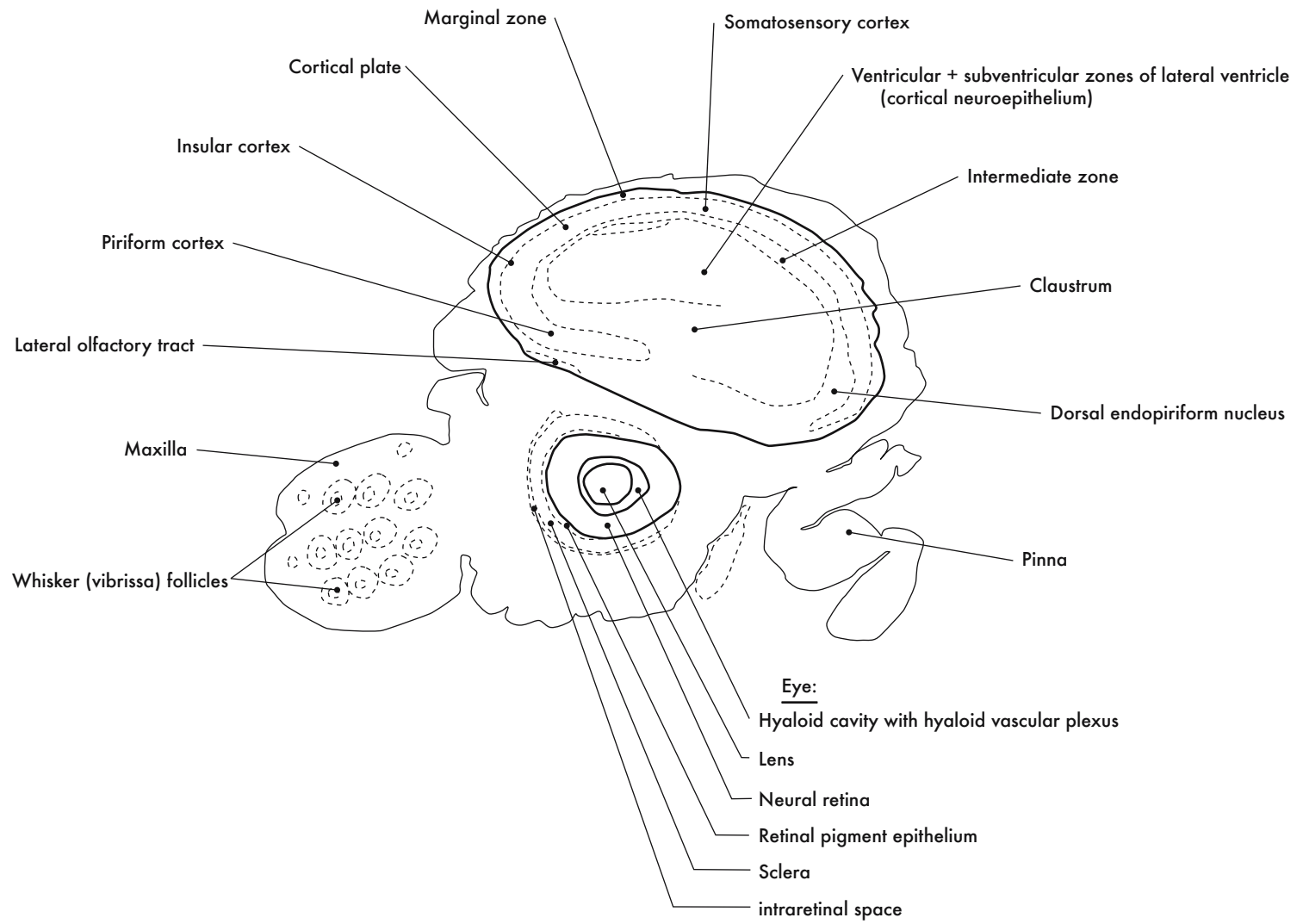
GD 12 HORIZONTAL 18

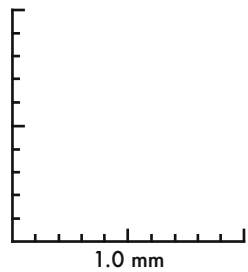
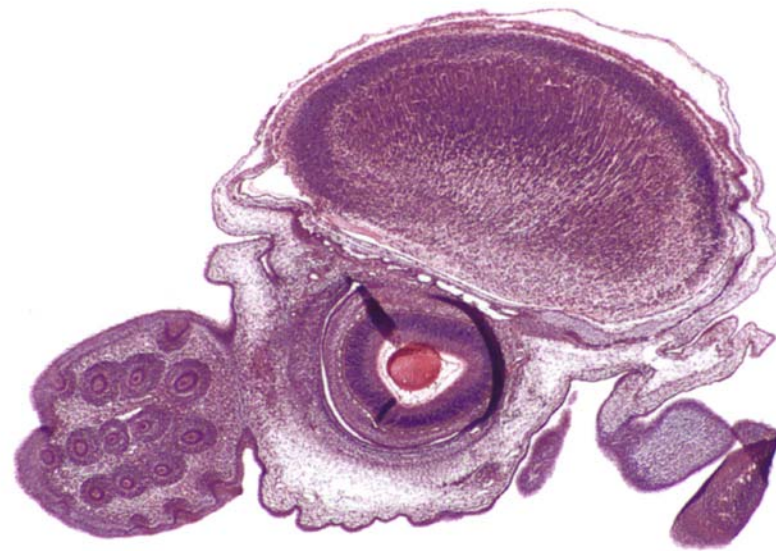
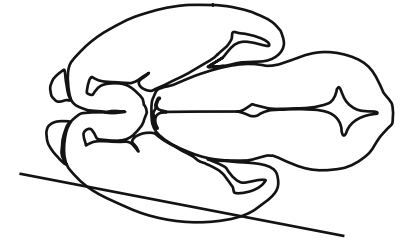




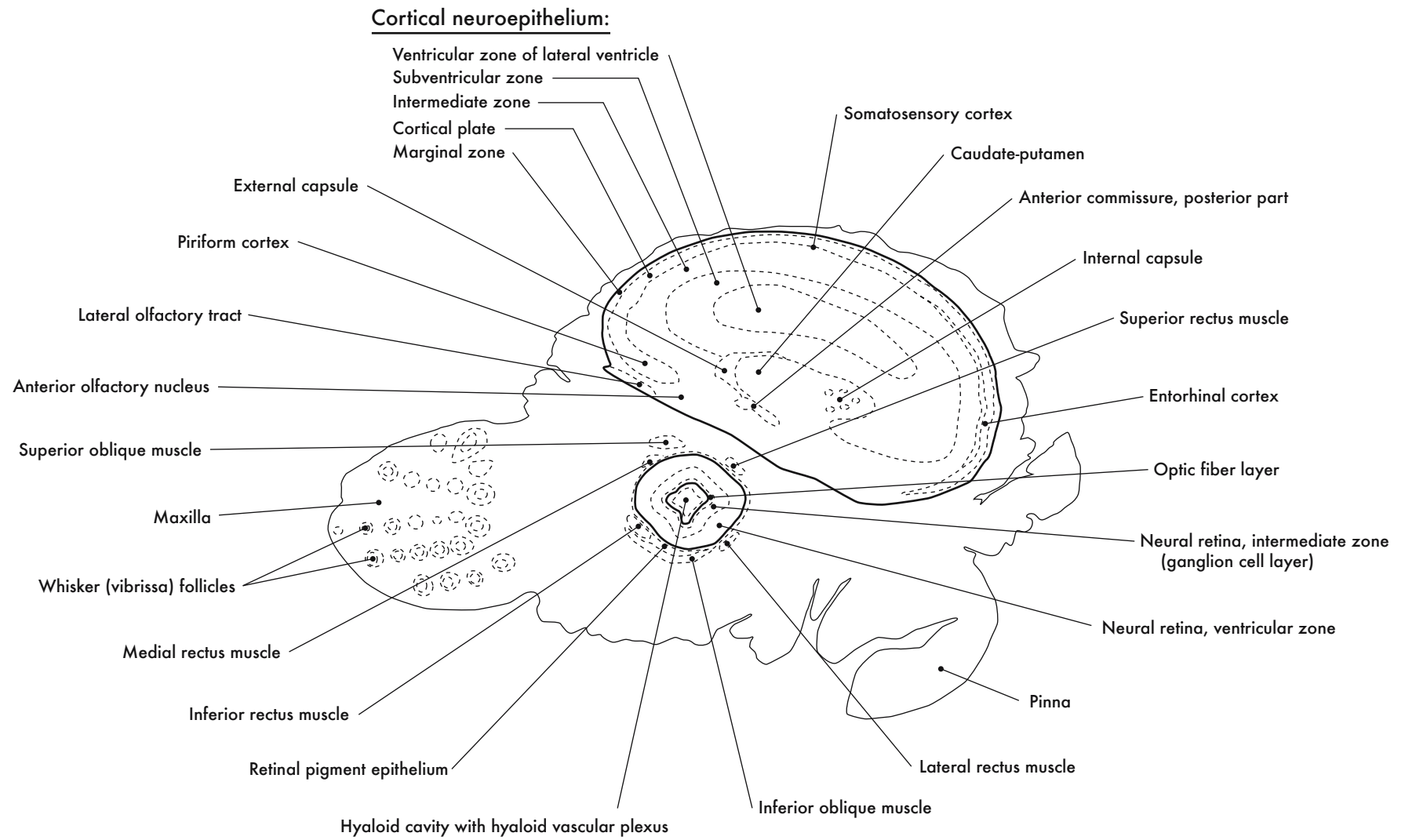
HP denotes image enlargement

### GESTATIONAL DAY 14 (GD 14) SAGITTAL SECTIONS

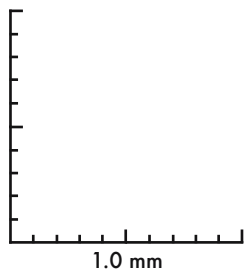
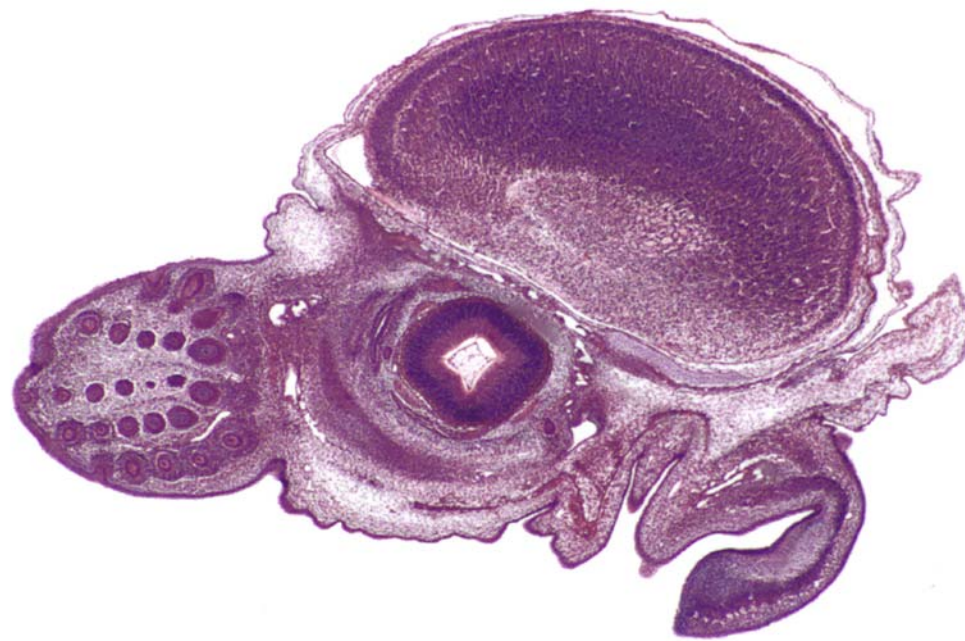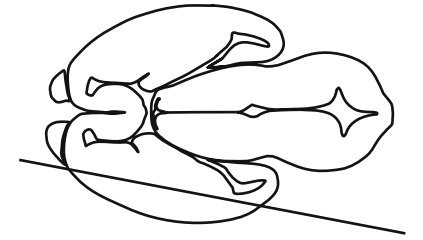




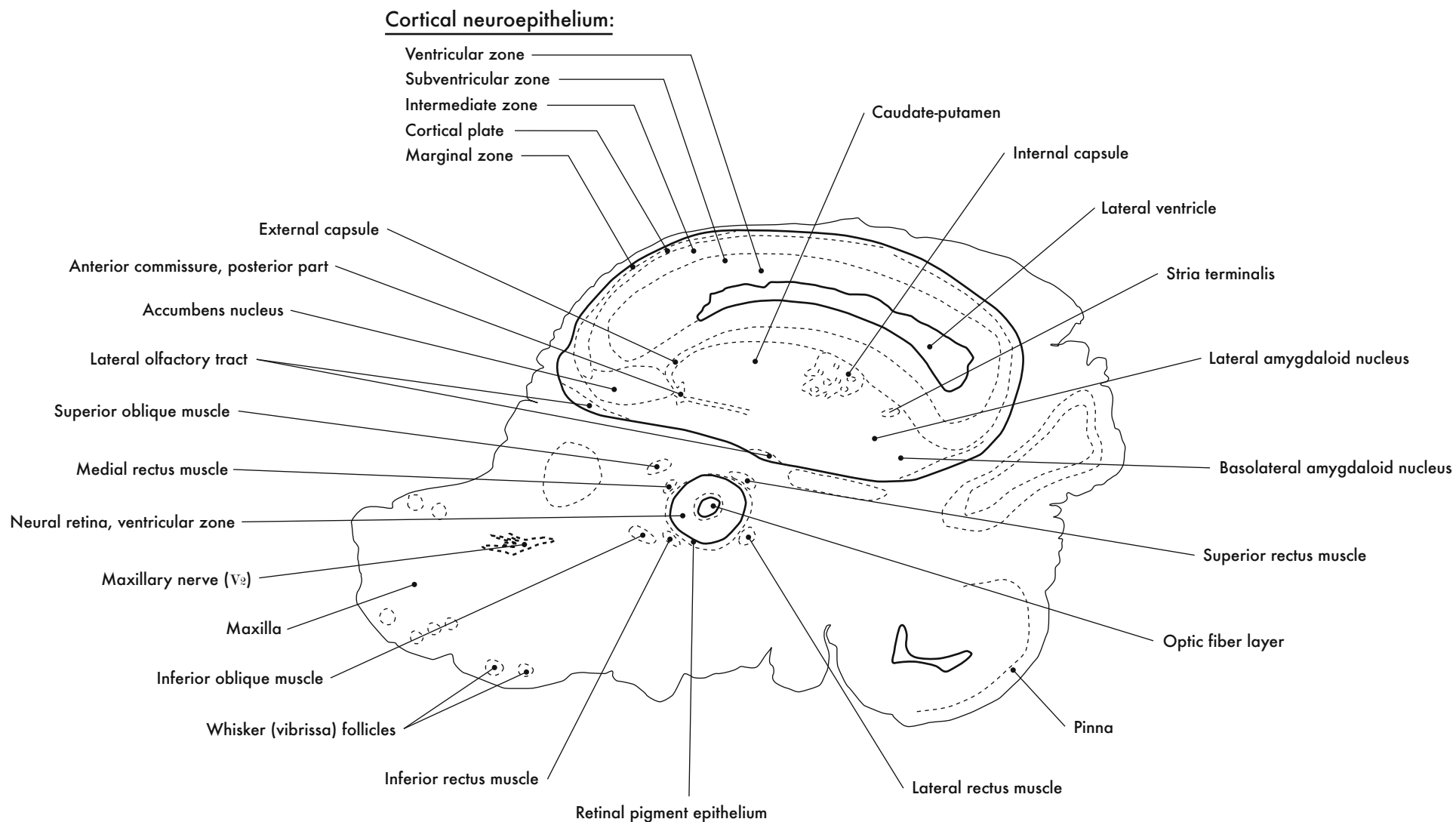
GD 14 SAGITTAL 1

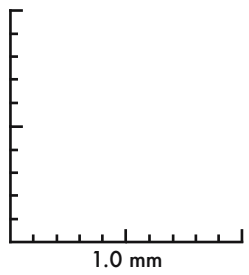
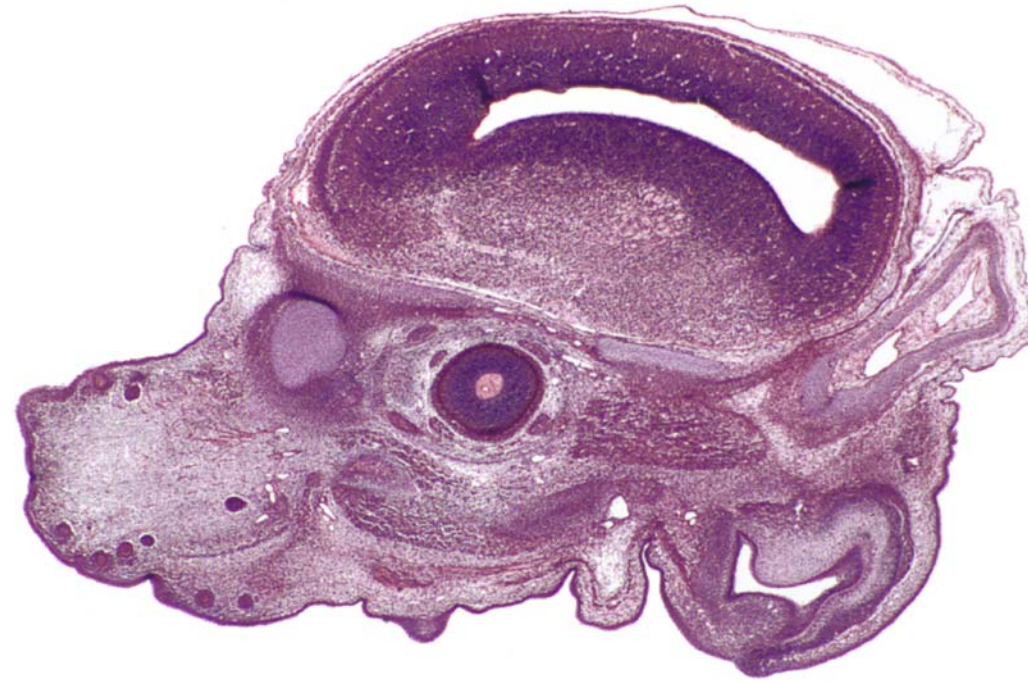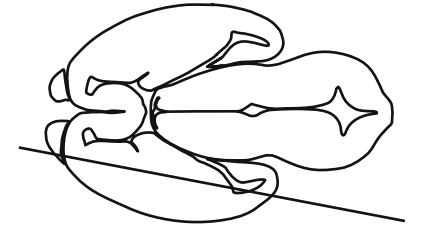




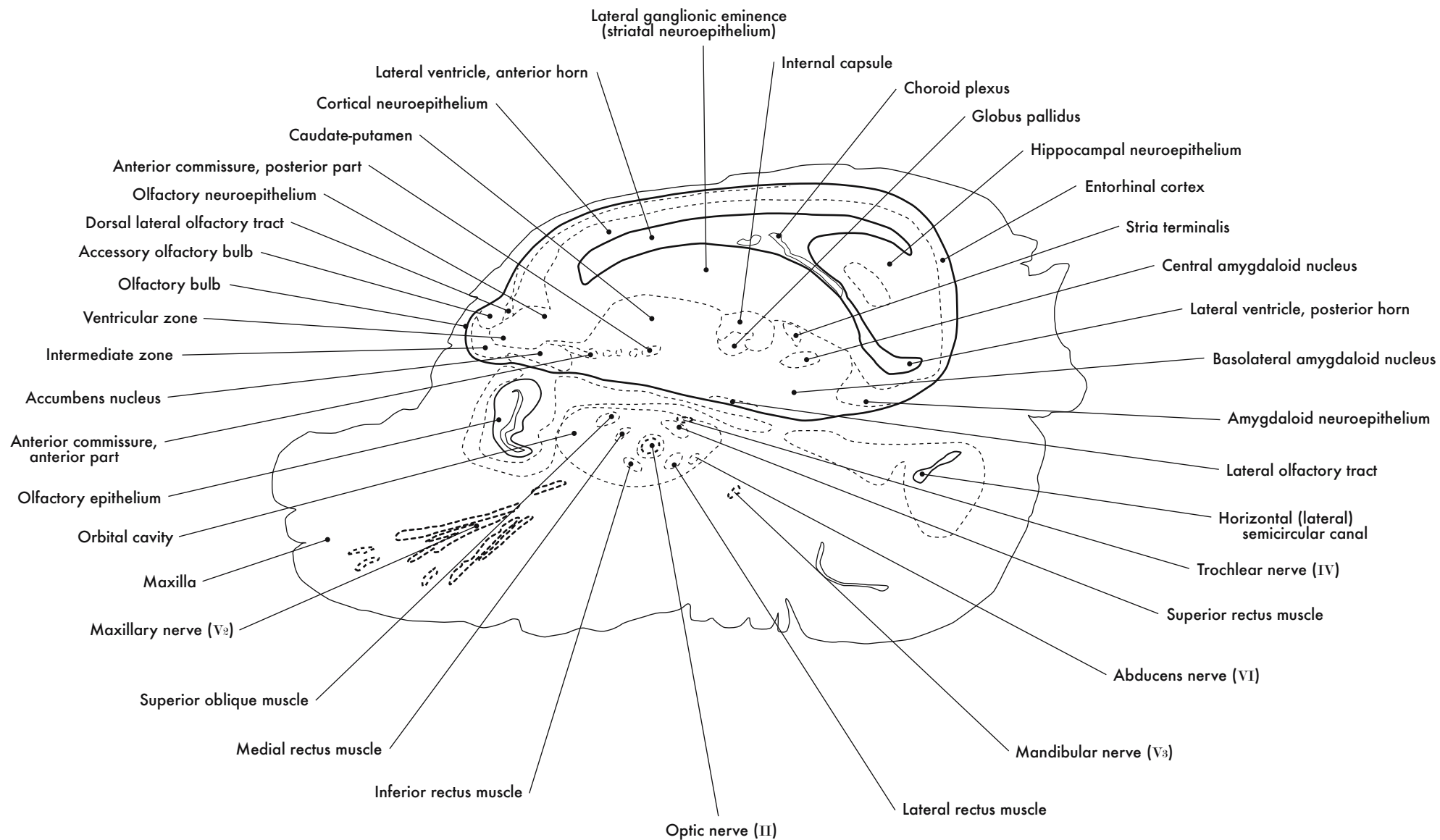


GD 14 SAGITTAL 2

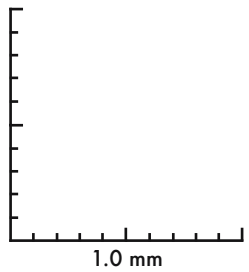
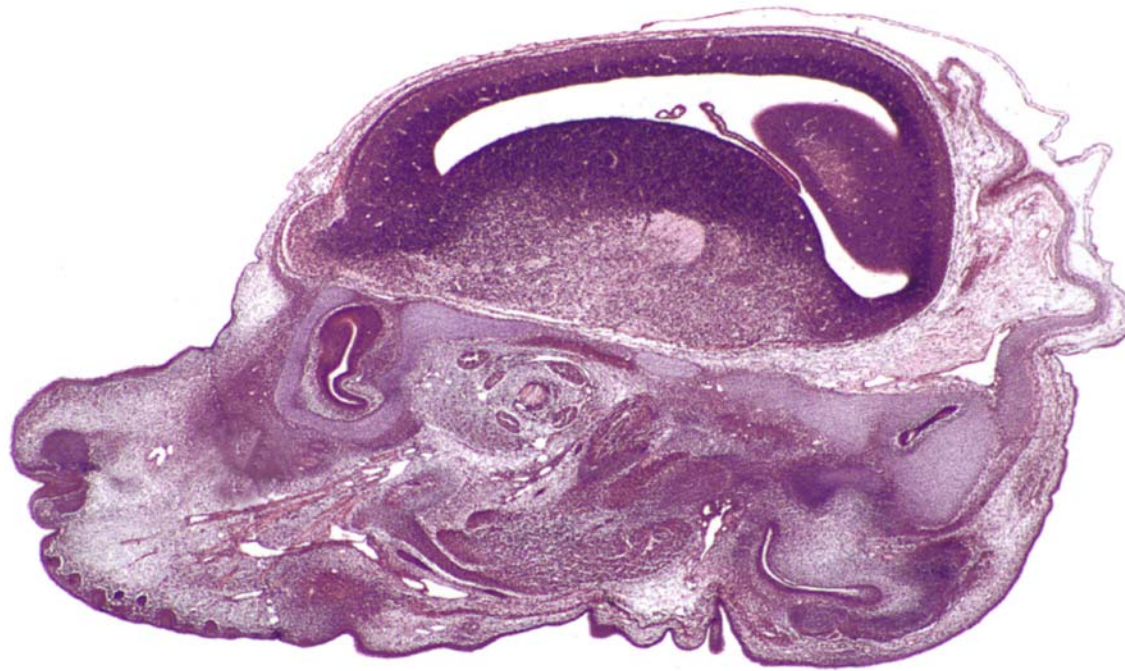
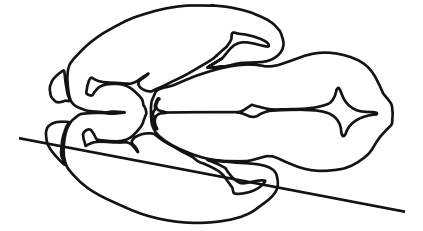




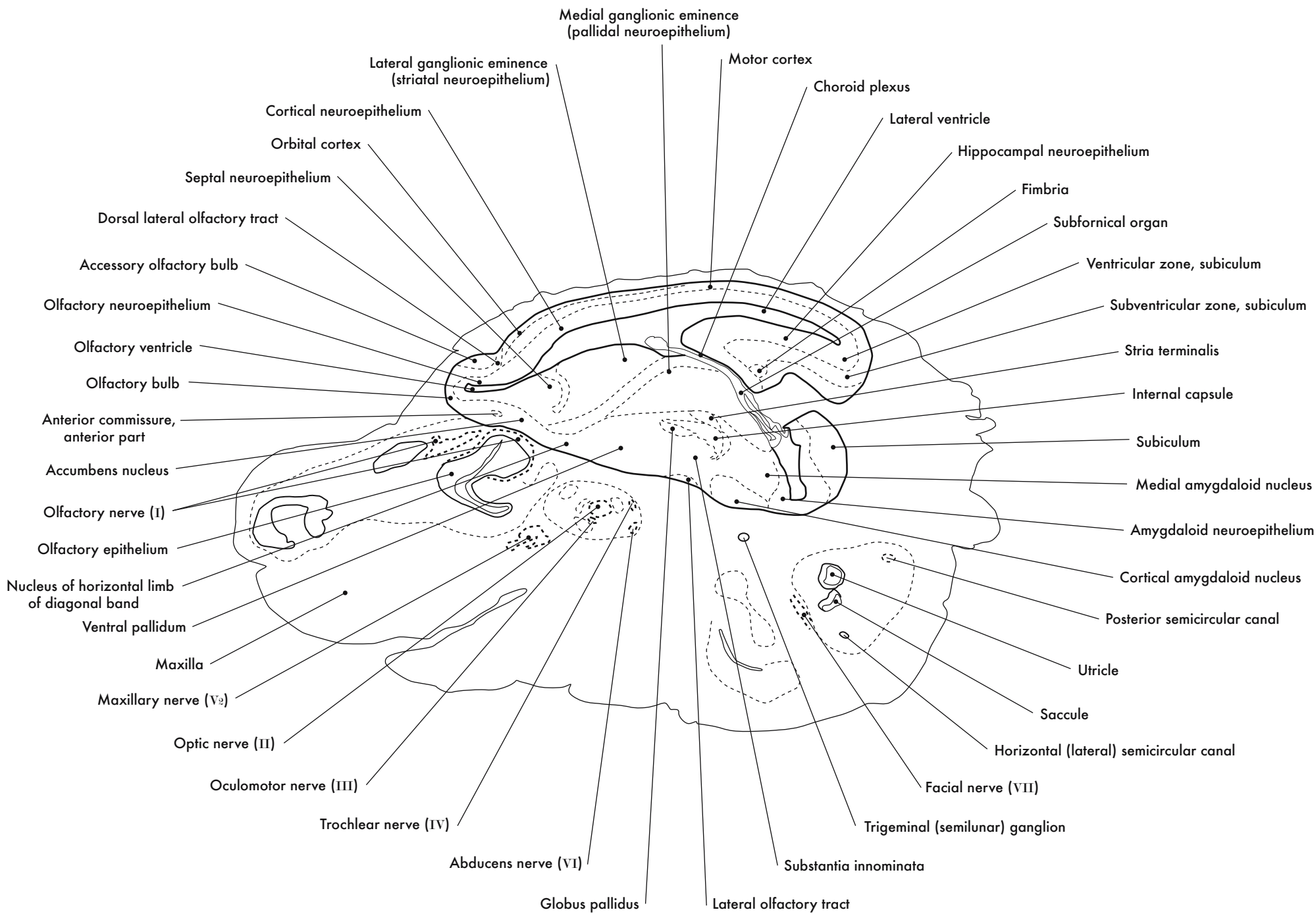
GD 14 SAGITTAL 3

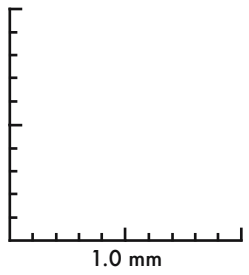
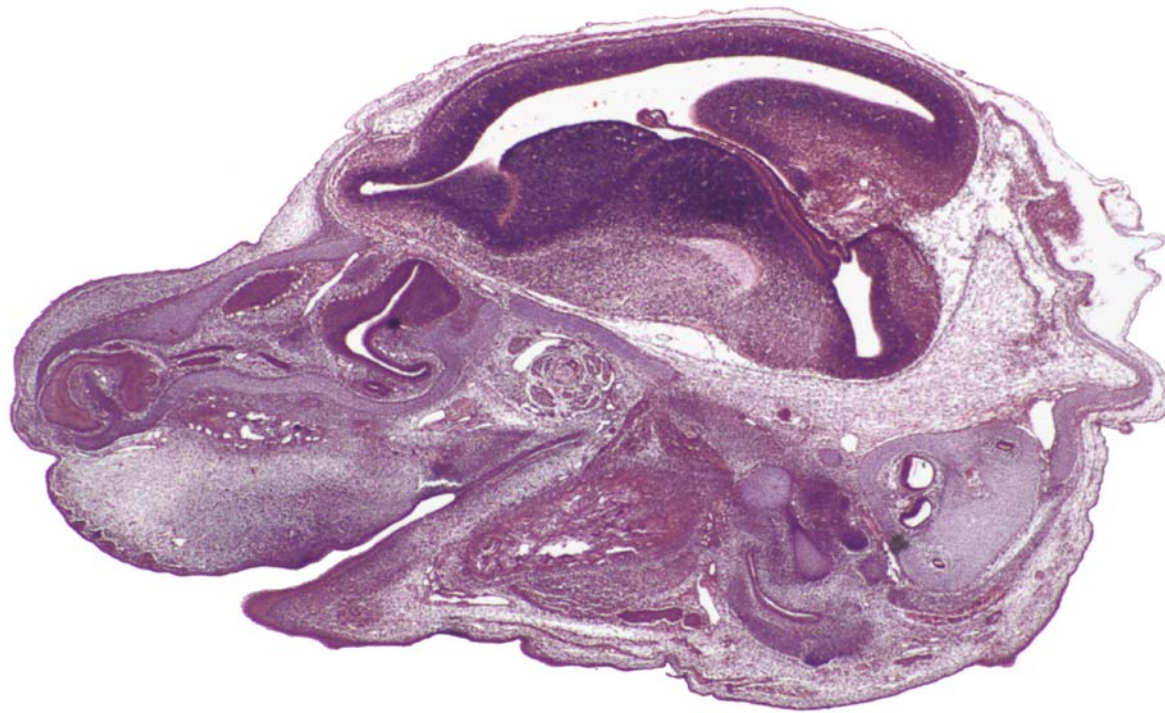
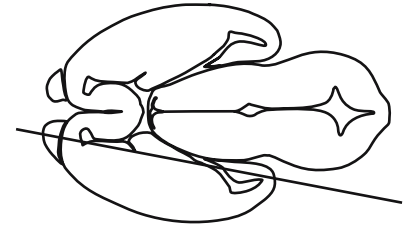




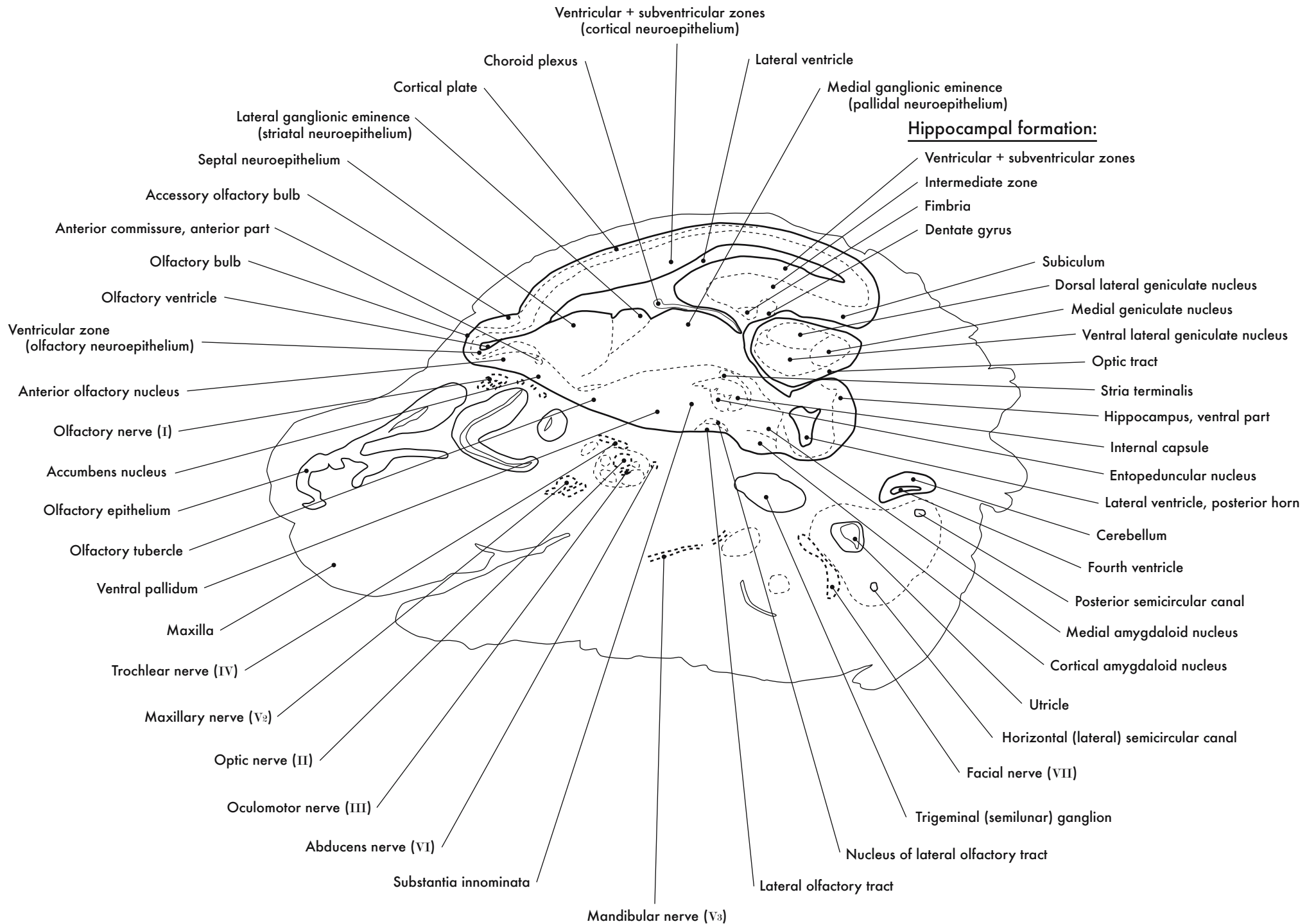


GD 14 SAGITTAL 4

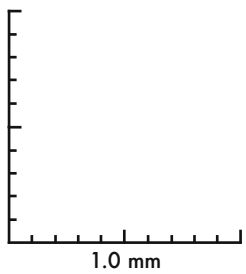
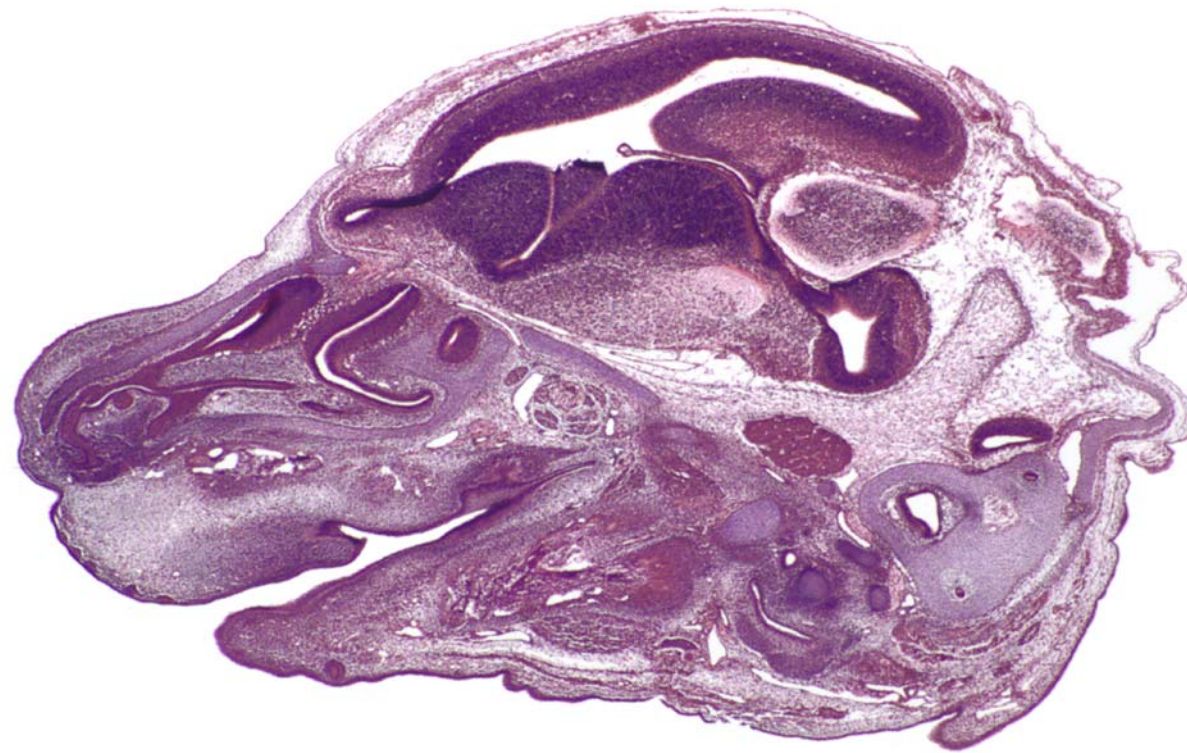
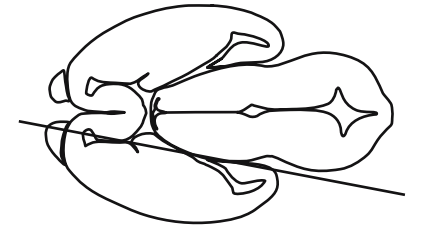




GD 14 SAGITTAL 5

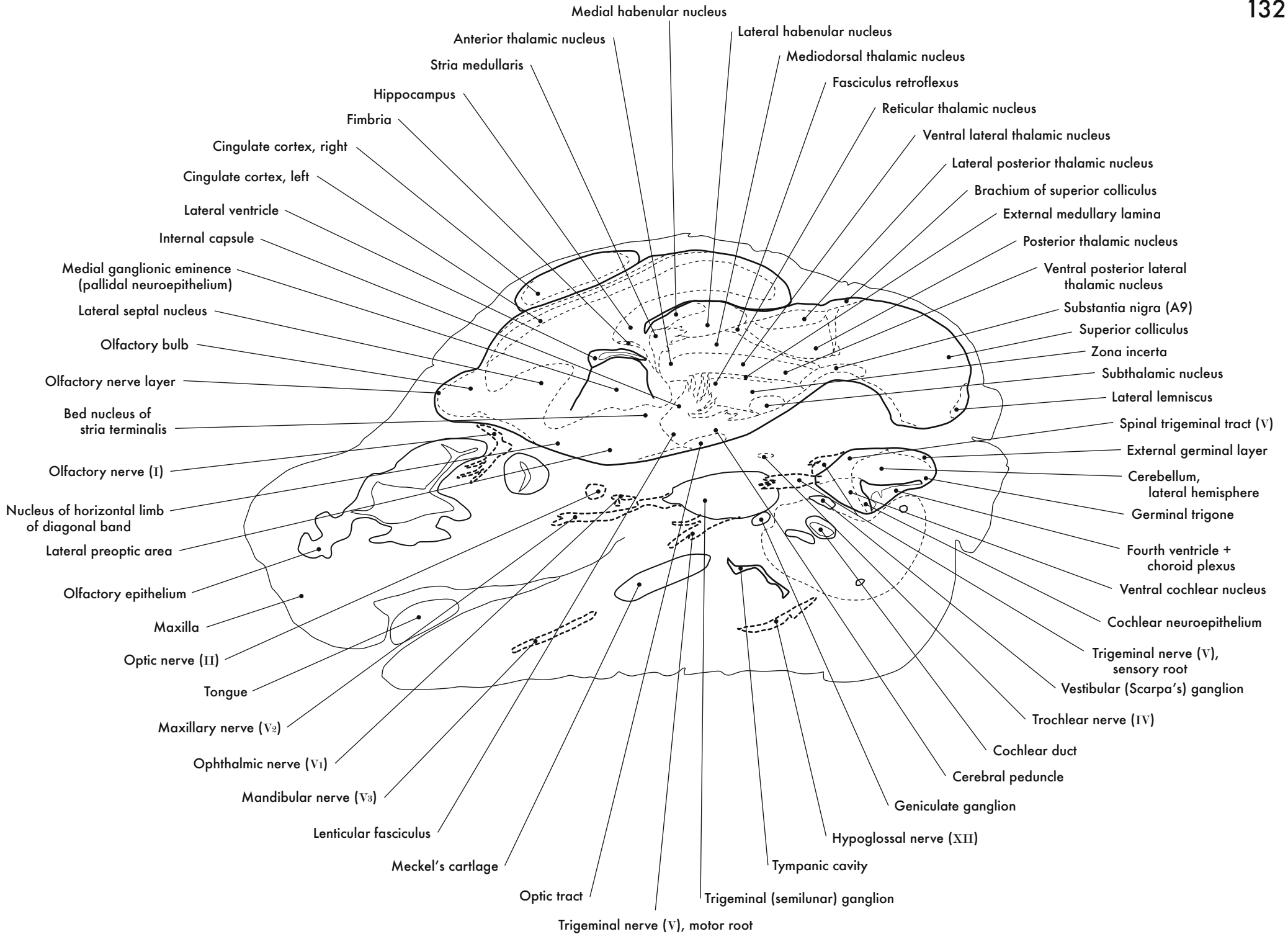


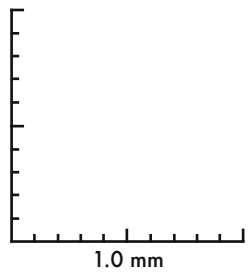
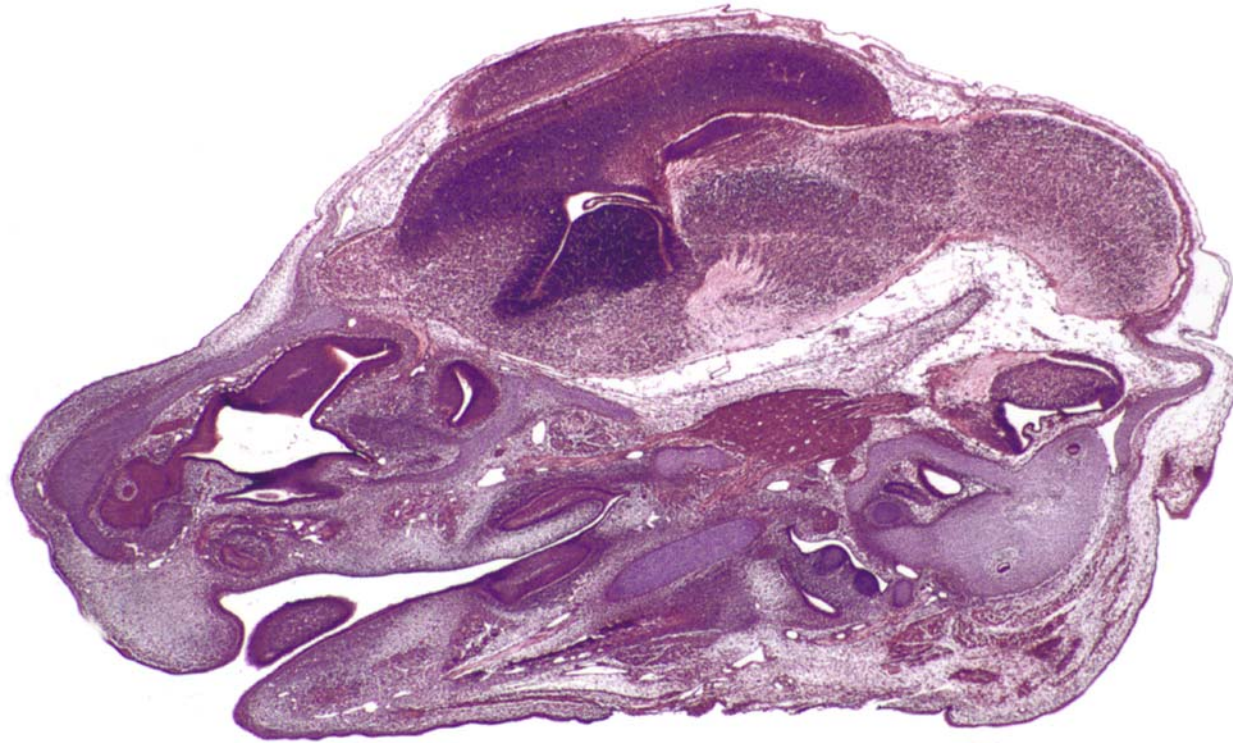
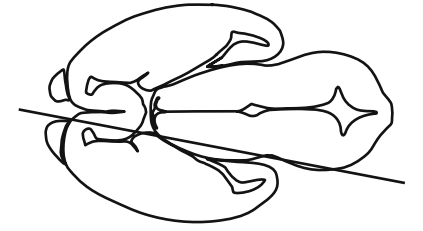




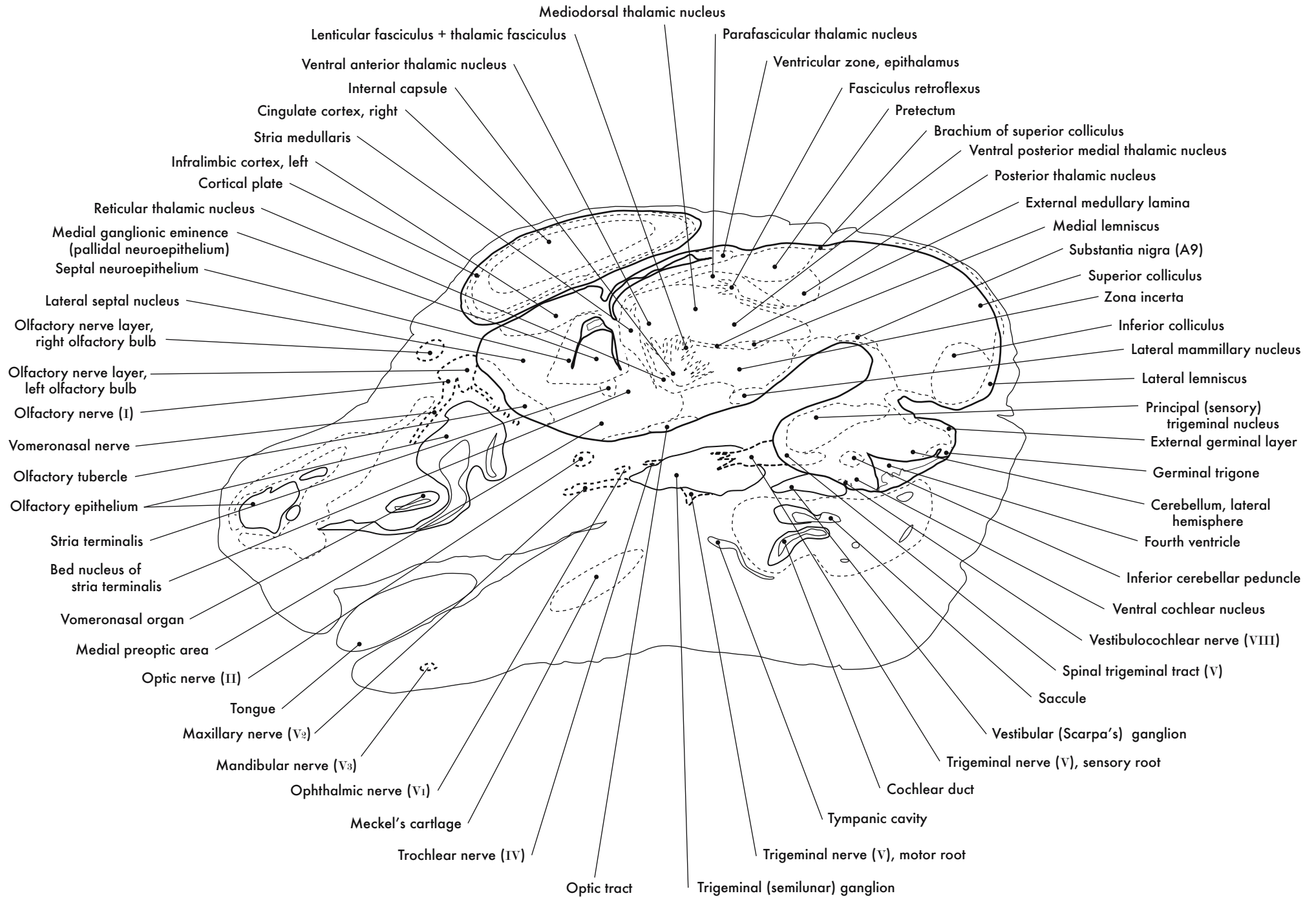
GD 14 SAGITTAL 6

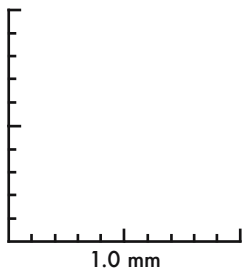
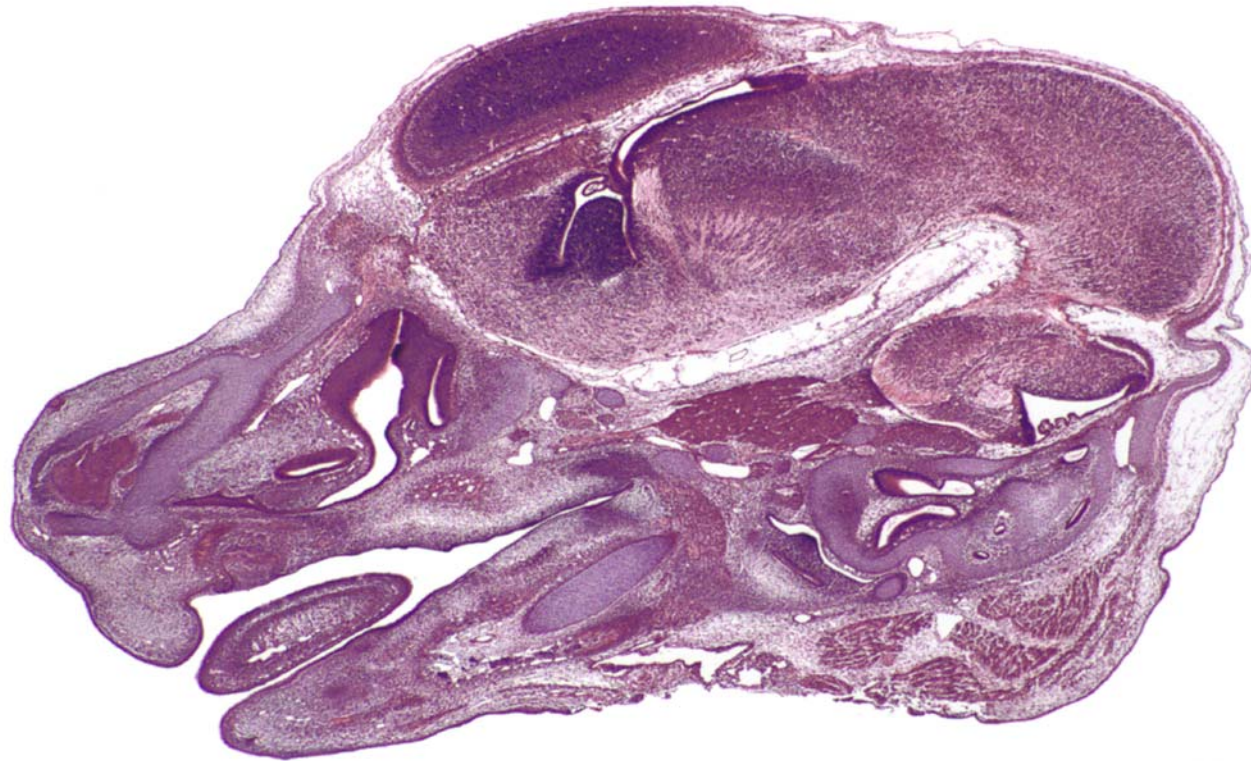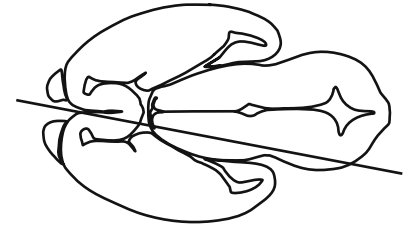






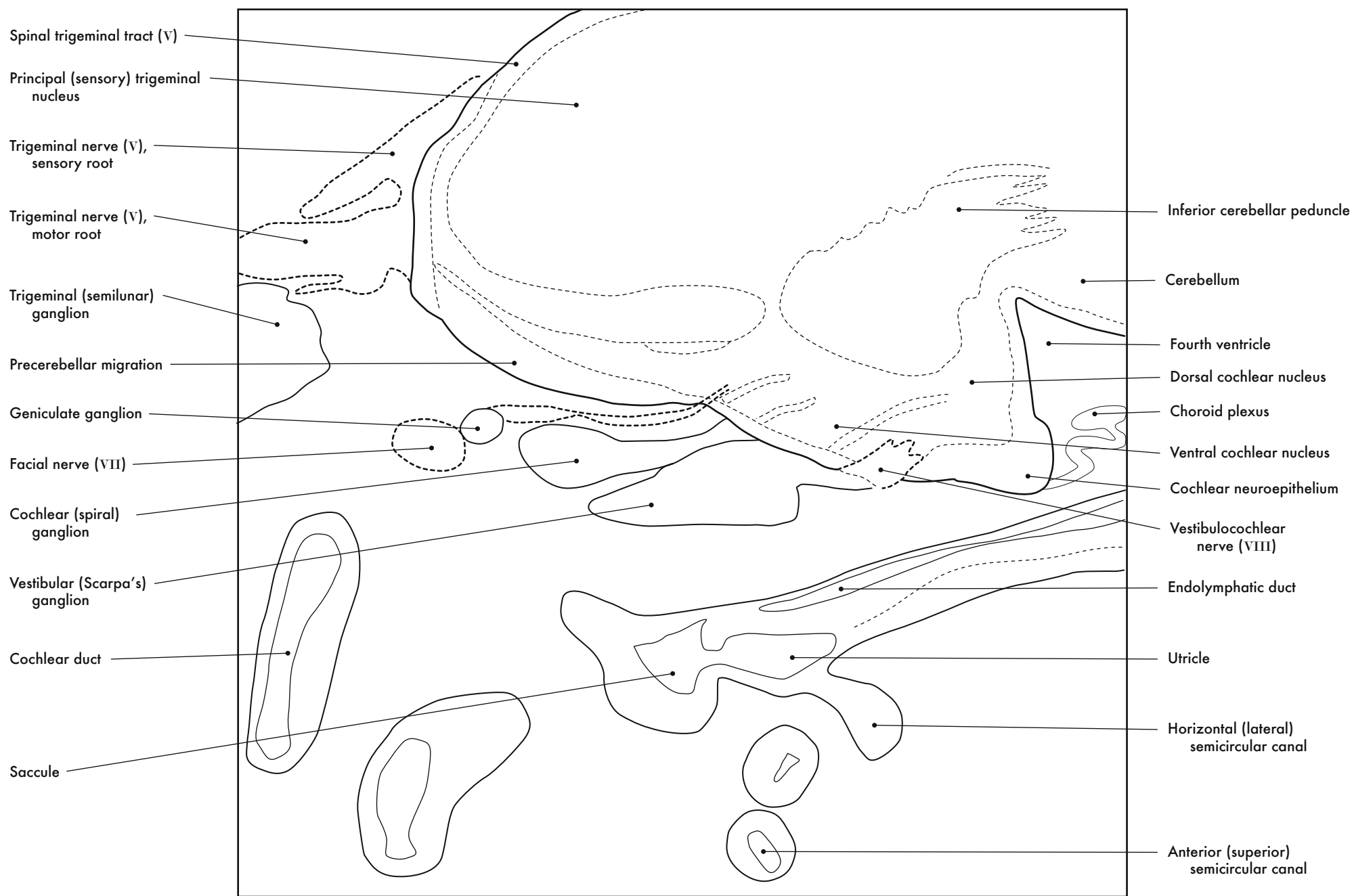
GD 14 SAGITTAL 7





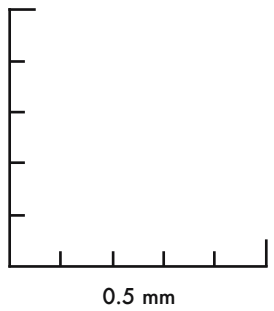
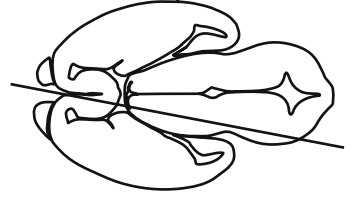
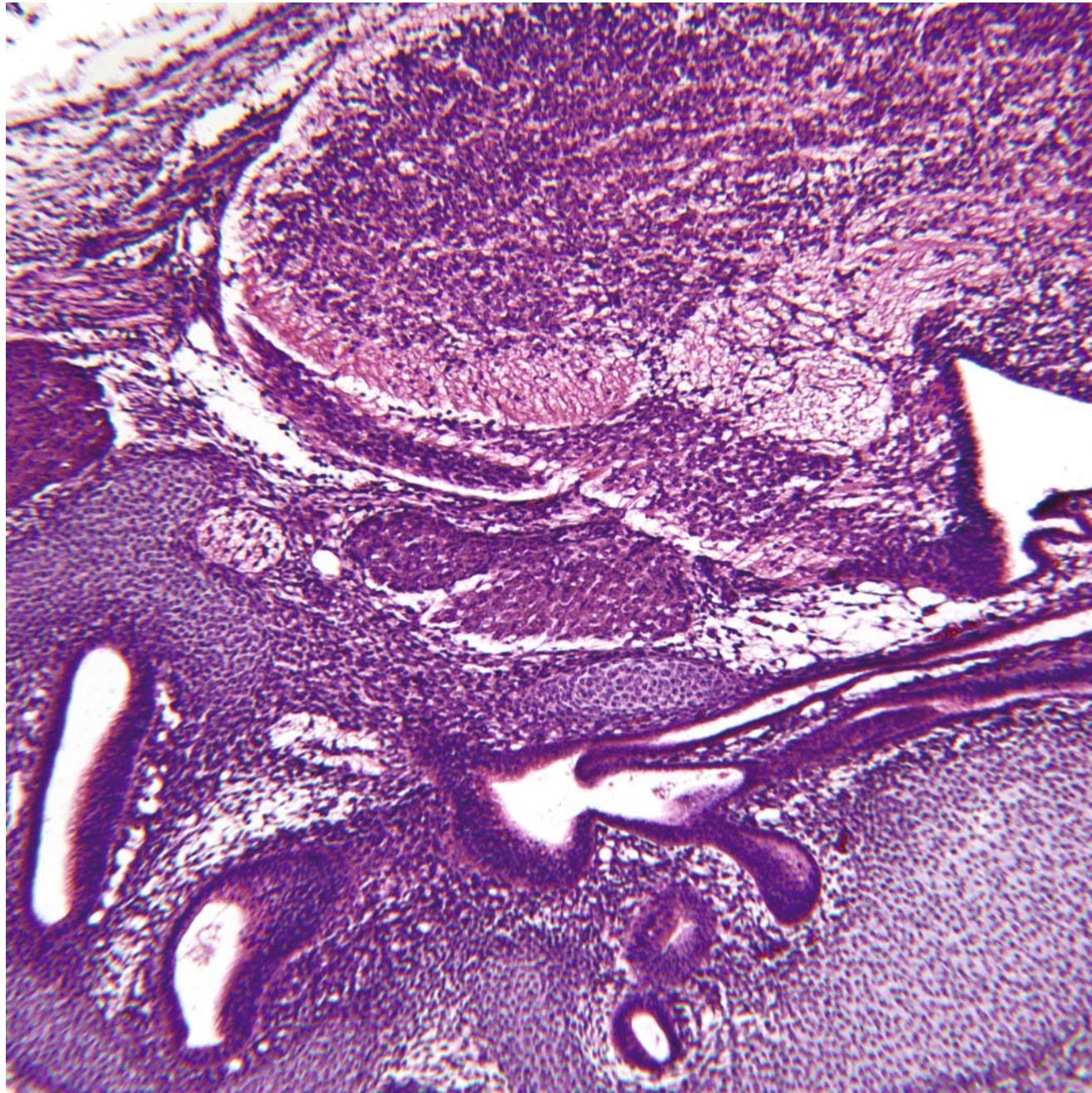
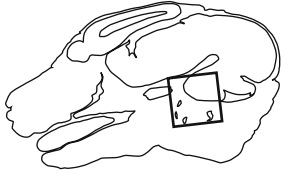
GD 14 SAGITTAL 8





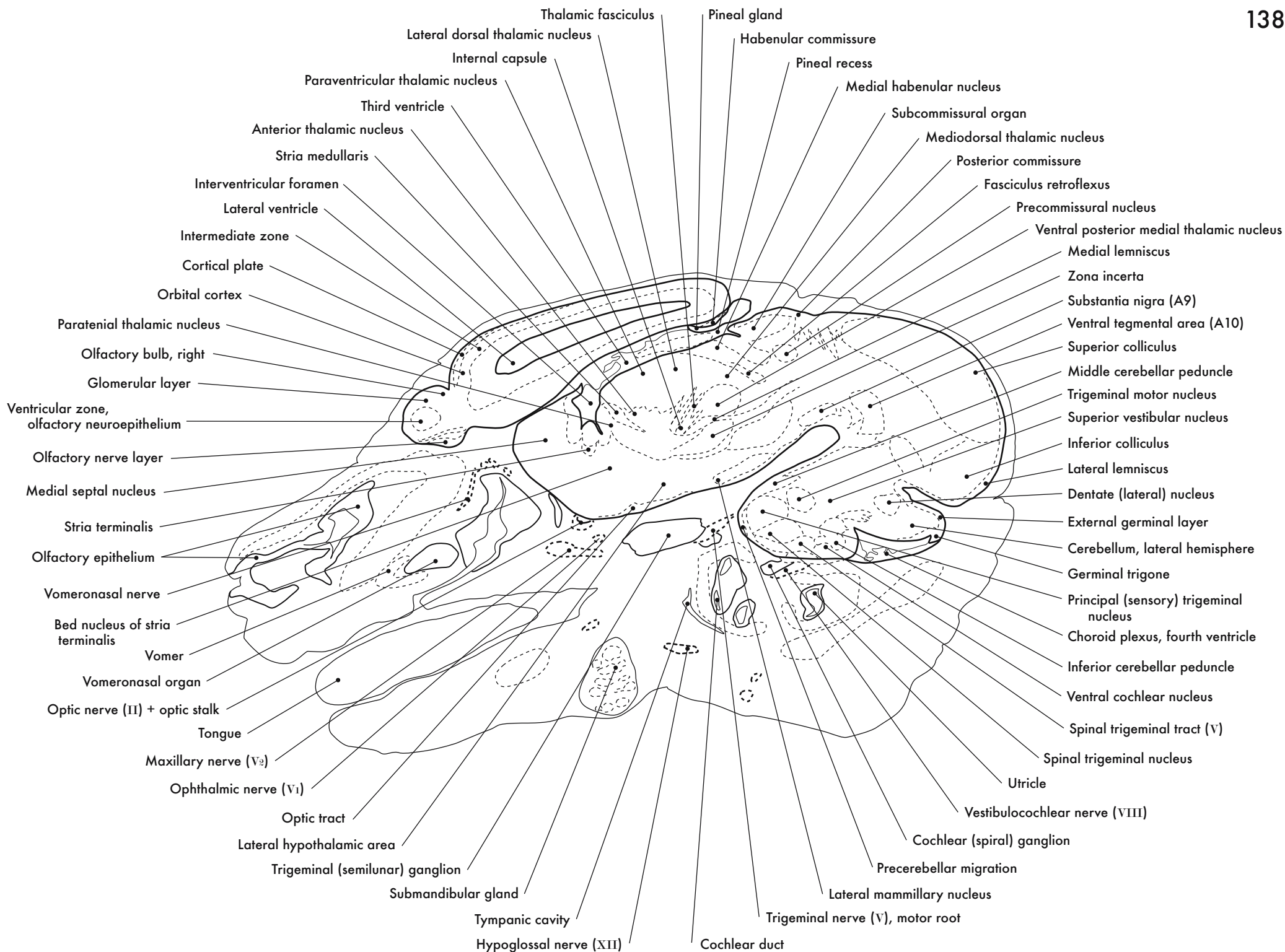
Ganglia and Inner Ear

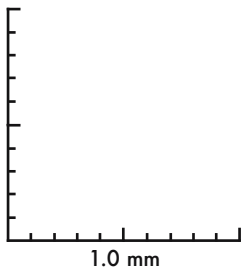
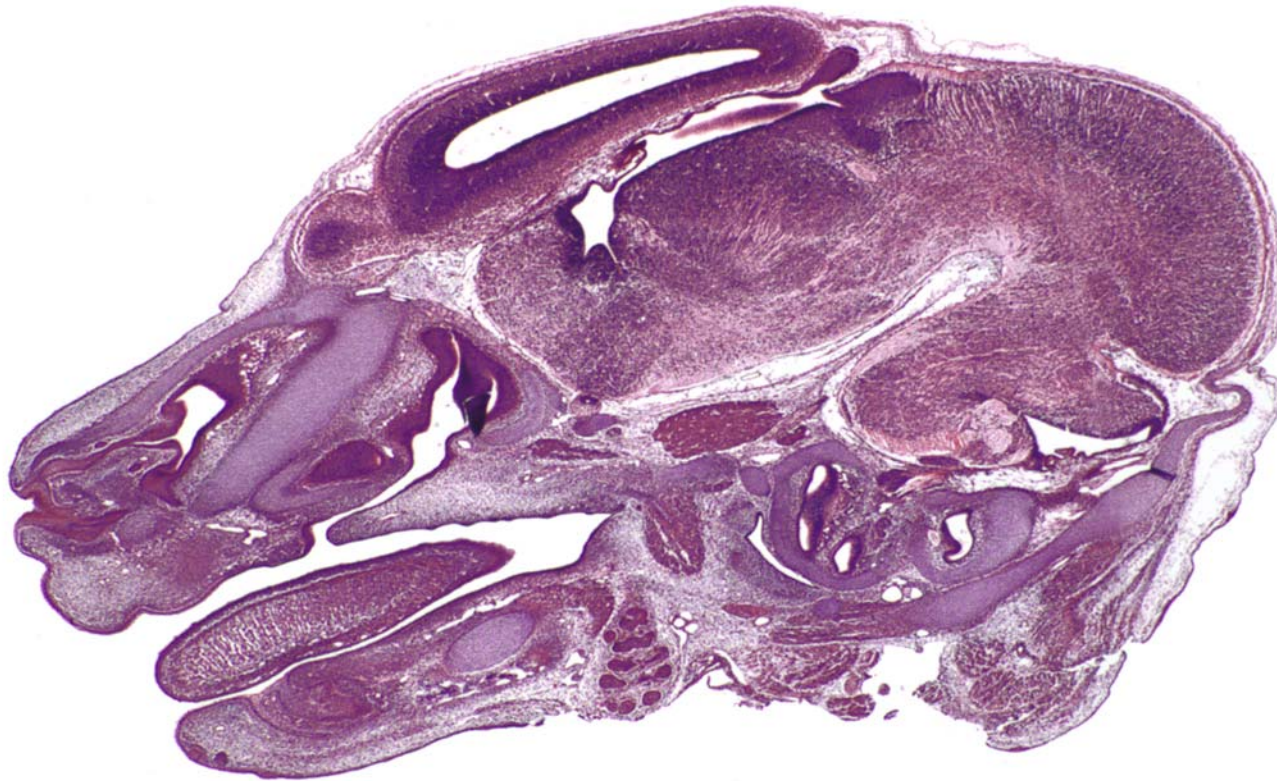
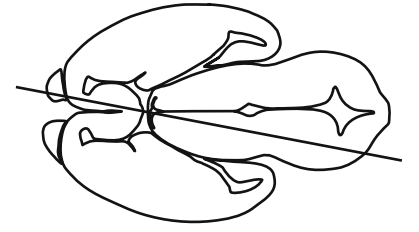




GD 14 SAGITTAL 9

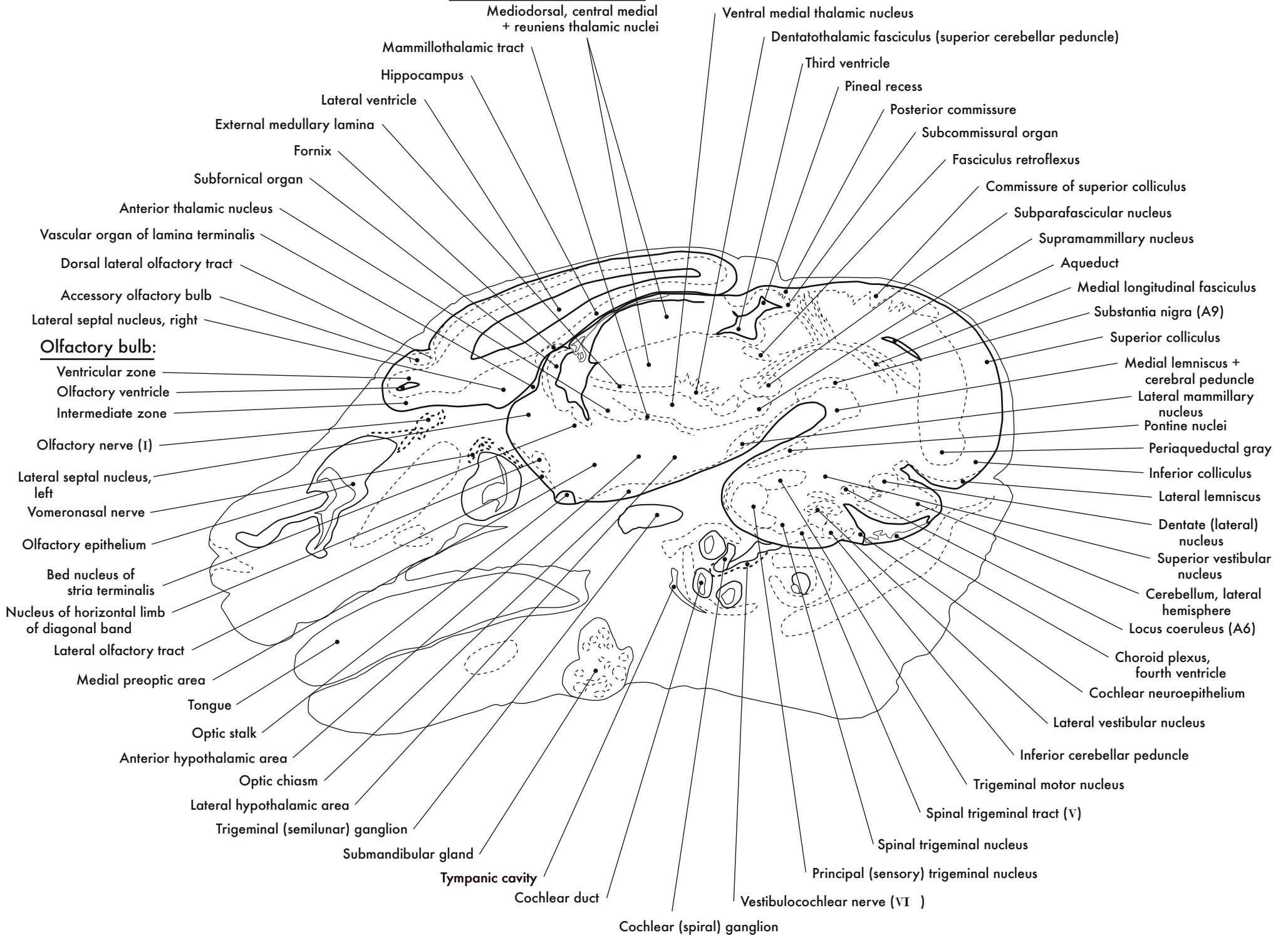




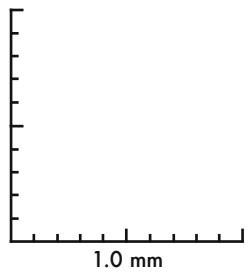
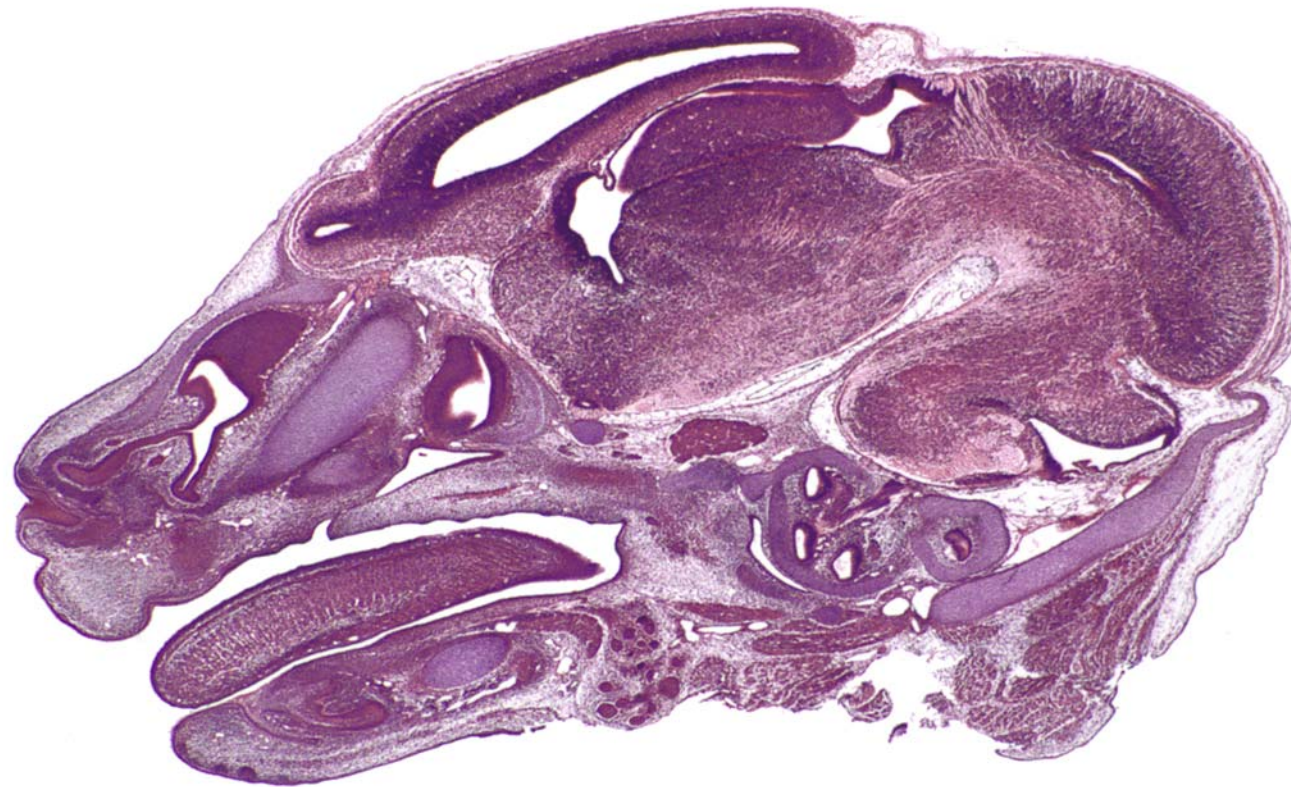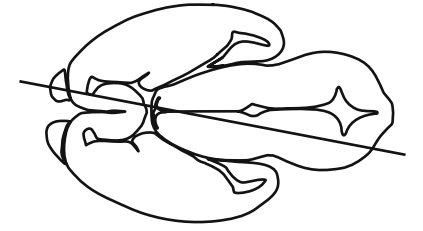


GD 14 SAGITTAL 10

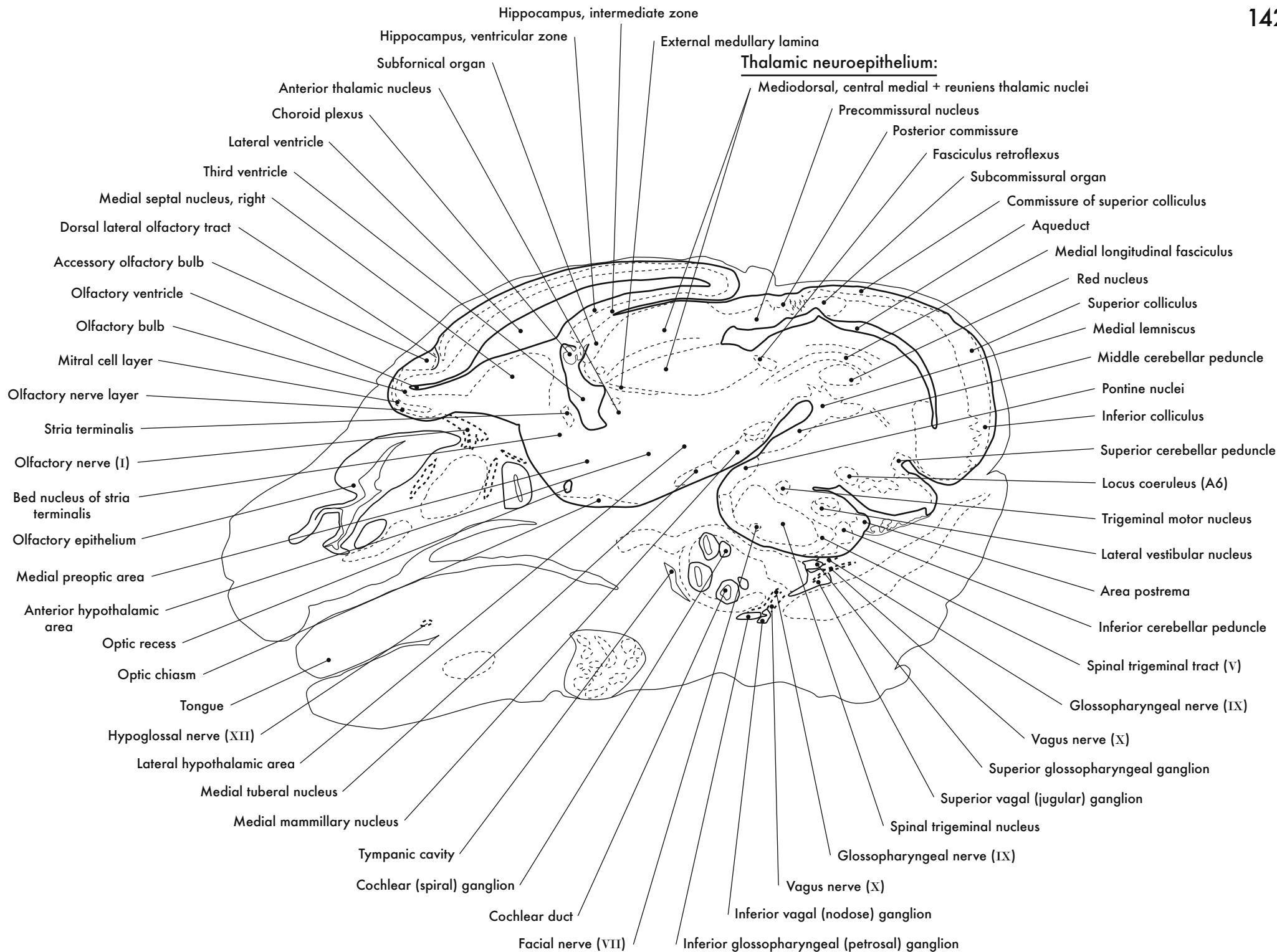
**Thalamic neuroepithelium:**

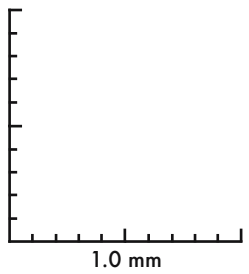
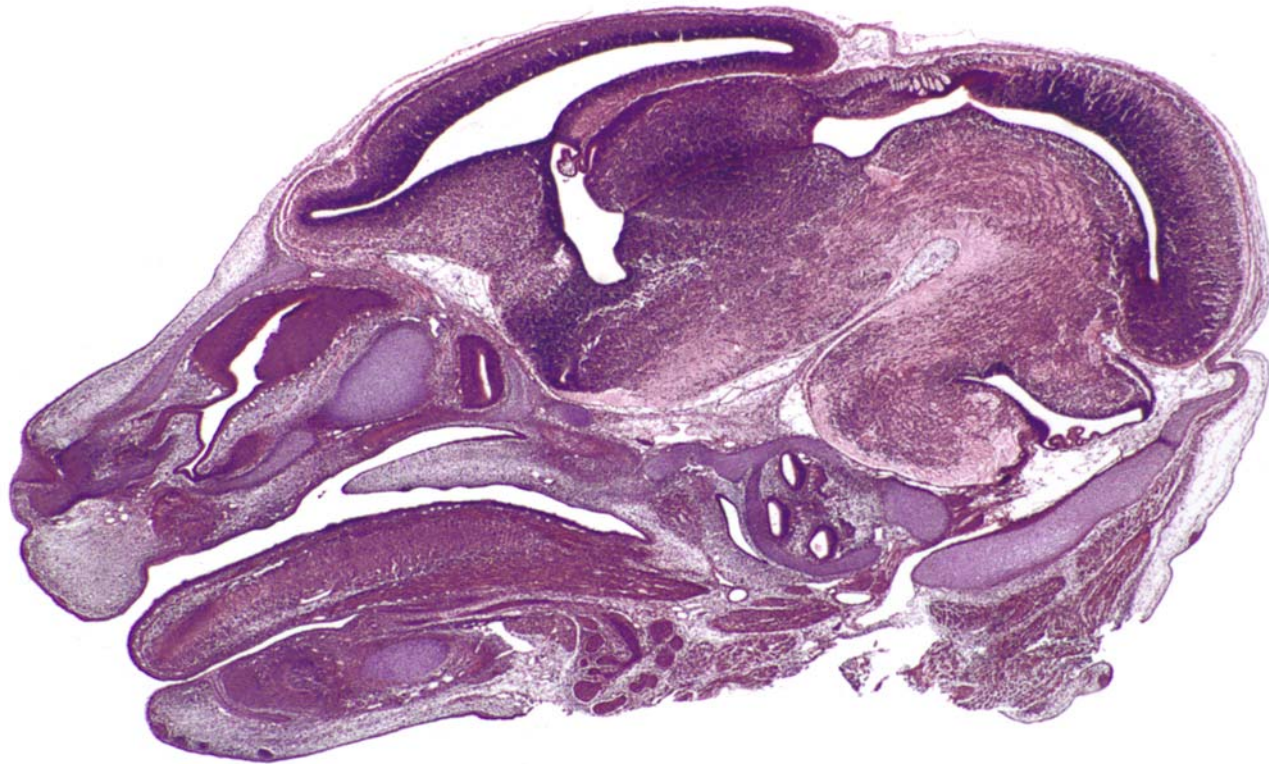
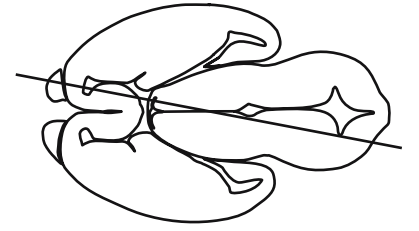






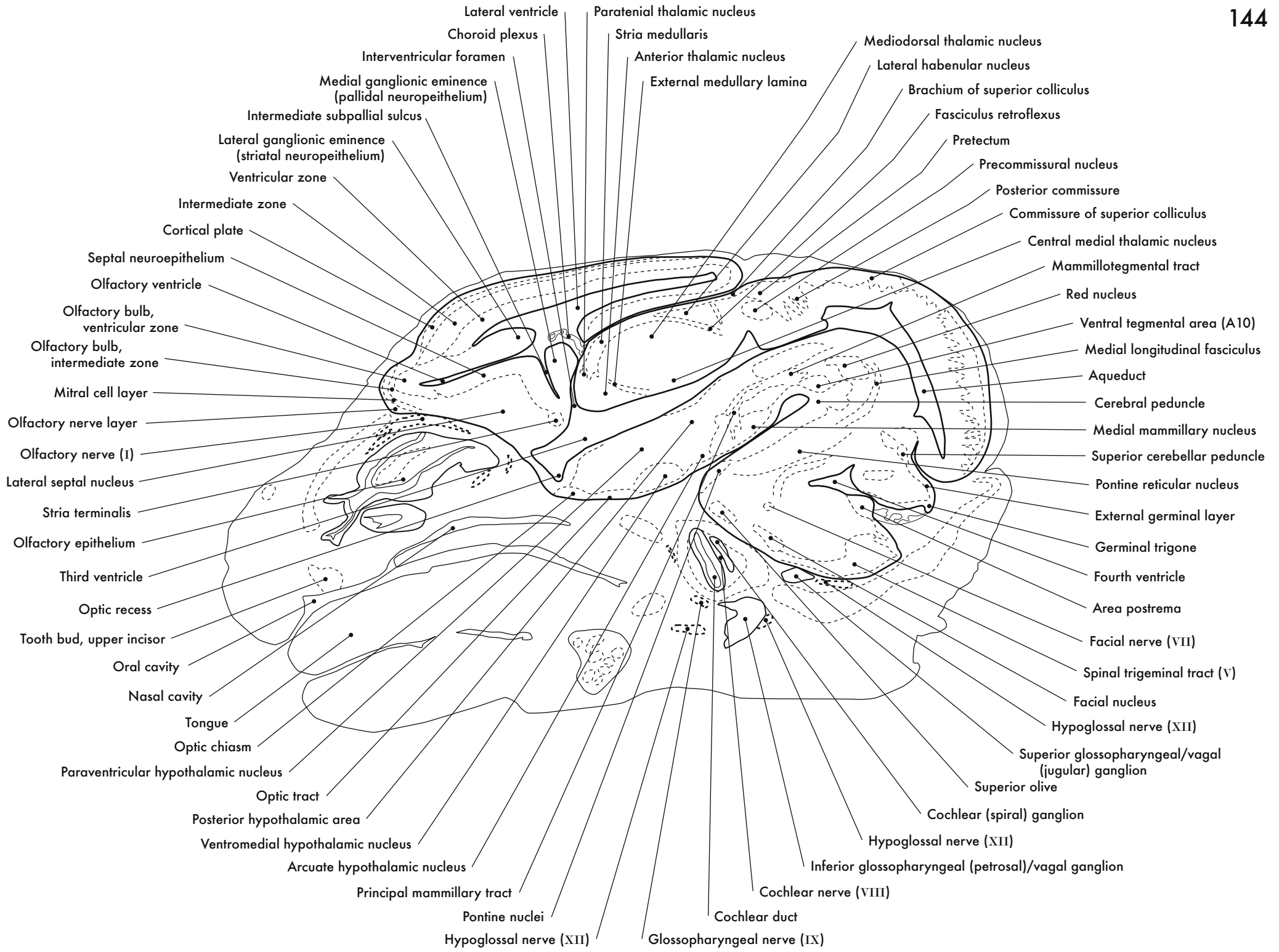
GD 14 SAGITTAL 11



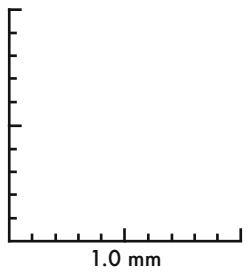
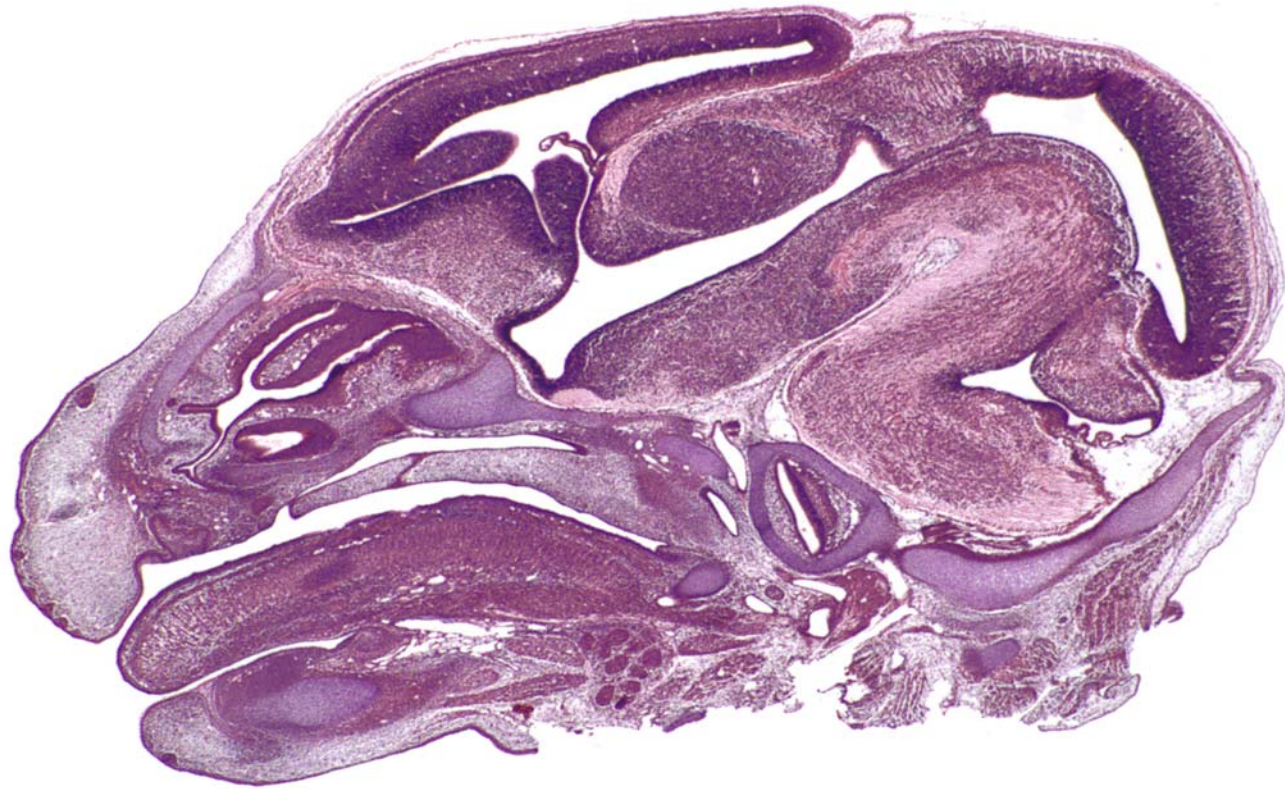
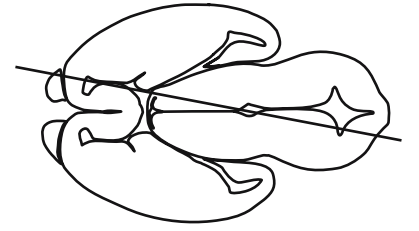


GD 14 SAGITTAL 12

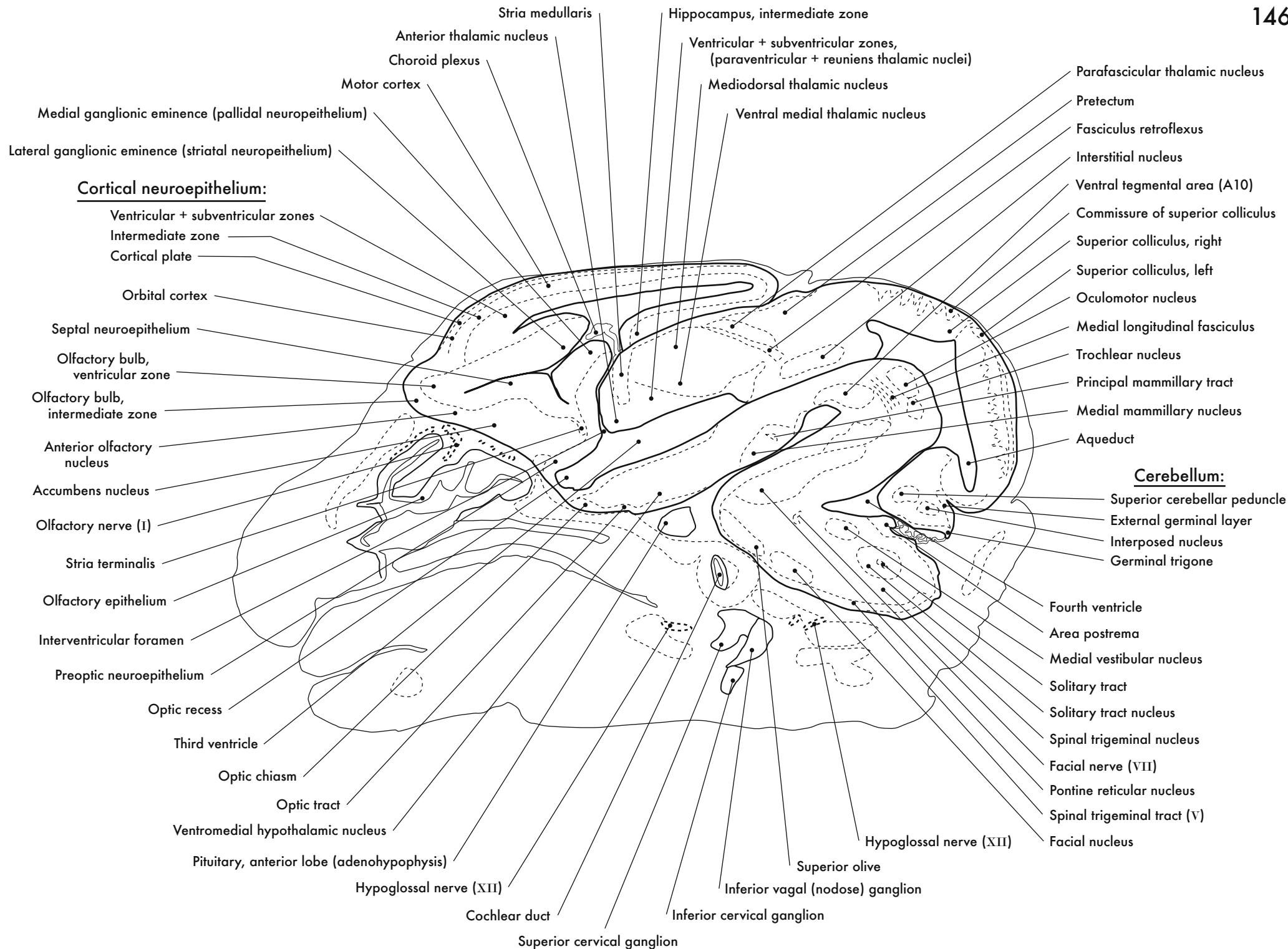


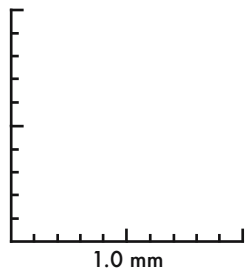
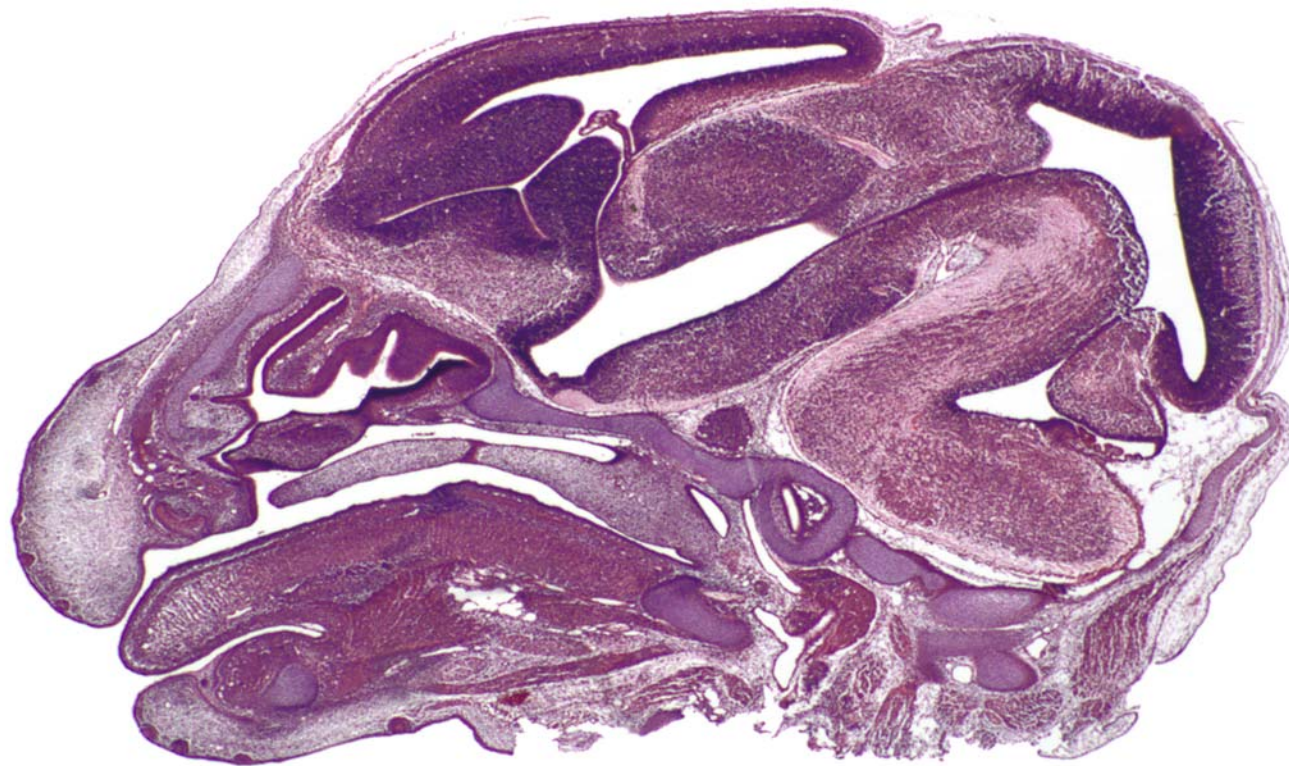
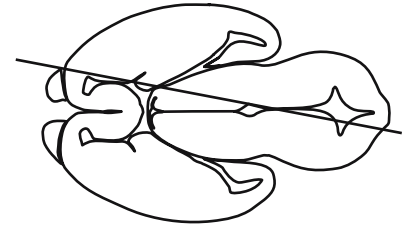






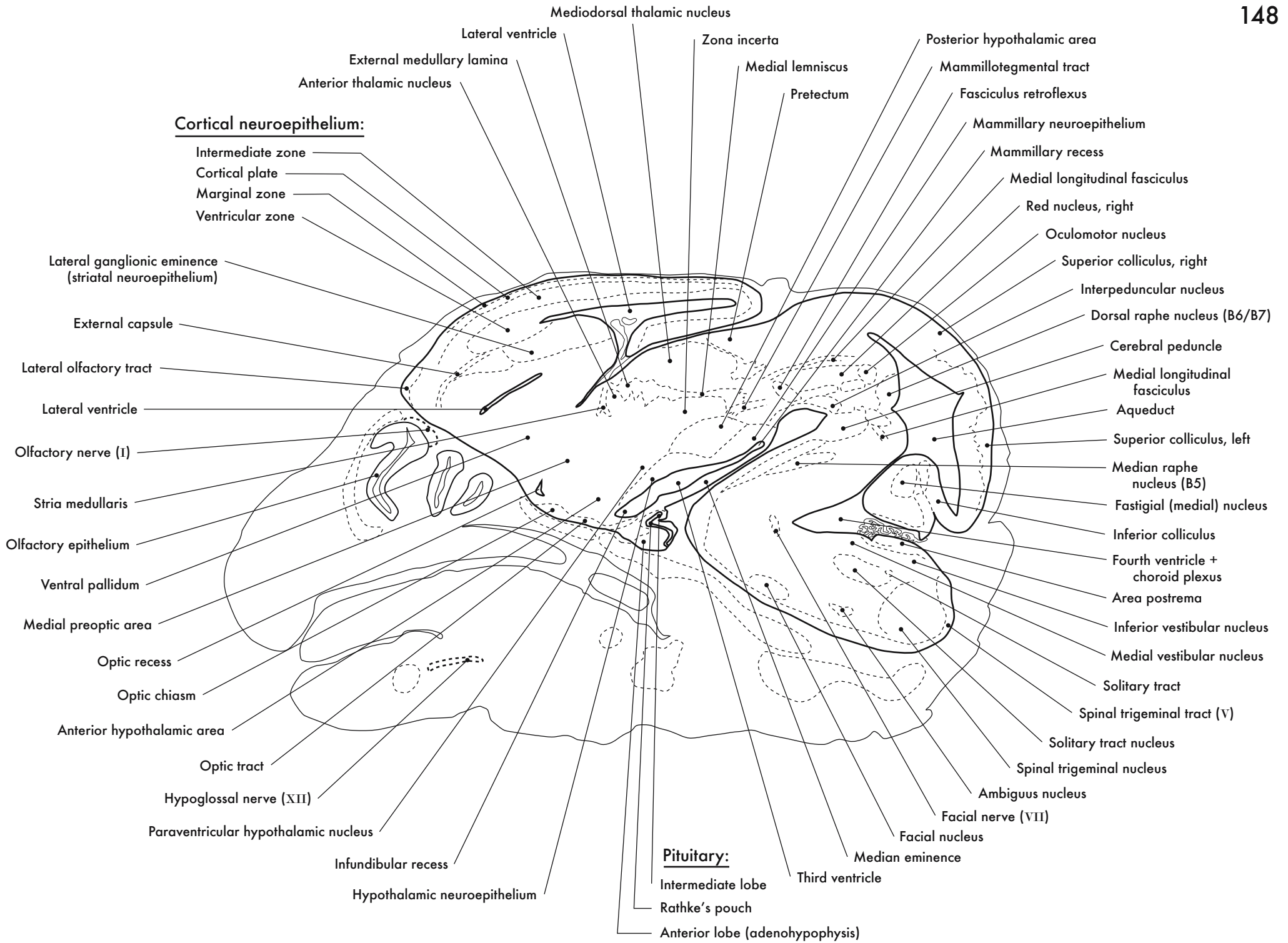
GD 14 SAGITTAL 13



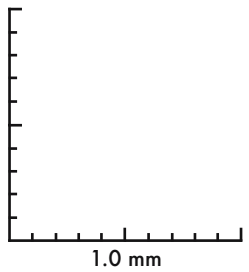
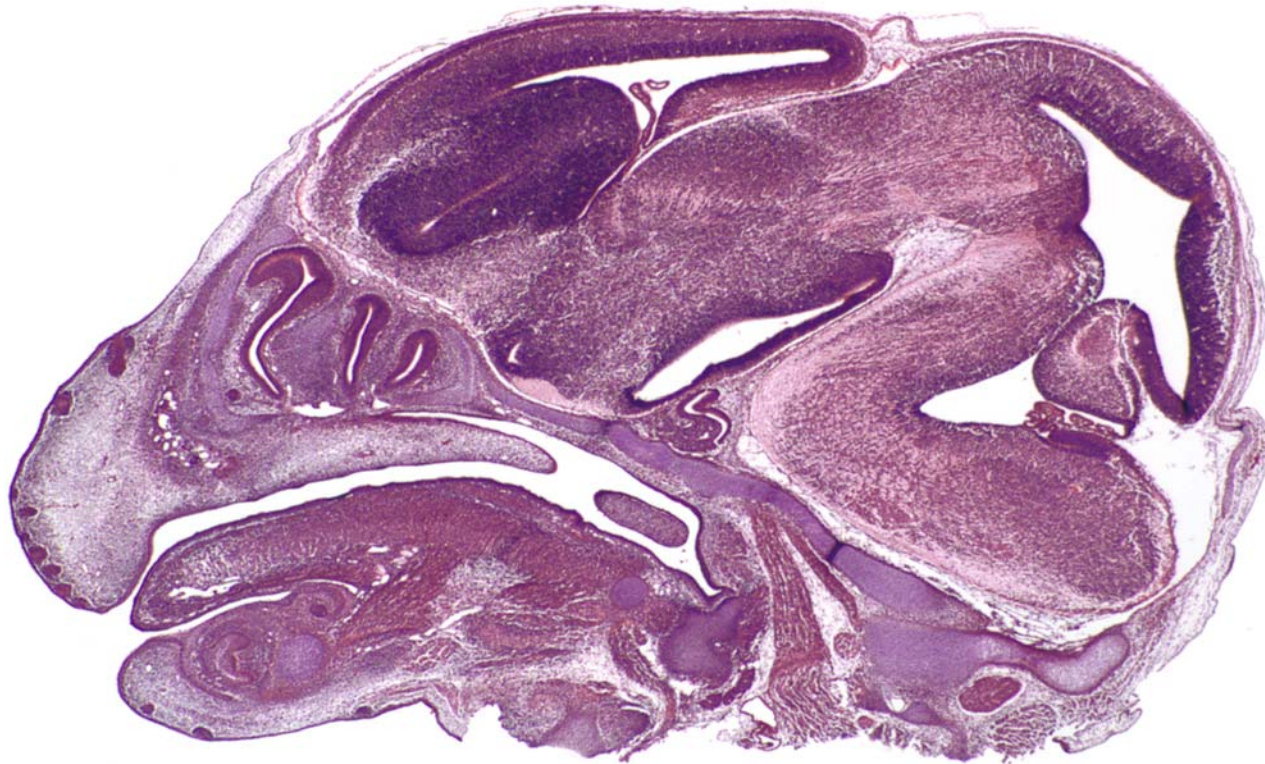
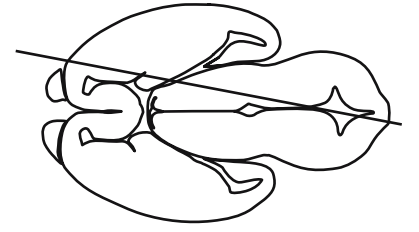


GD 14 SAGITTAL 14

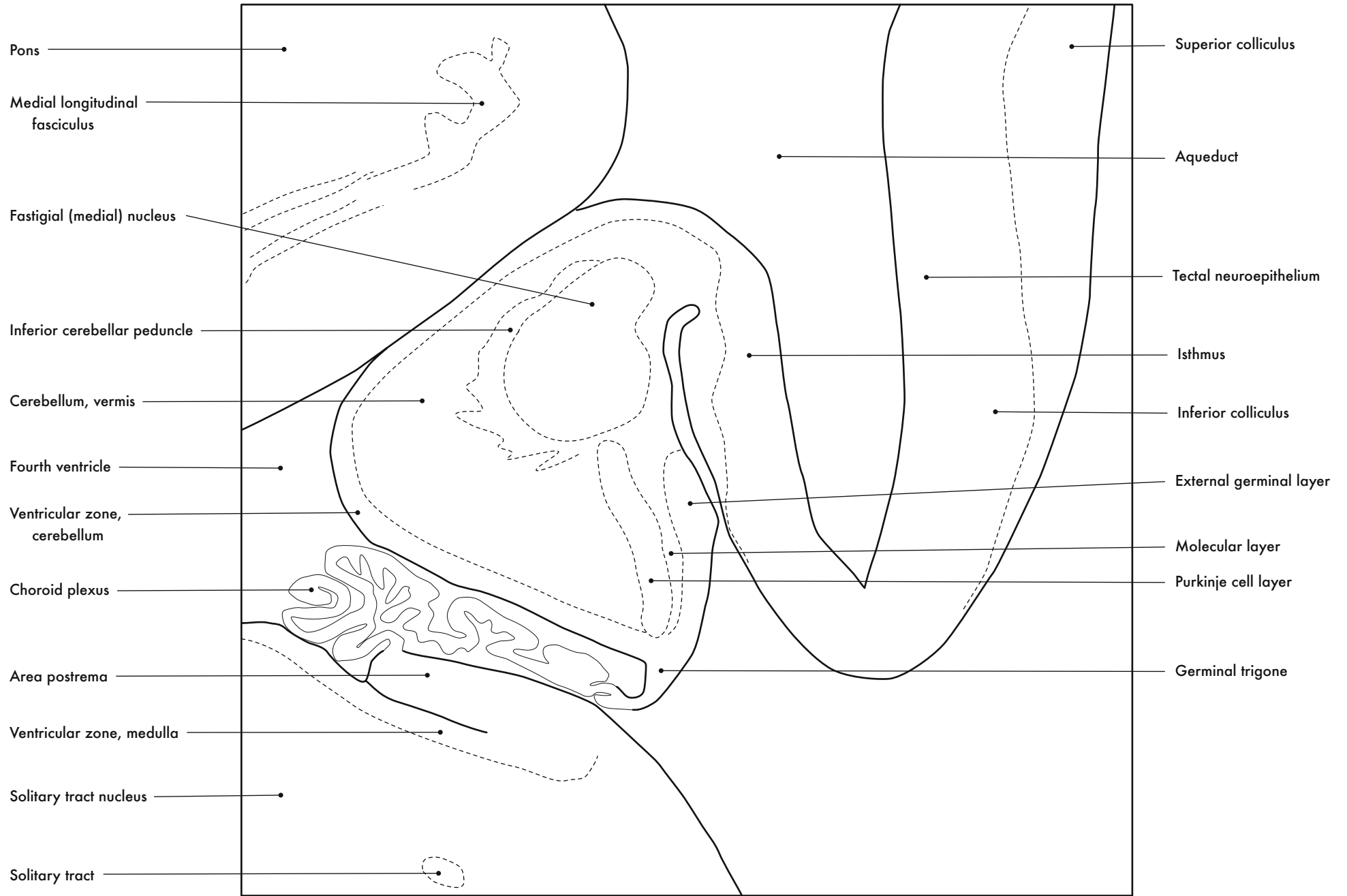








GD 14 SAGITTAL 15



Pons

Medial longitudinal fasciculus

Fastigial (medial) nucleus

Inferior cerebellar peduncle

Cerebellum, vermis

Fourth ventricle

Ventricular zone, cerebellum

Choroid plexus

Area postrema

Ventricular zone, medulla

Solitary tract nucleus

Solitary tract

Superior colliculus

Aqueduct

Tectal neuroepithelium

Isthmus

Inferior colliculus

External germinal layer

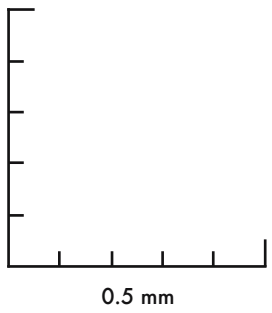
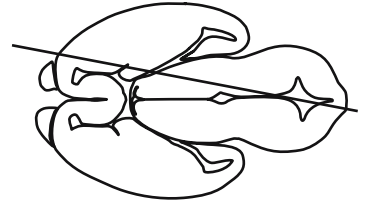
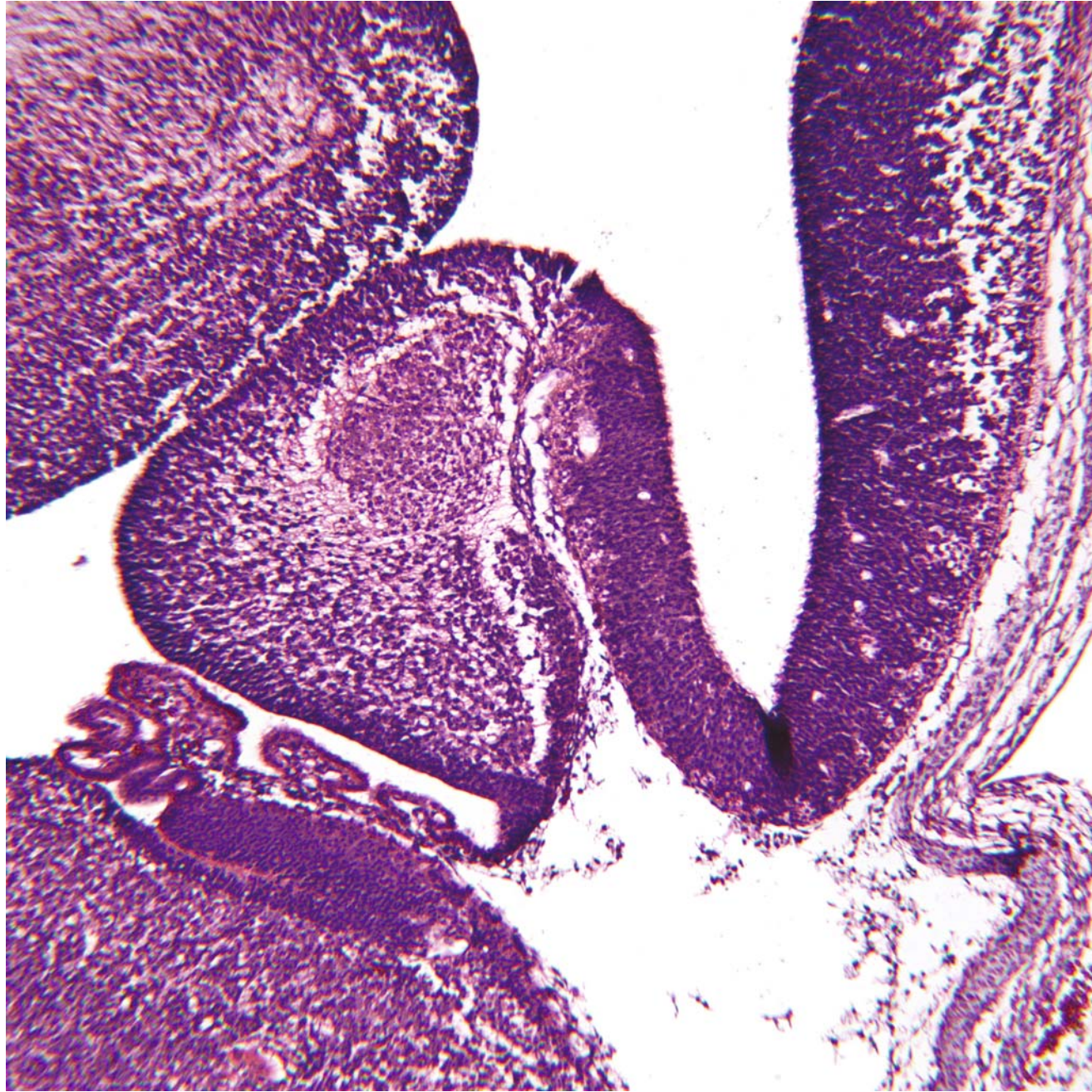
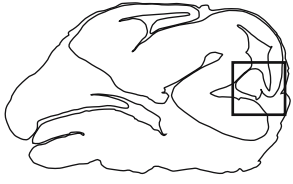
Molecular layer

Purkinje cell layer

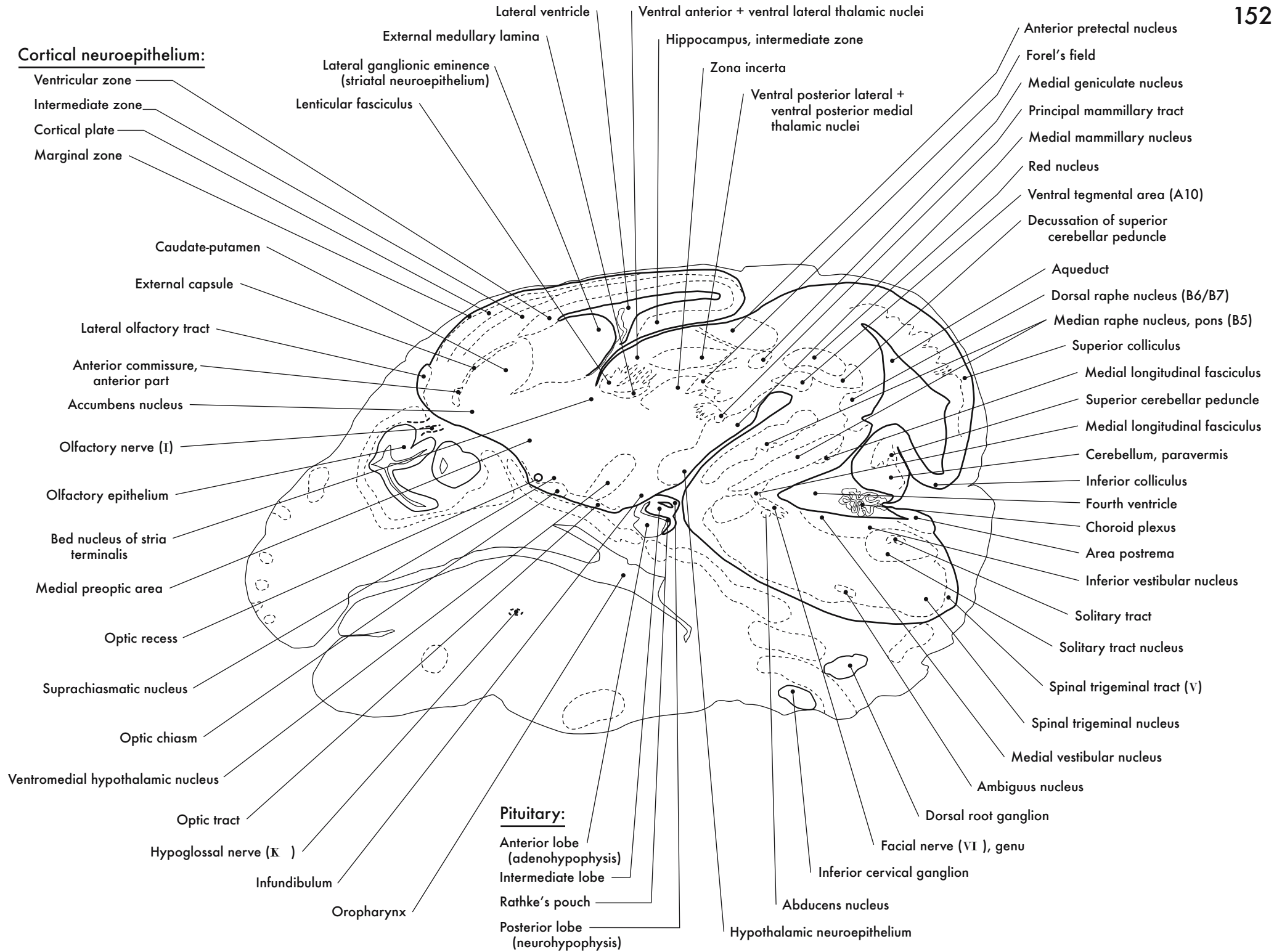
Germinal trigone

Cerebellum

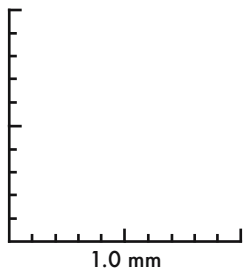
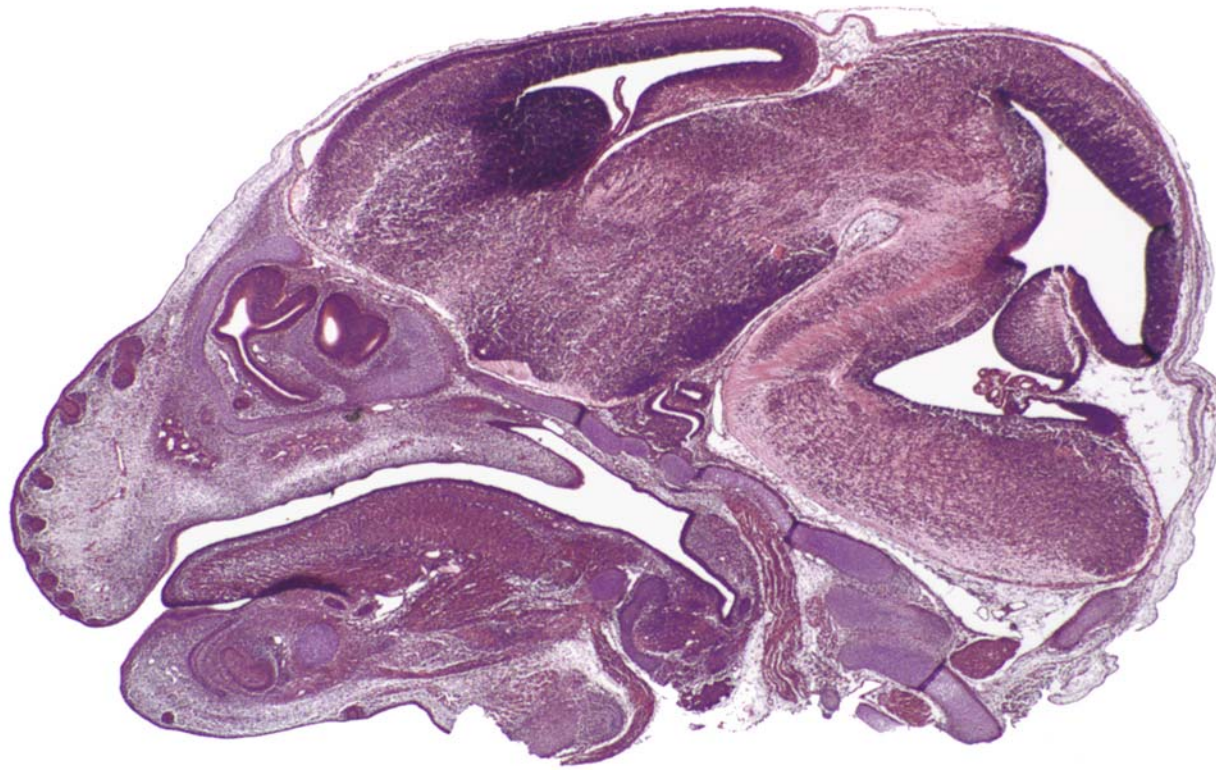
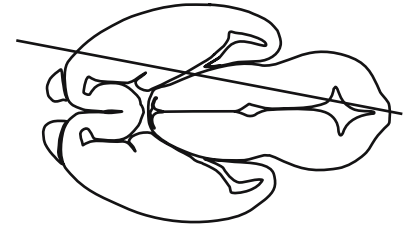




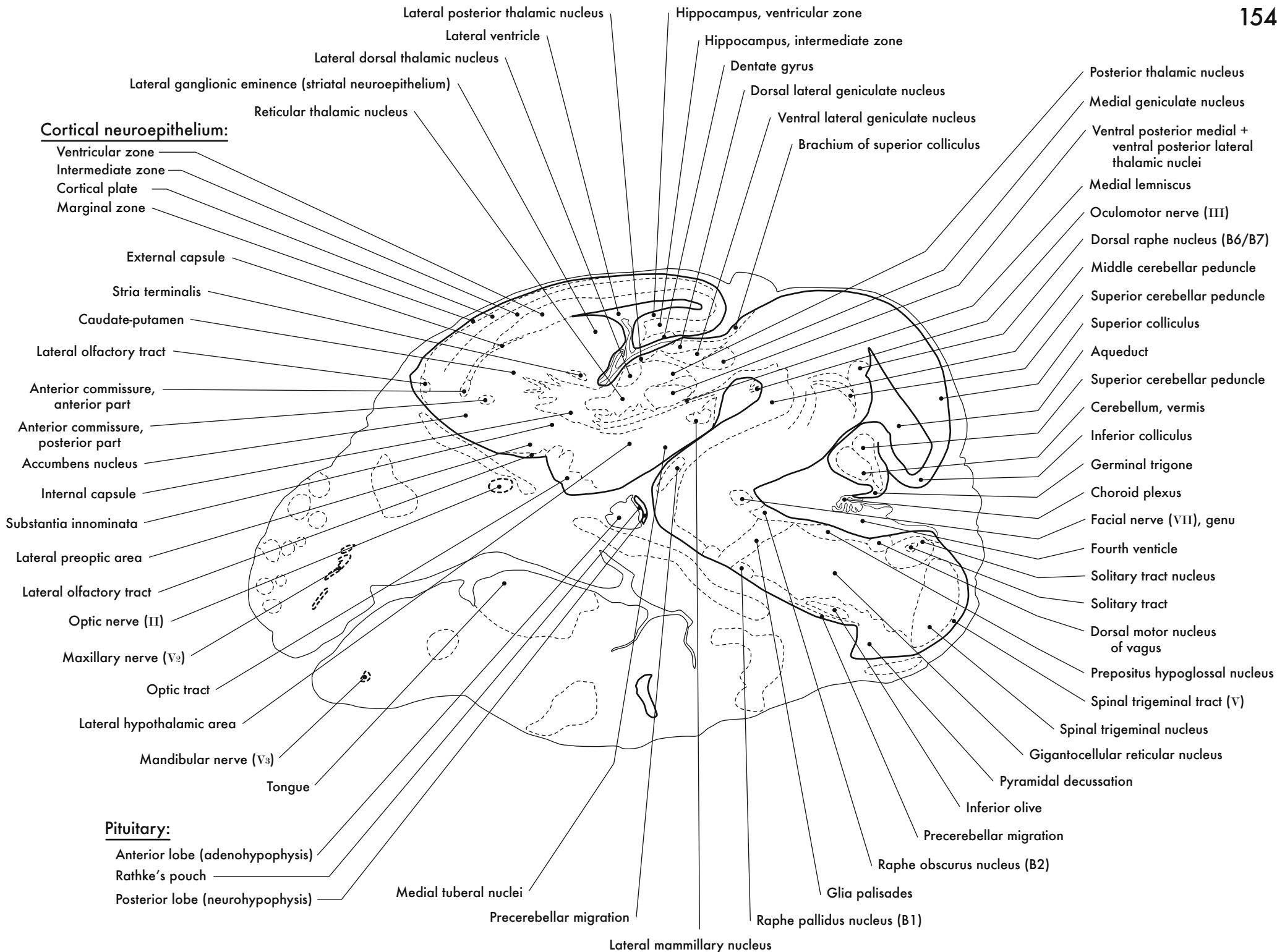
GD 14 SAGITTAL 16

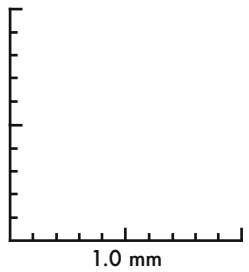
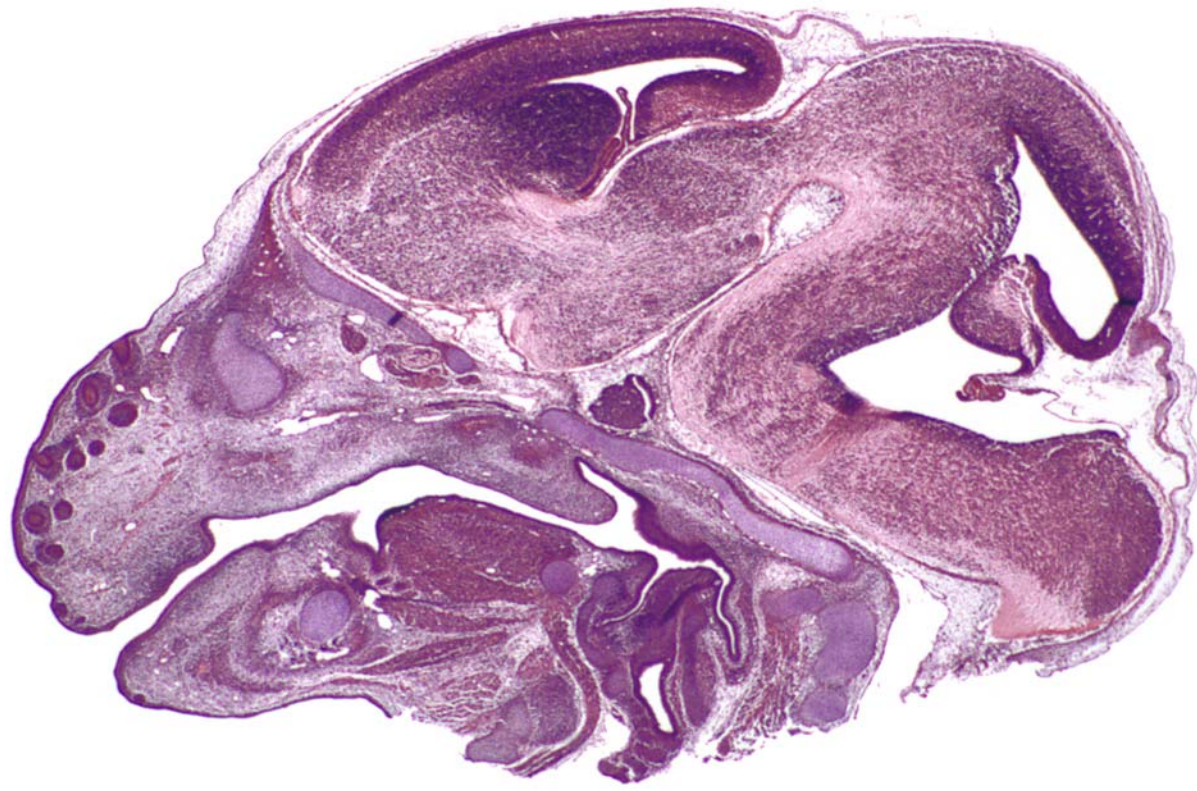
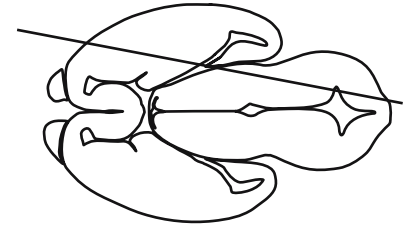






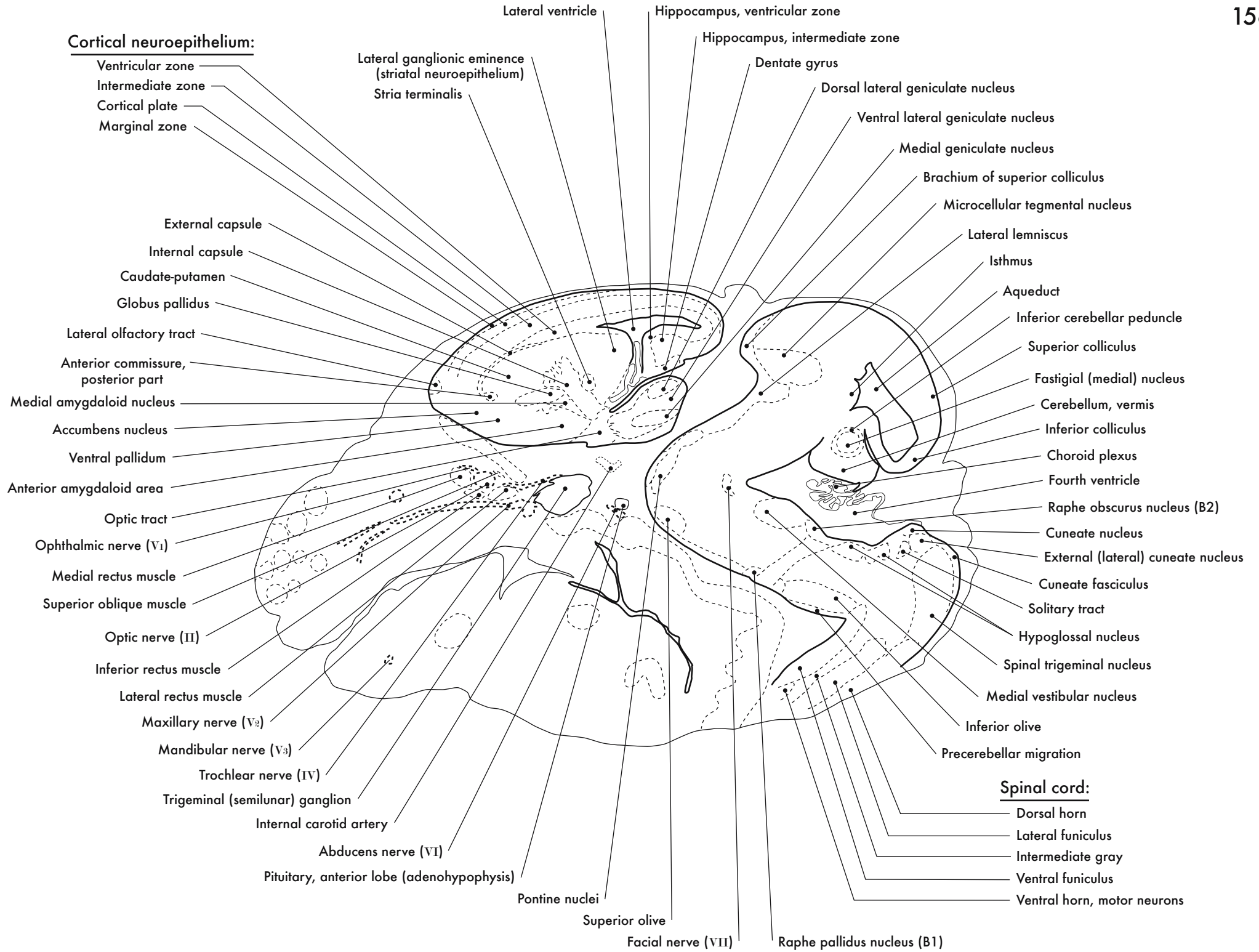
GD 14 SAGITTAL 17



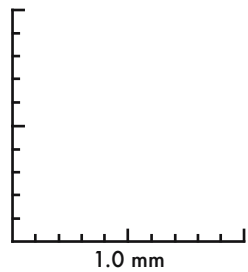
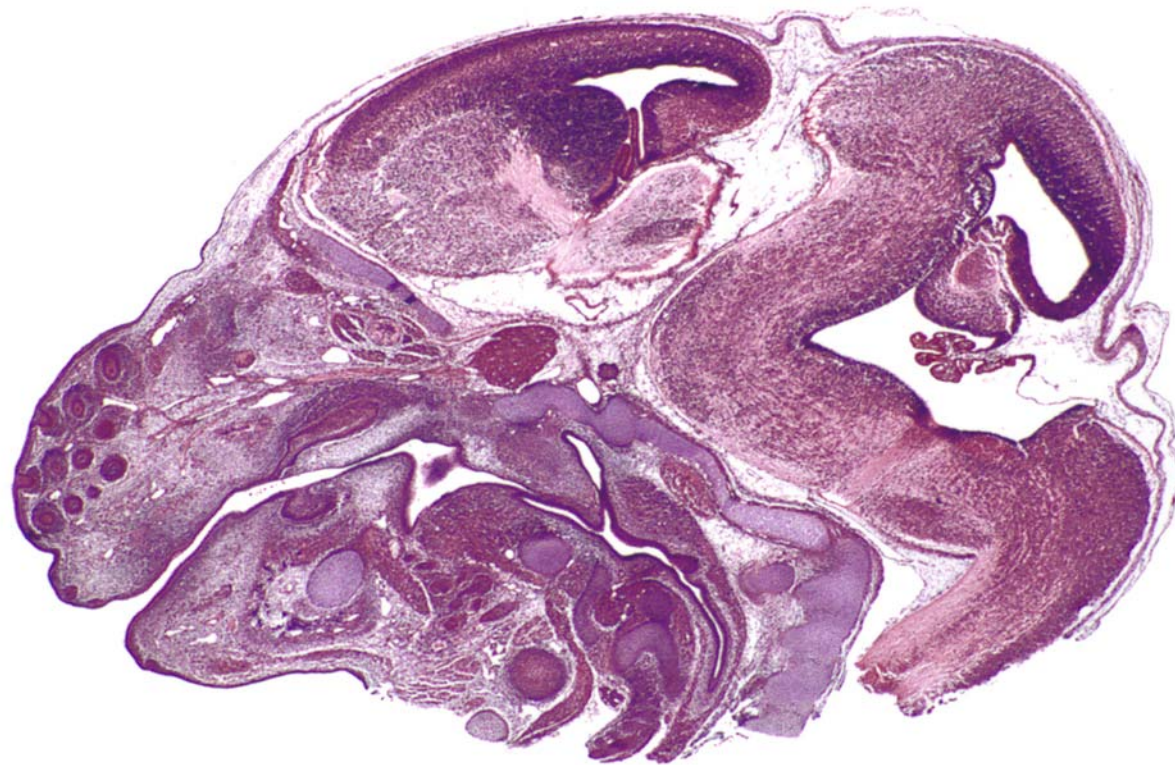
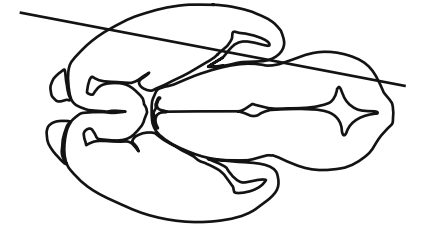


GD 14 SAGITTAL 18

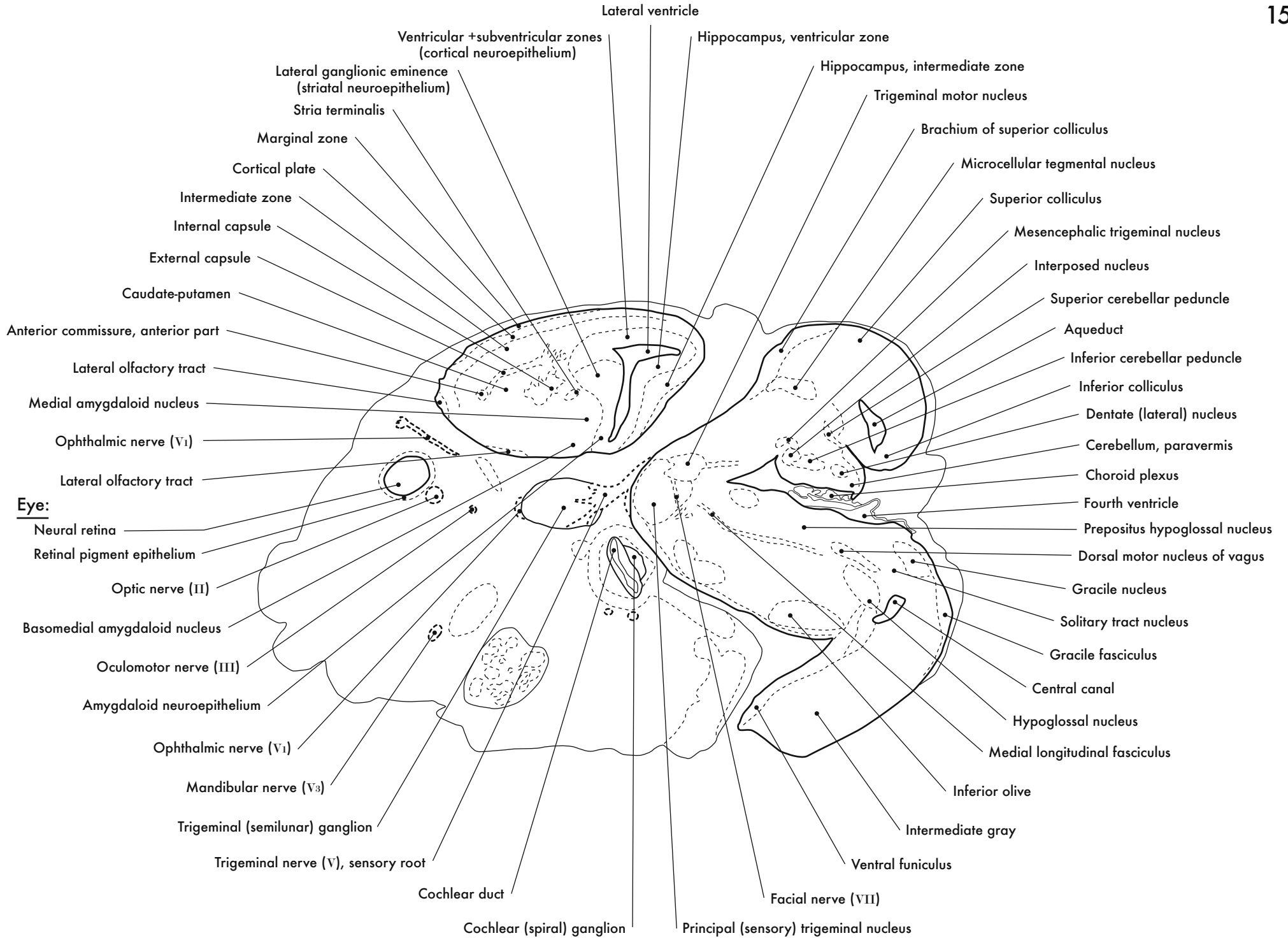


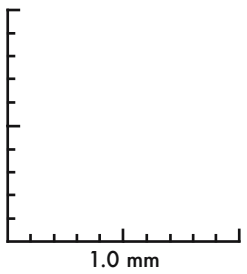
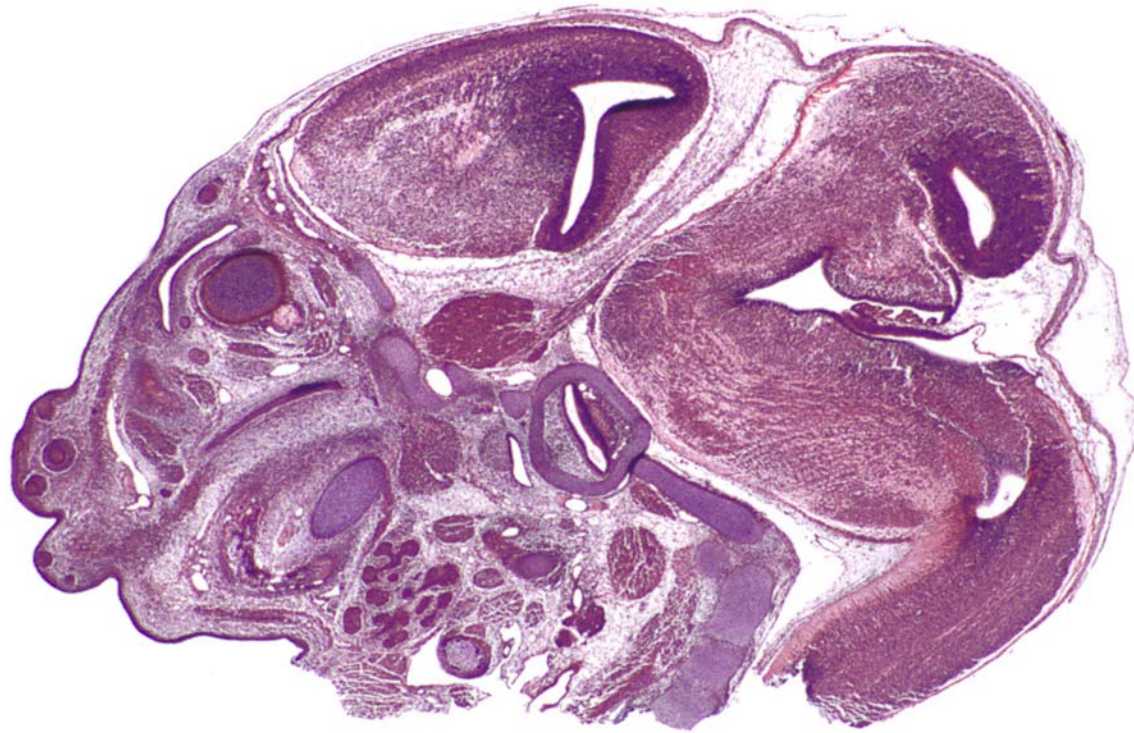
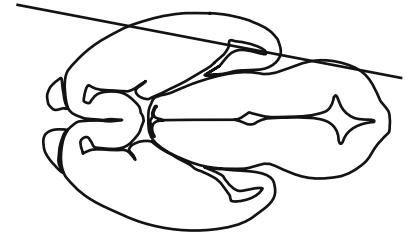






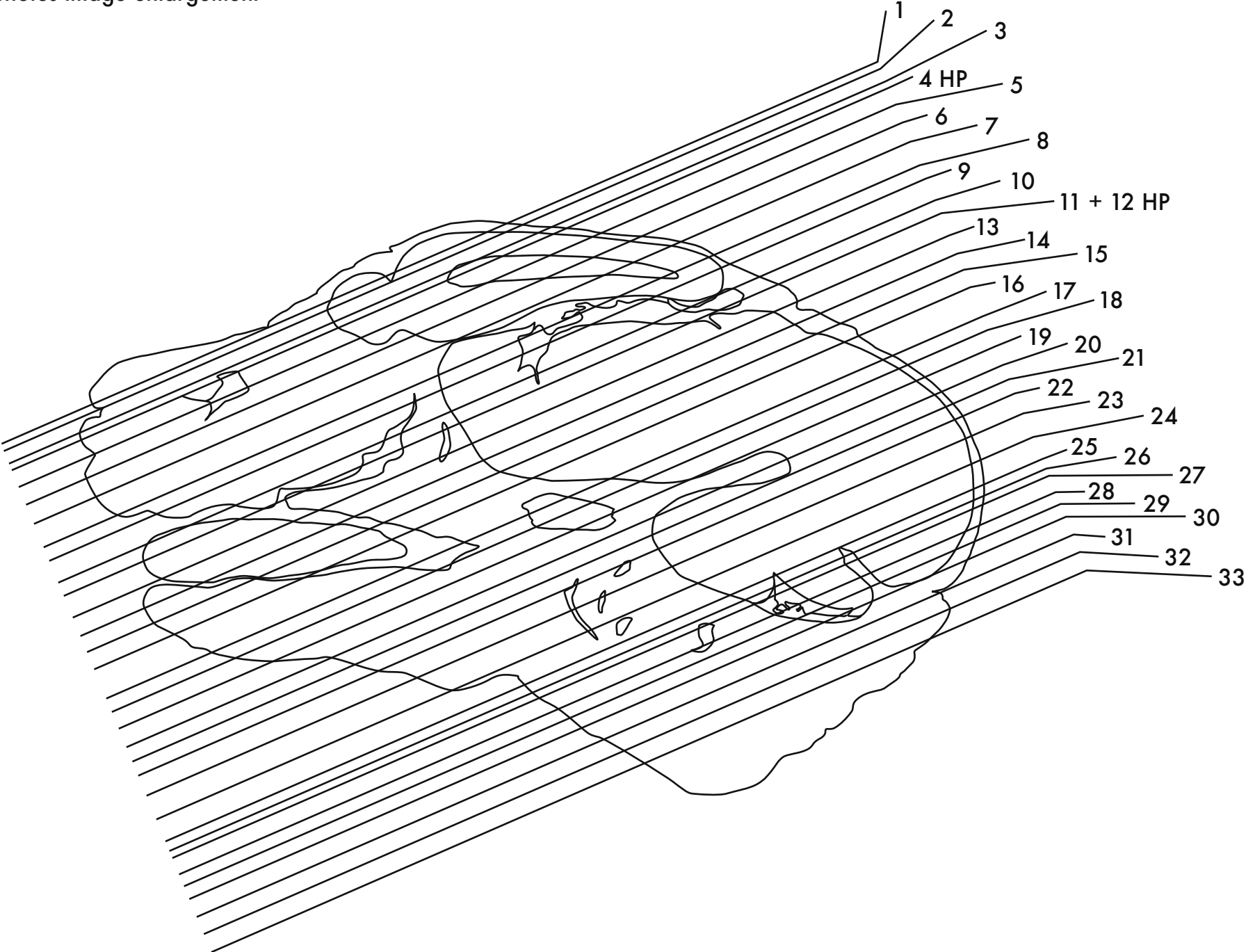
GD 14 SAGITTAL 19





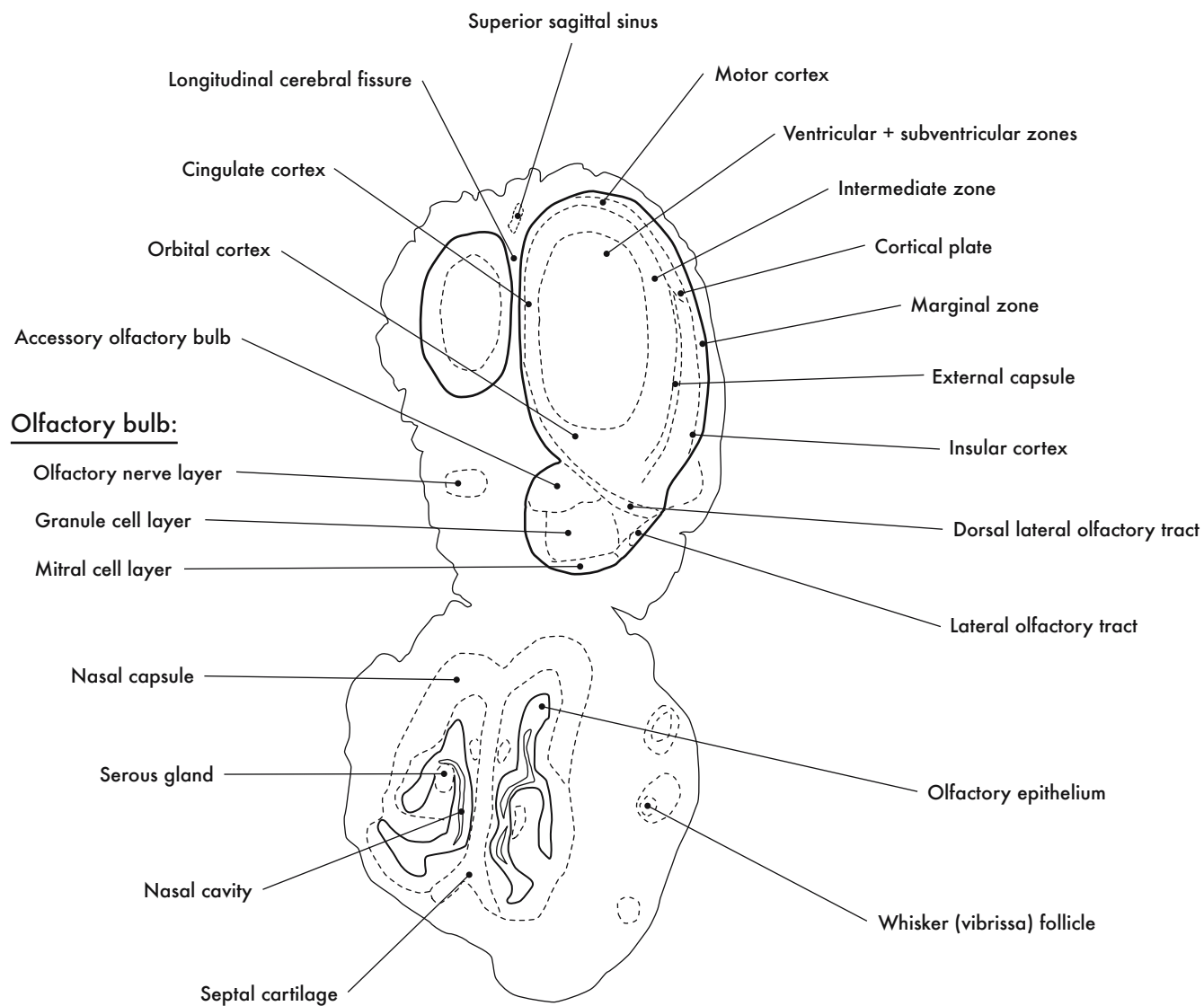
GD 14 SAGITTAL 20

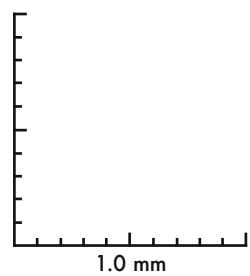
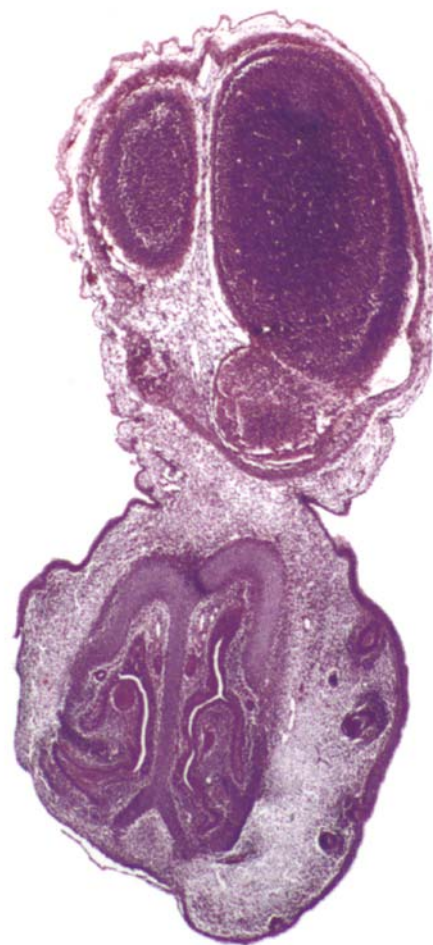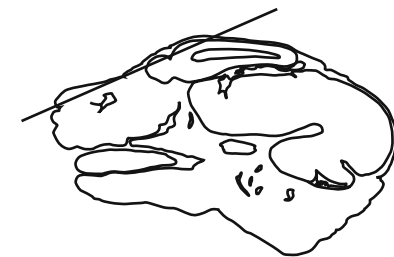
HP denotes image enlargement



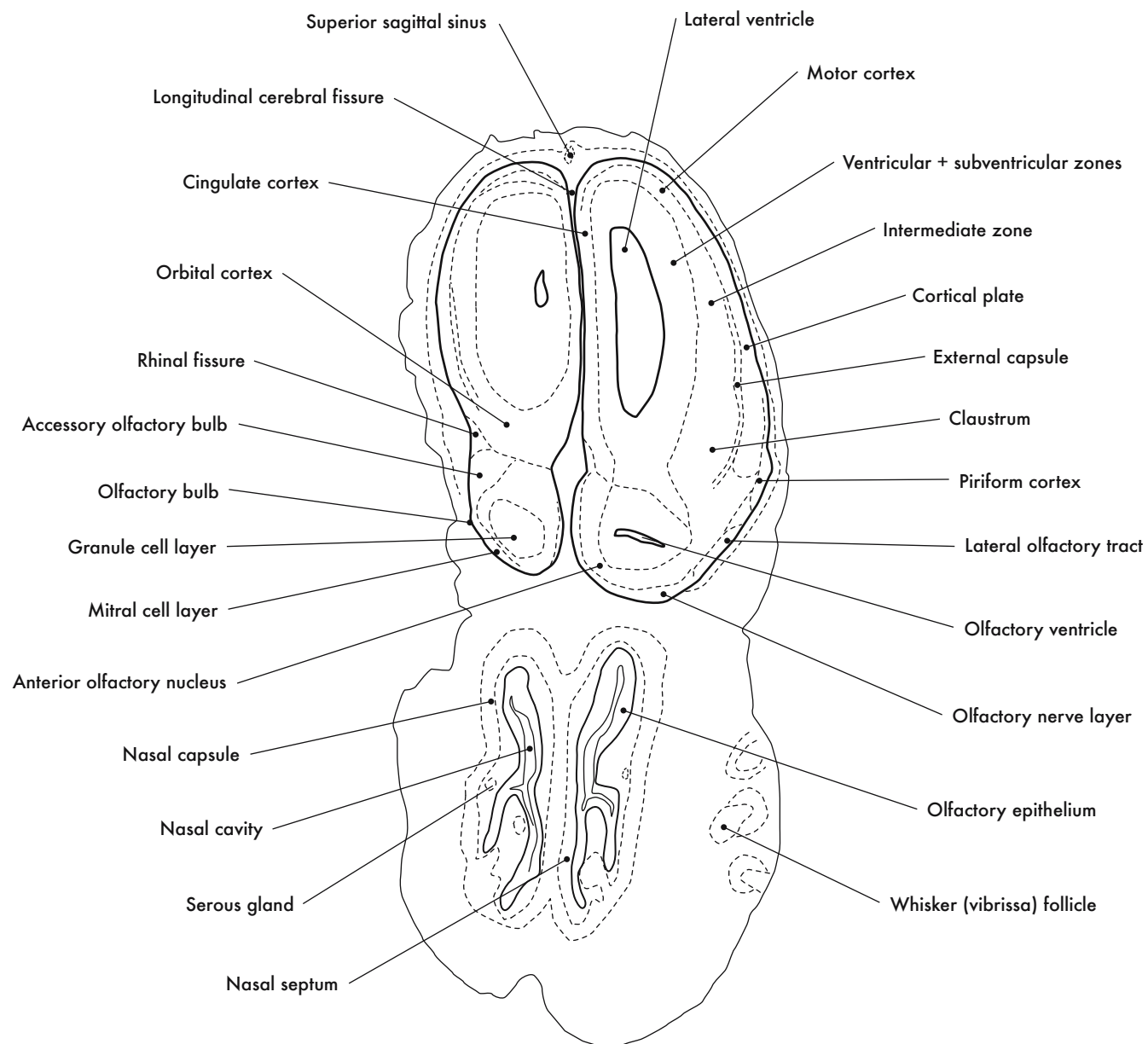
**GESTATIONAL DAY 14 (GD 14)  
CORONAL SECTIONS**

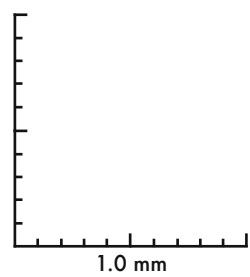
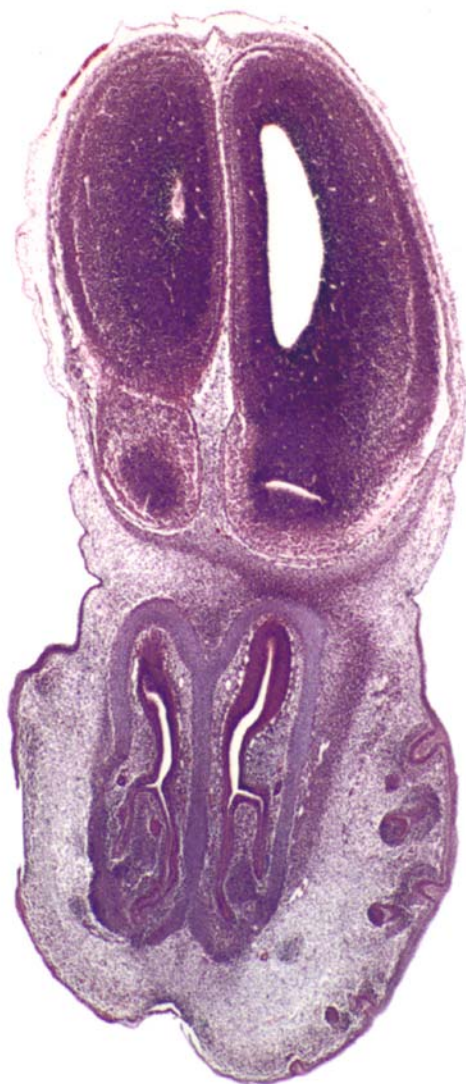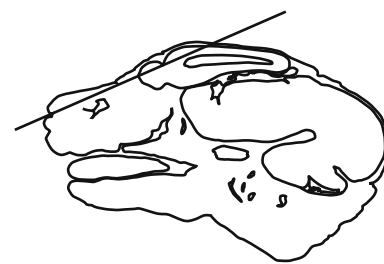






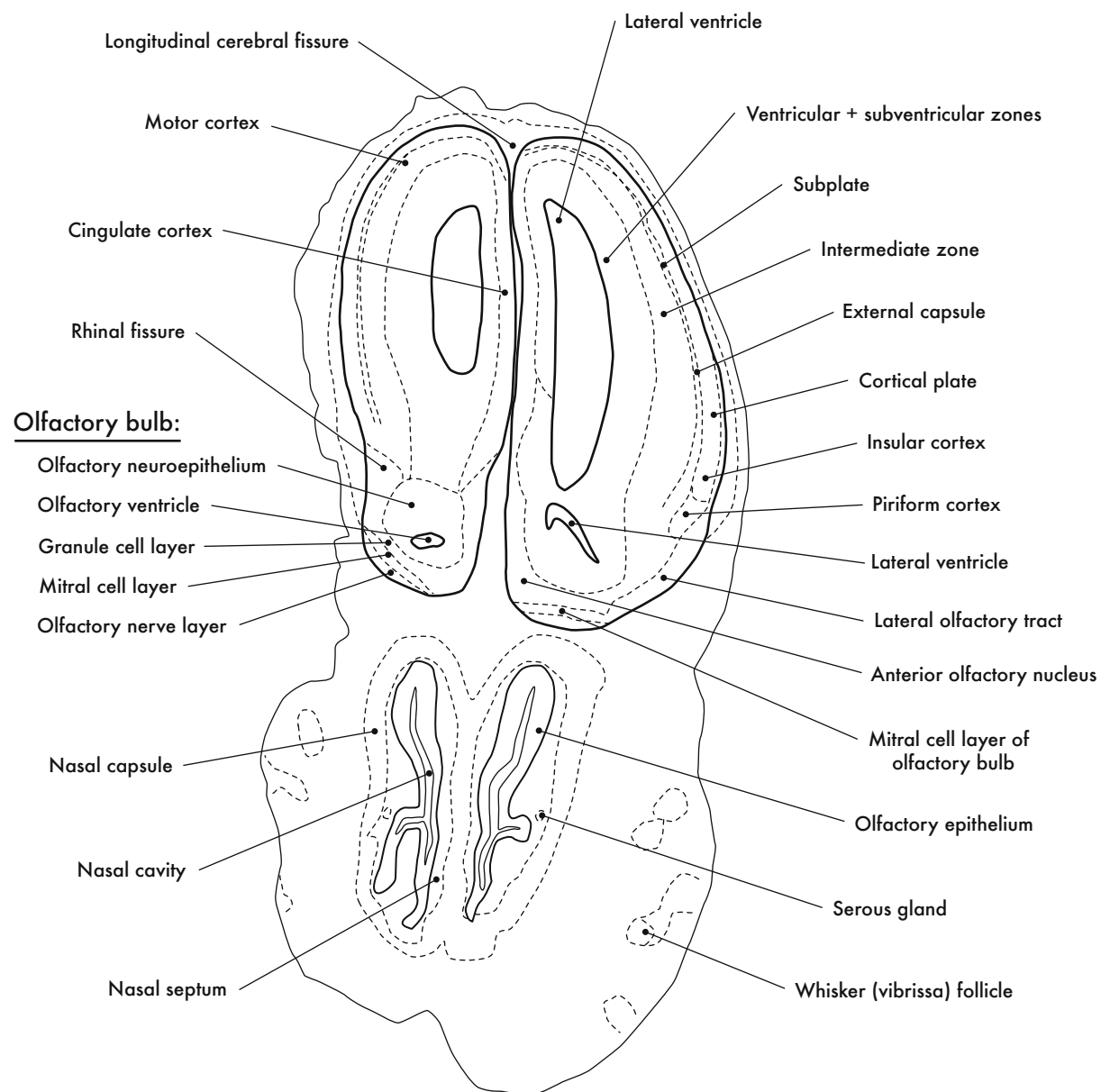
GD 14 CORONAL 1

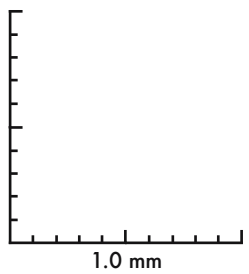
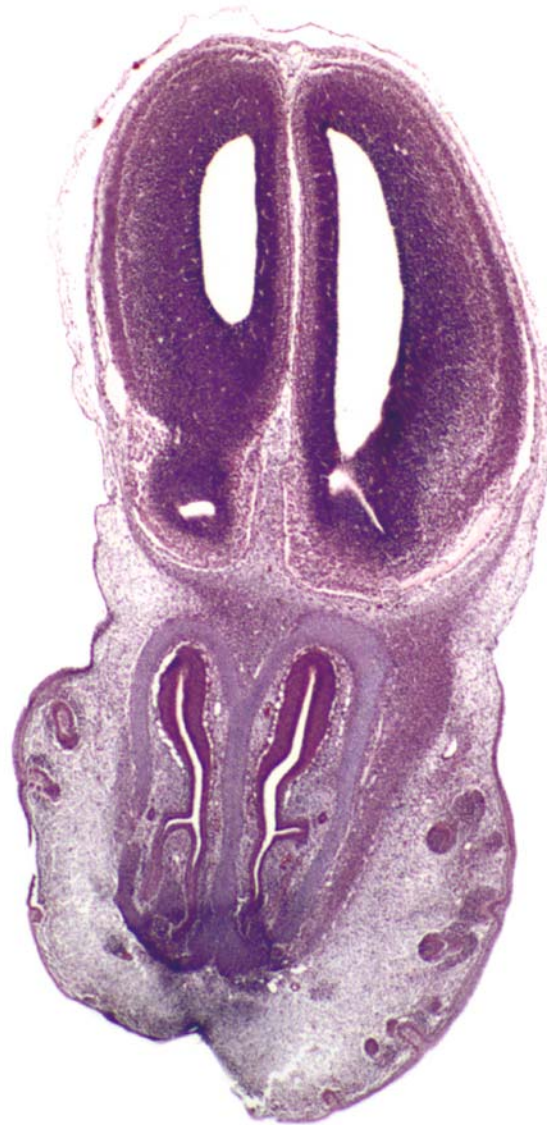
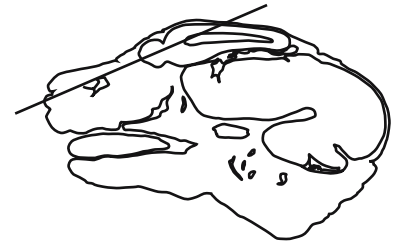


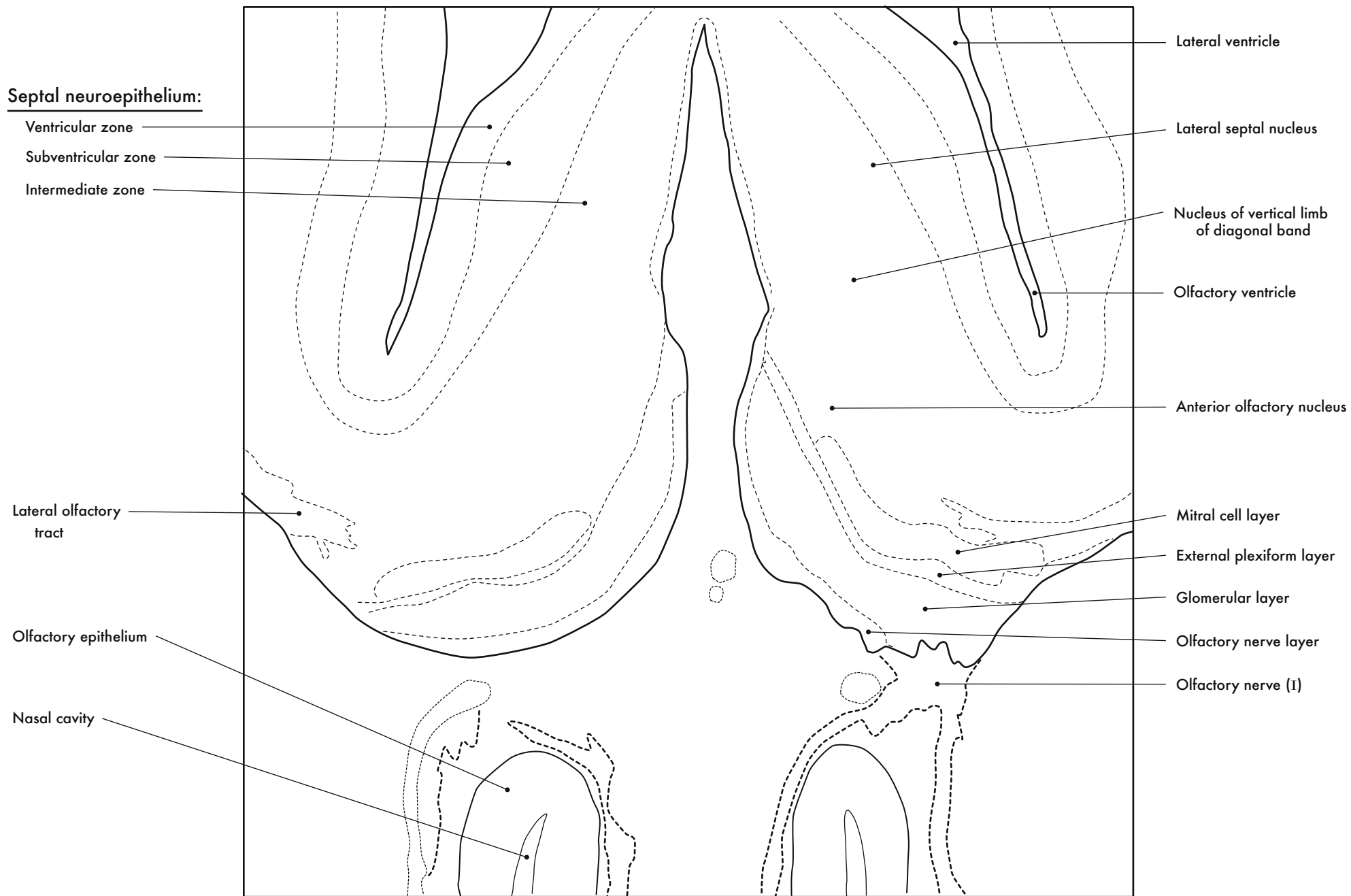
GD 14 CORONAL 2





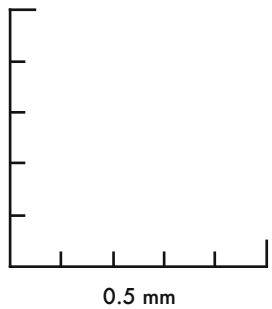
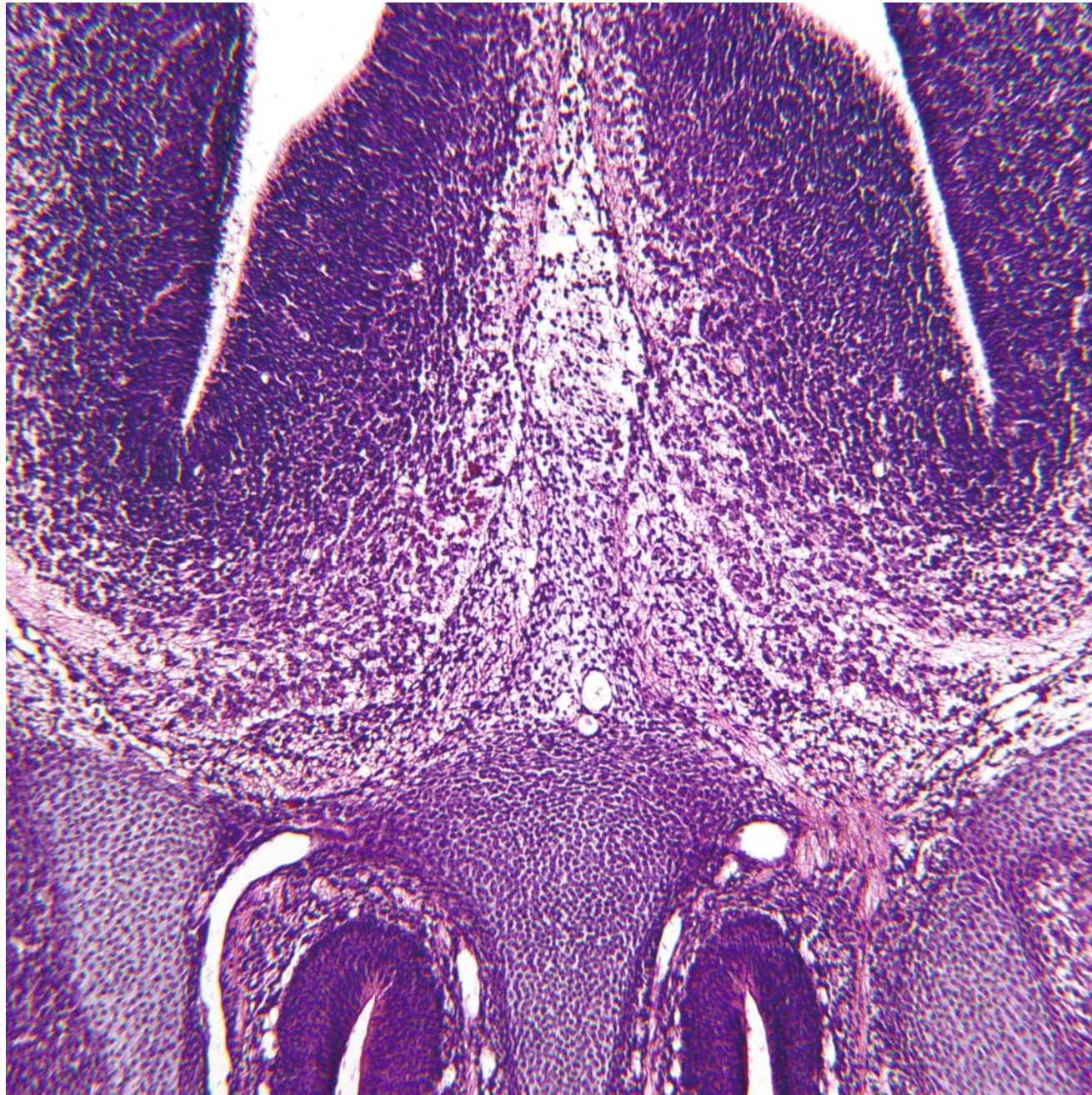
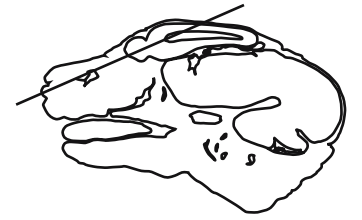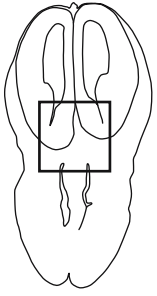


GD 14 CORONAL 3



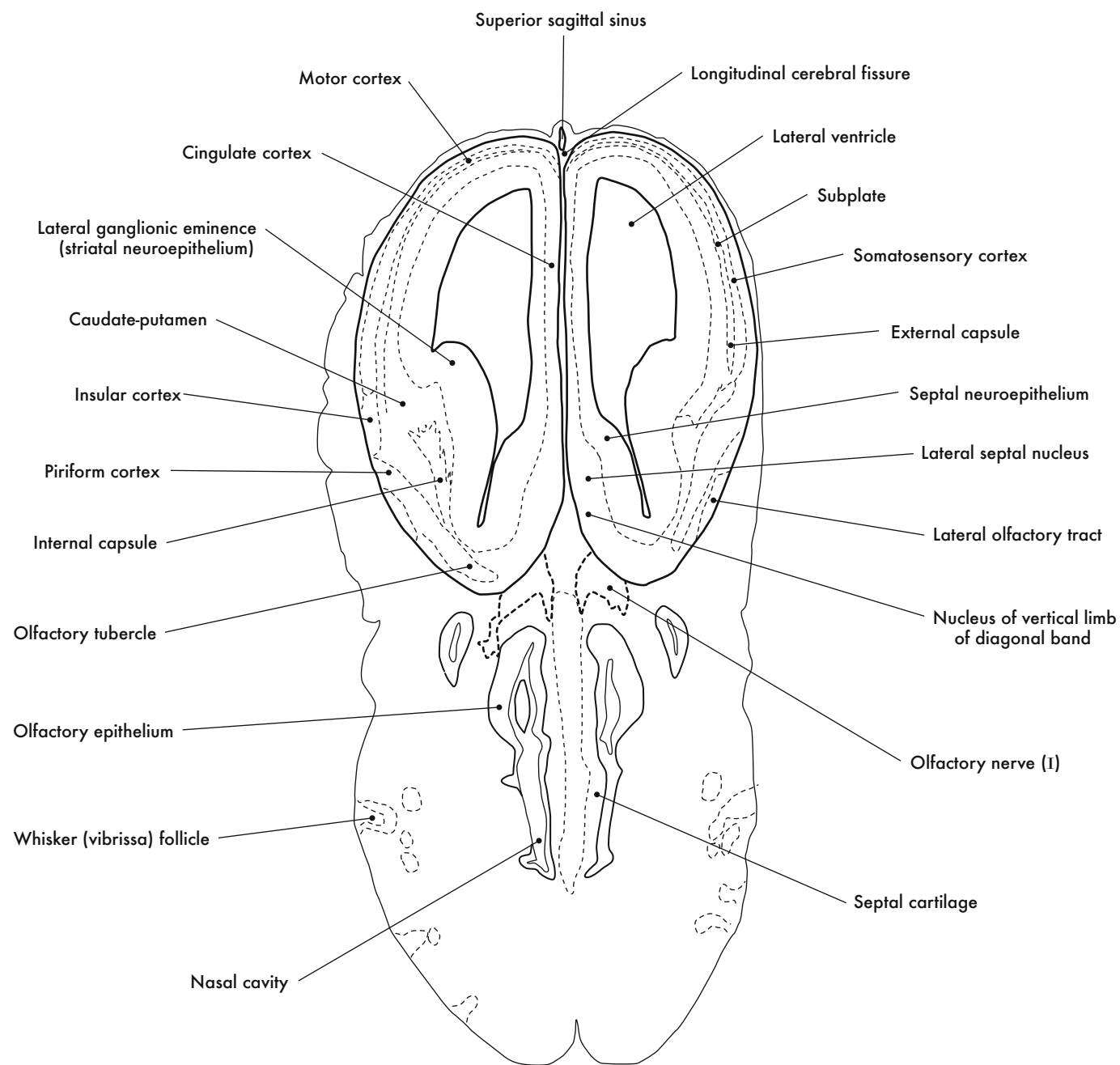
Olfactory Bulb, Olfactory Nerve and Septal Area

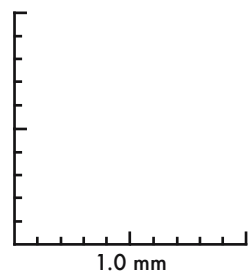
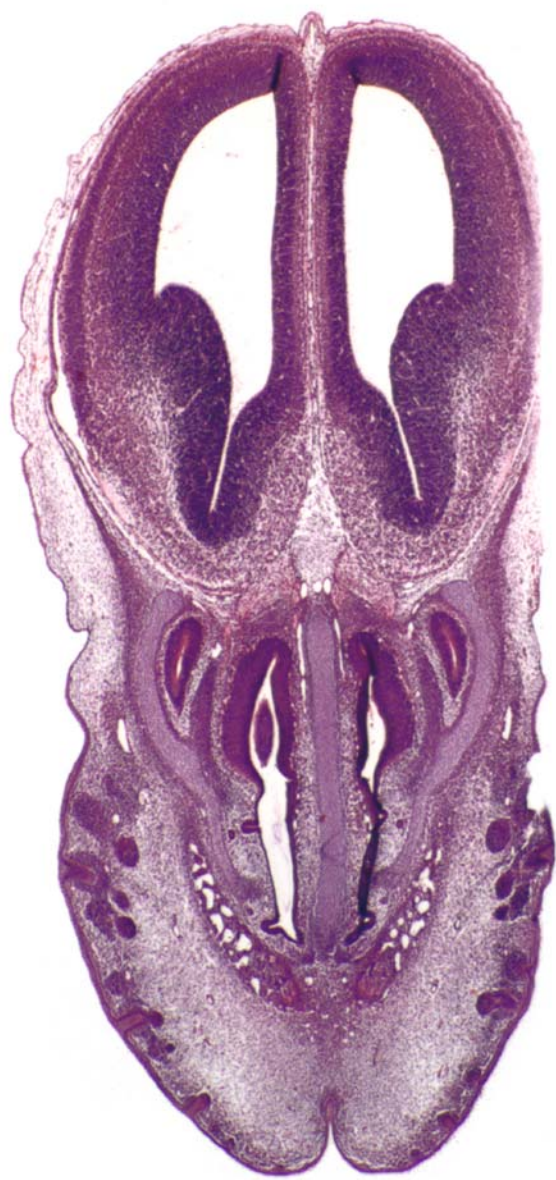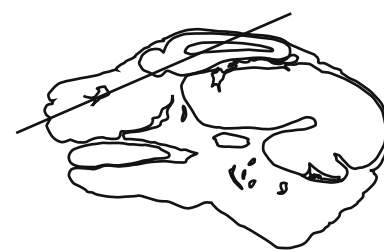




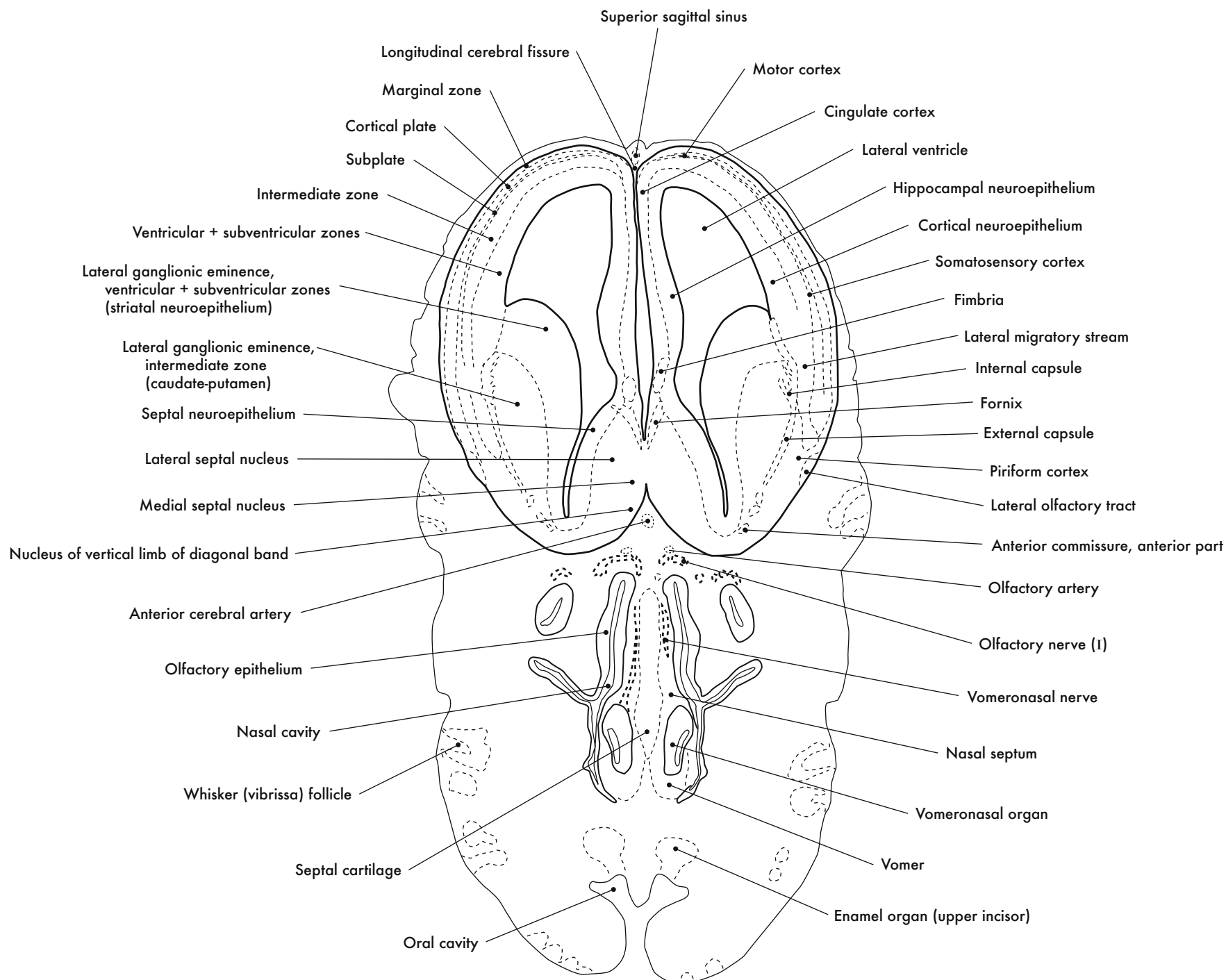
GD 14 CORONAL 4

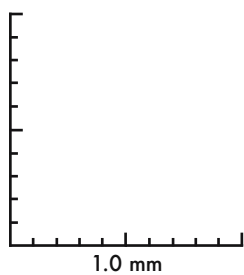
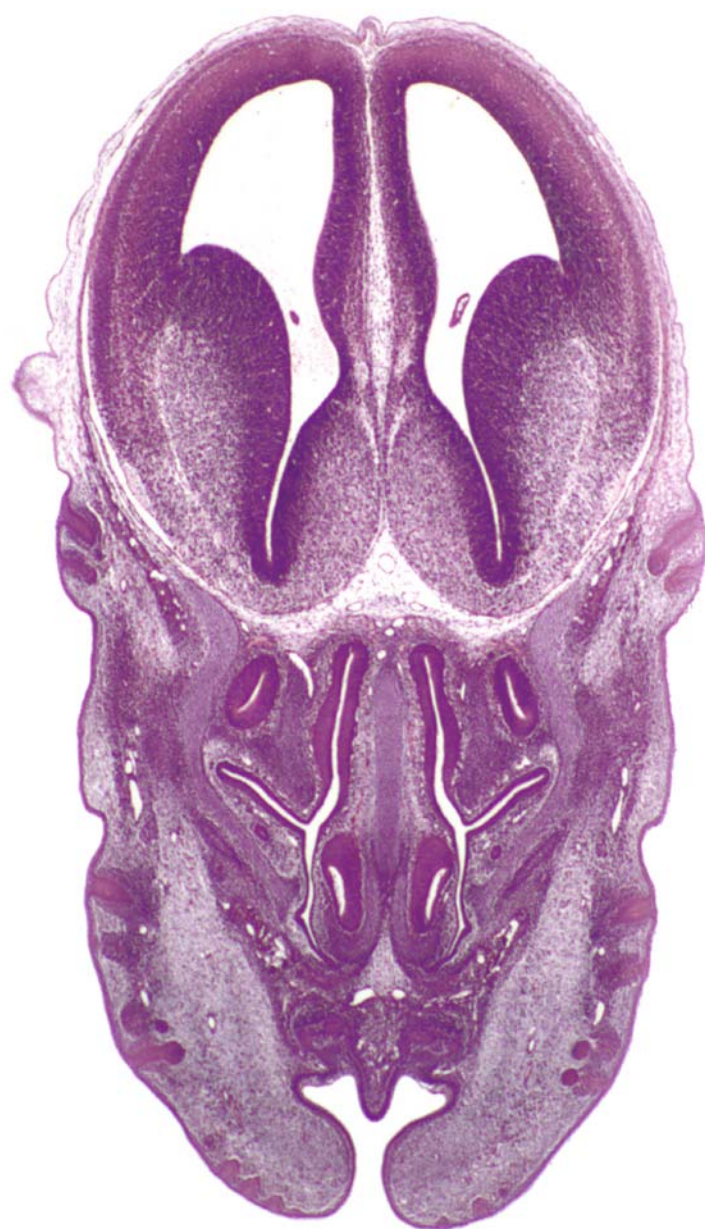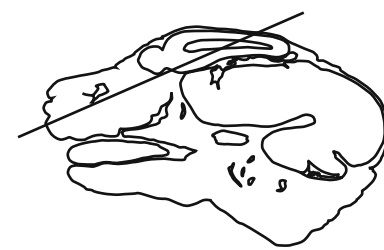






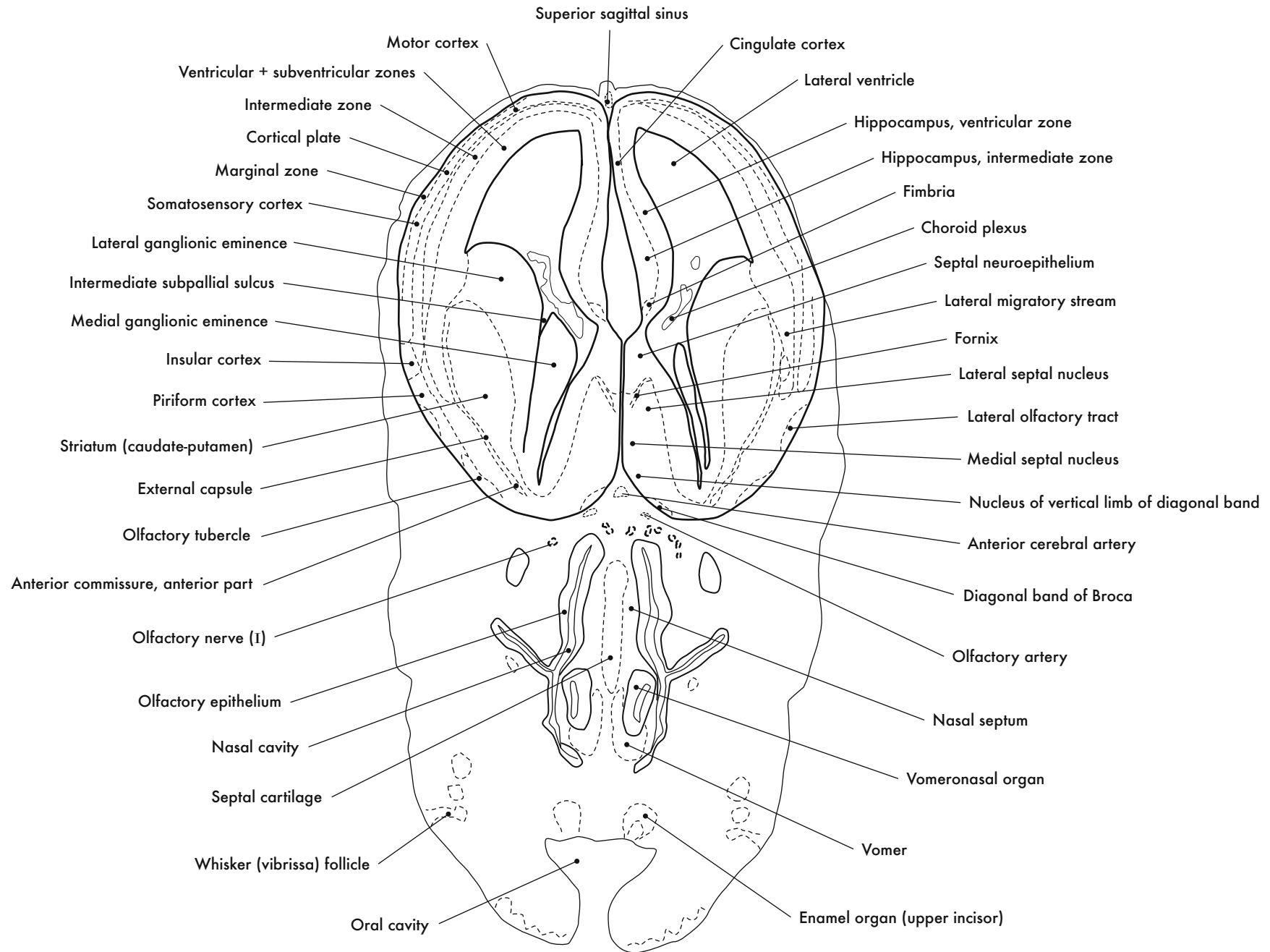
GD 14 CORONAL 5

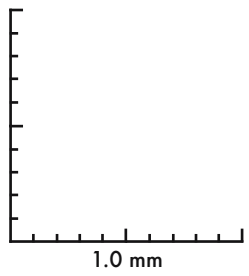
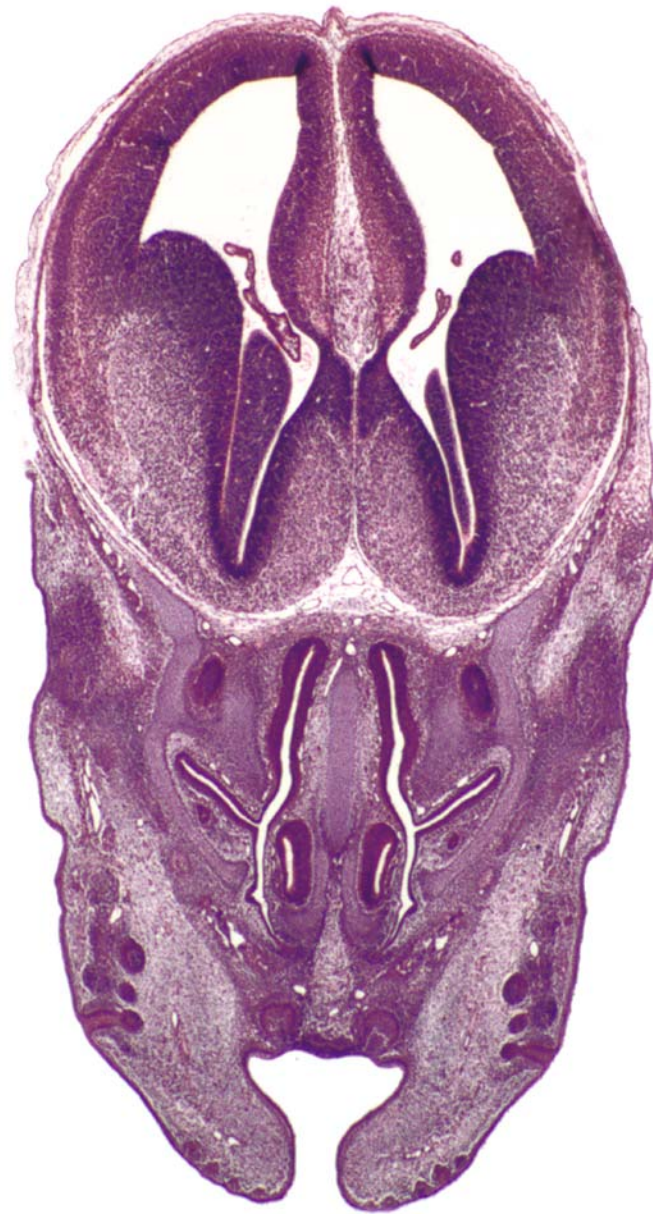
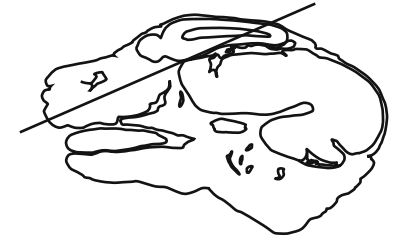


GD 14 CORONAL 6

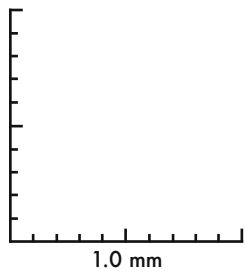
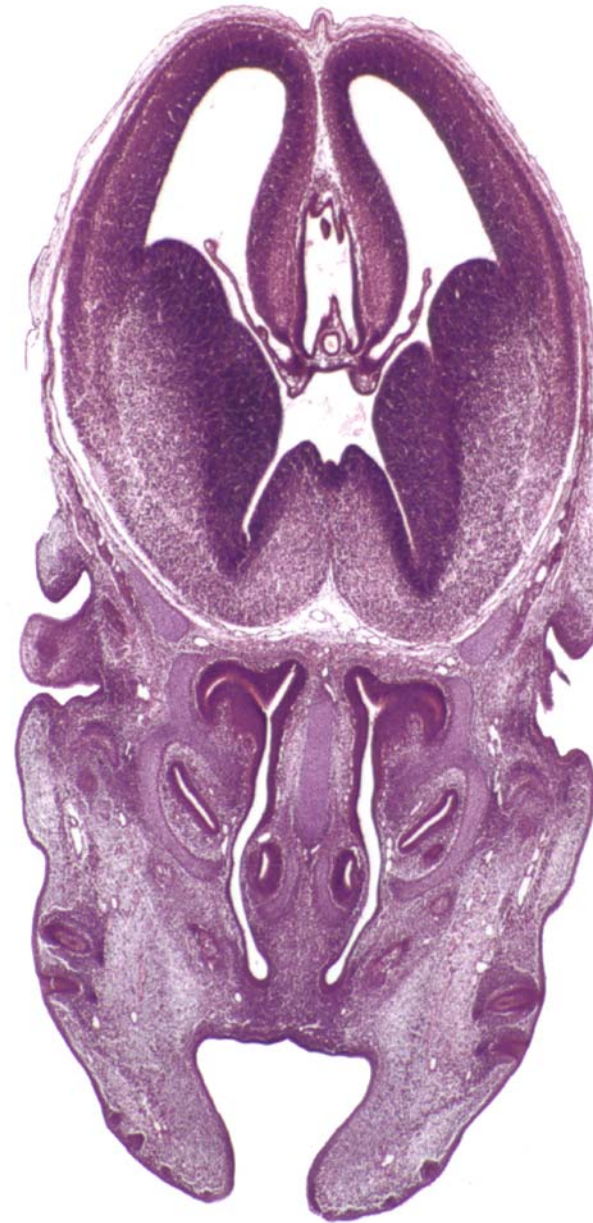






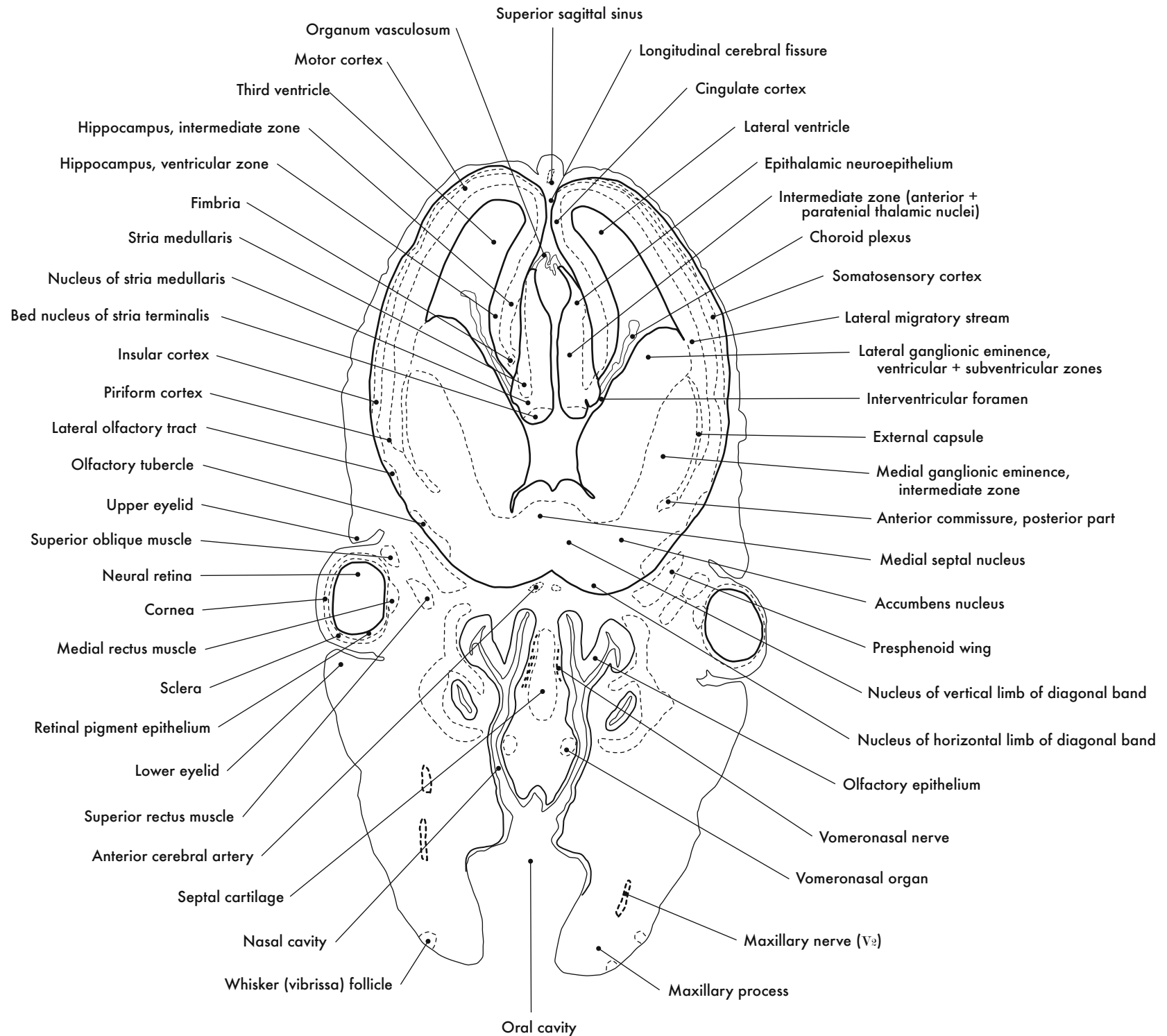
GD 14 CORONAL 7

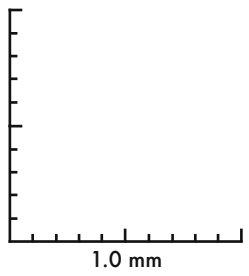
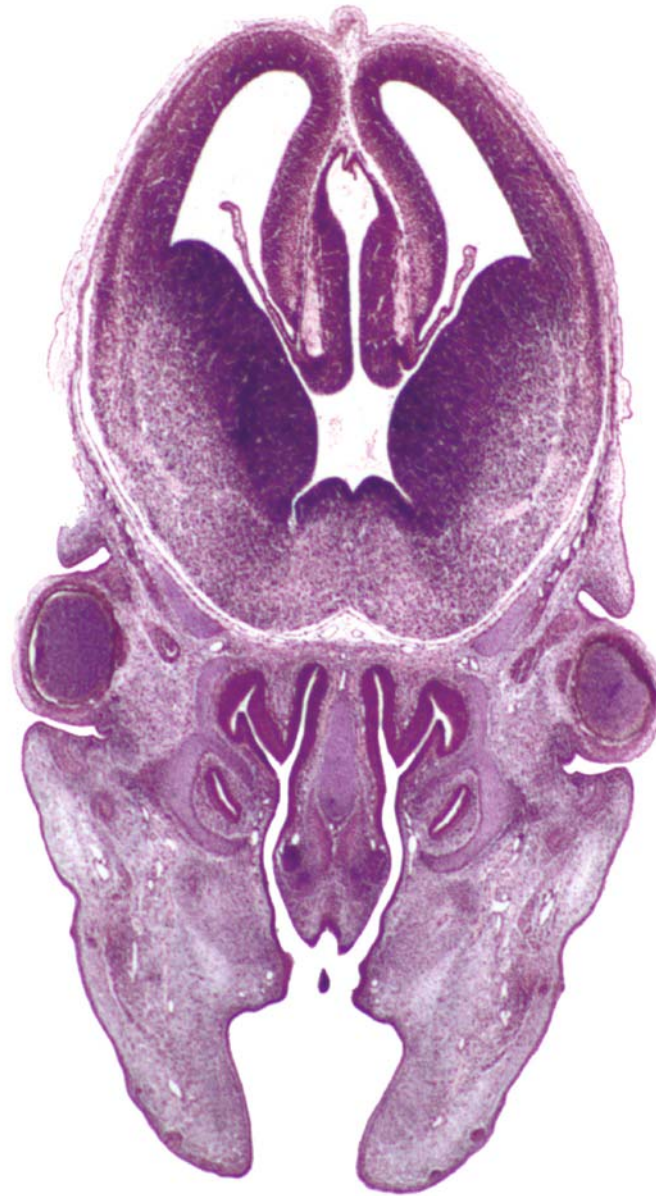
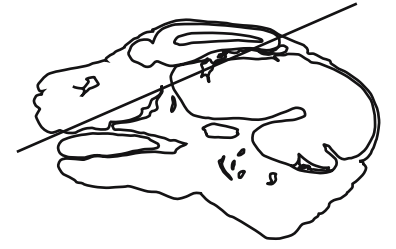


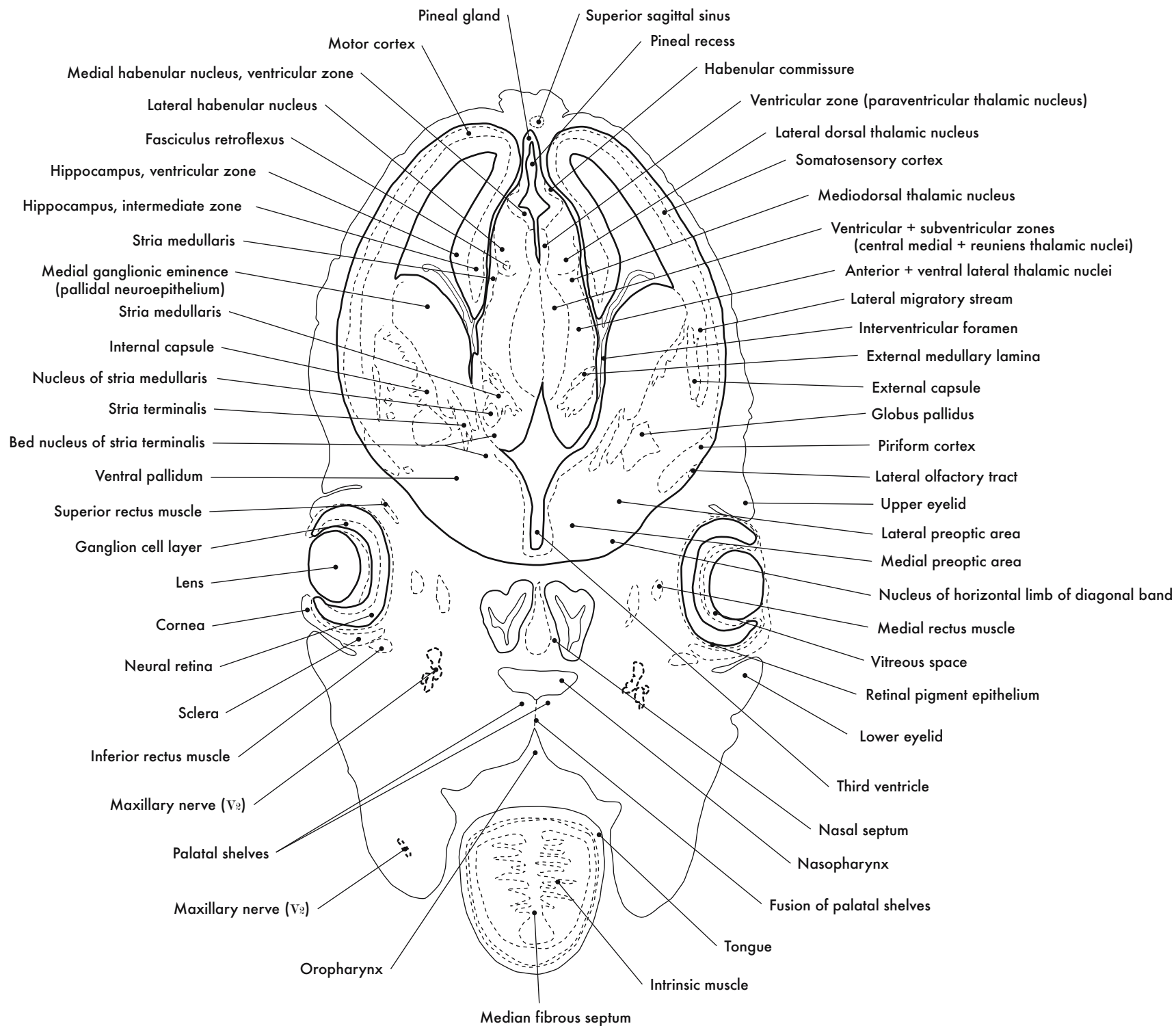
GD 14 CORONAL 8

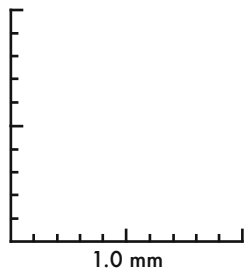
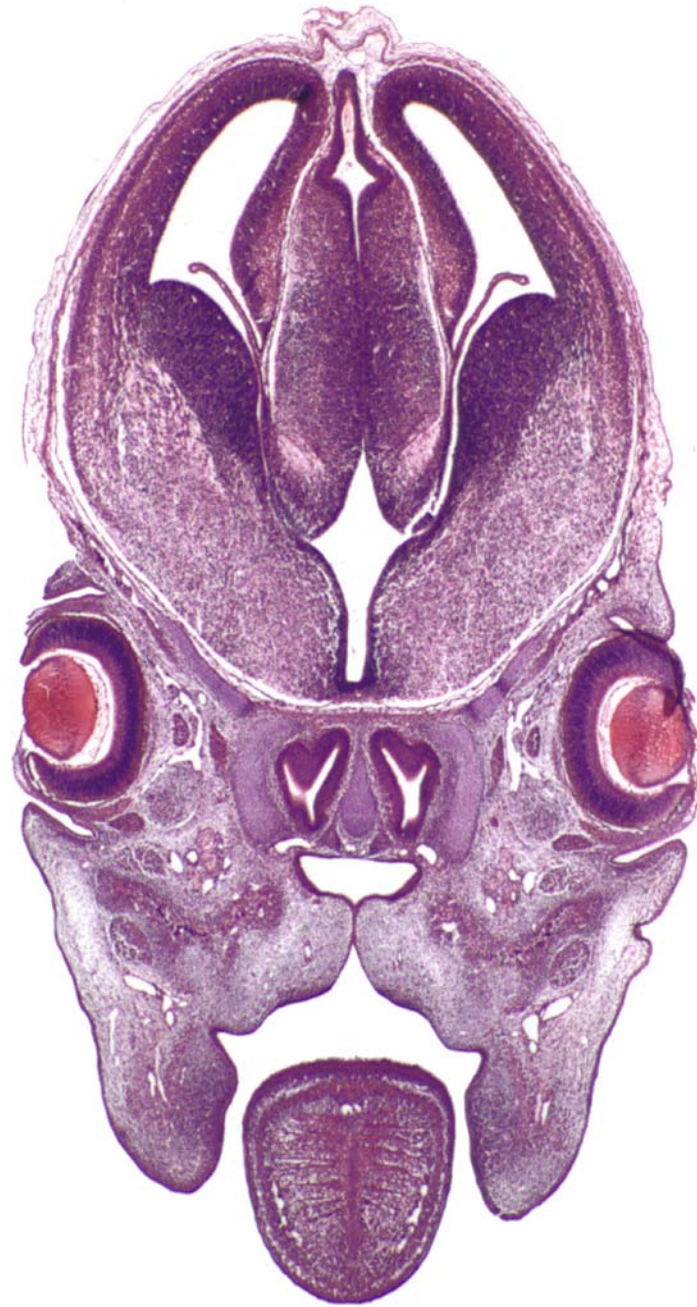
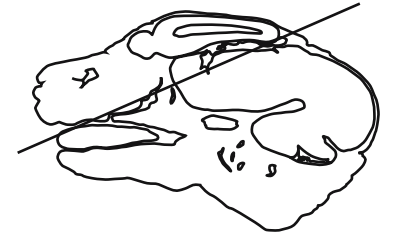






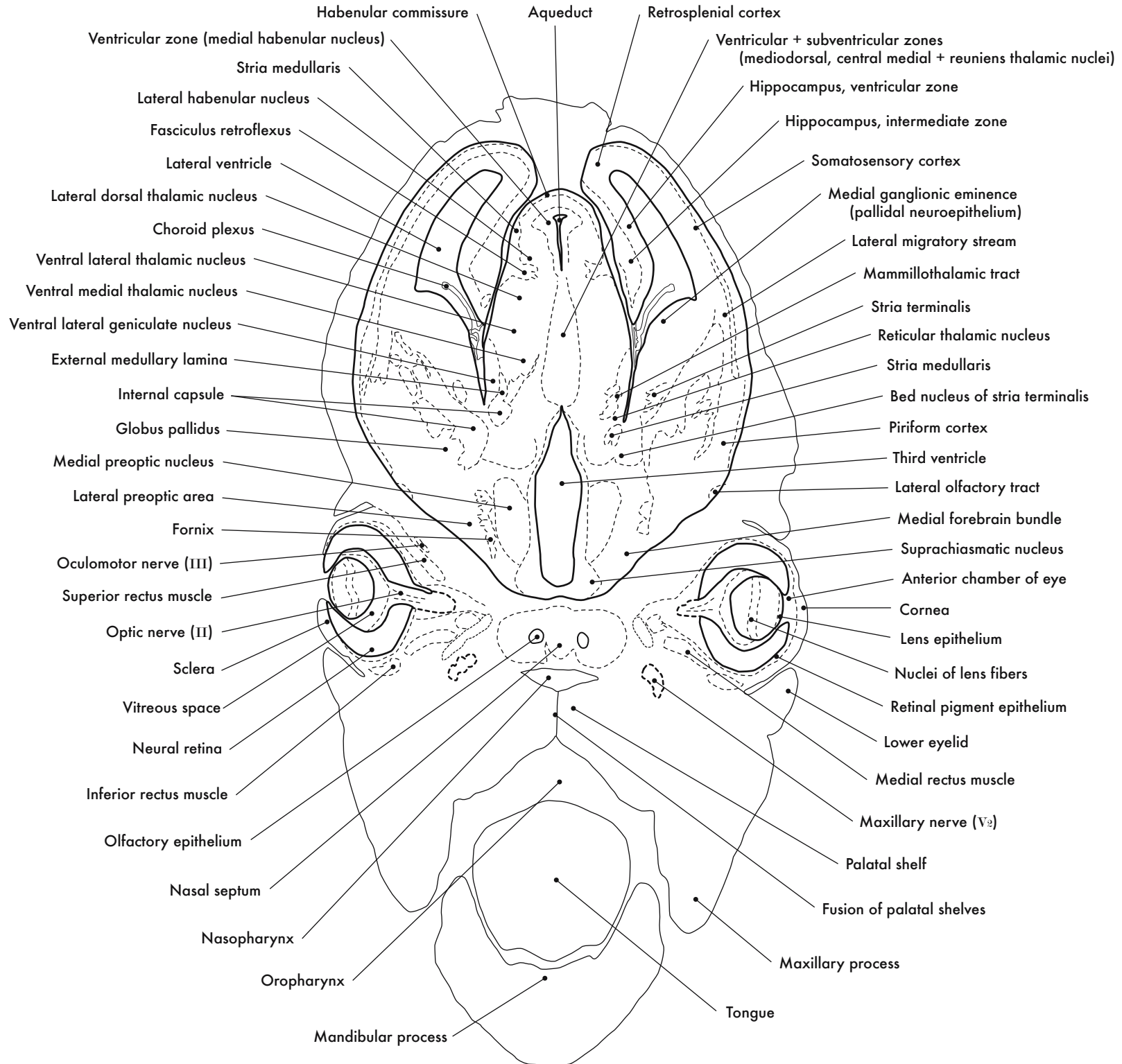
GD 14 CORONAL 9

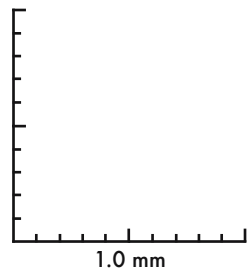
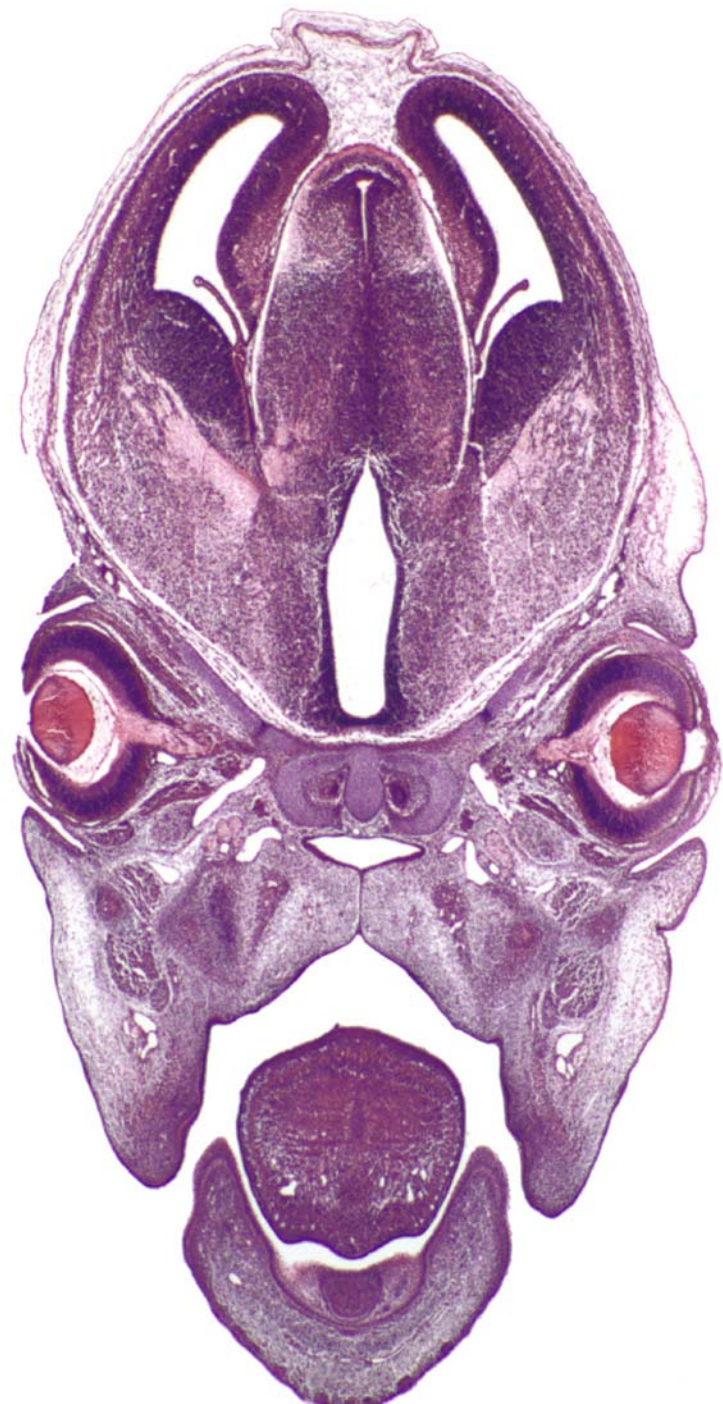



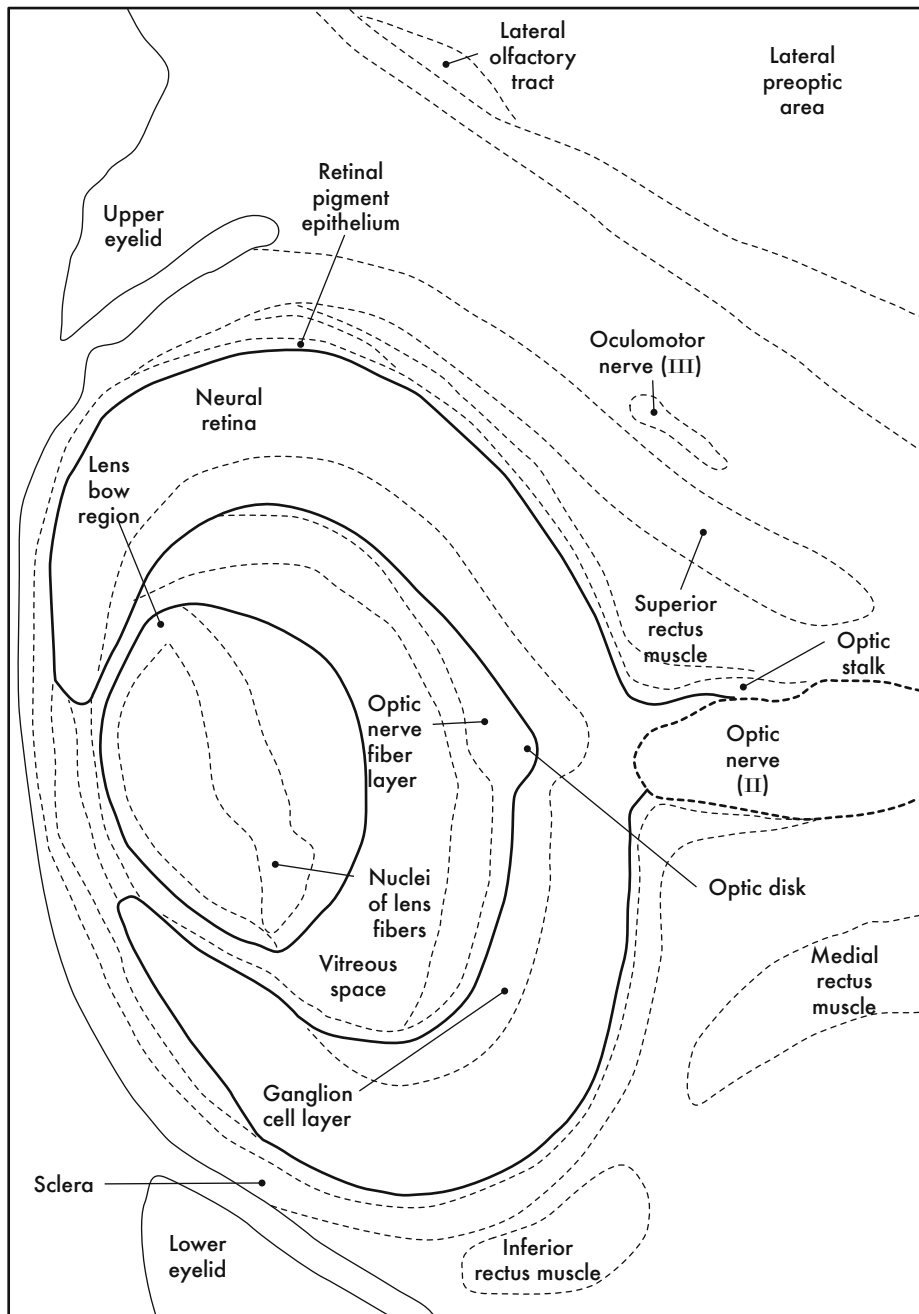
GD 14 CORONAL 10



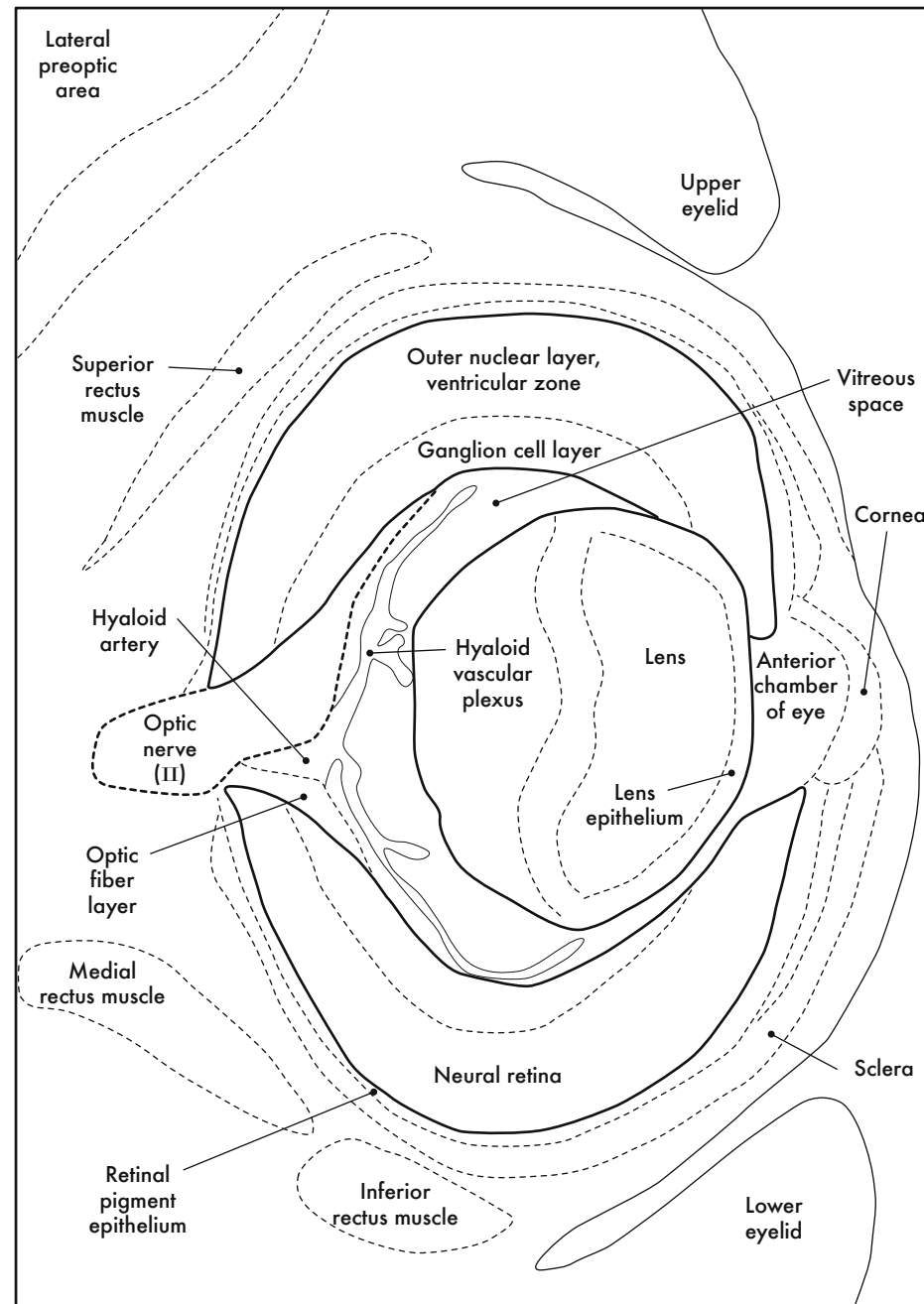




GD 14 CORONAL 11

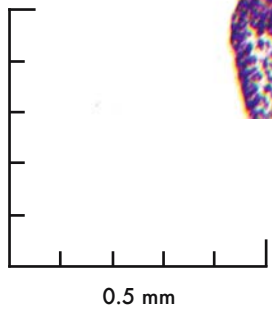
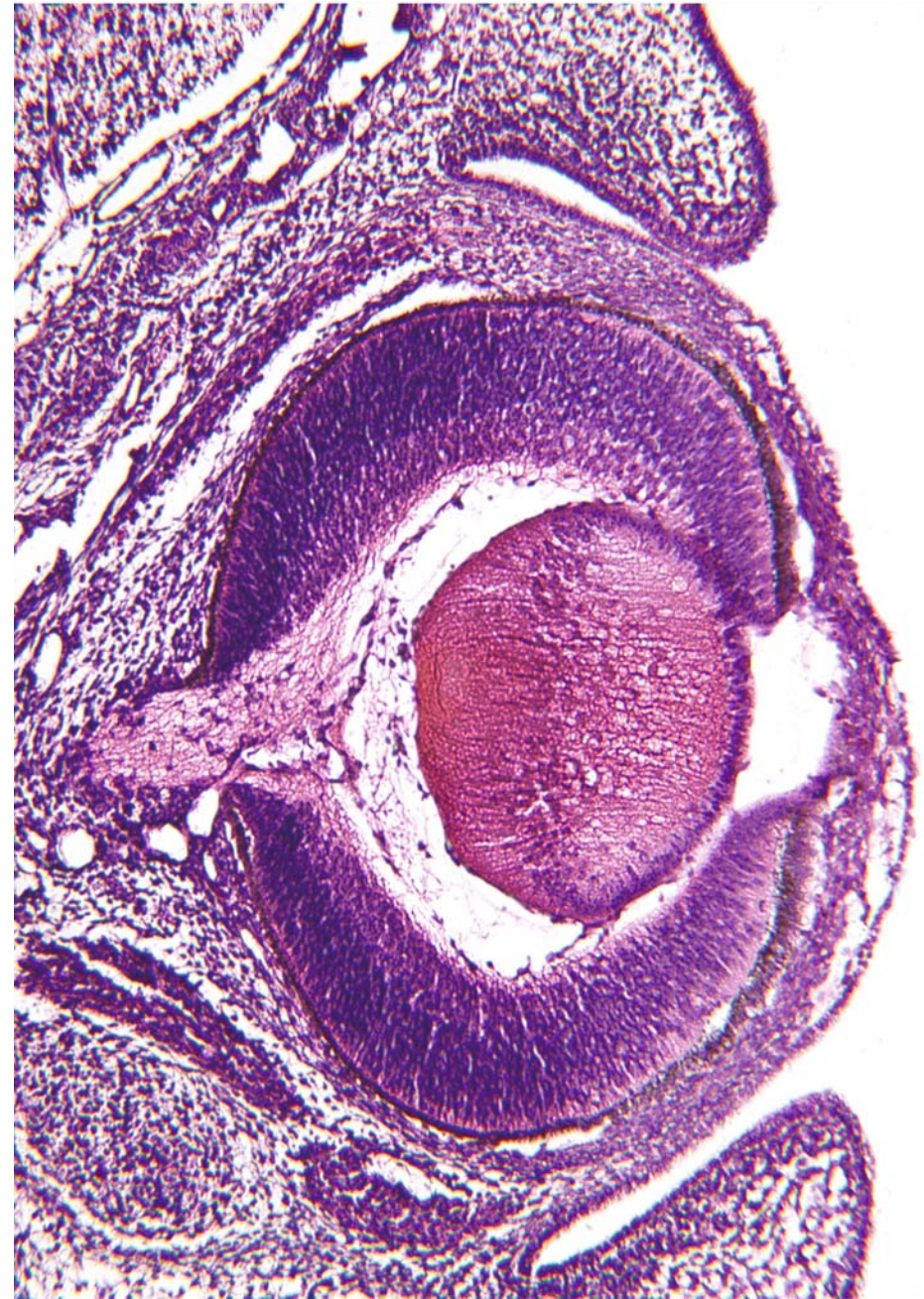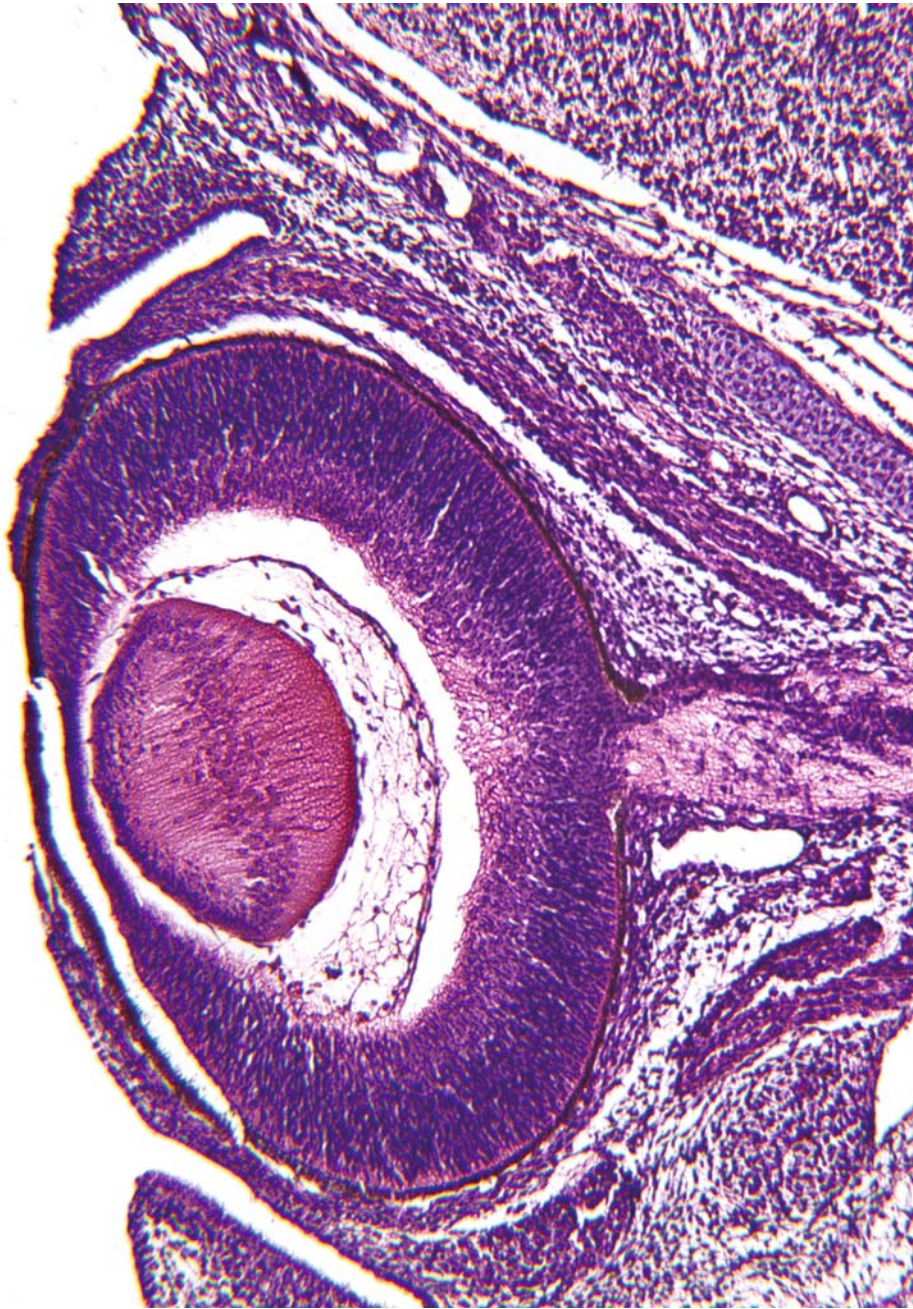


A. Left Eye



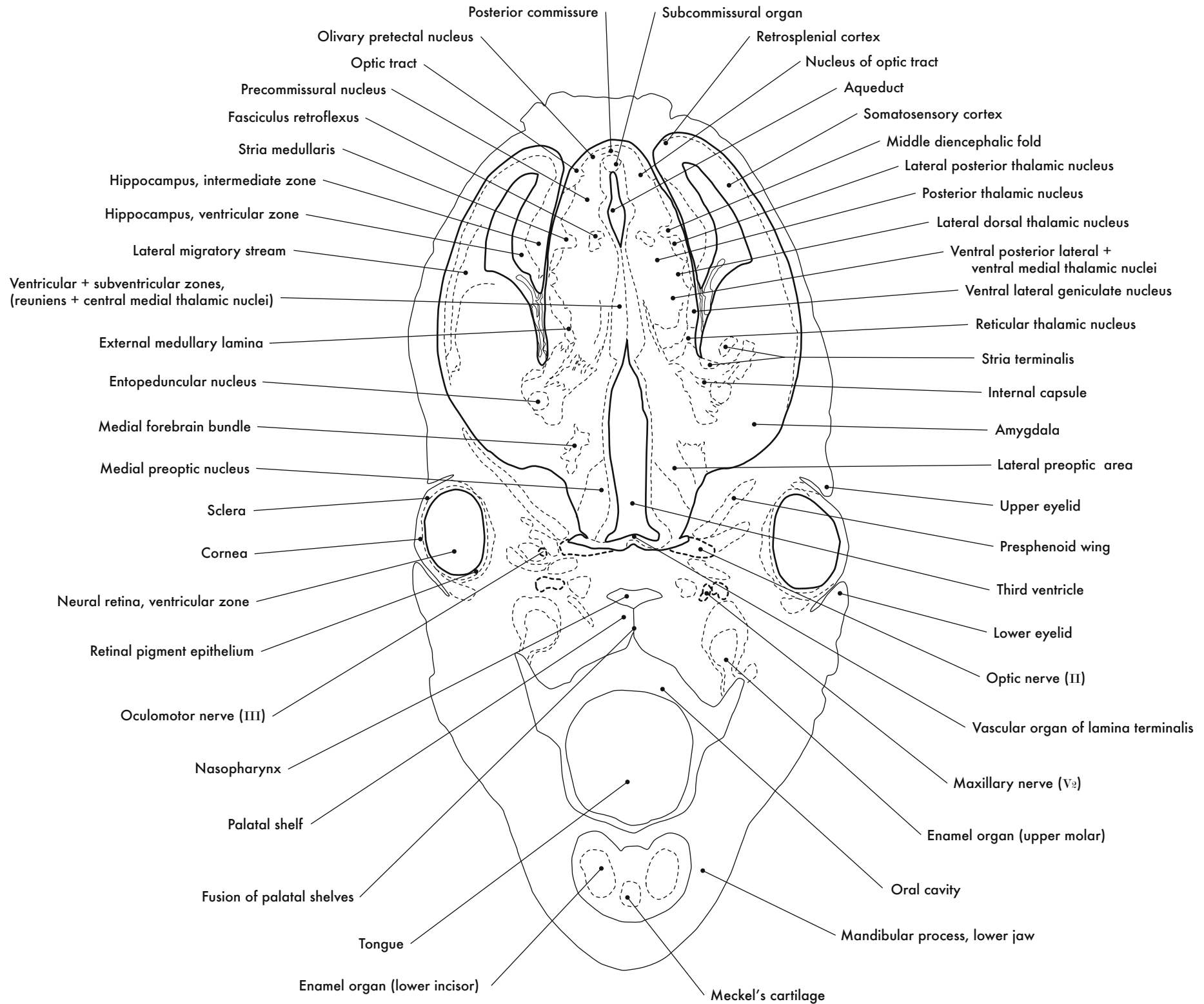
B. Right Eye

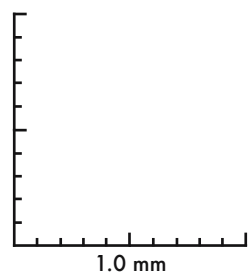
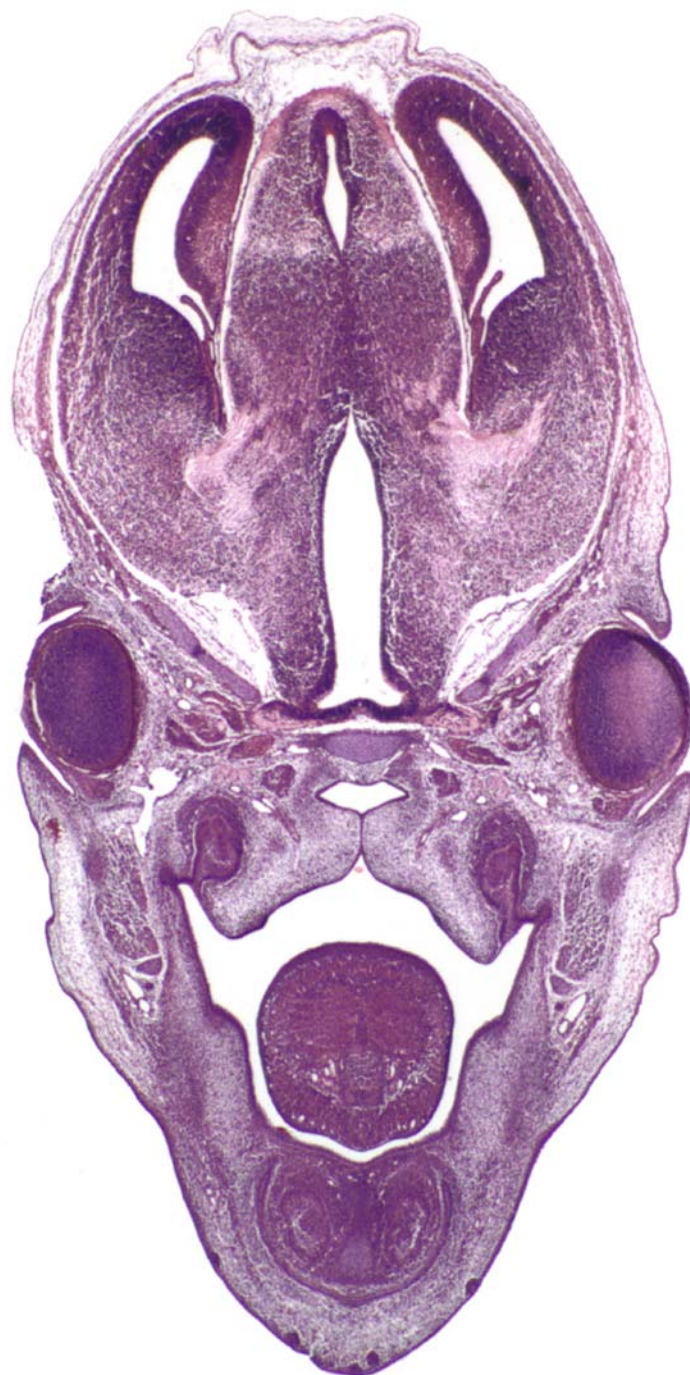
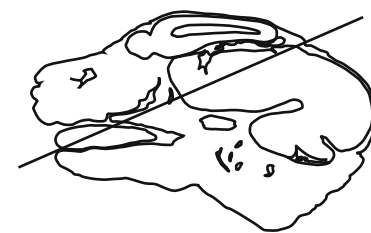



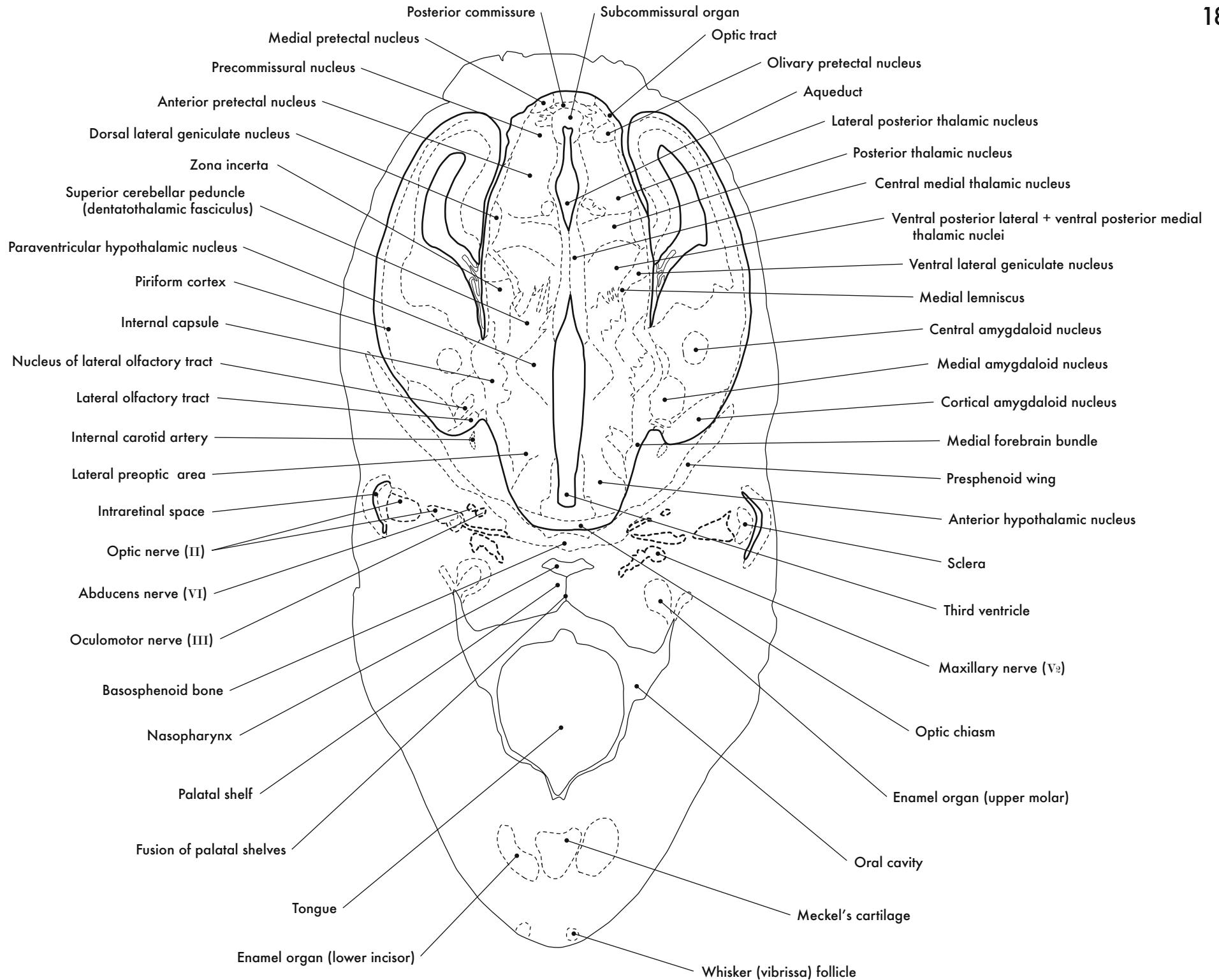
GD 14 CORONAL 12

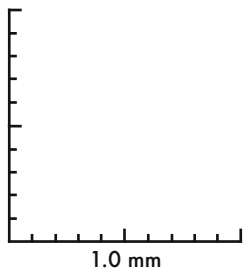
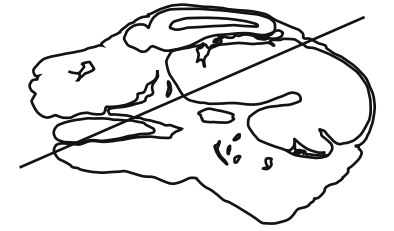
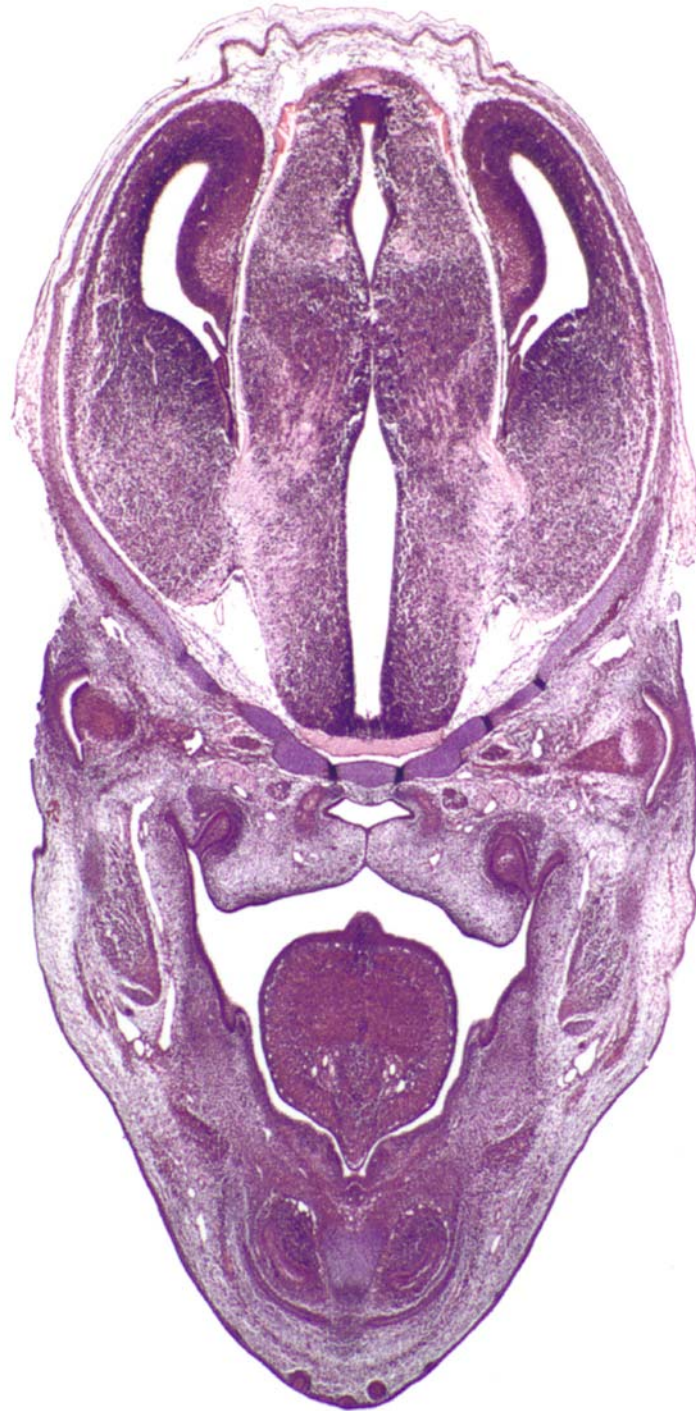




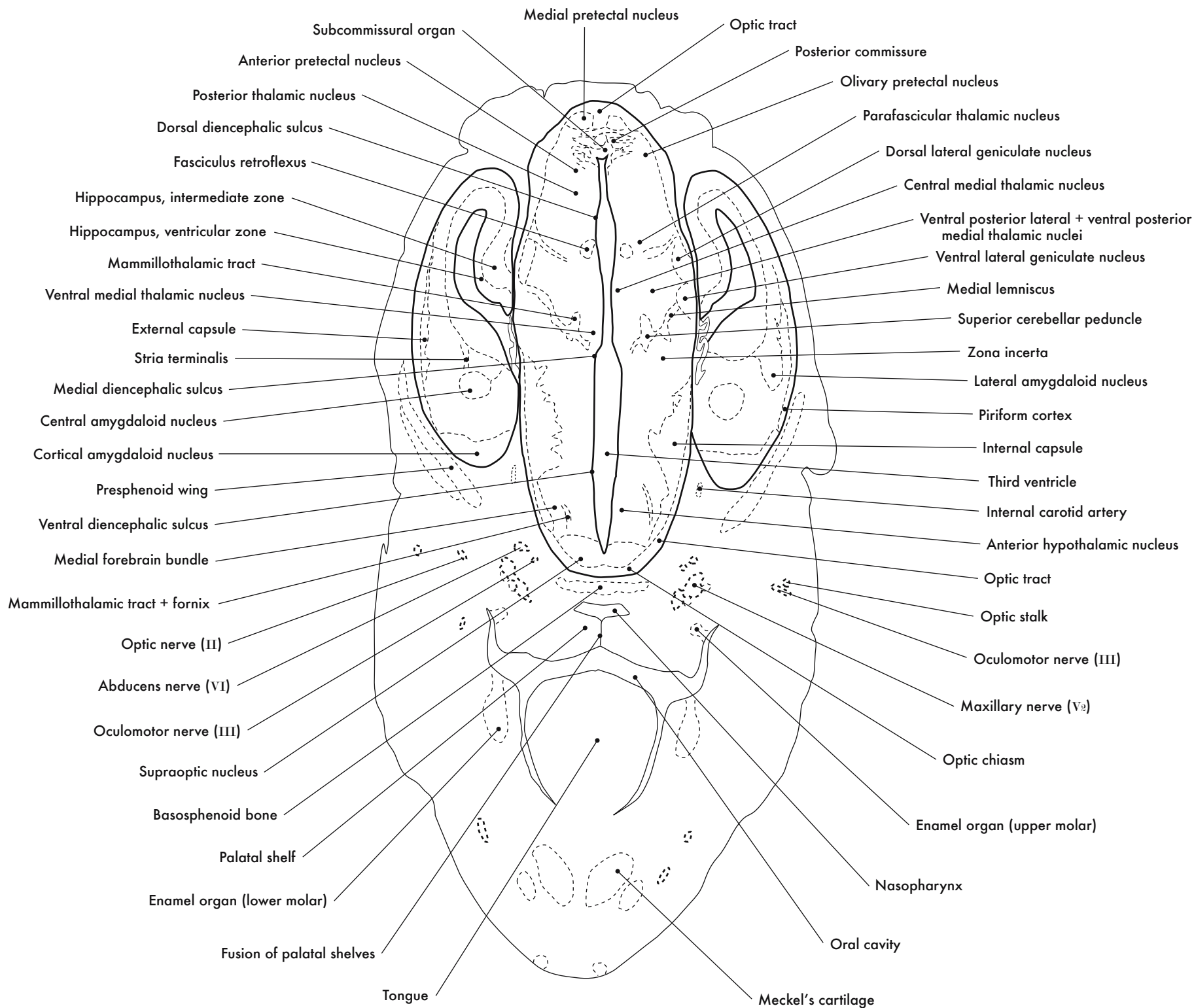
GD 14 CORONAL 13

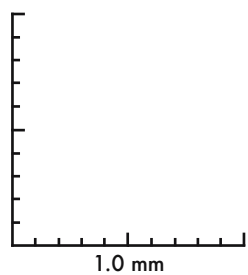
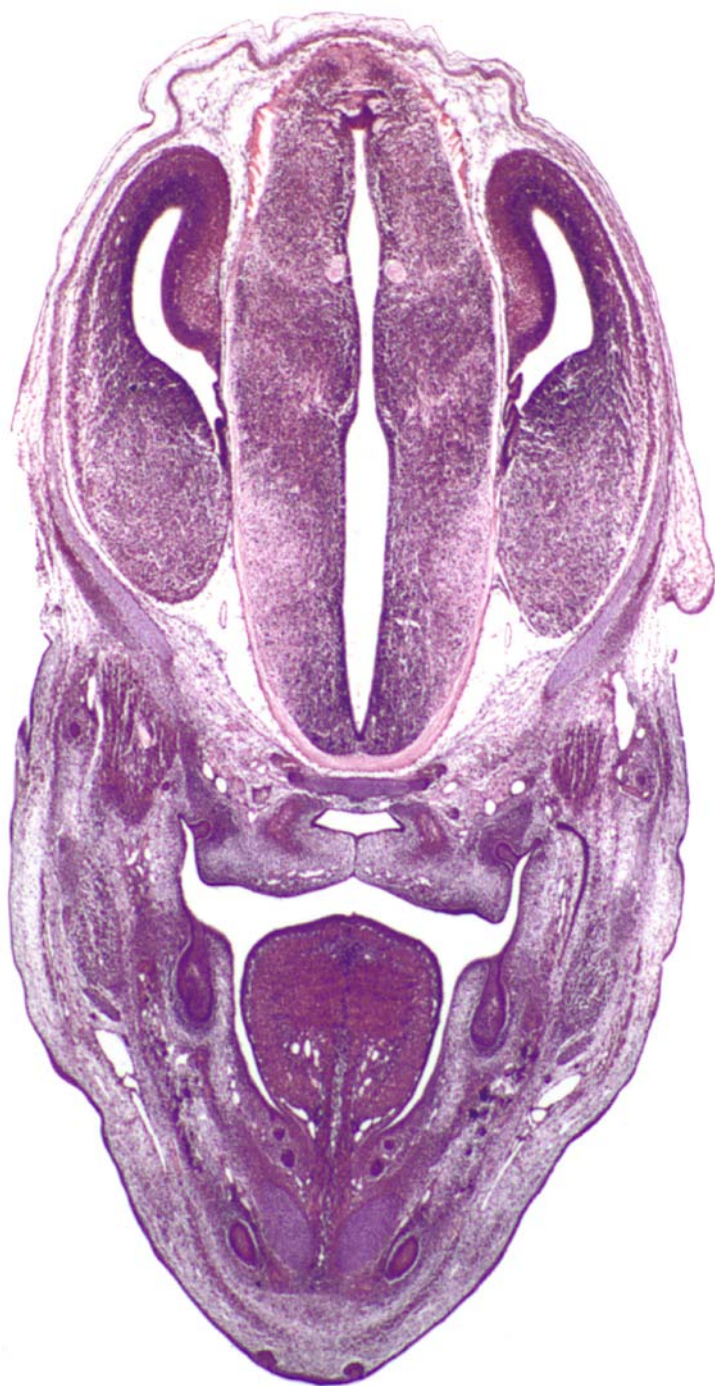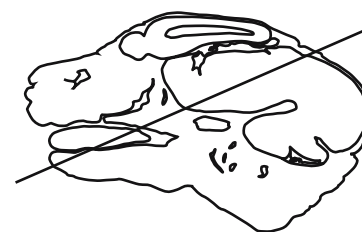




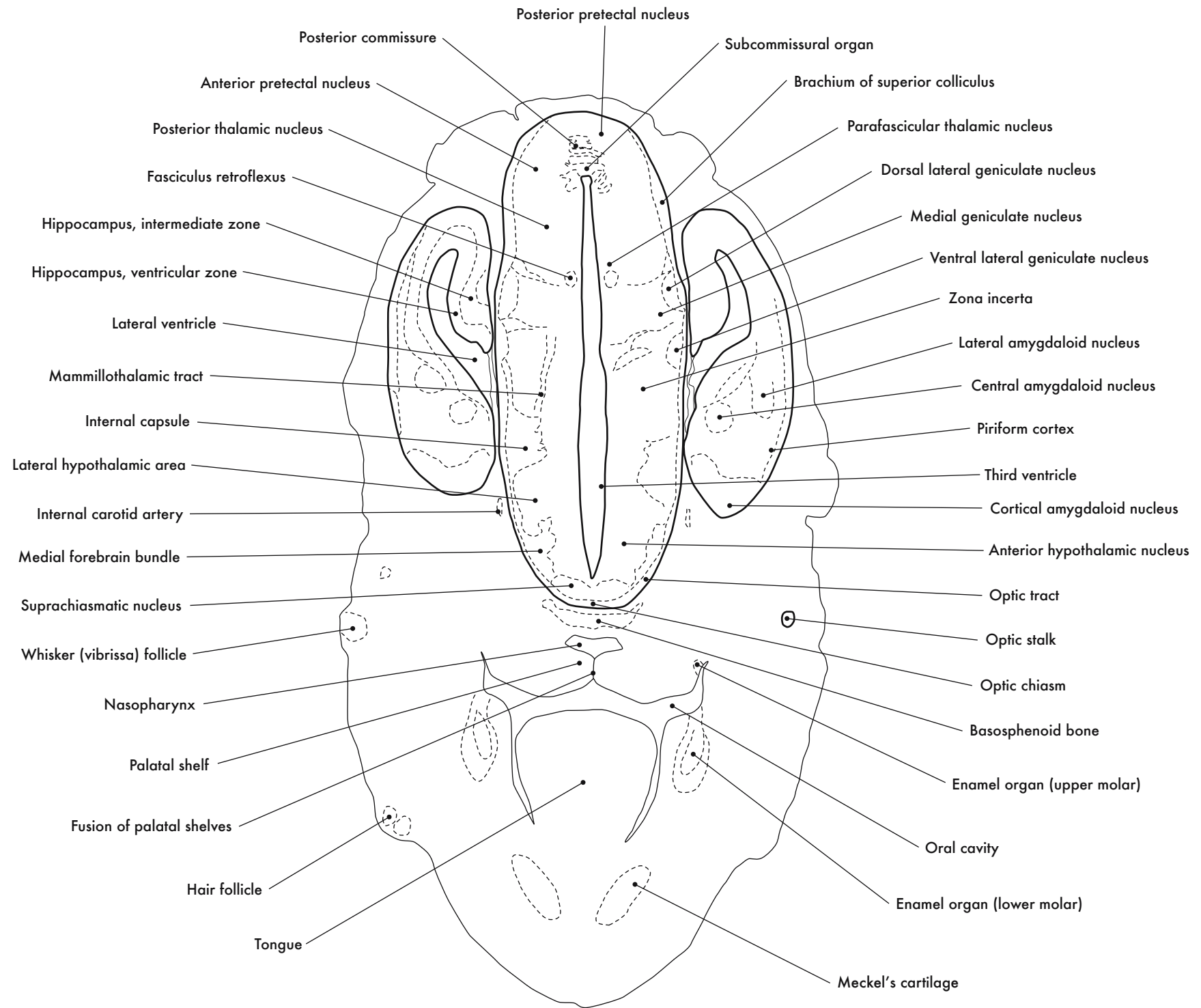
GD 14 CORONAL 14

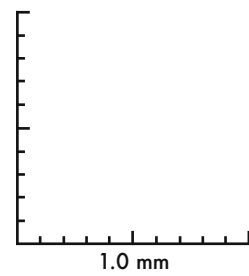
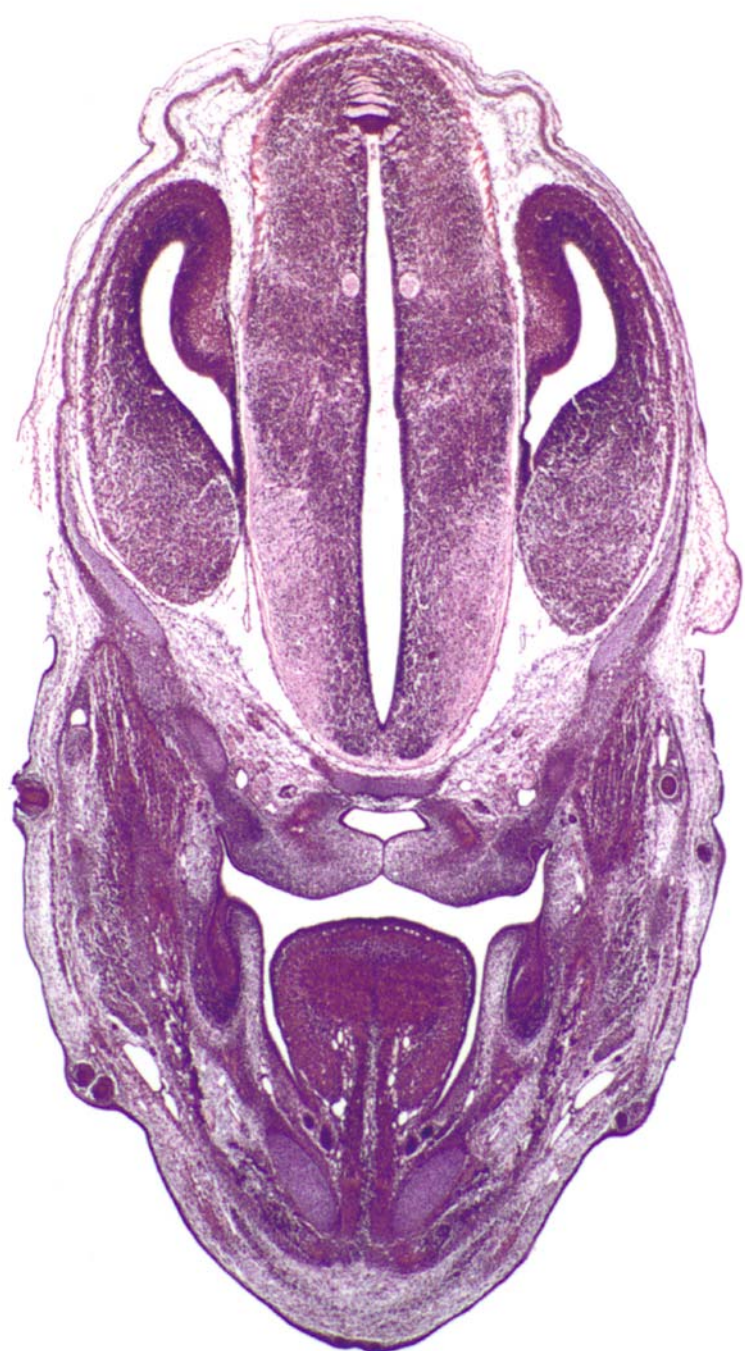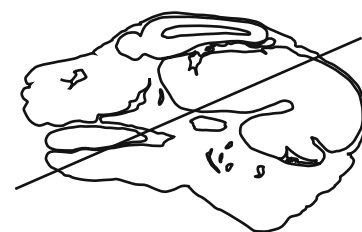






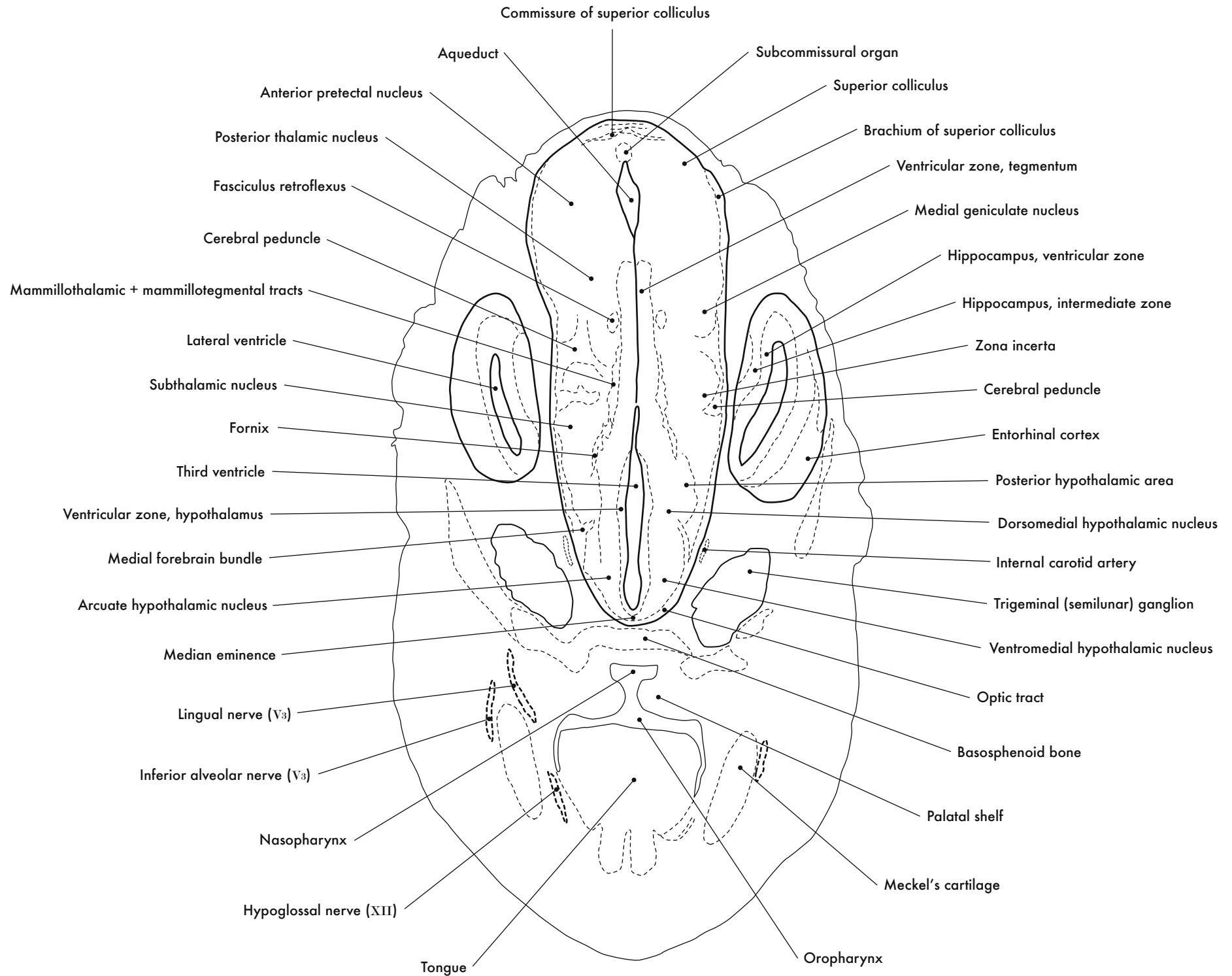
GD 14 CORONAL 15

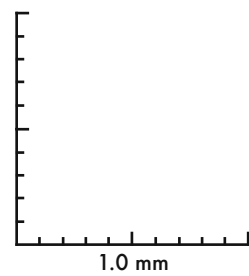
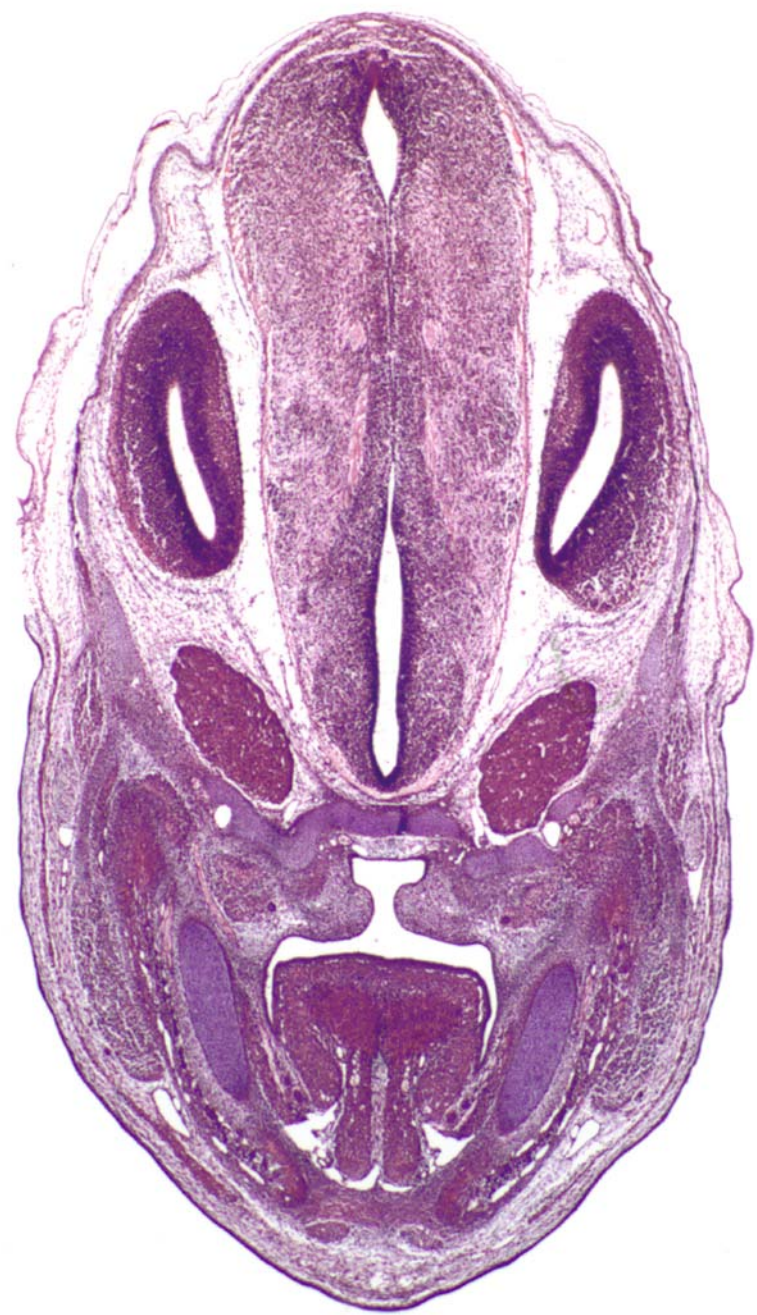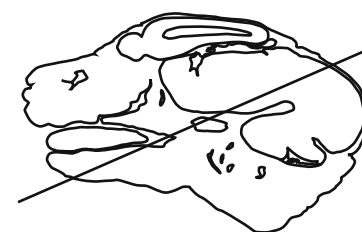




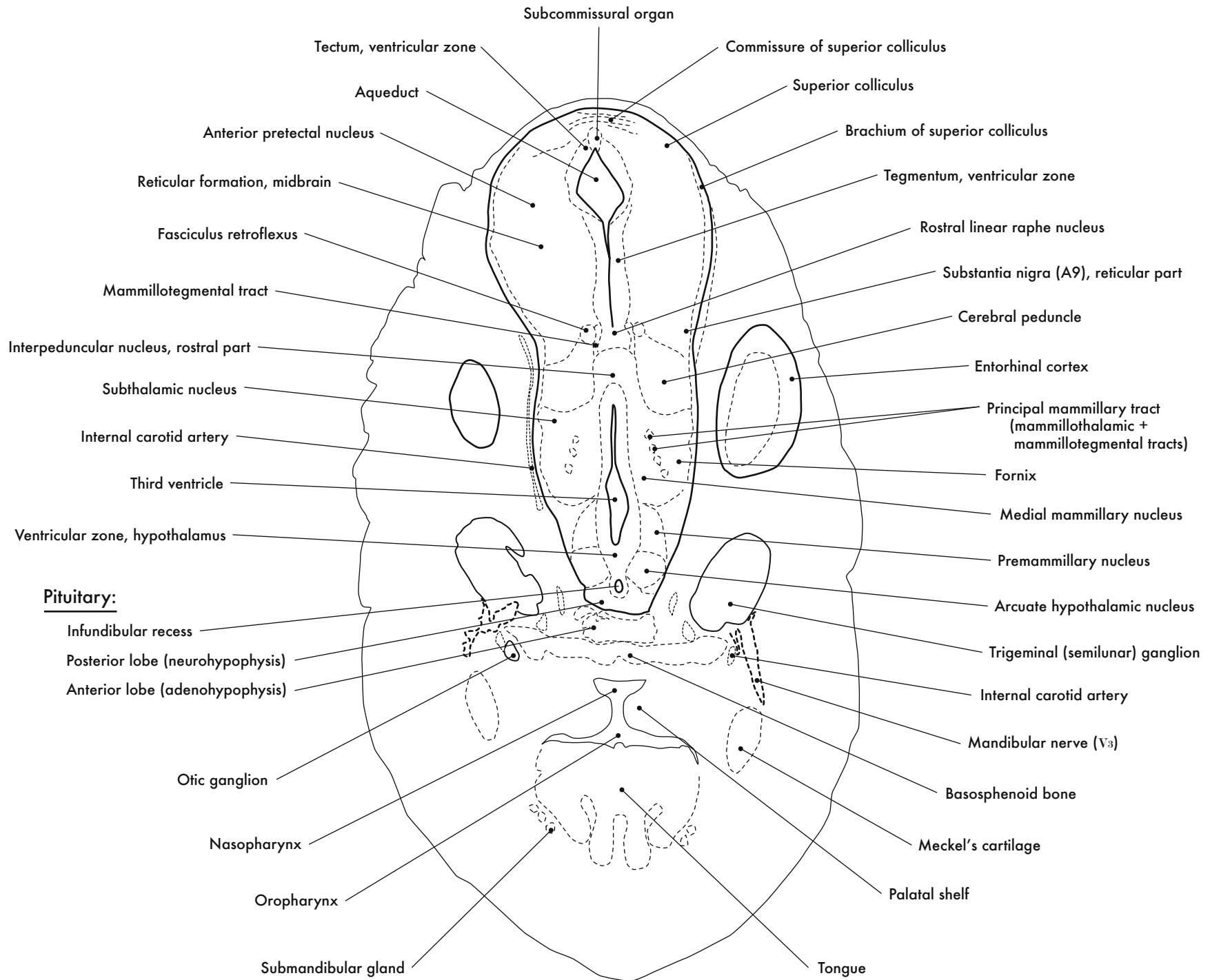
GD 14 CORONAL 16

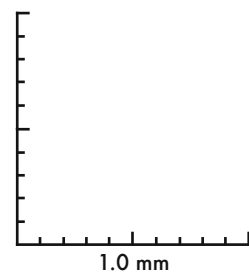
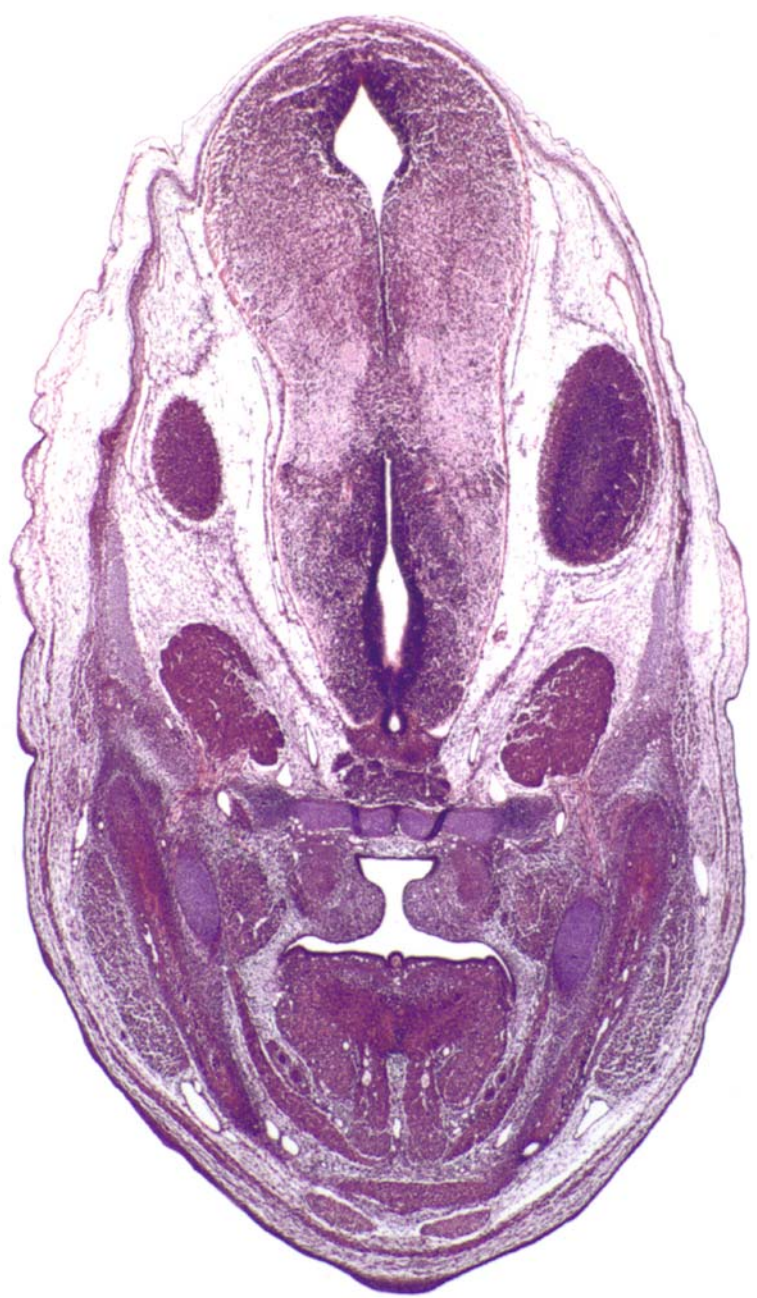
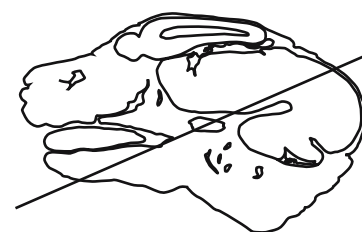




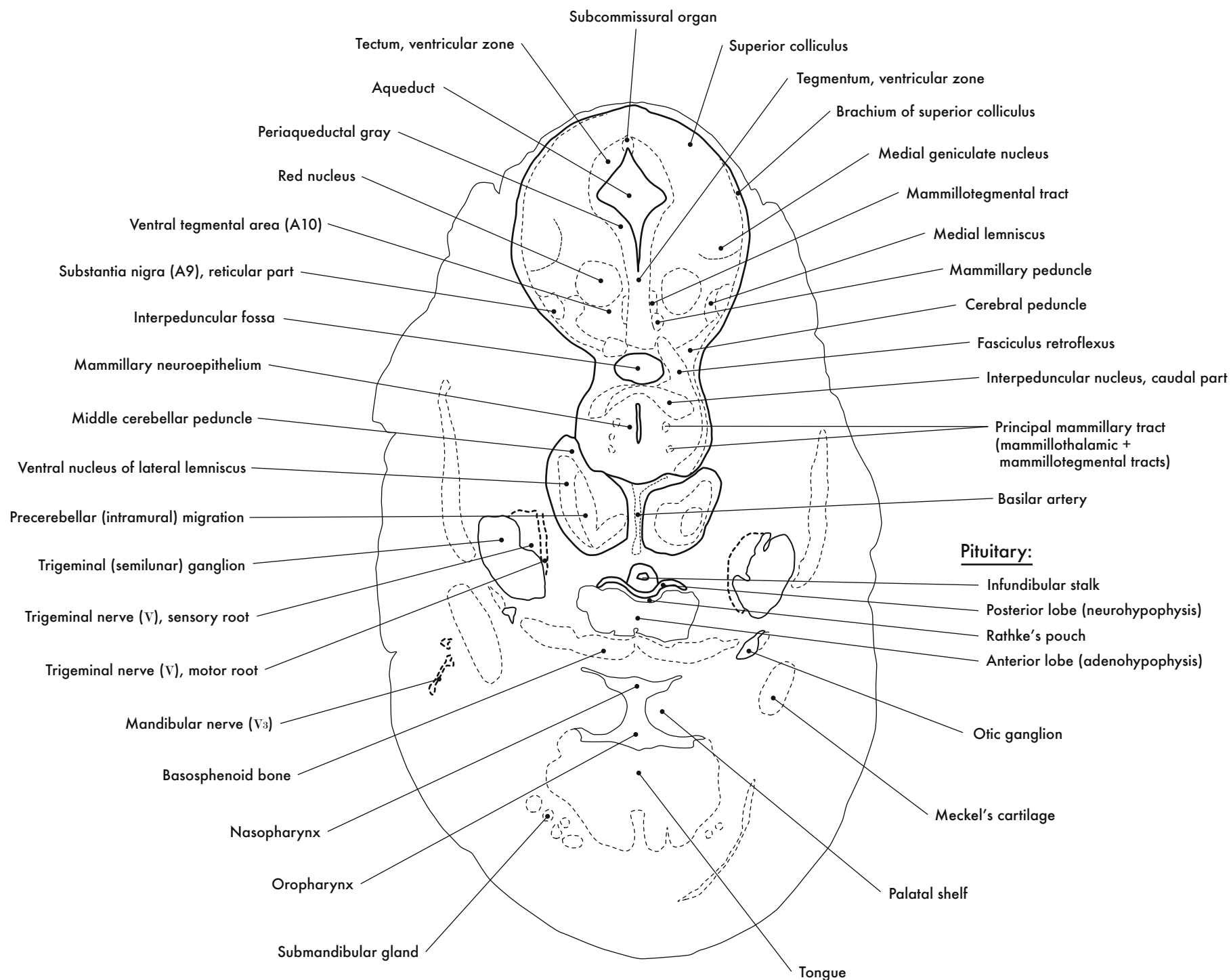
GD 14 CORONAL 17

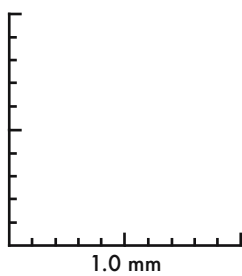
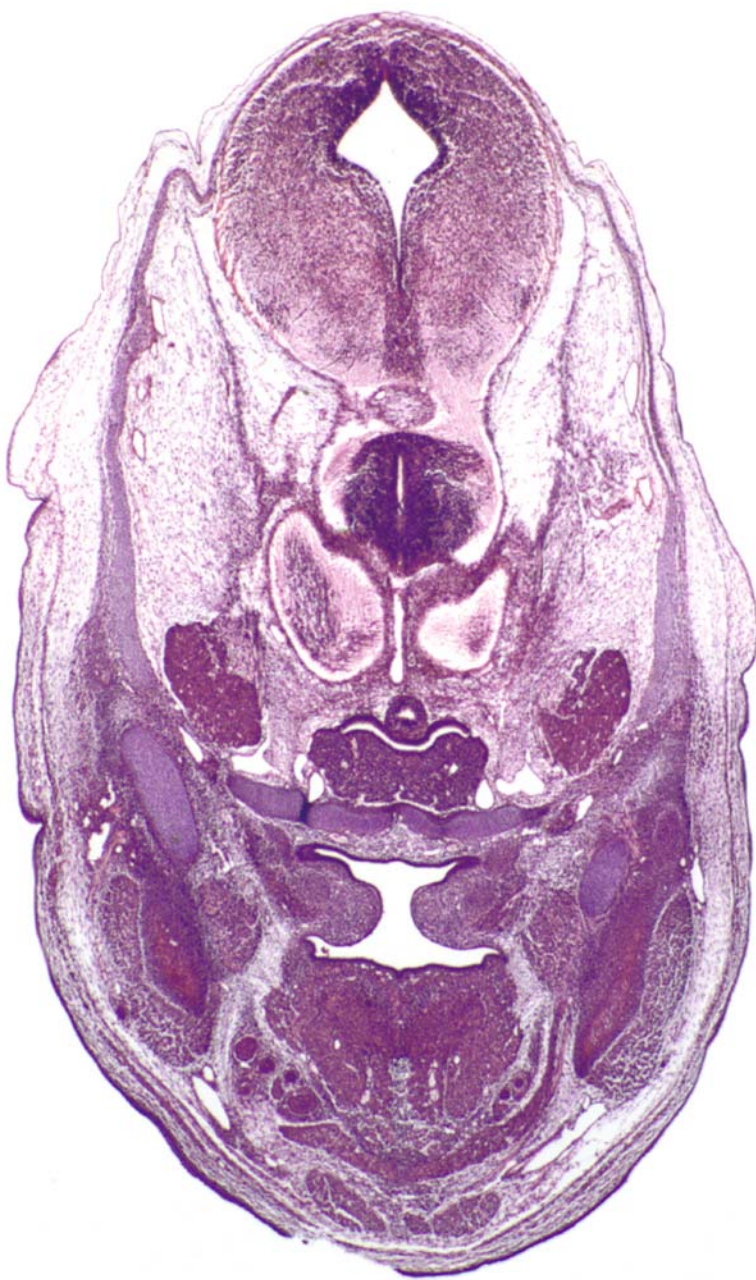
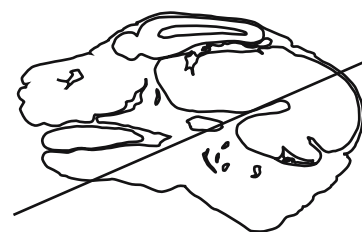



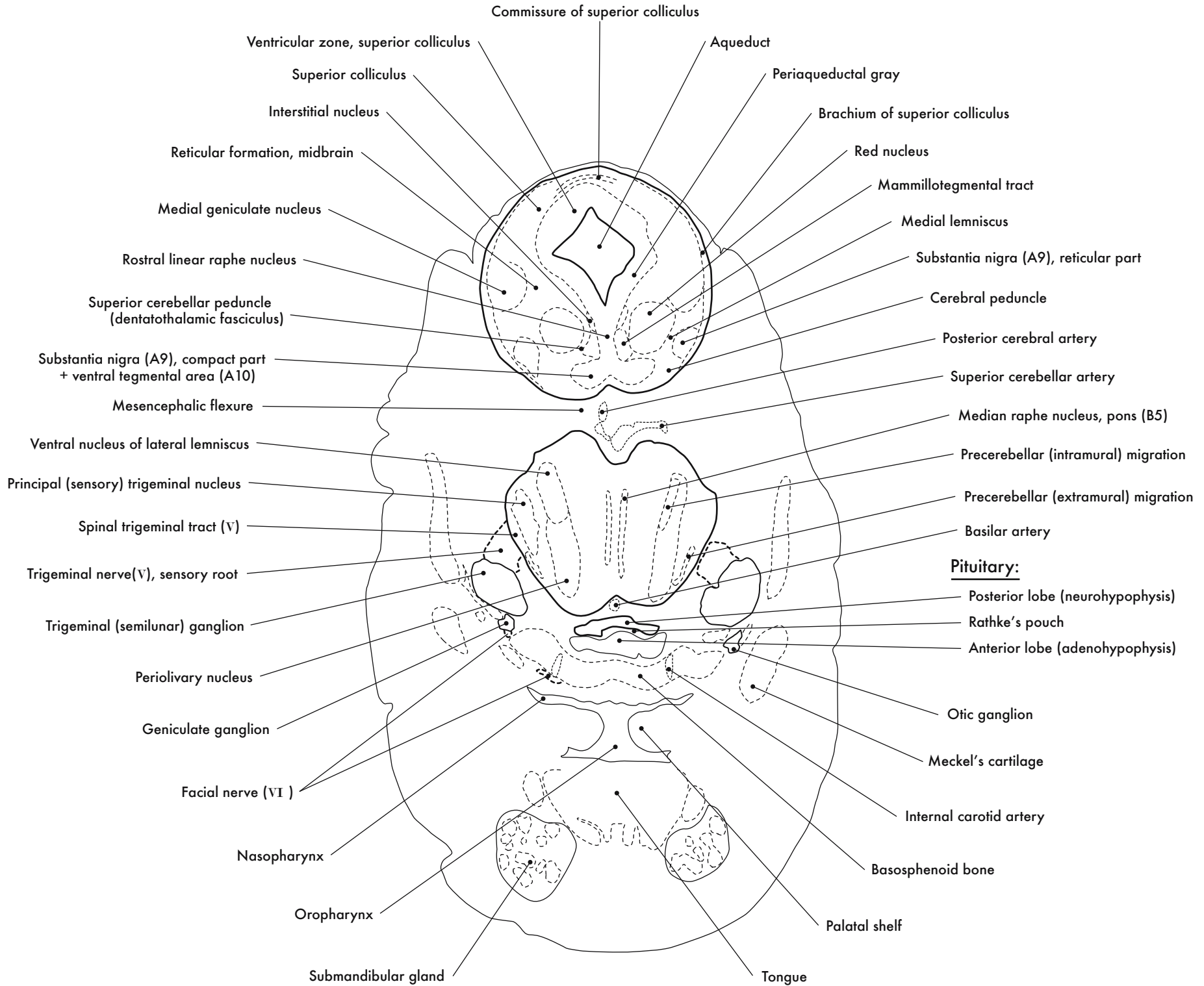
GD 14 CORONAL 18

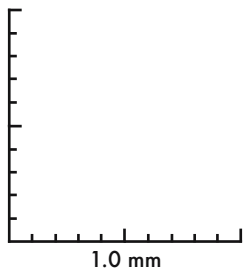
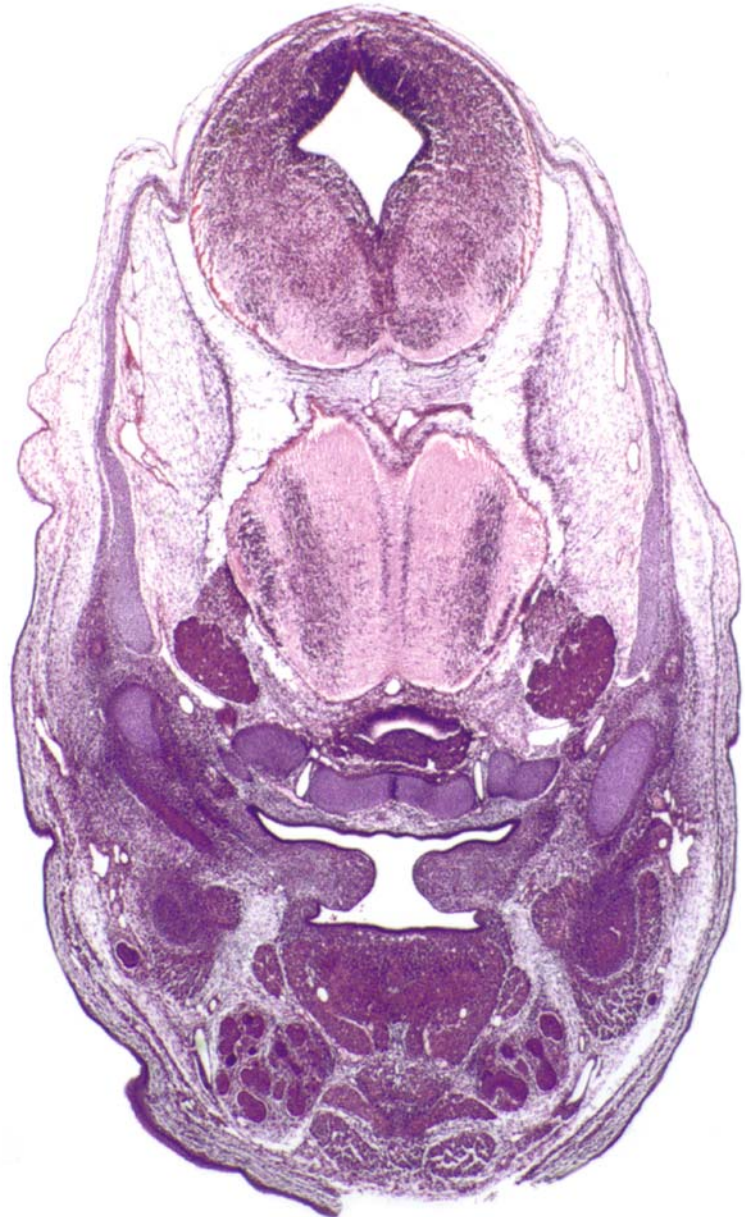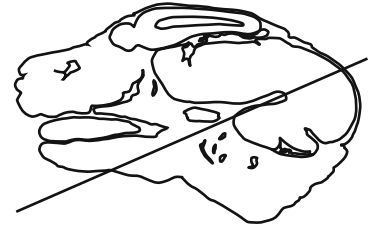






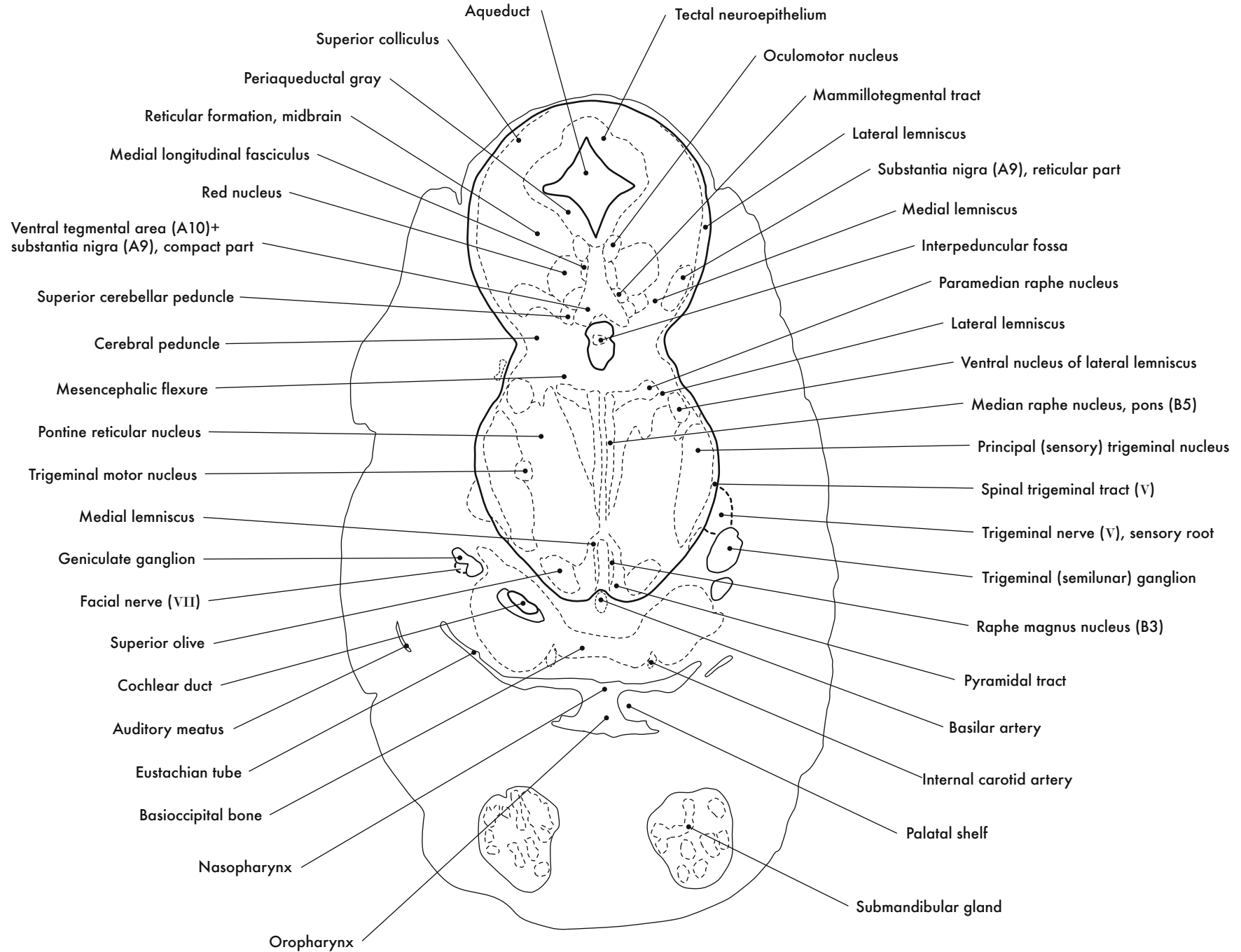
GD 14 CORONAL 19

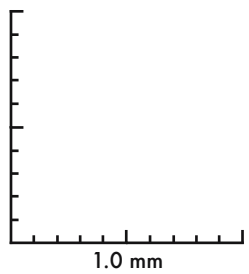
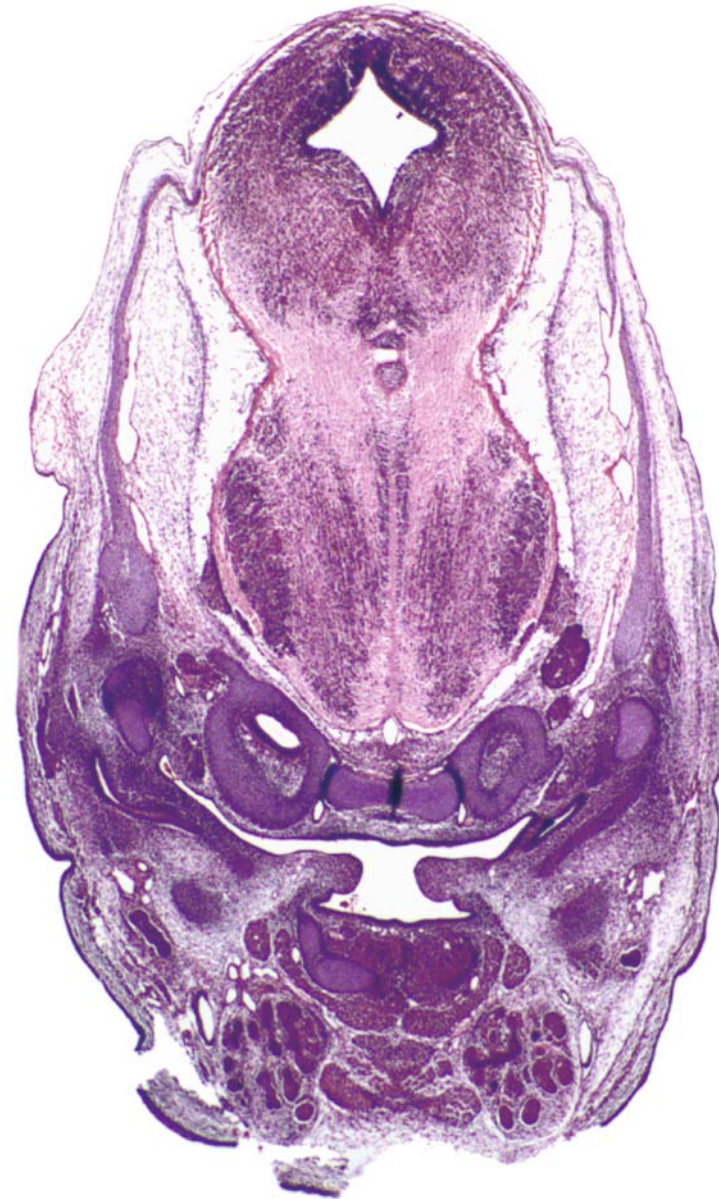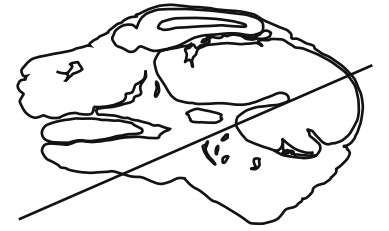




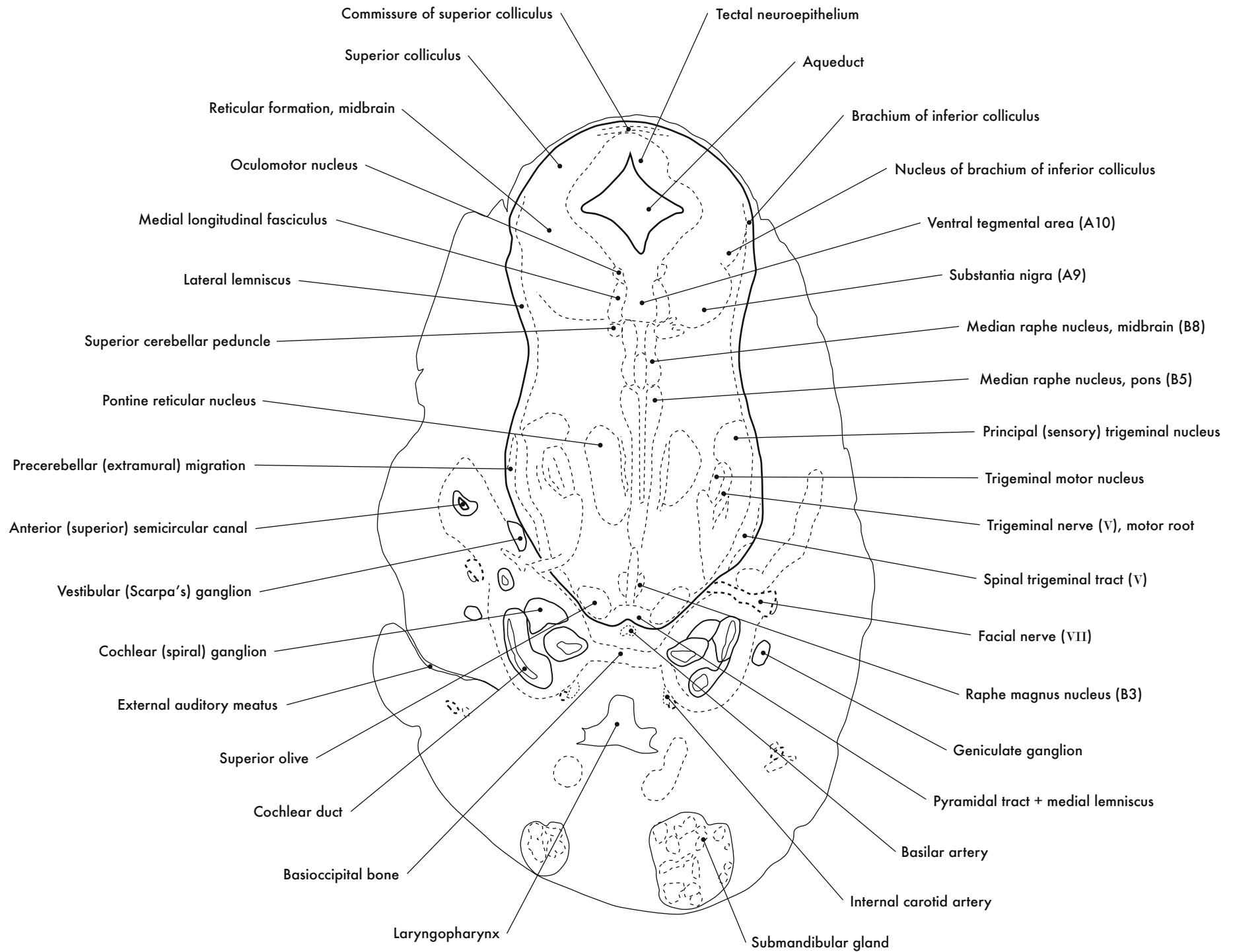
GD 14 CORONAL 20

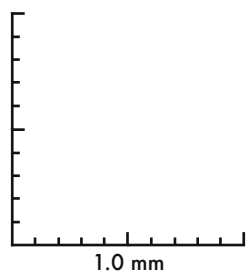
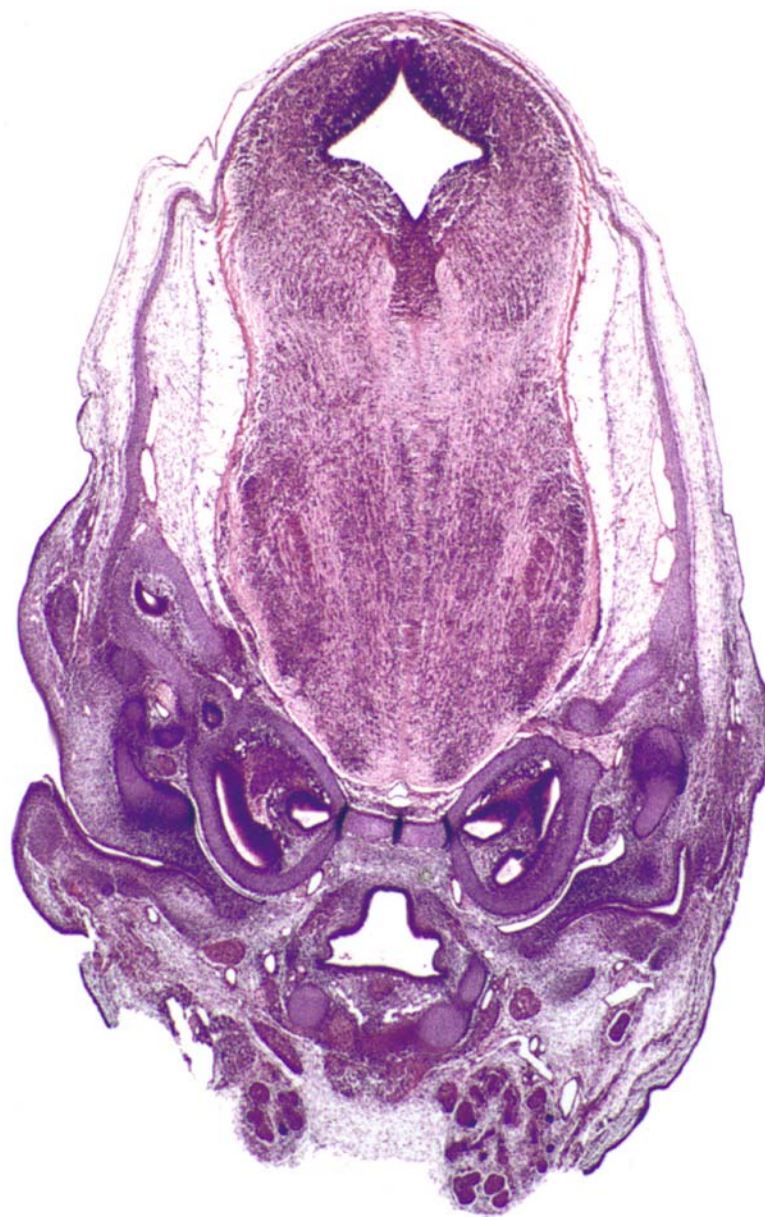
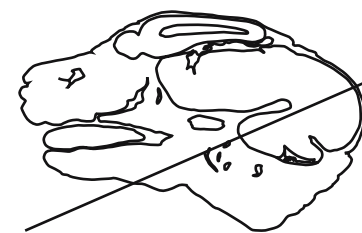




GD 14 CORONAL 21

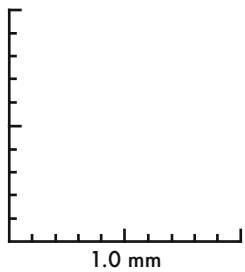
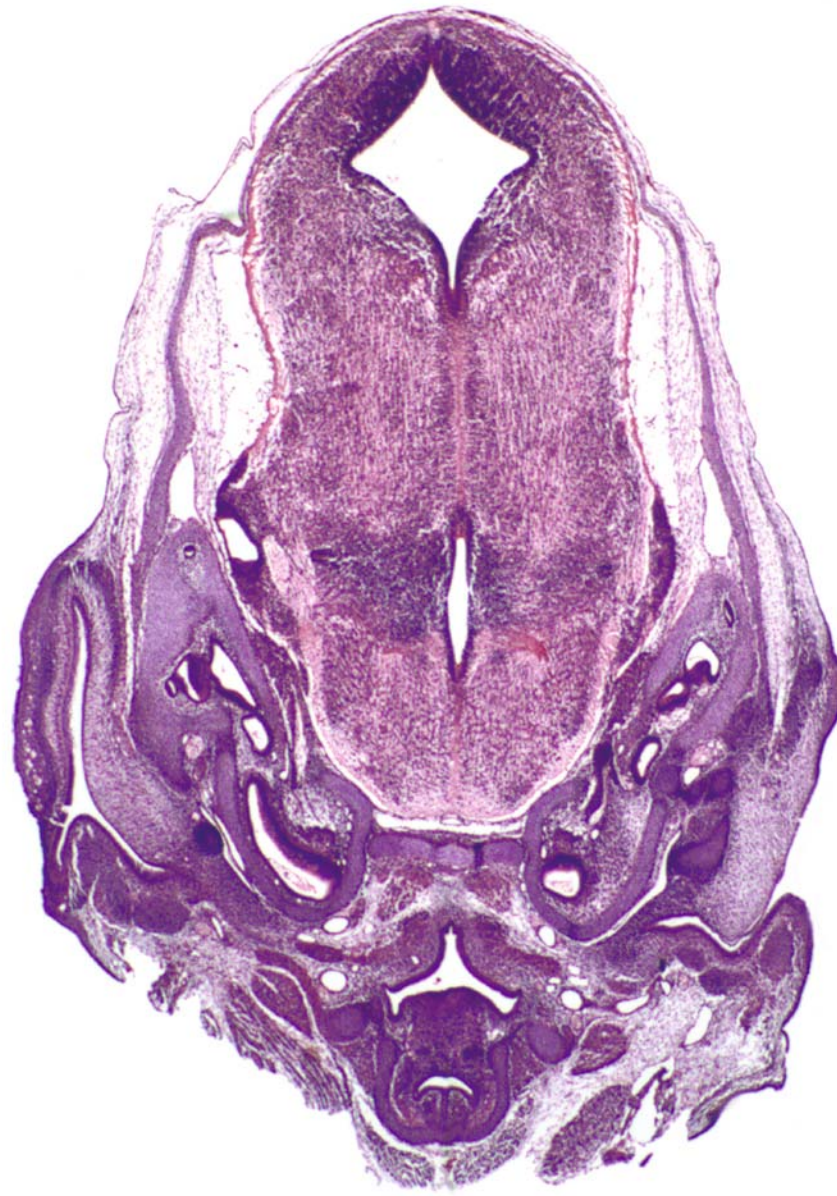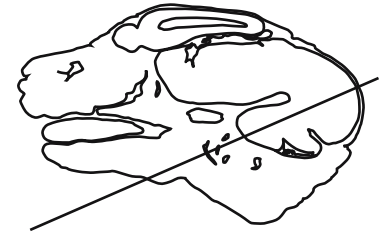




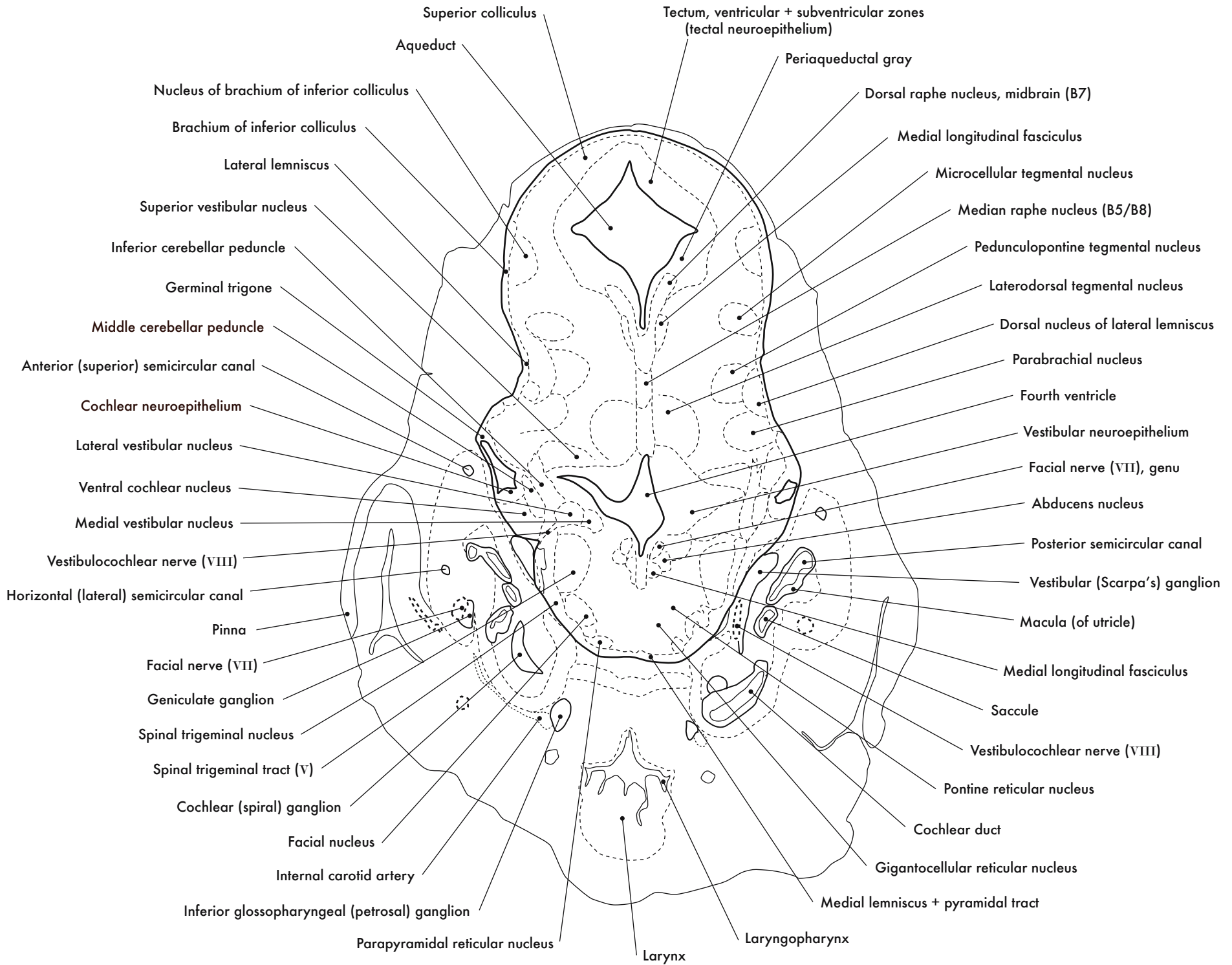
GD 14 CORONAL 22



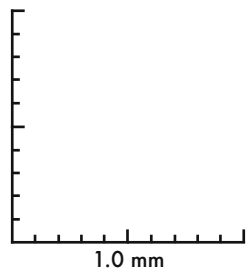
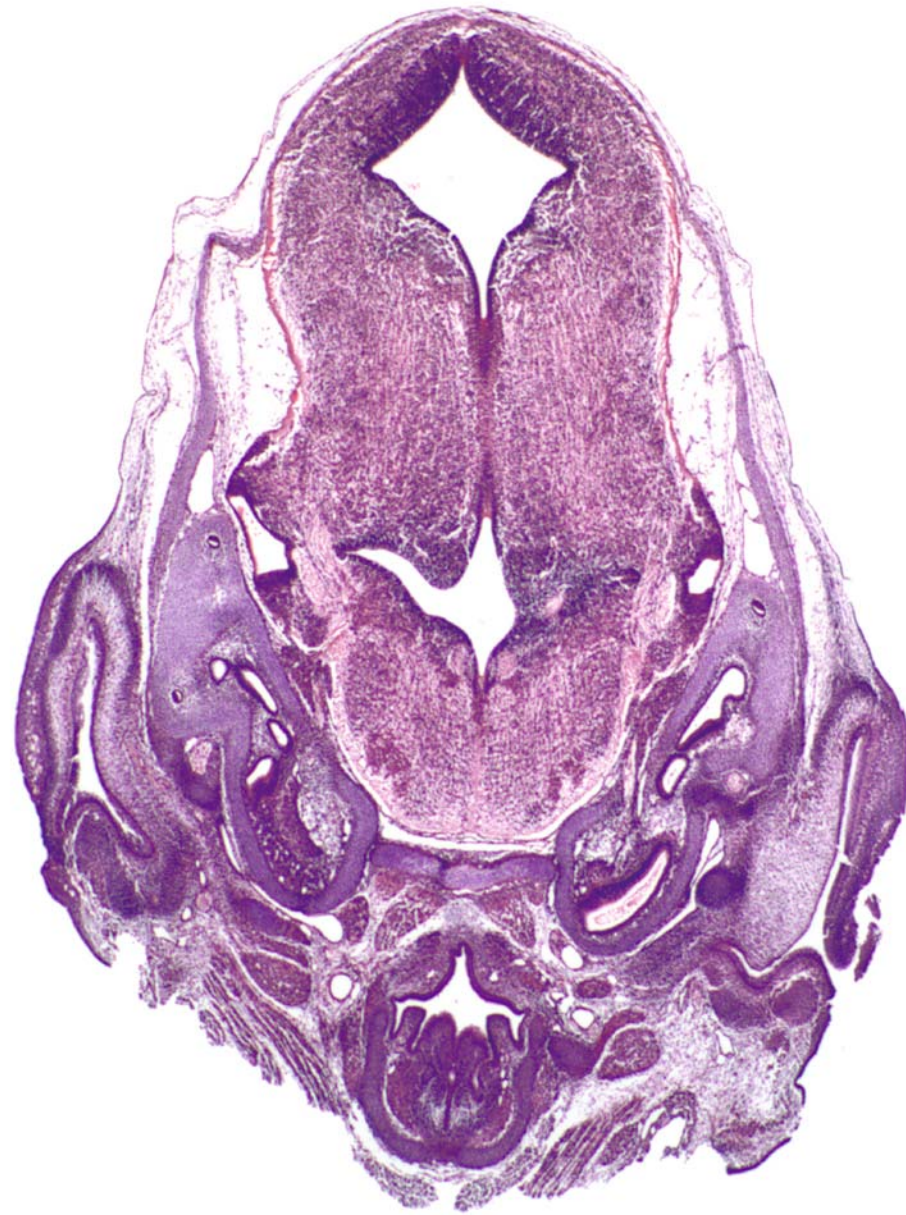
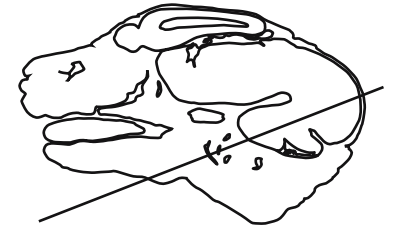




GD 14 CORONAL 23

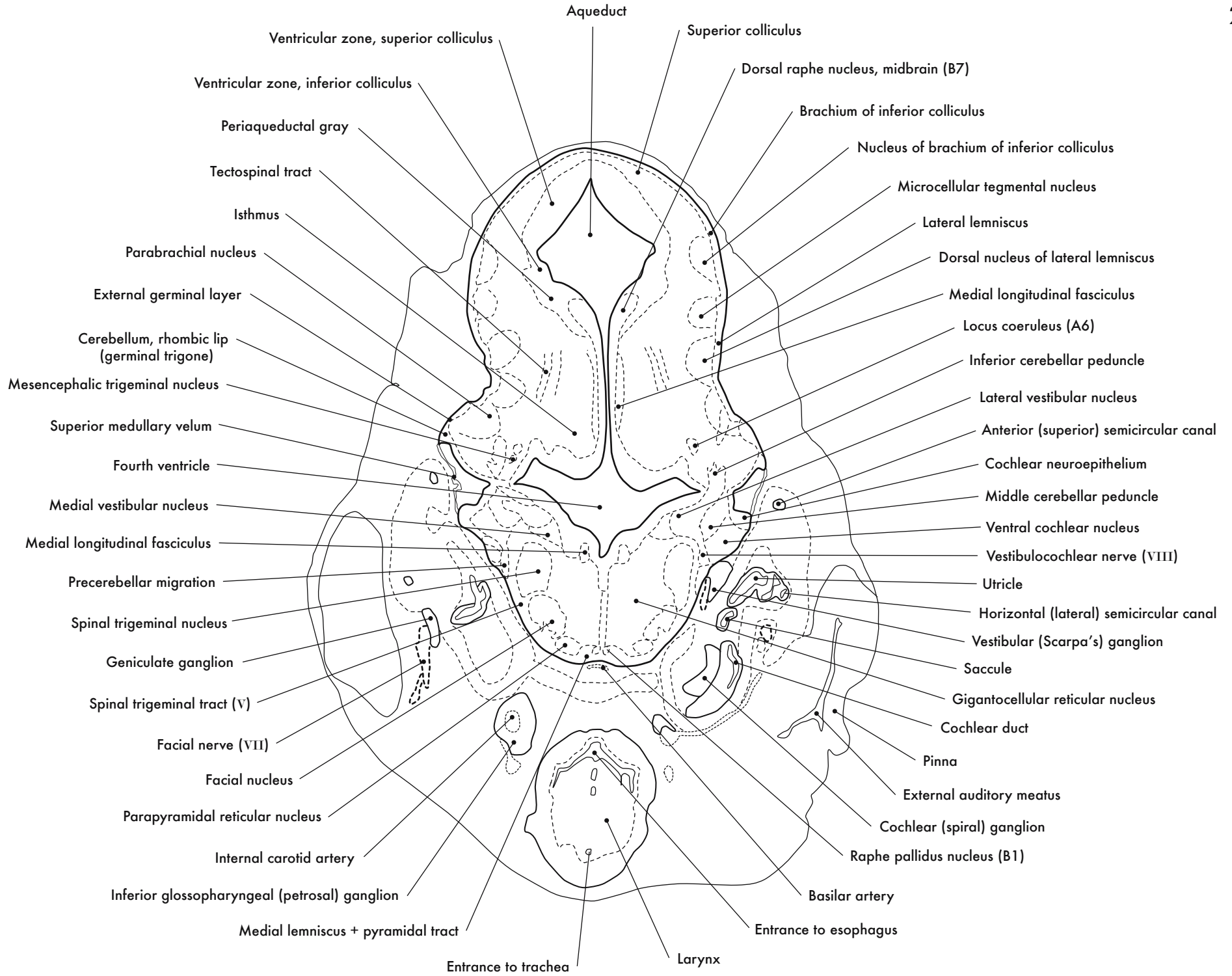


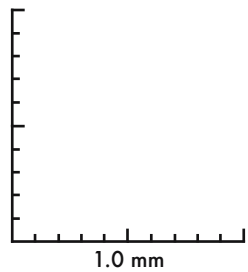
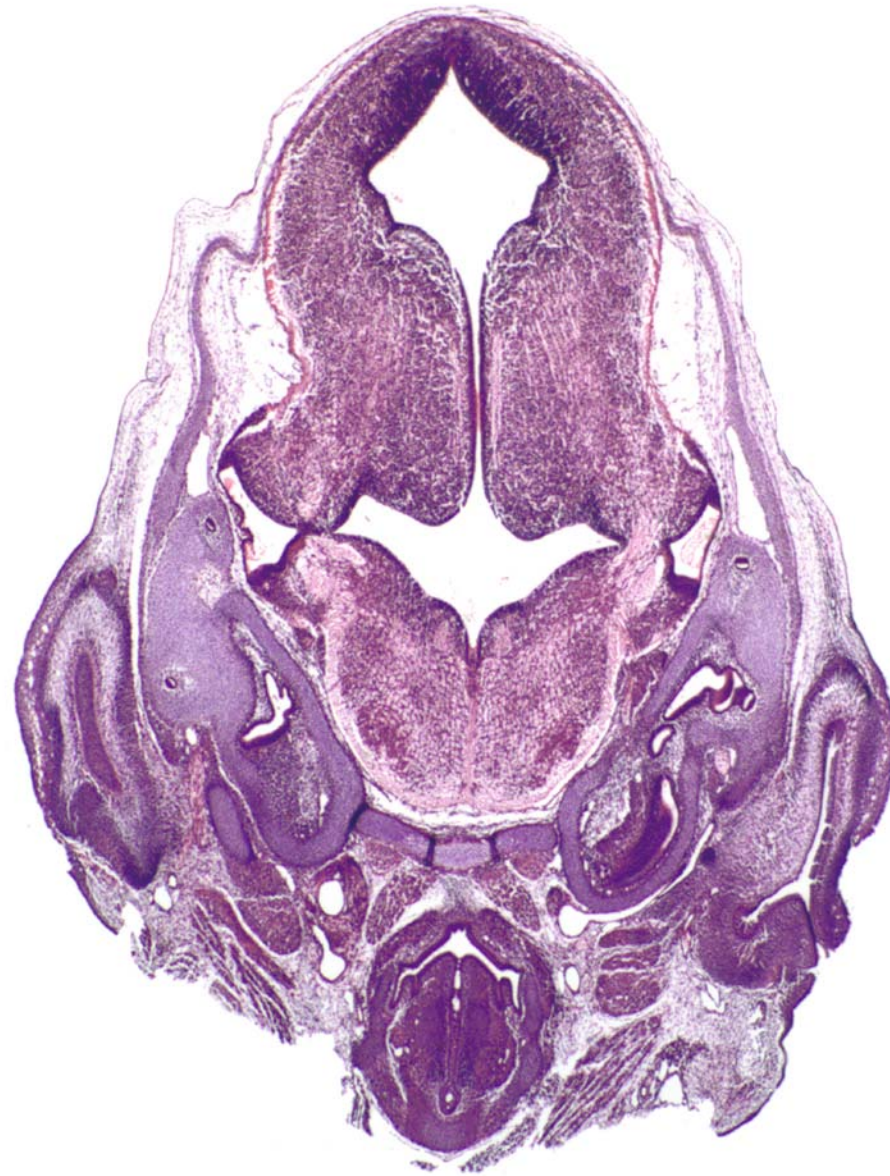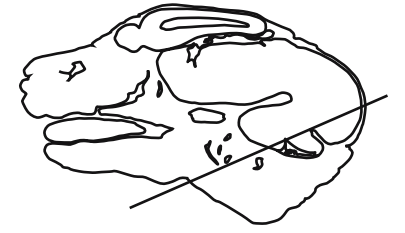




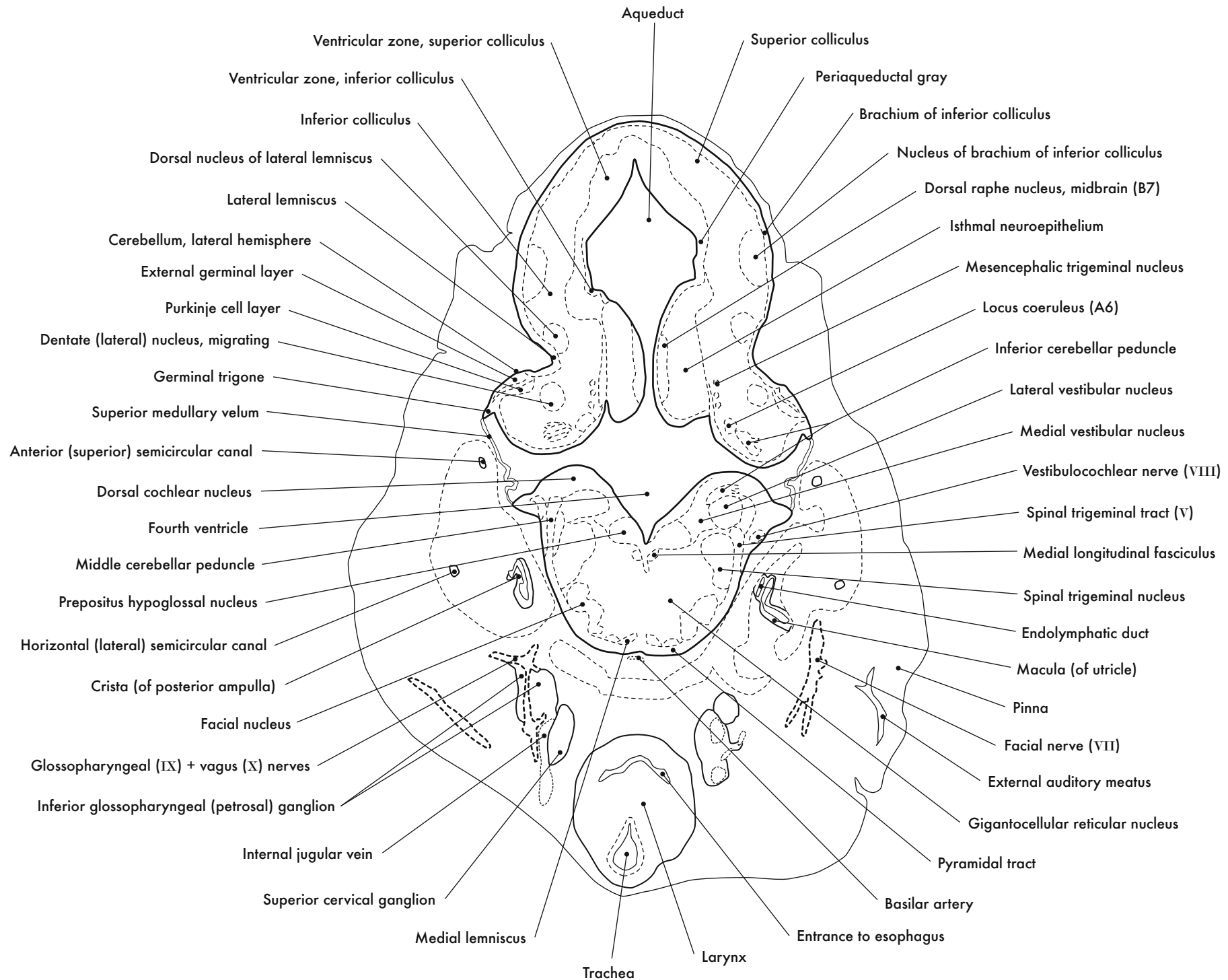
GD 14 CORONAL 24

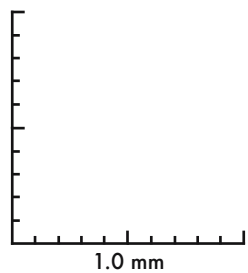
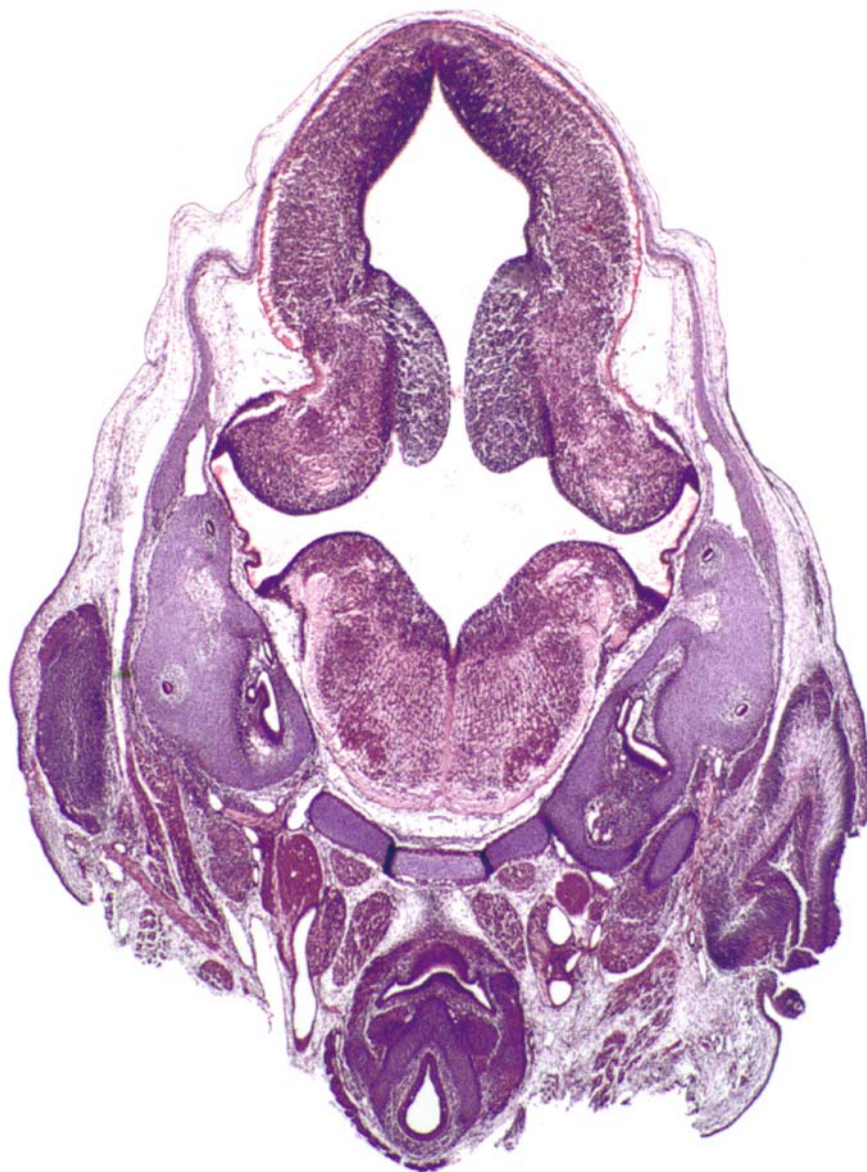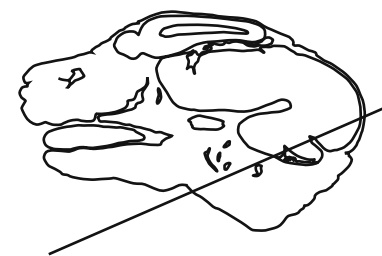






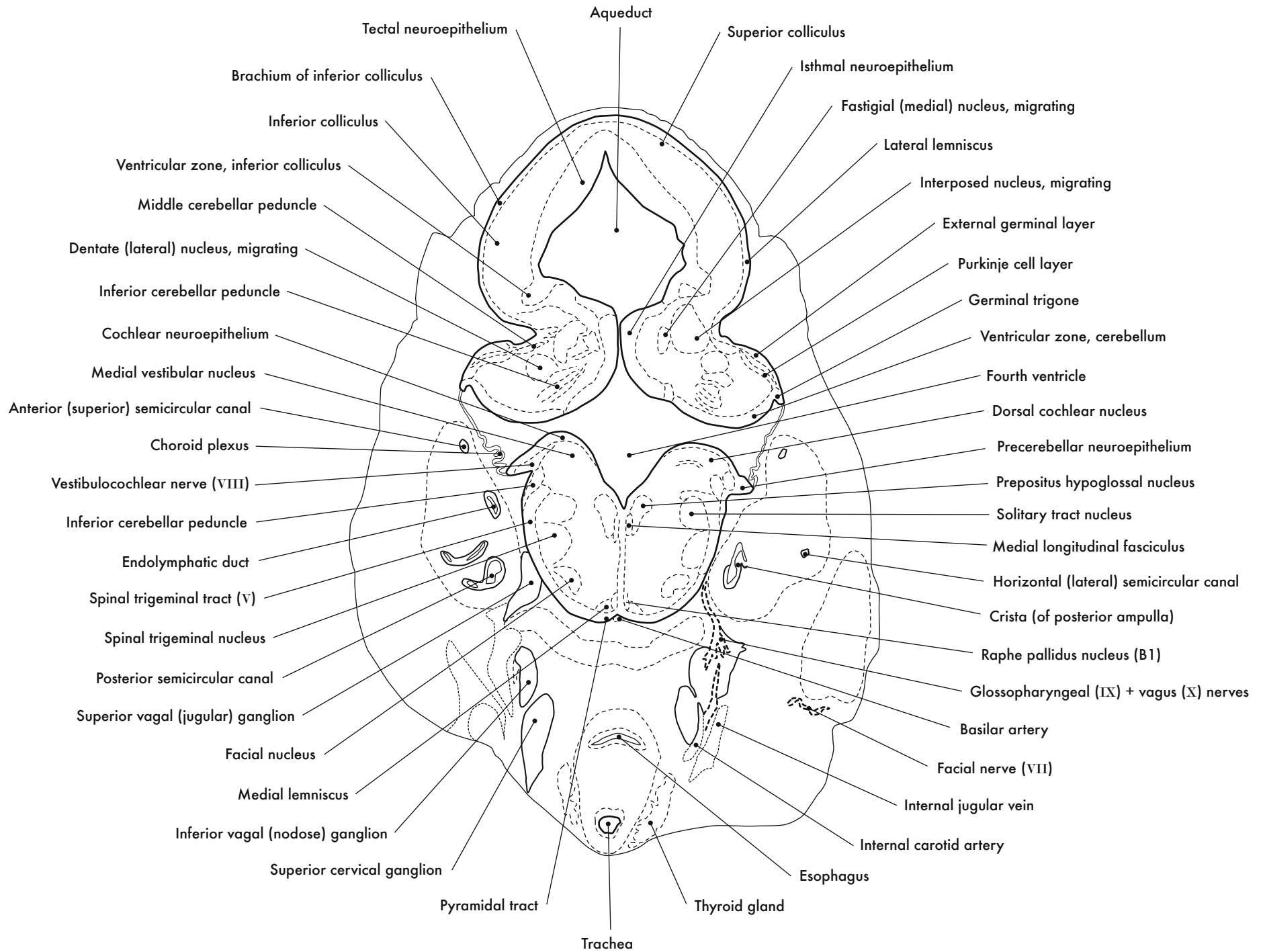
GD 14 CORONAL 25

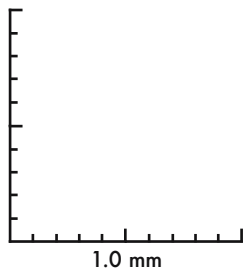
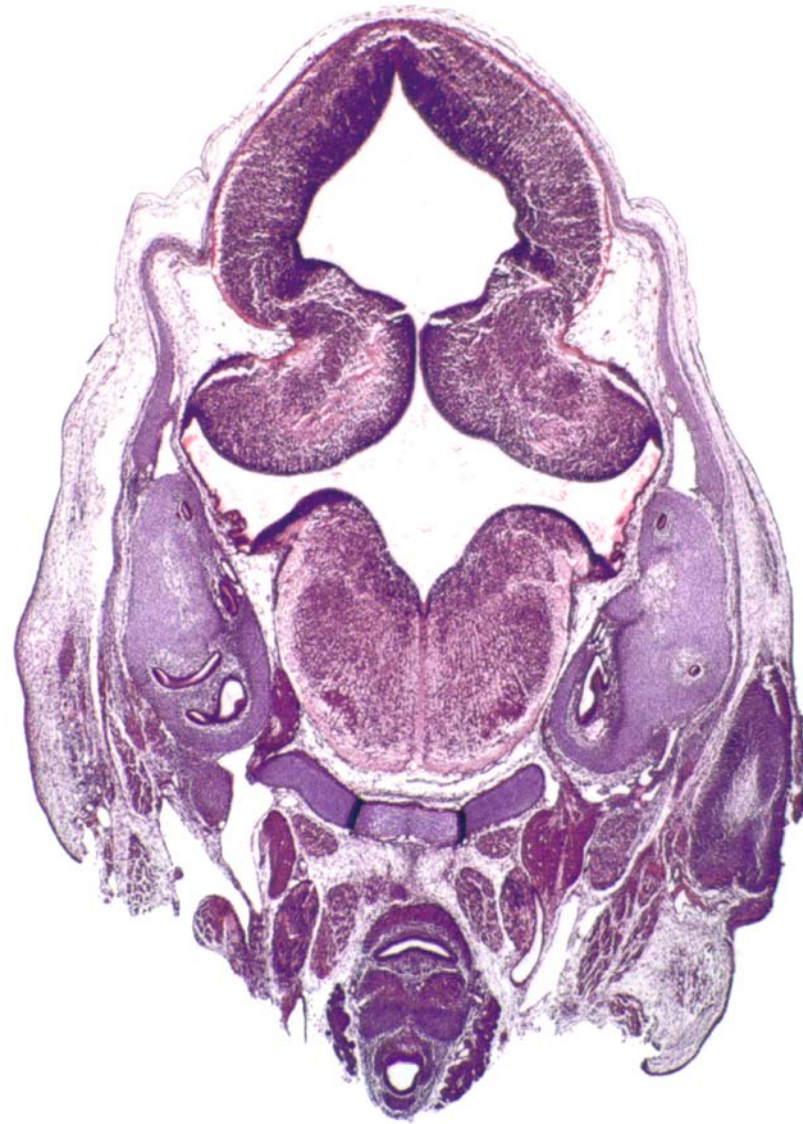
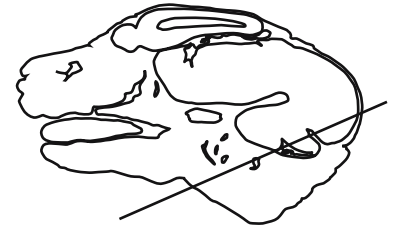


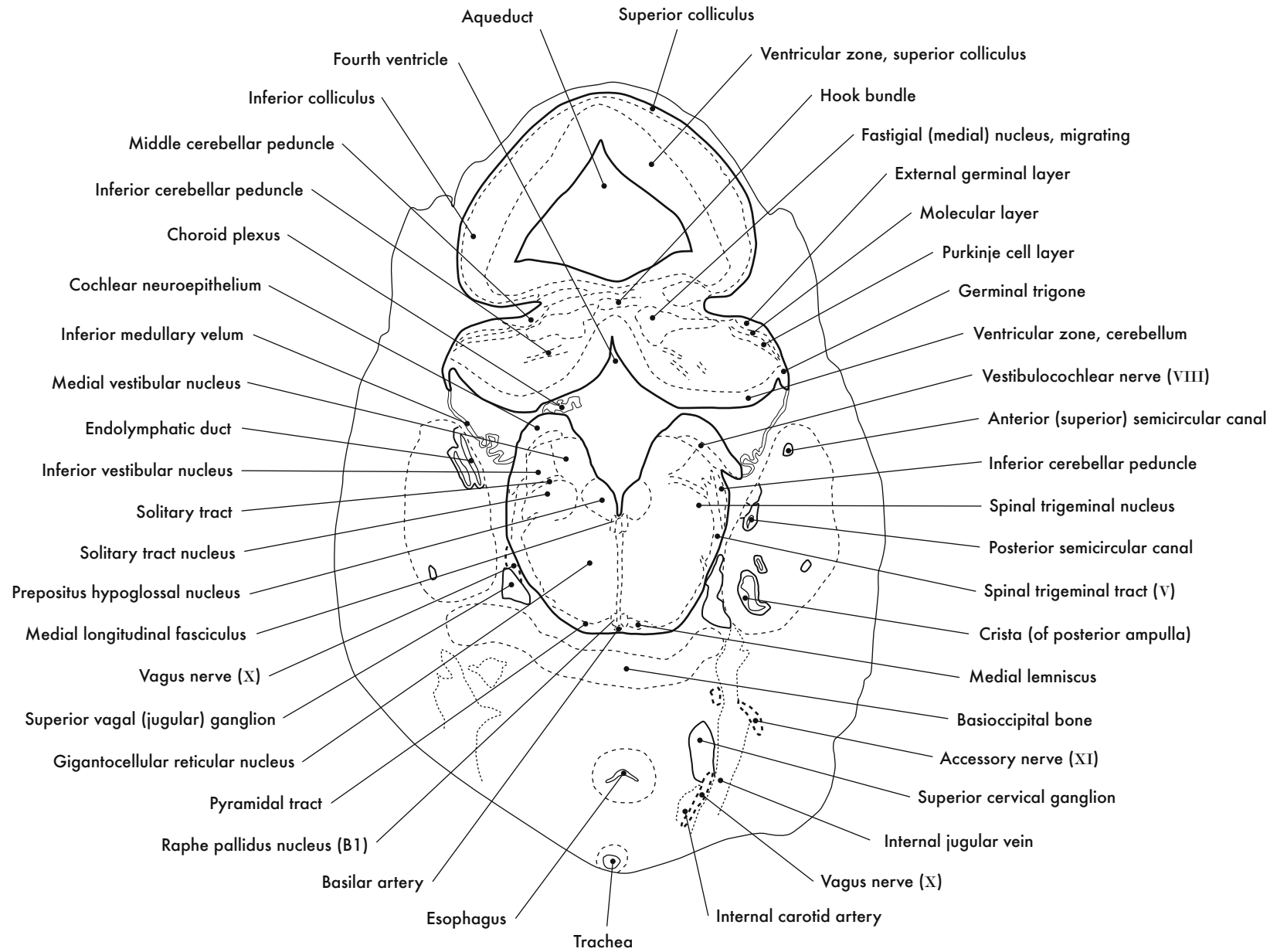
GD 14 CORONAL 26

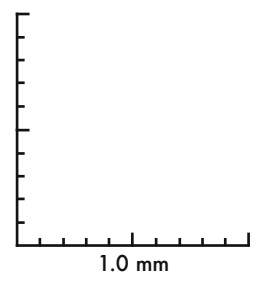
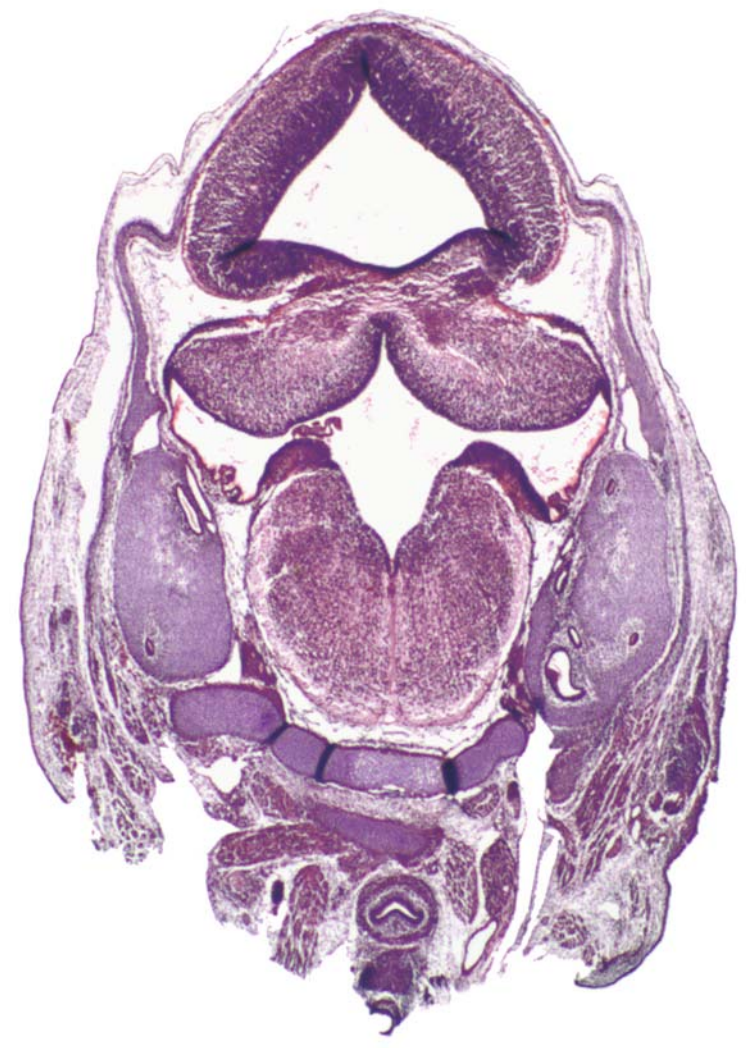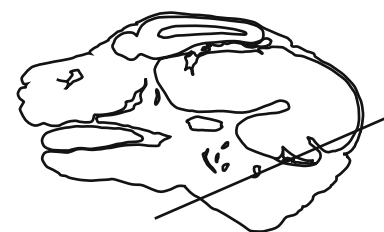






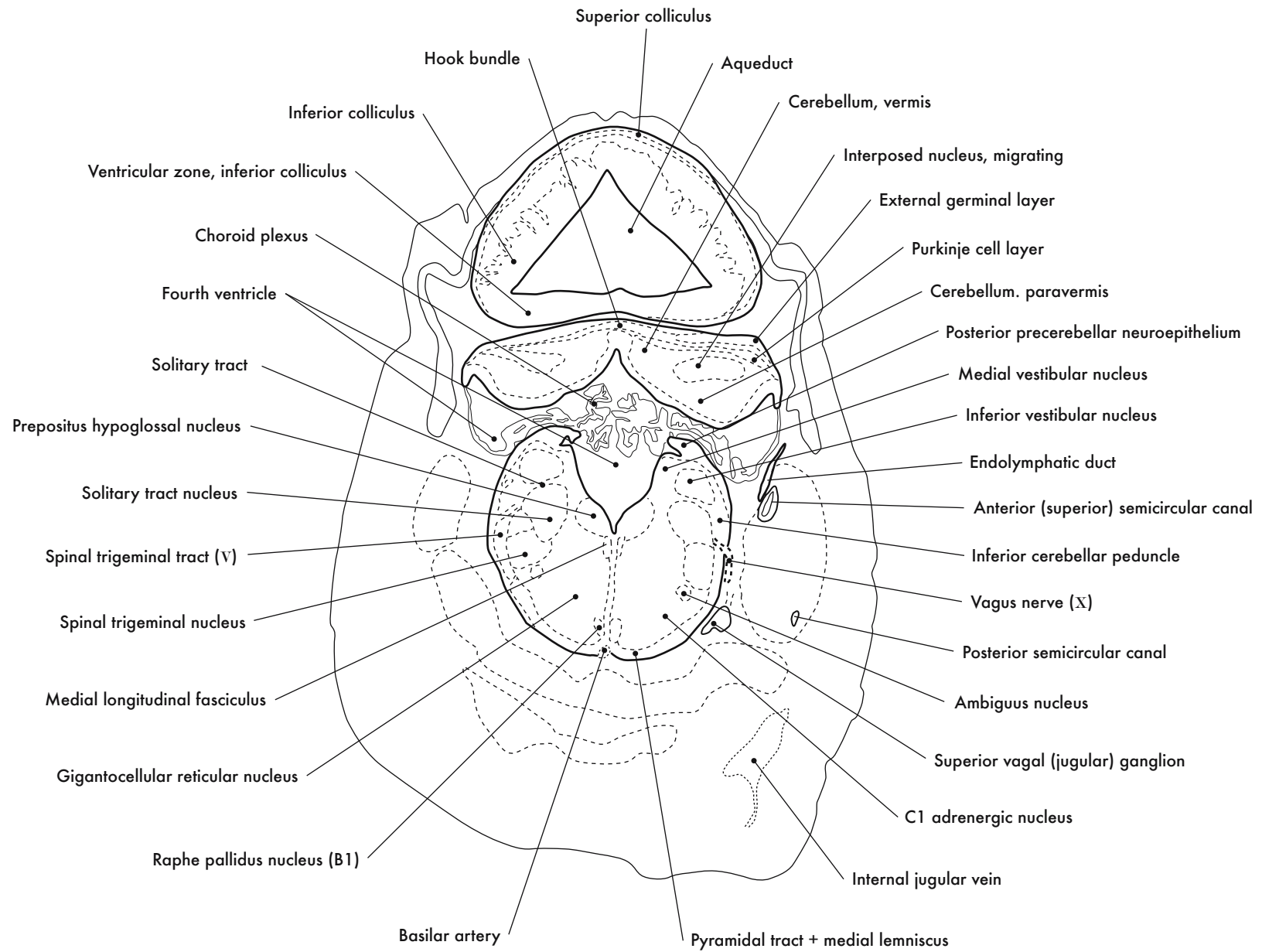
GD 14 CORONAL 27

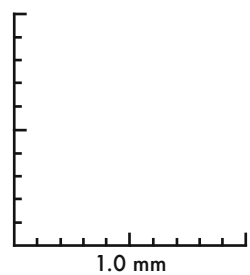
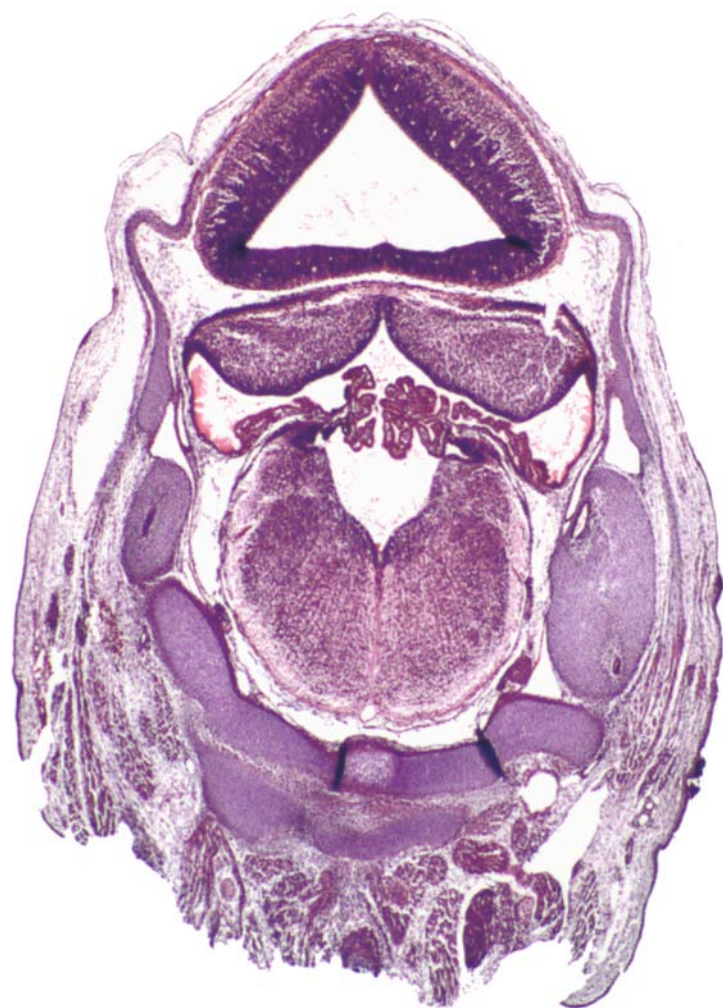
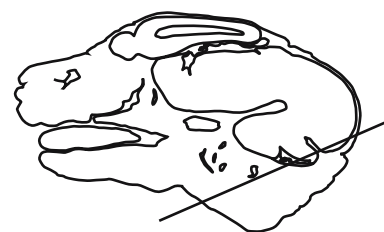


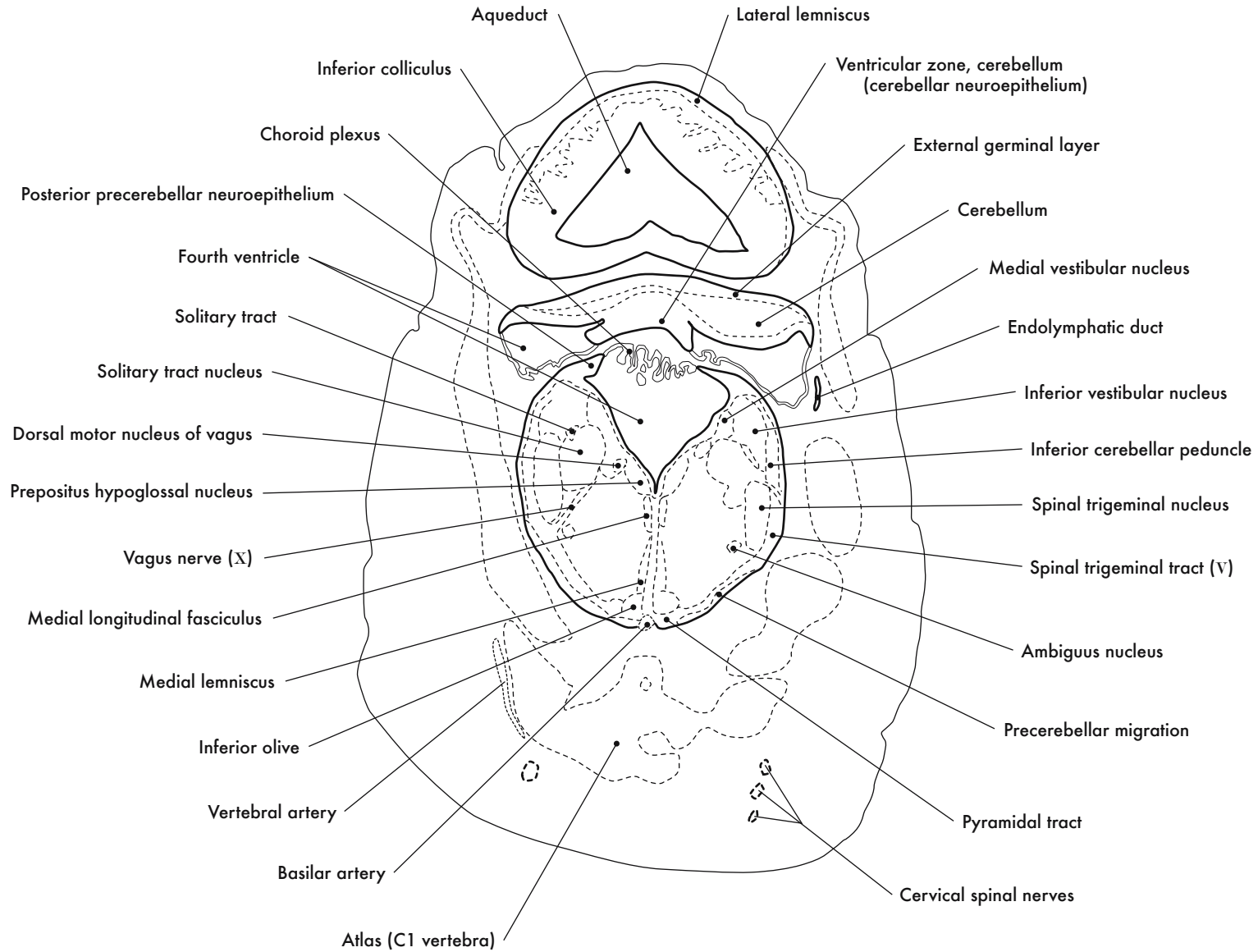
GD 14 CORONAL 28

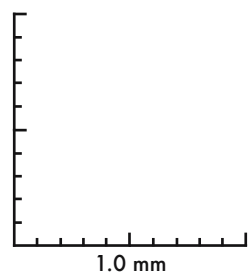
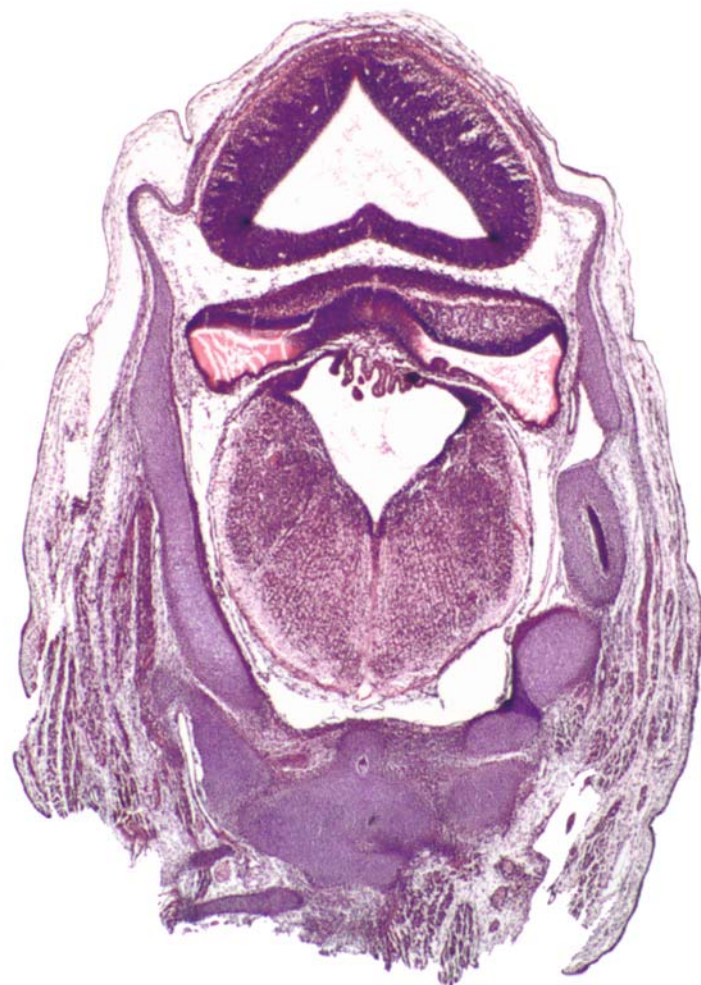
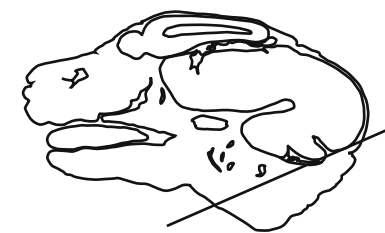





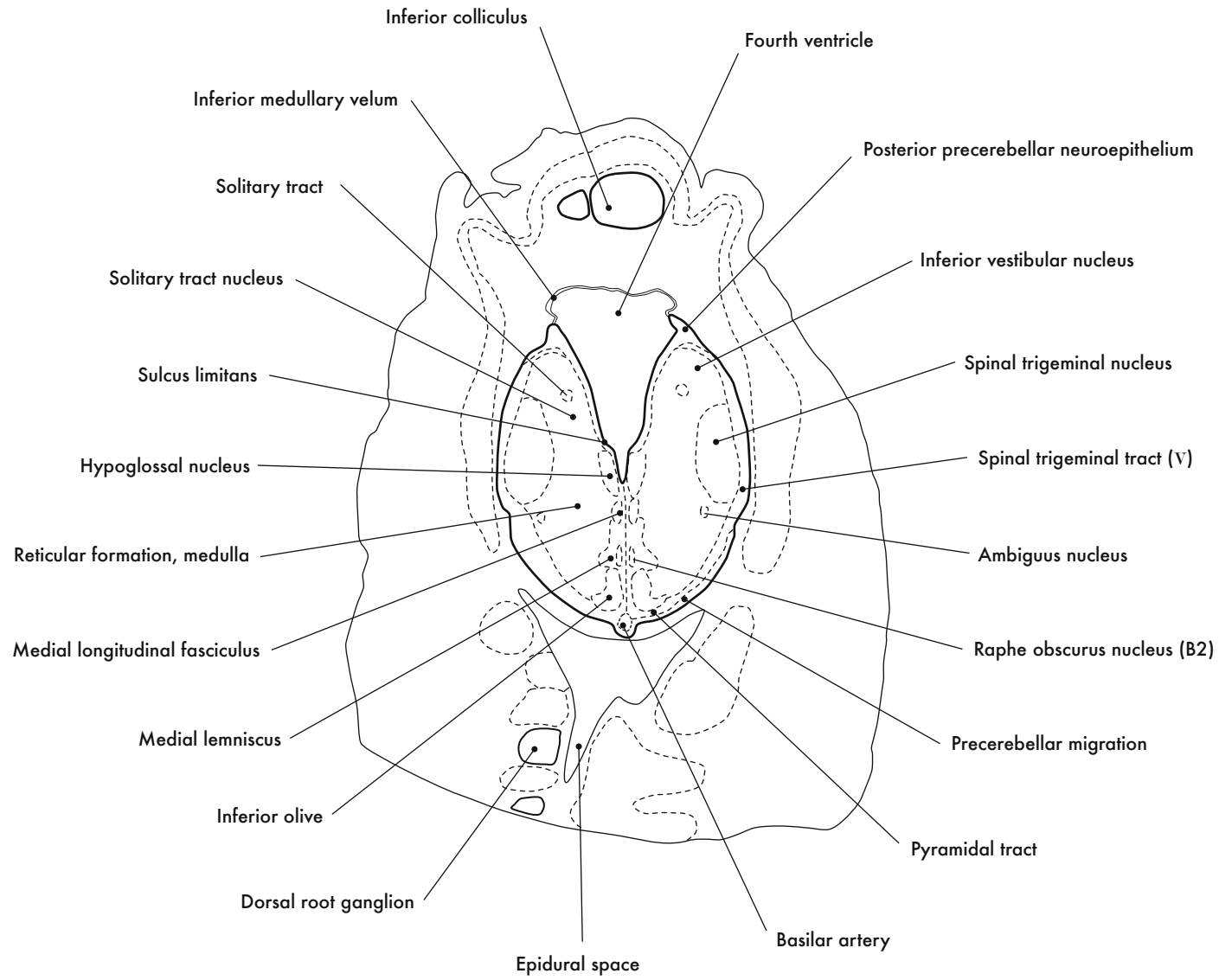
GD 14 CORONAL 29

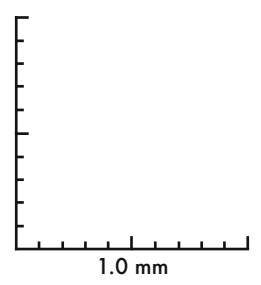
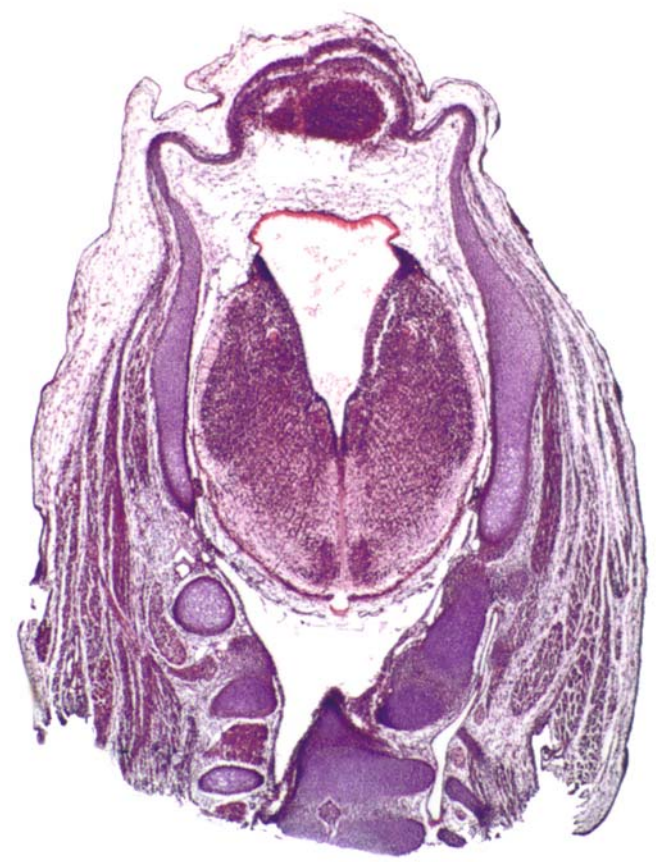
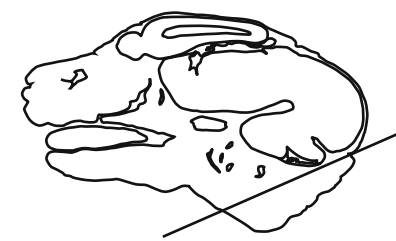



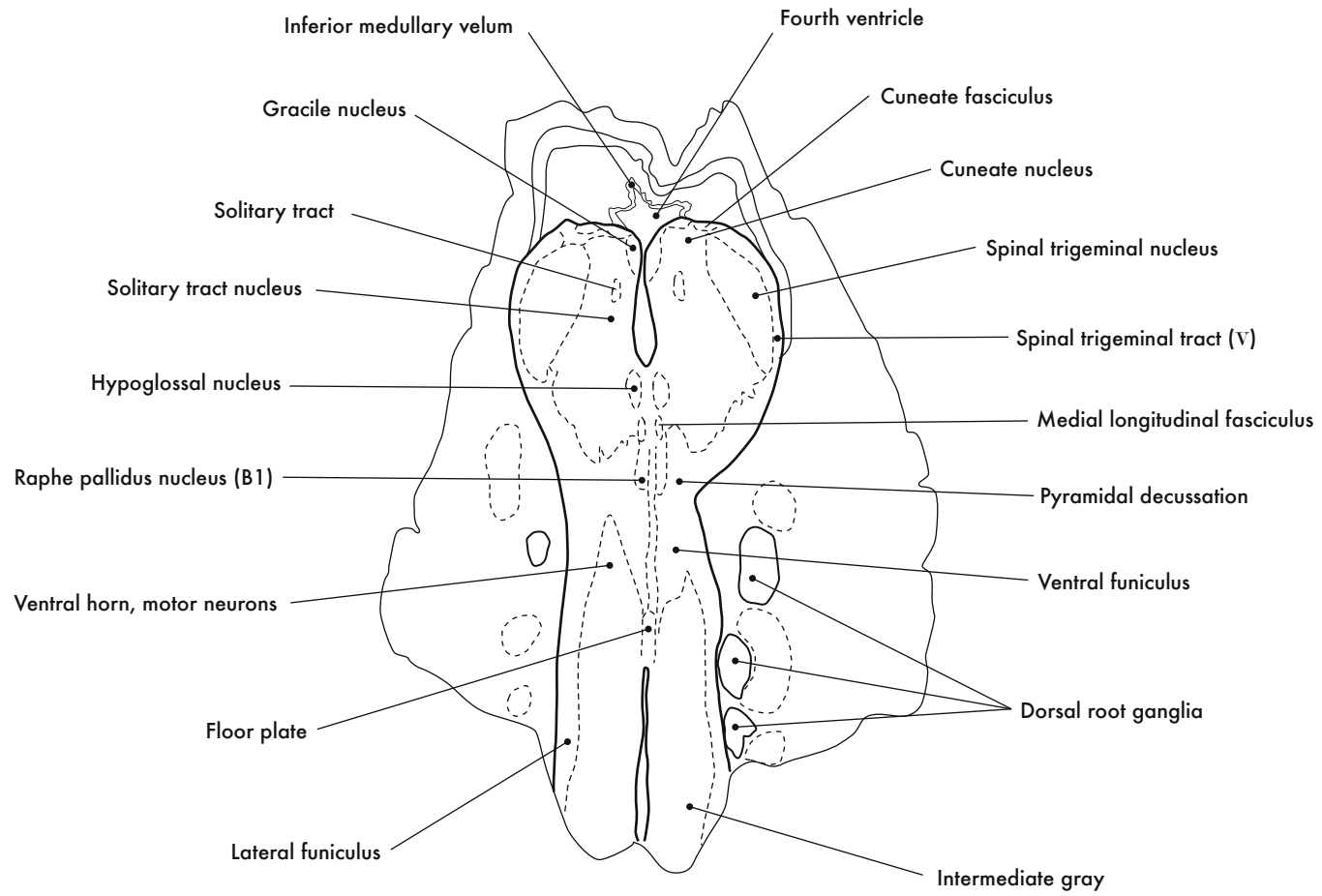
GD 14 CORONAL 30

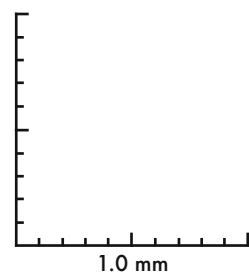
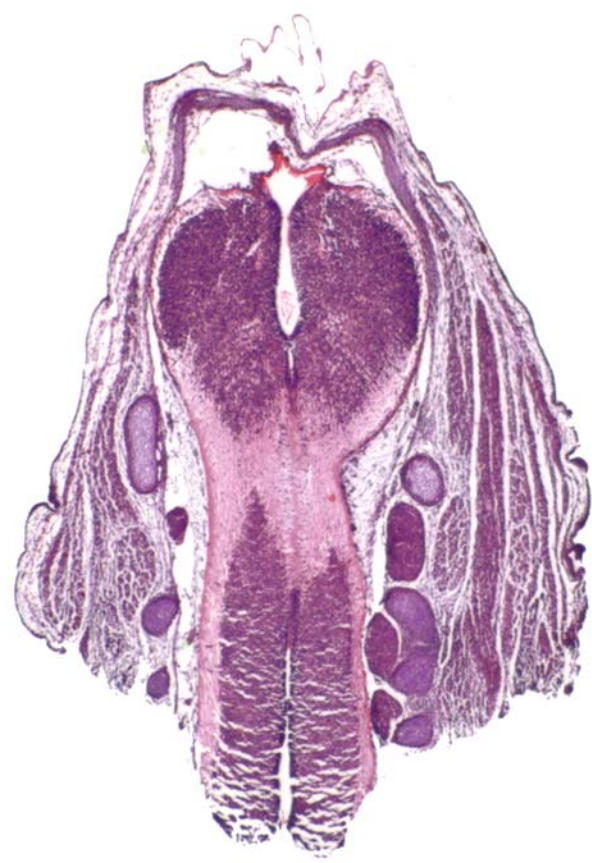
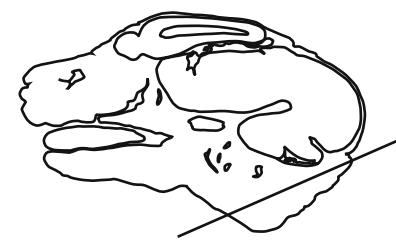





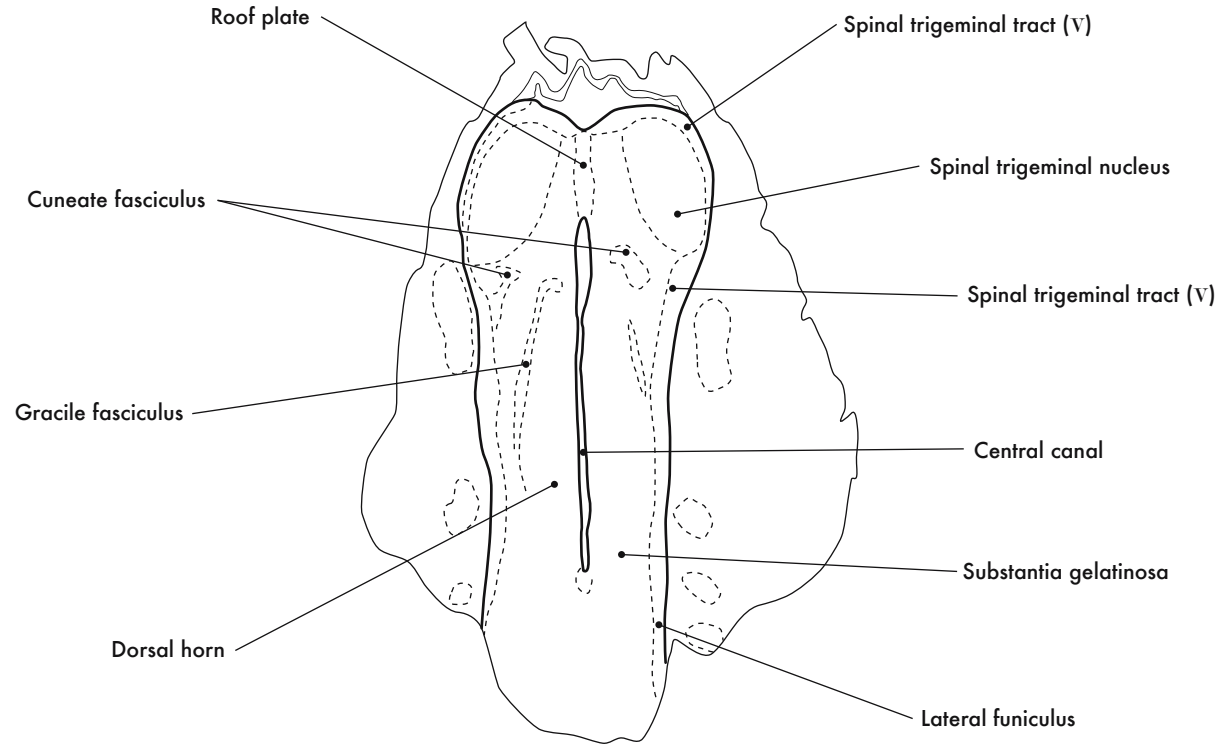
GD 14 CORONAL 31

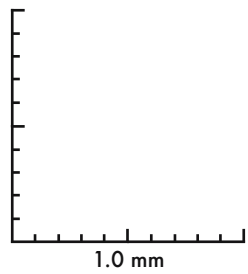
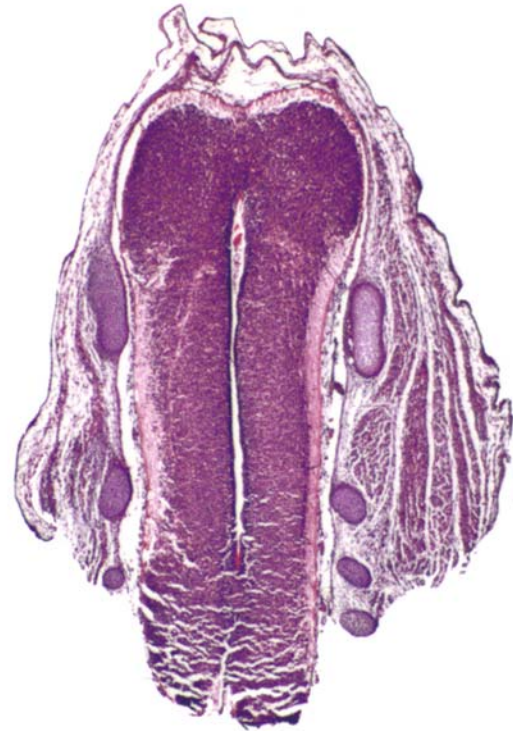
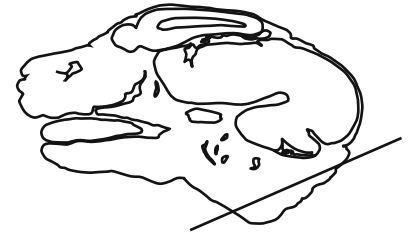



GD 14 CORONAL 32






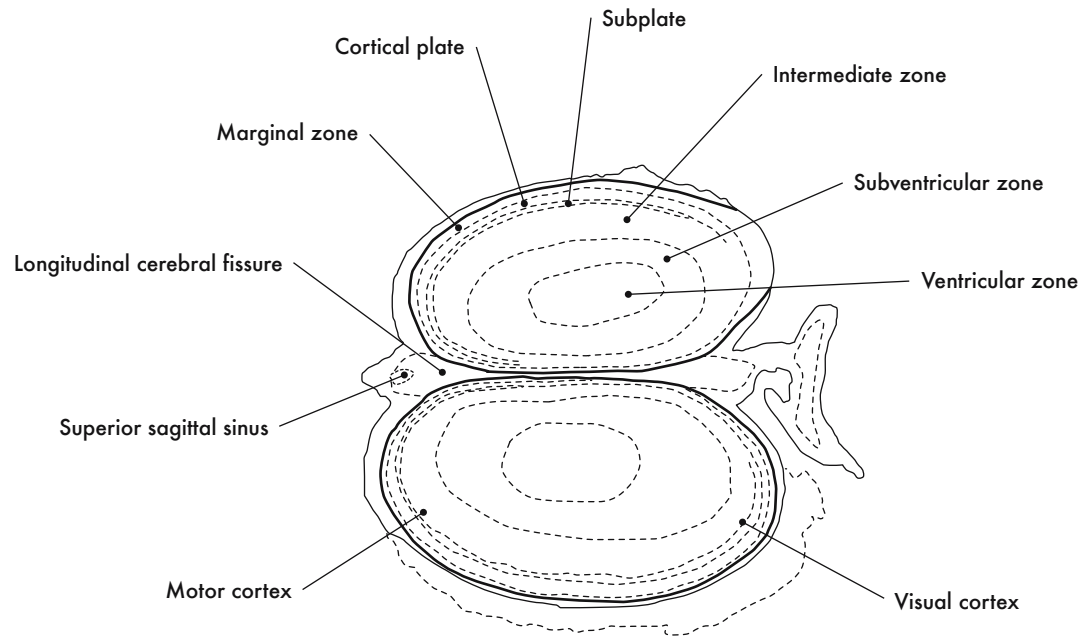


GD 14 CORONAL 33

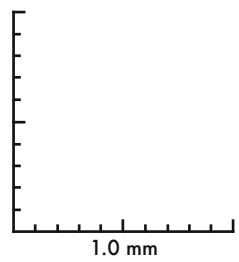
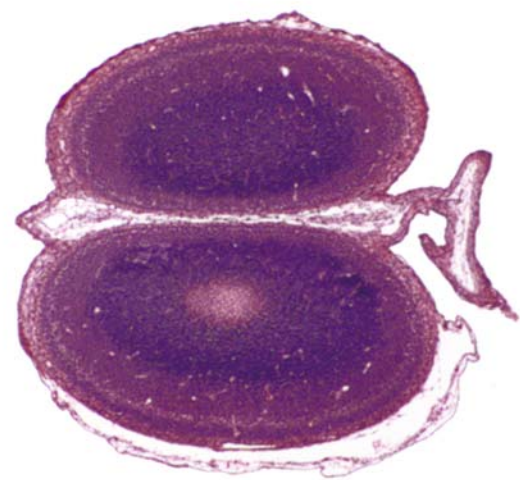
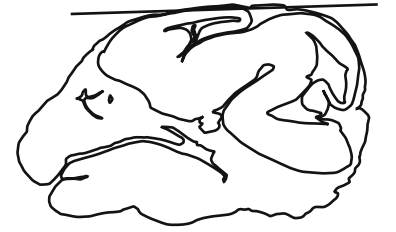HP denotes image enlargement



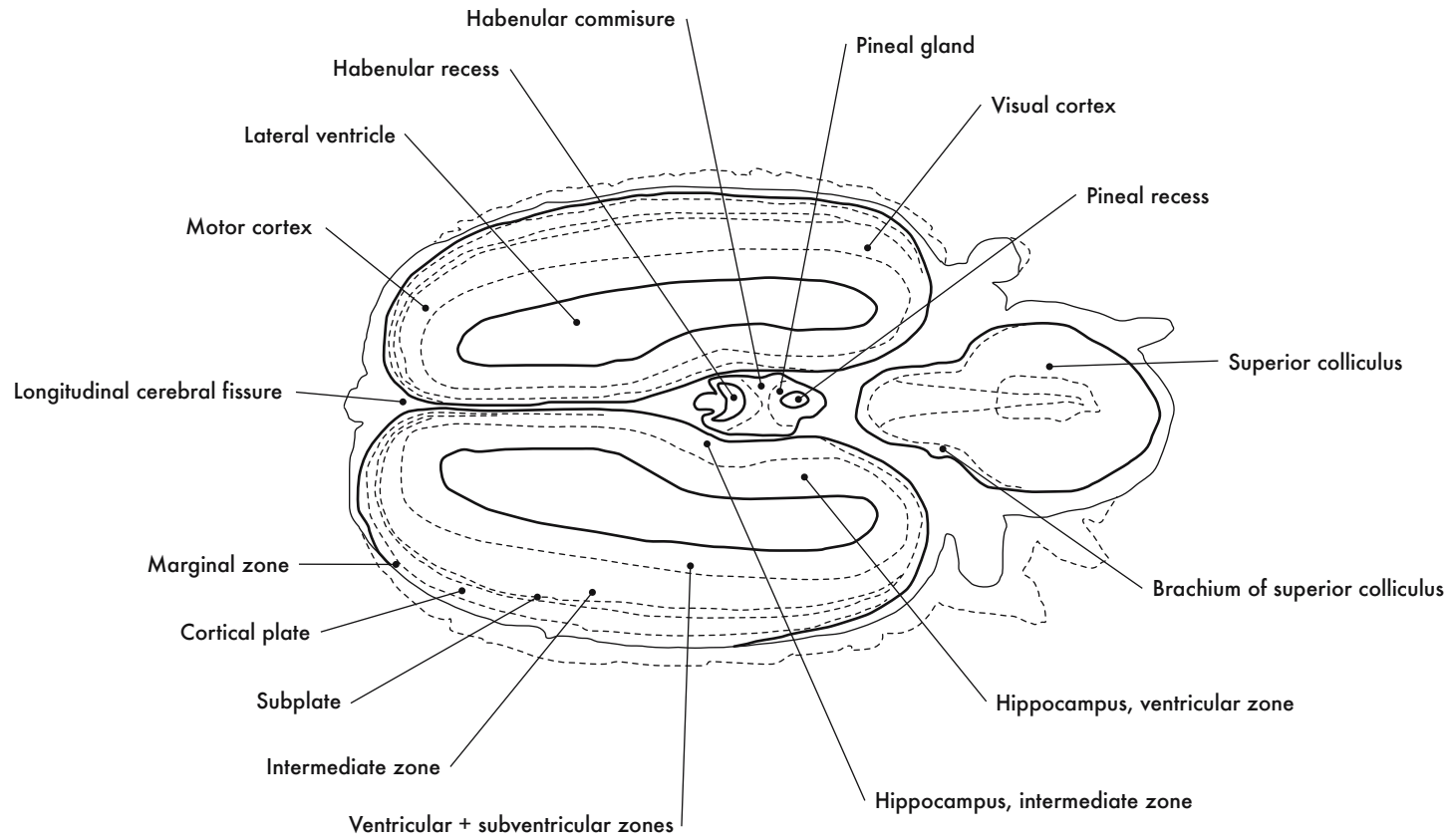
**GESTATIONAL DAY 14 (GD 14)  
HORIZONTAL SECTIONS**

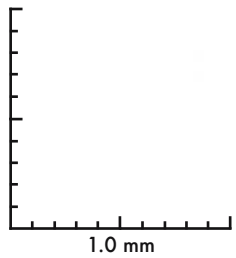
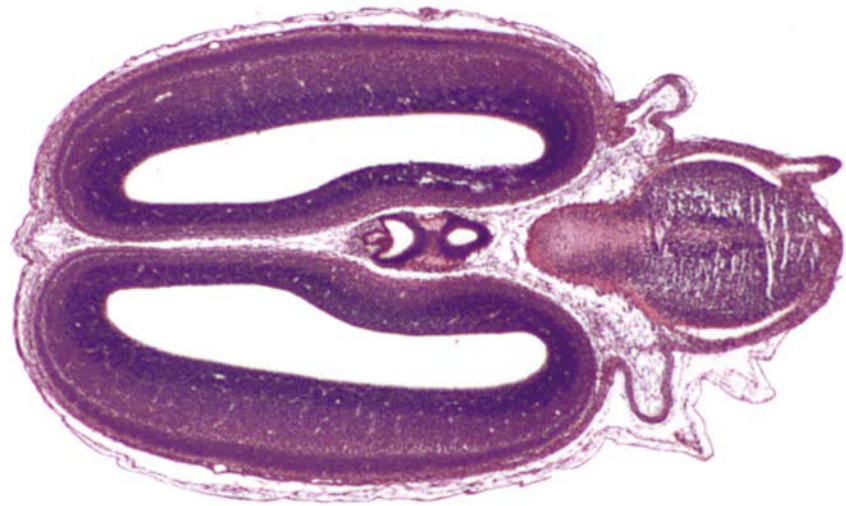
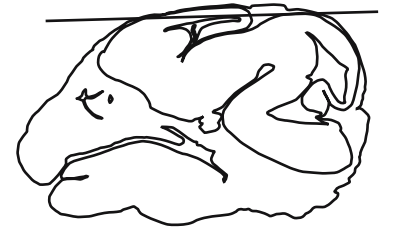



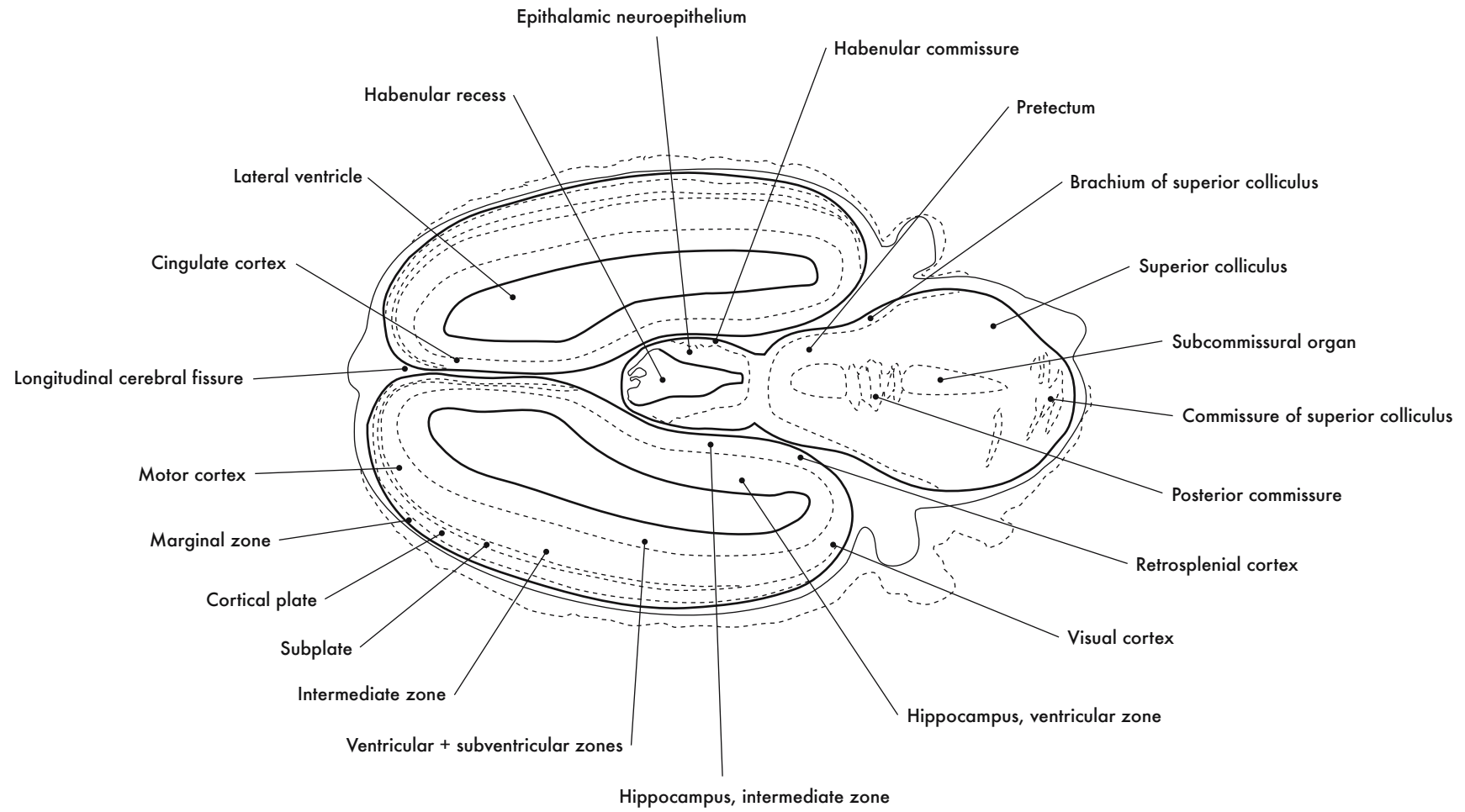


GD 14 HORIZONTAL 1

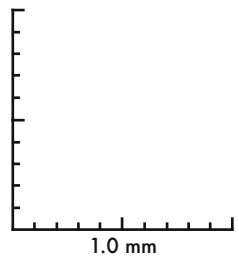
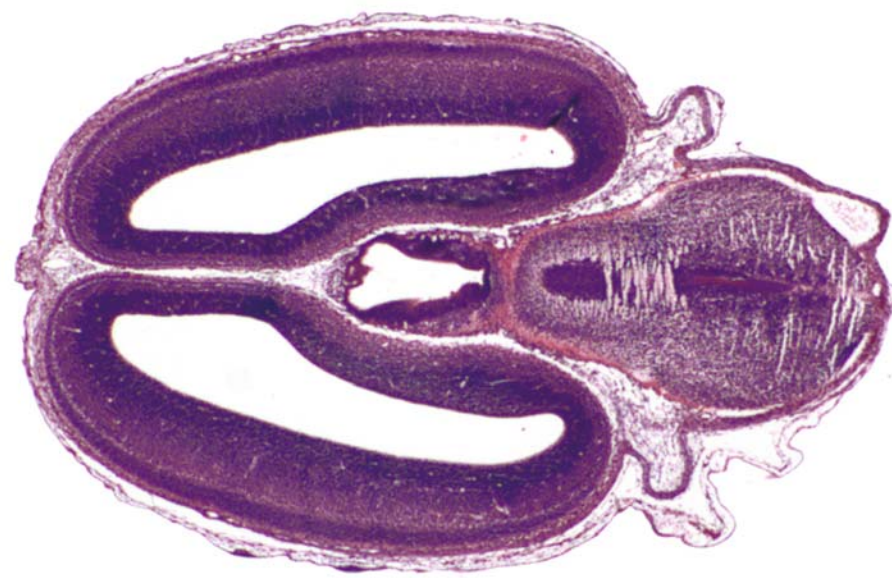
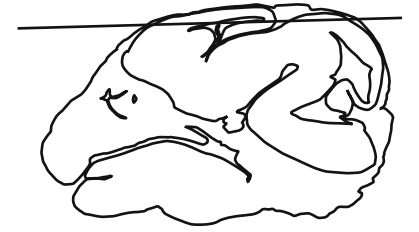



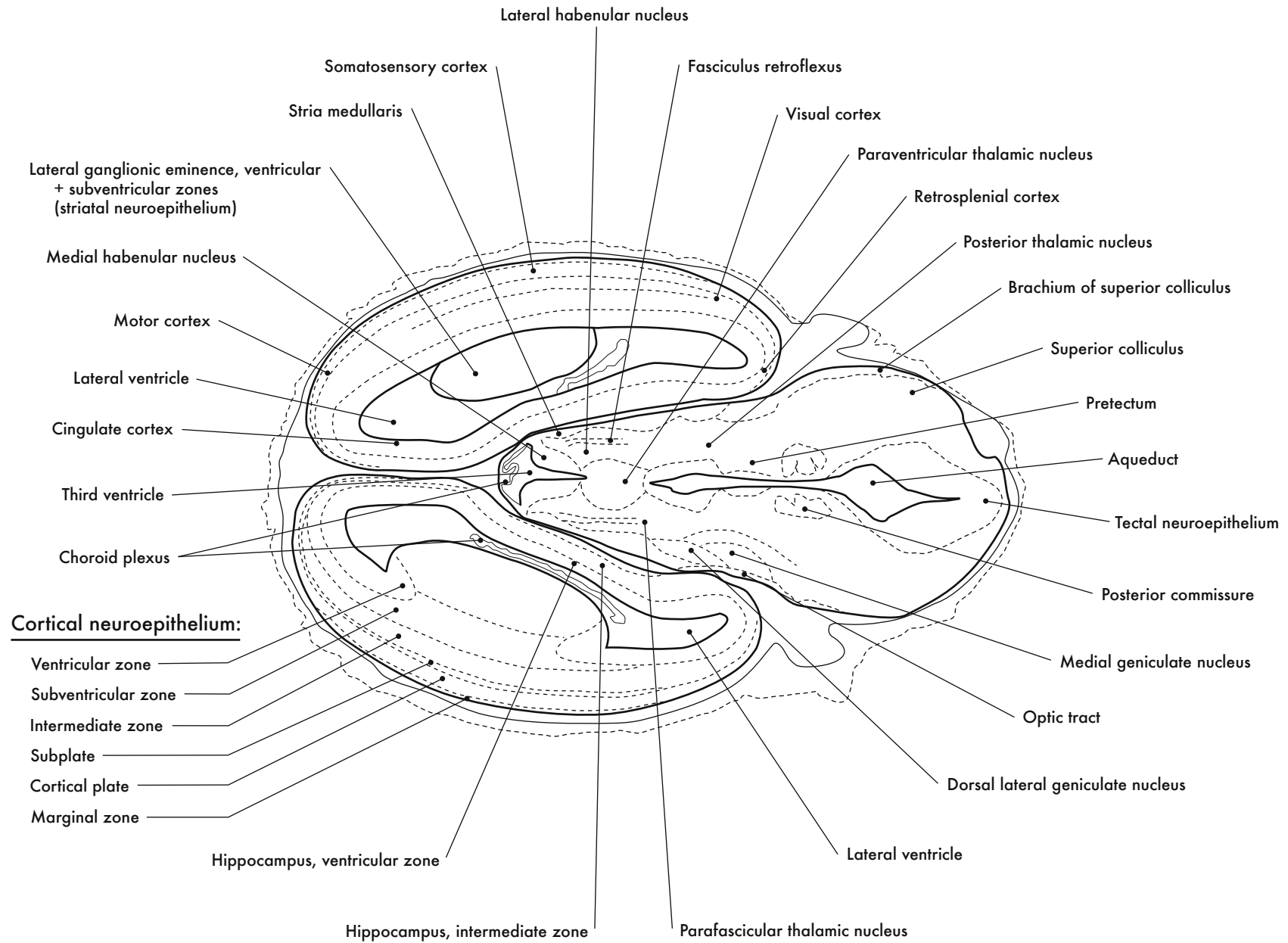
GD 14 HORIZONTAL 2

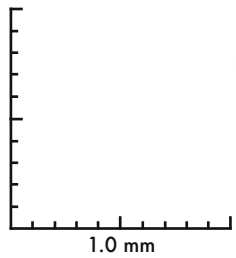
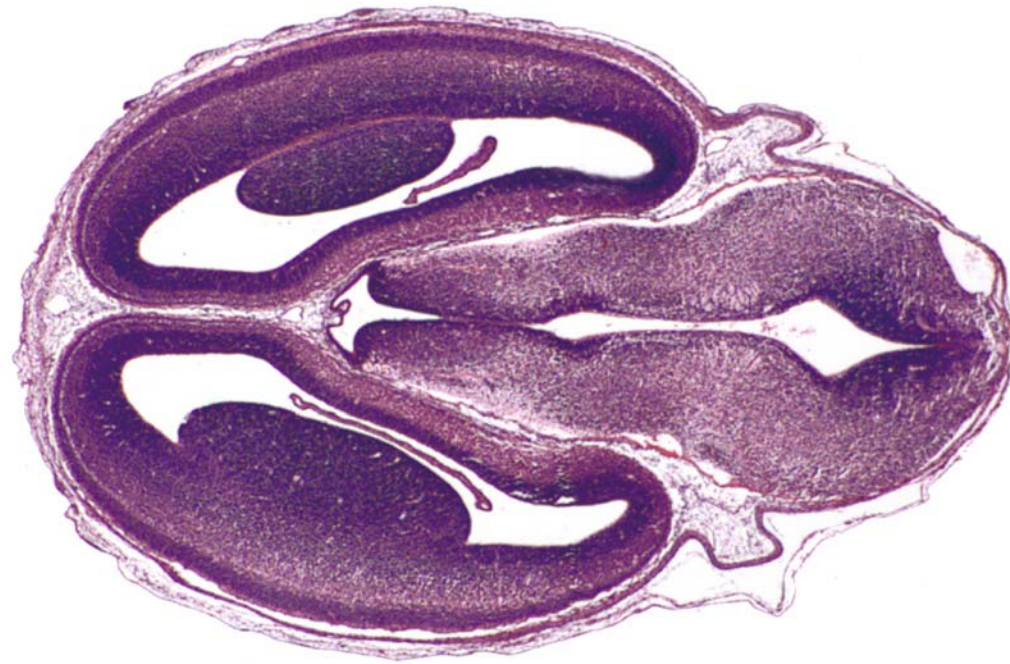
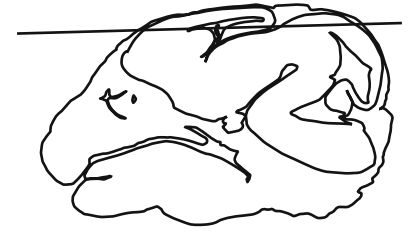


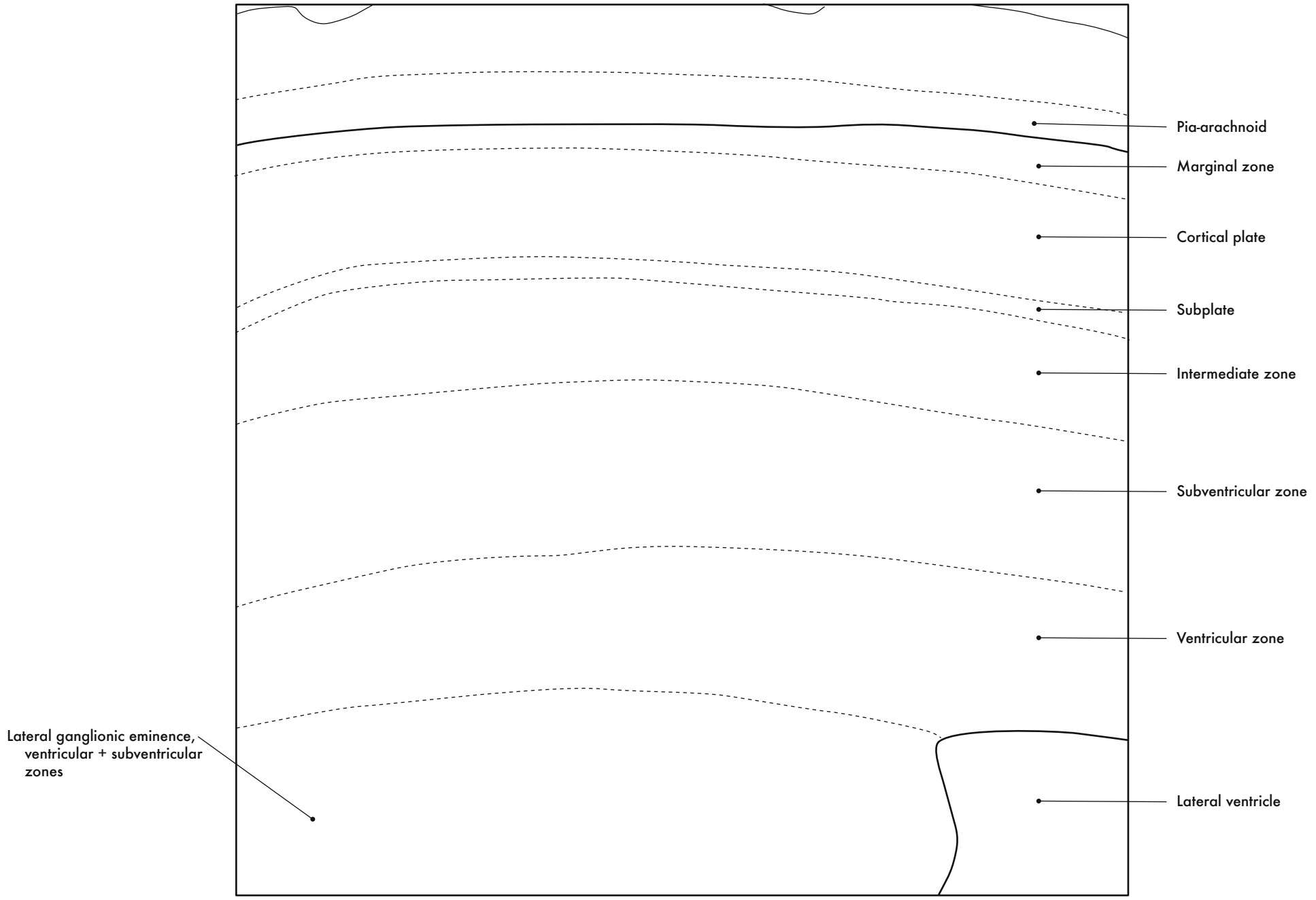


GD 14 HORIZONTAL 3



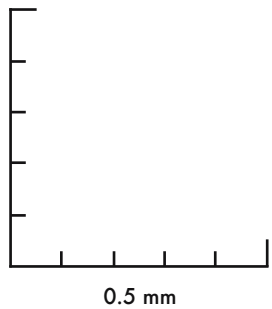
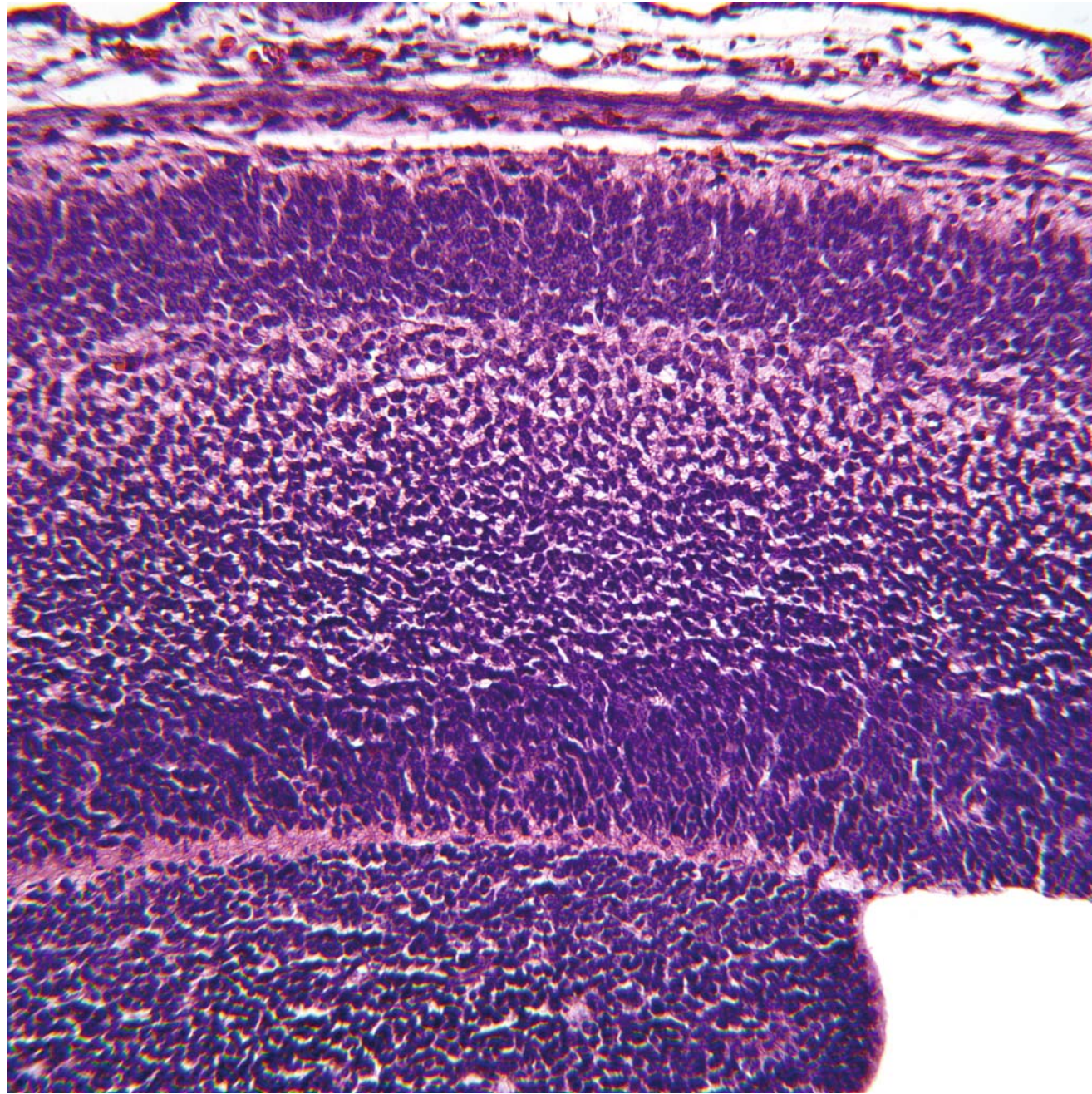
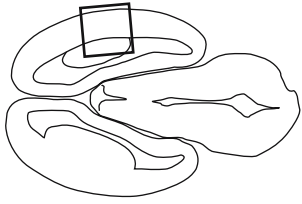


GD 14 HORIZONTAL 4



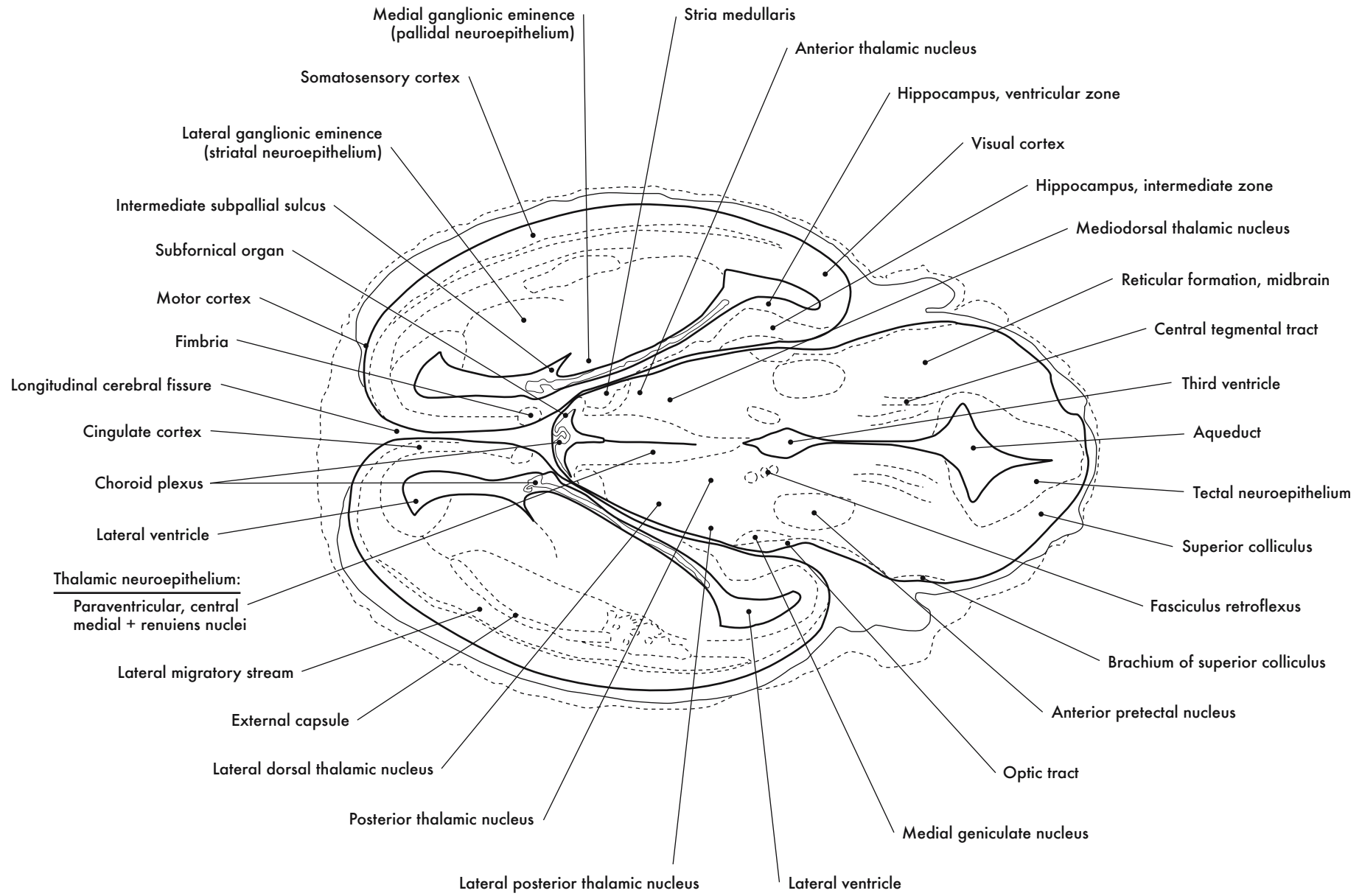
Cortical Neuroepithelium and Lateral Ganglionic Eminence



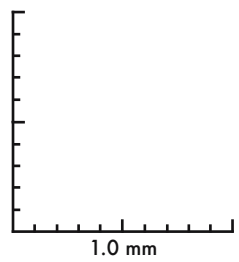
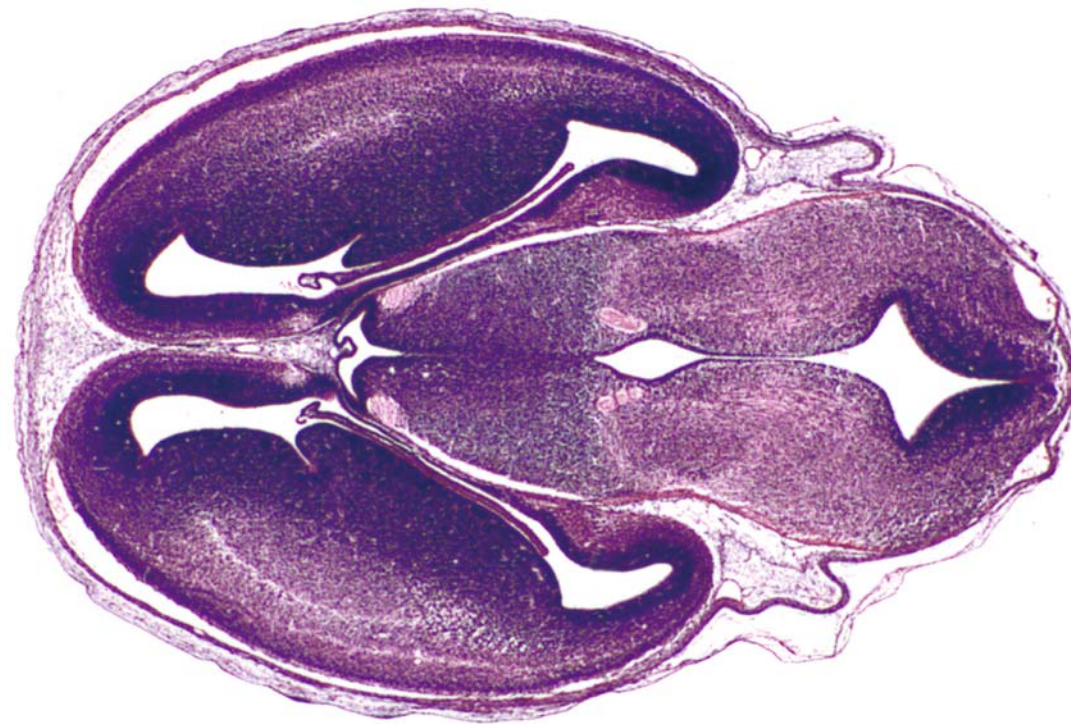


0.5 mm

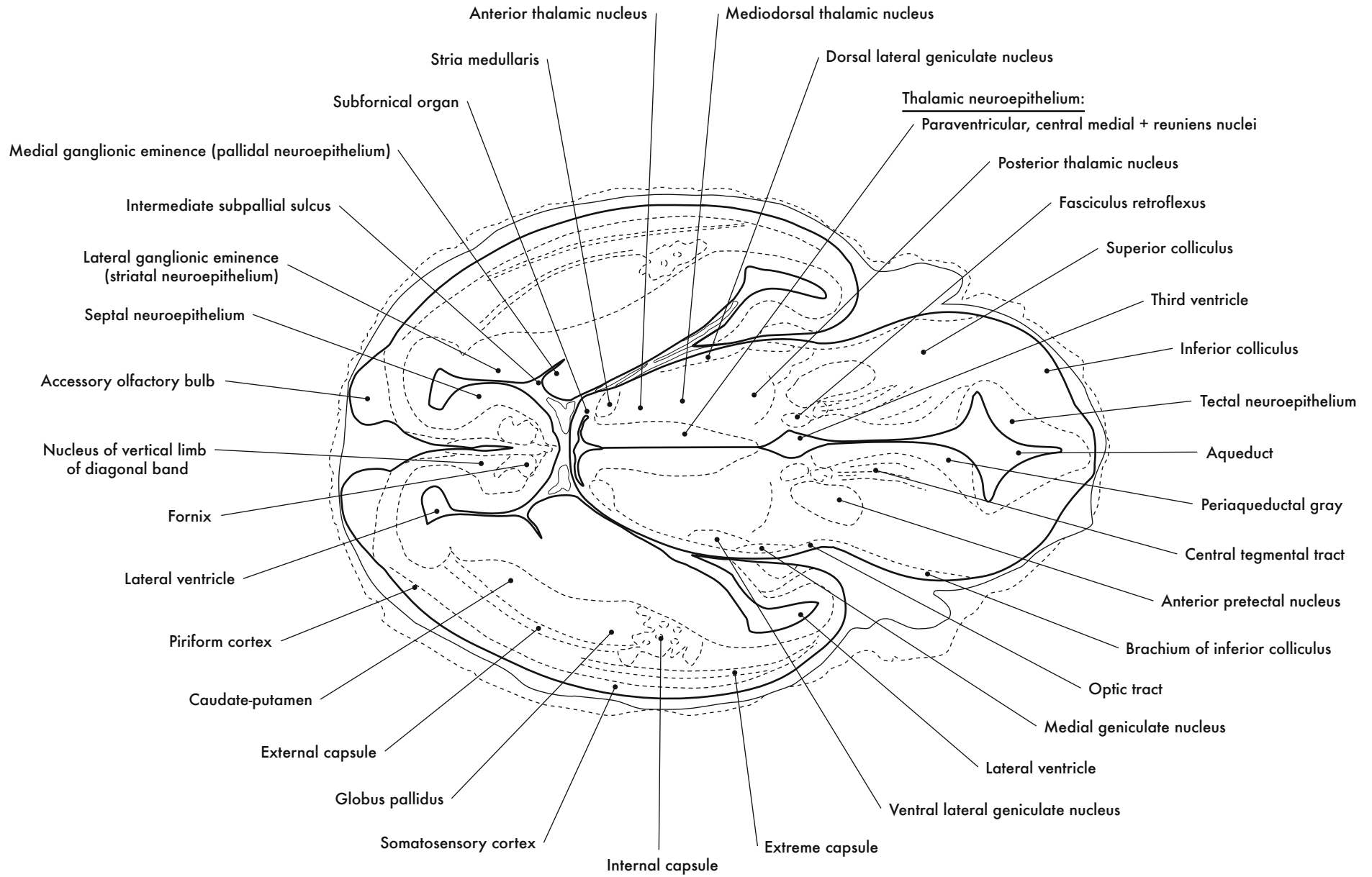
GD 14 HORIZONTAL 5



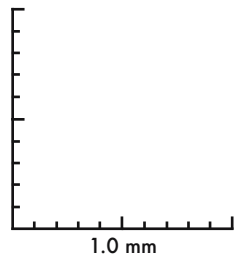
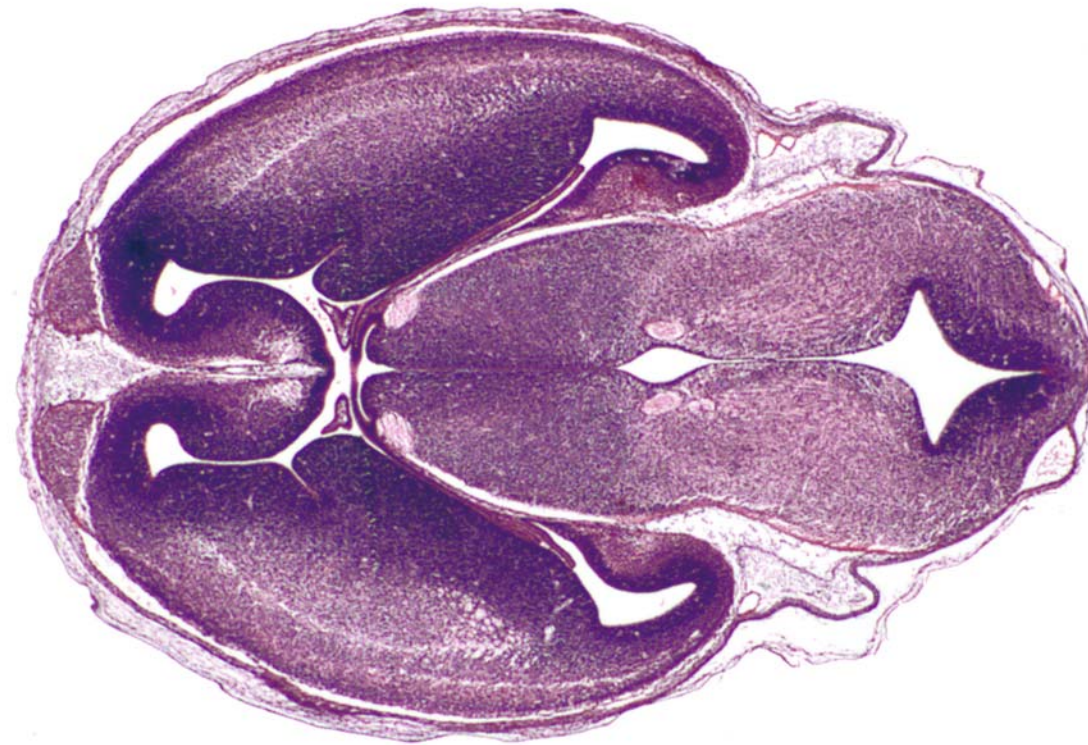




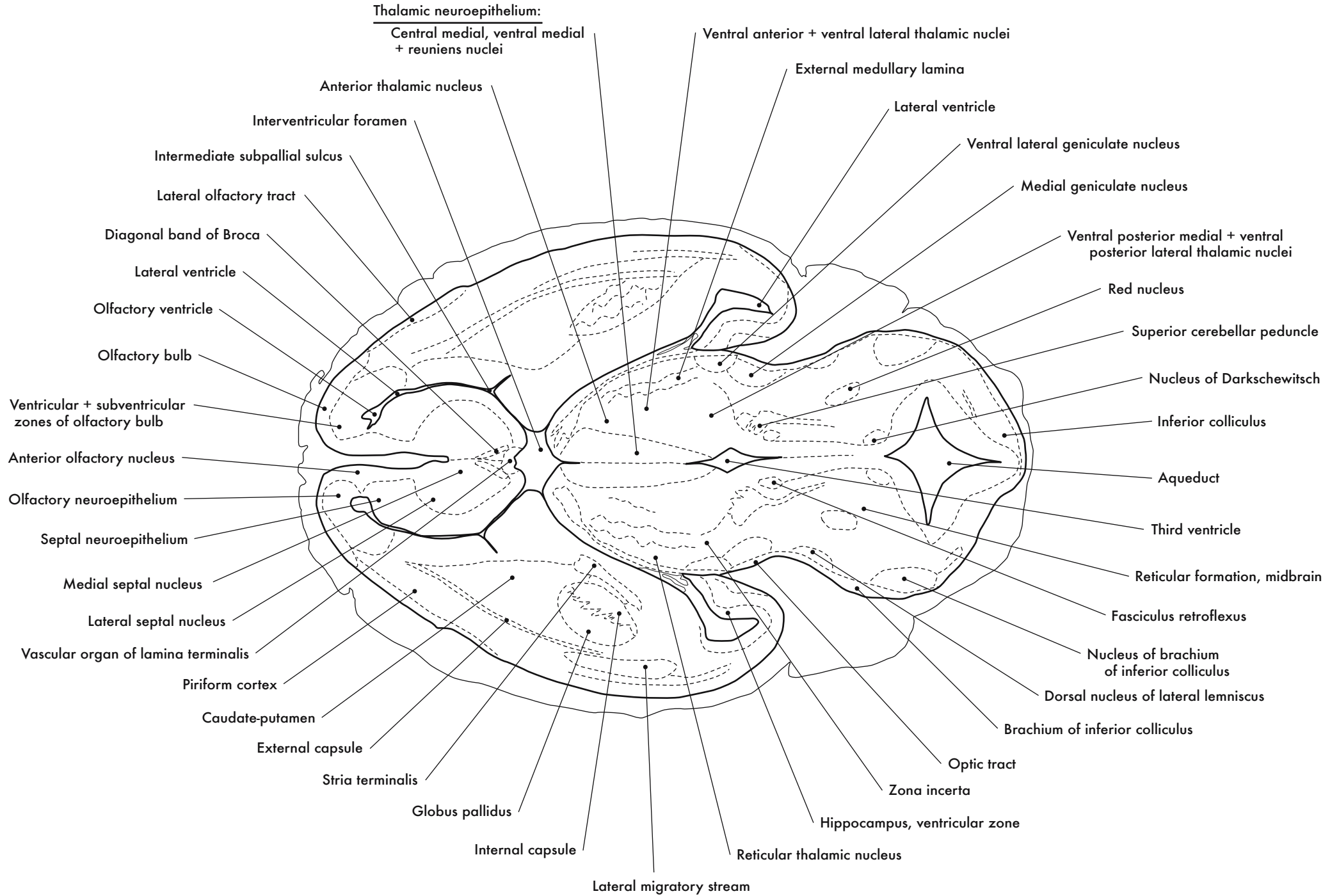
GD 14 HORIZONTAL 6

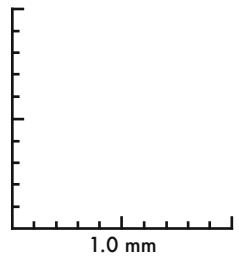
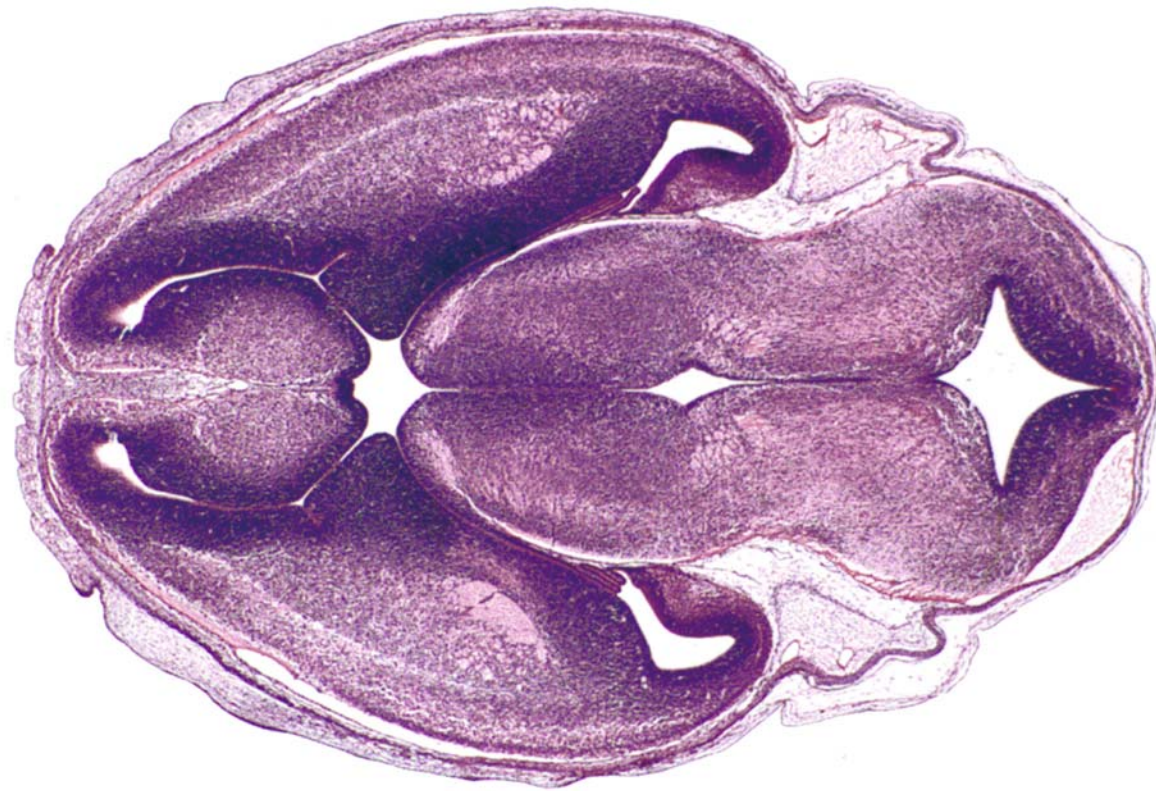




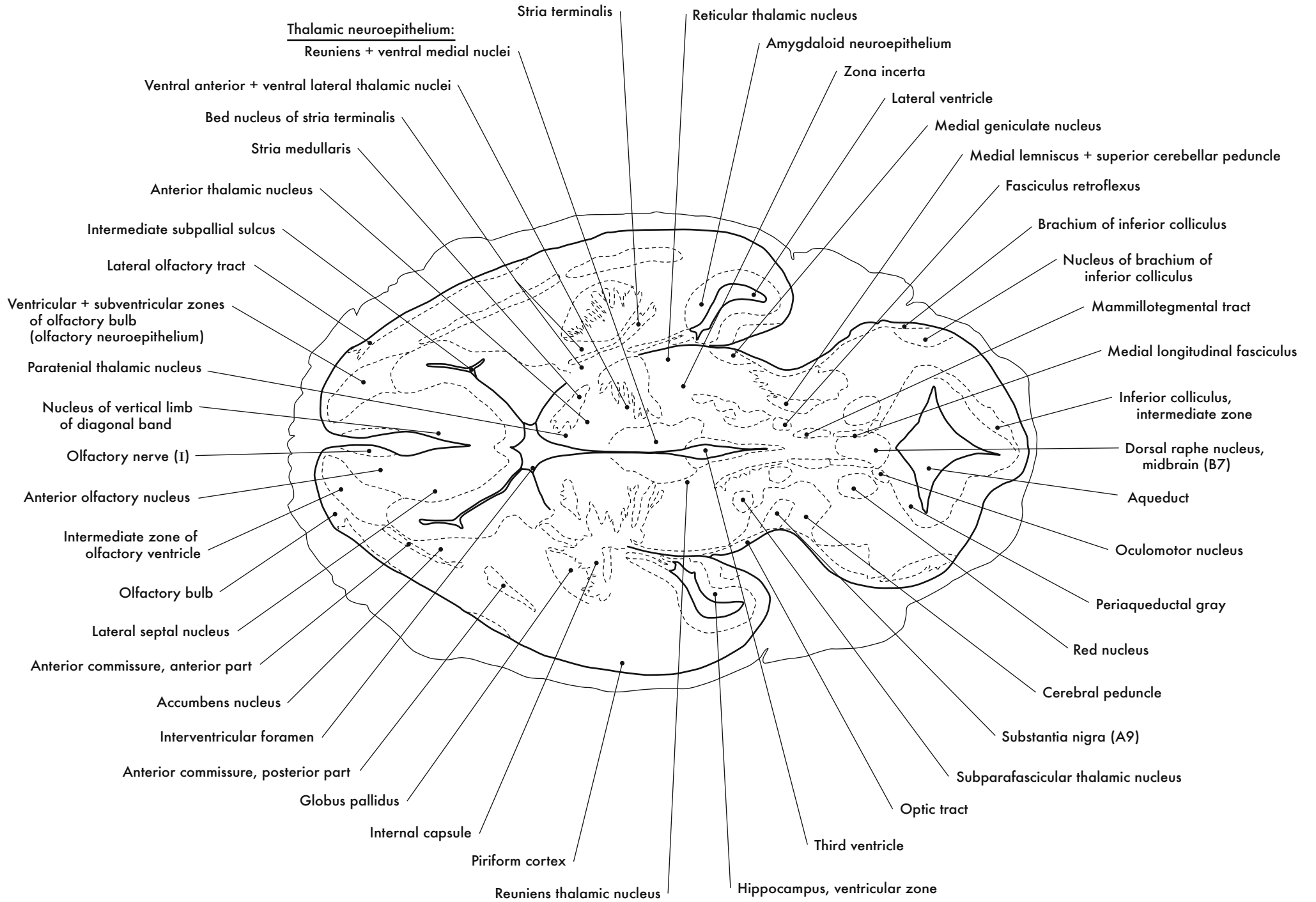


GD 14 HORIZONTAL 7

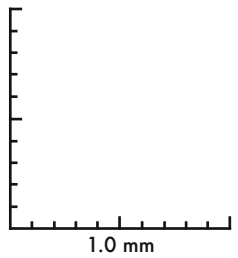
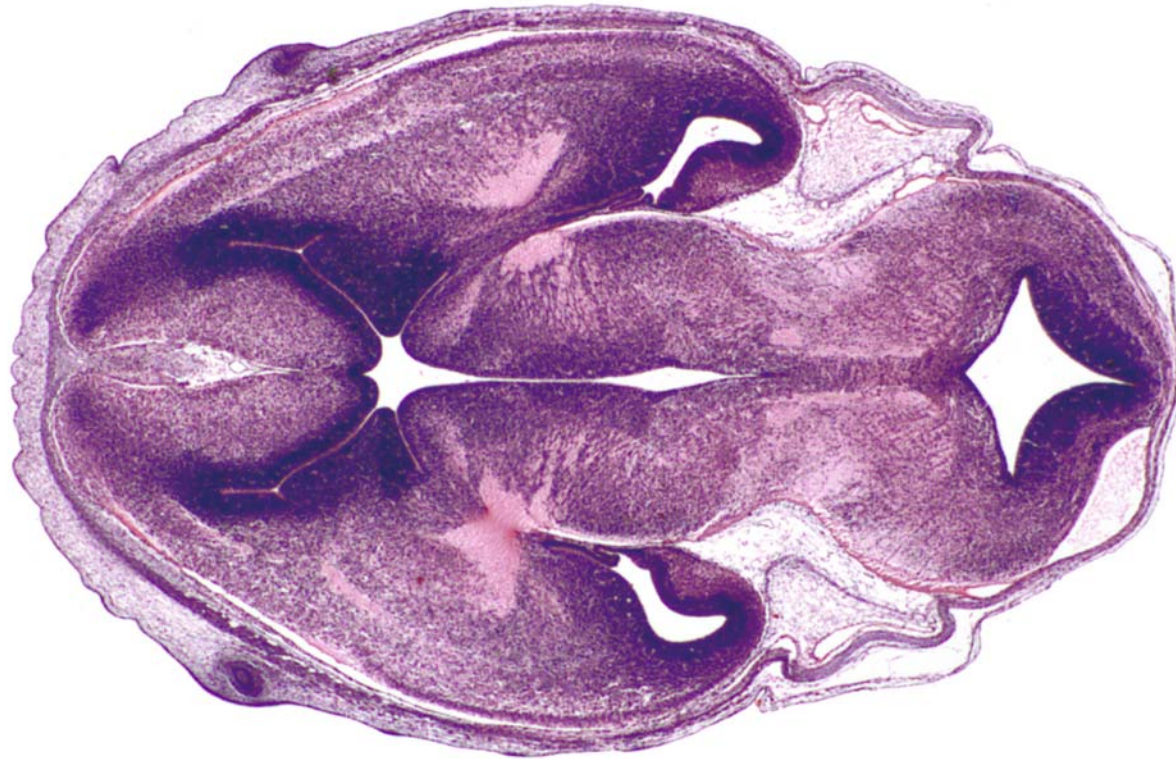



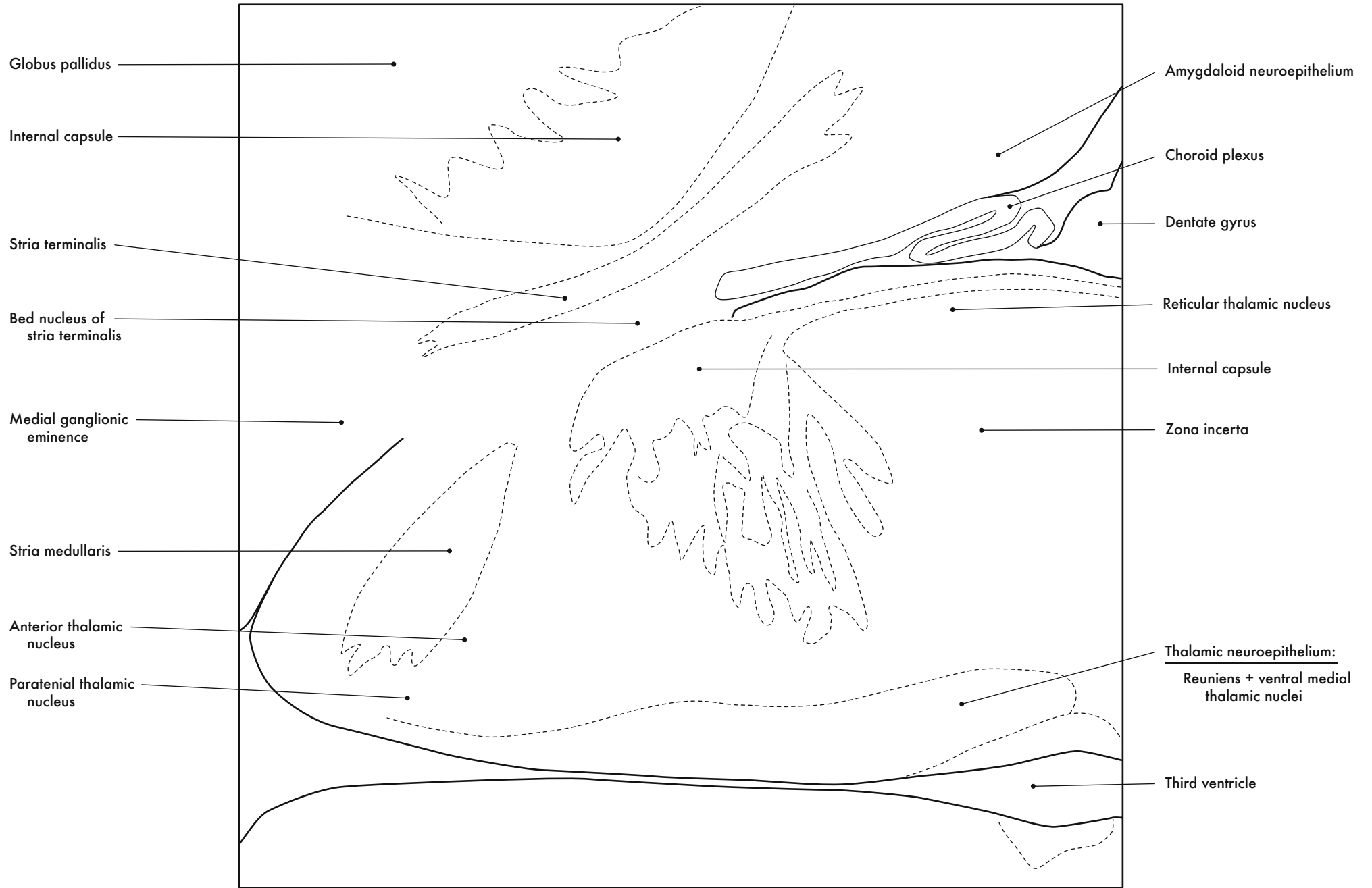
GD 14 HORIZONTAL 8





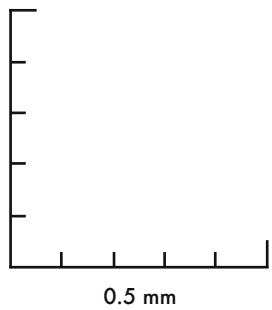
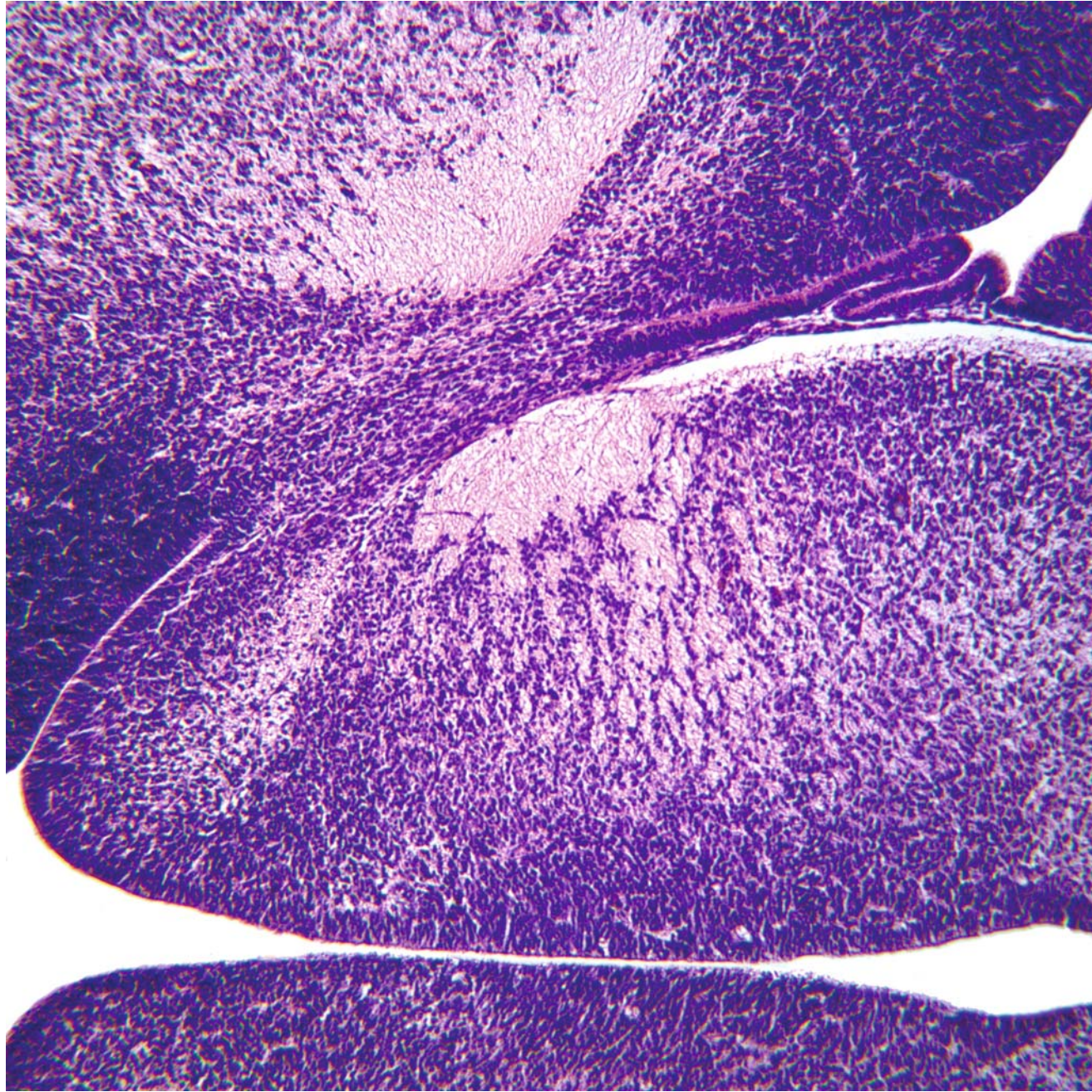
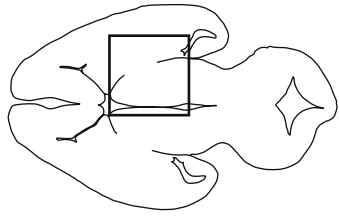


GD 14 HORIZONTAL 9

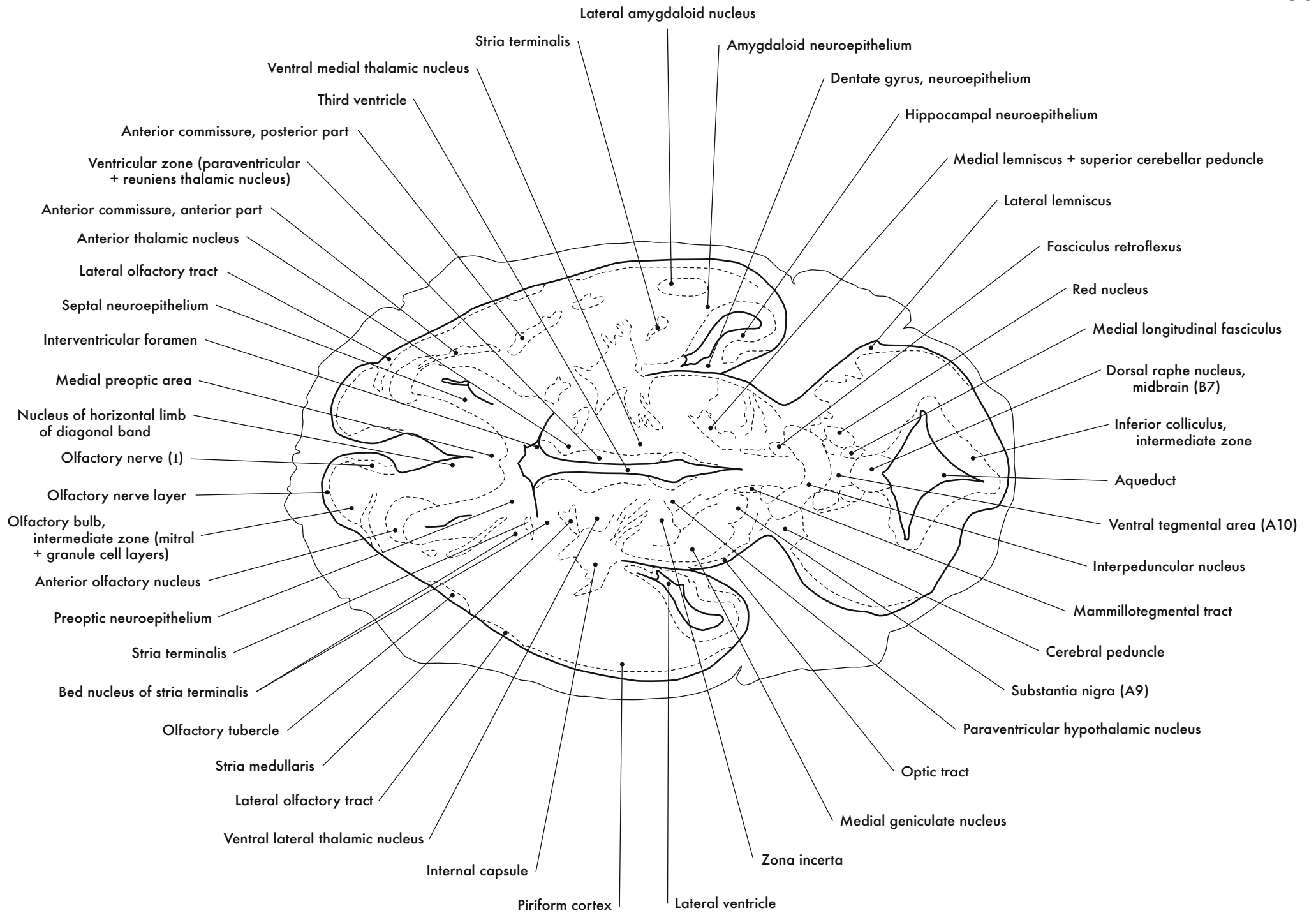


Internal Capsule, Stria Medullaris and Stria Terminalis

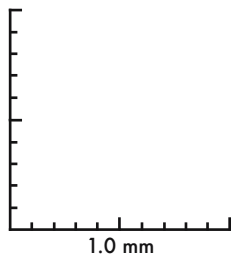
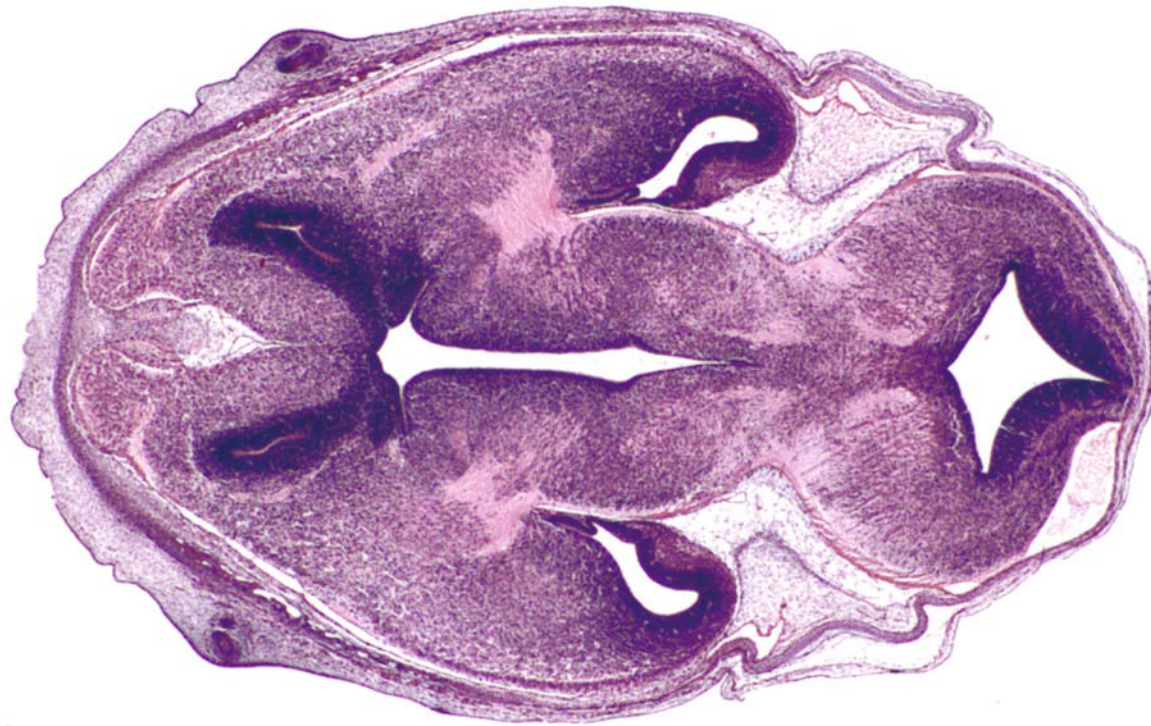
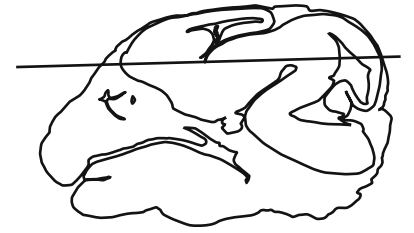


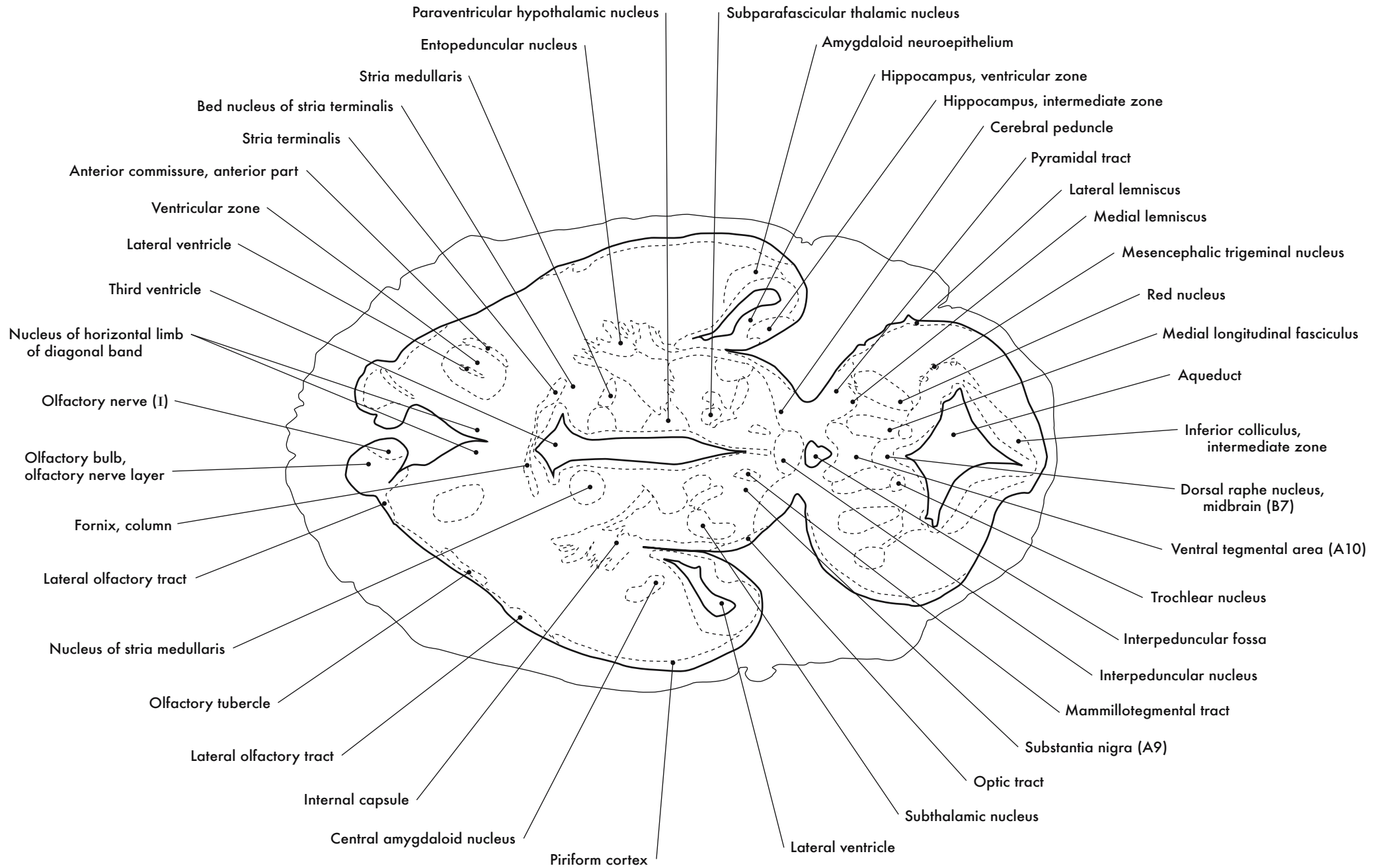
GD 14 HORIZONTAL 10

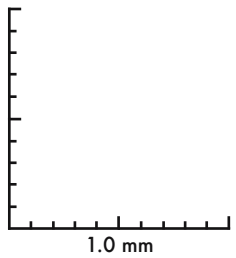
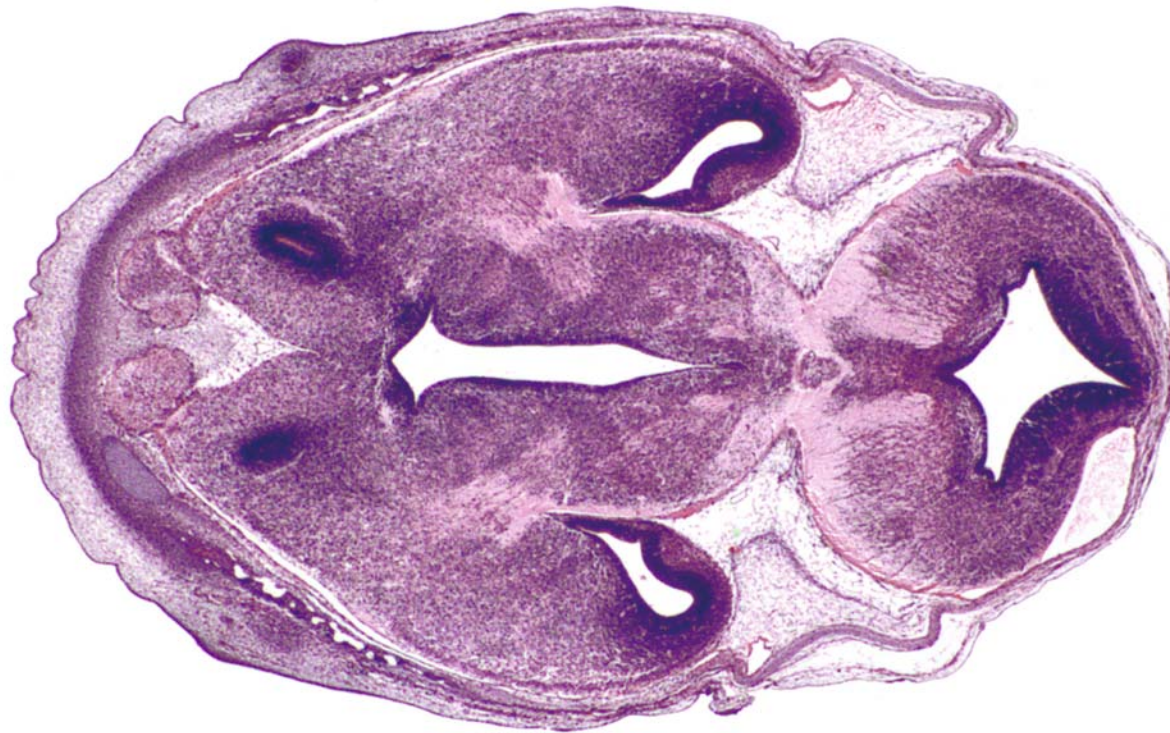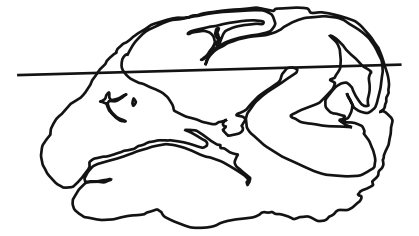




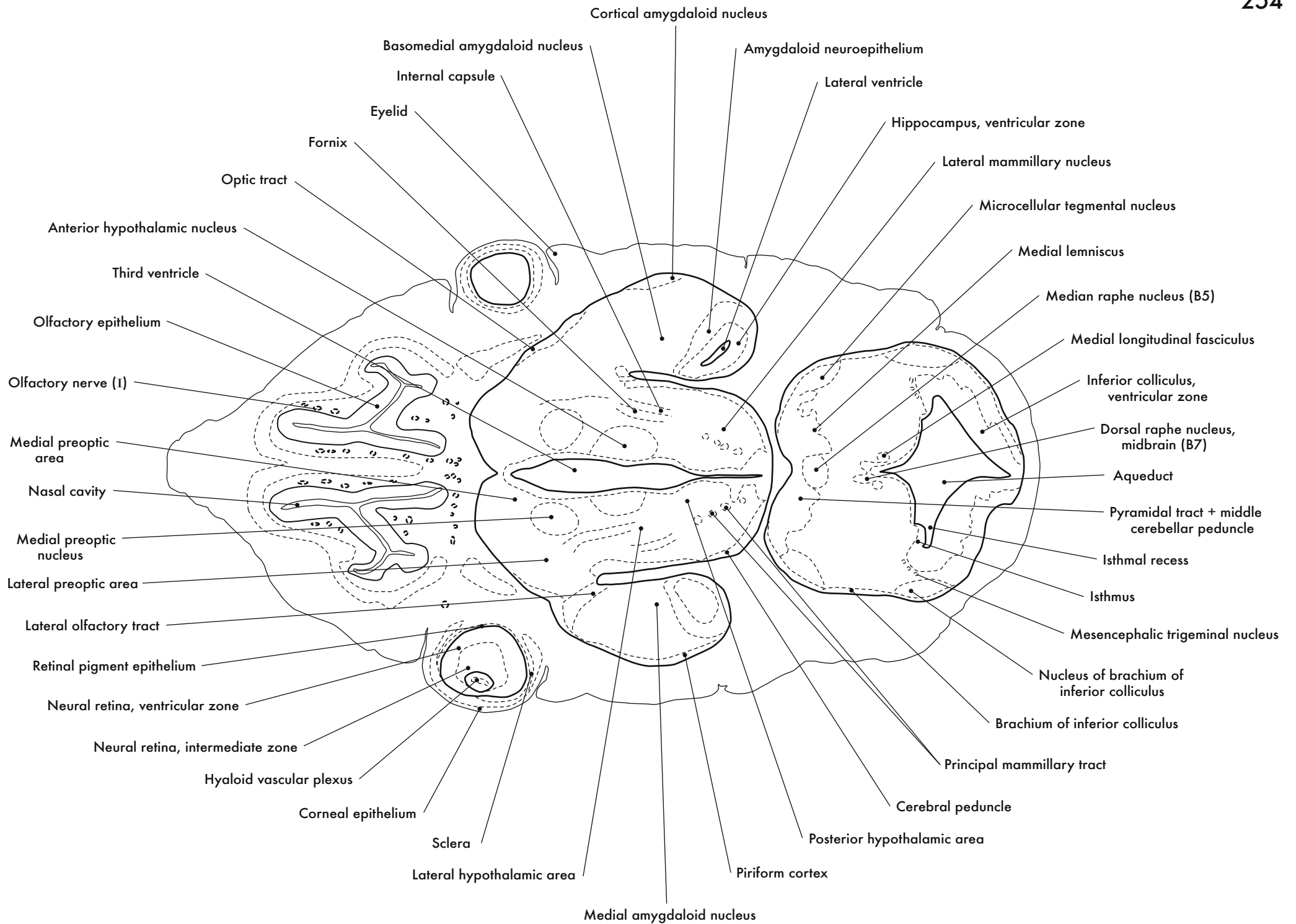


GD 14 HORIZONTAL 11

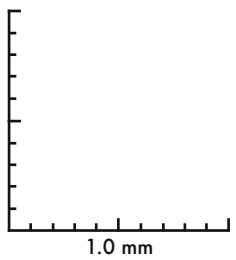
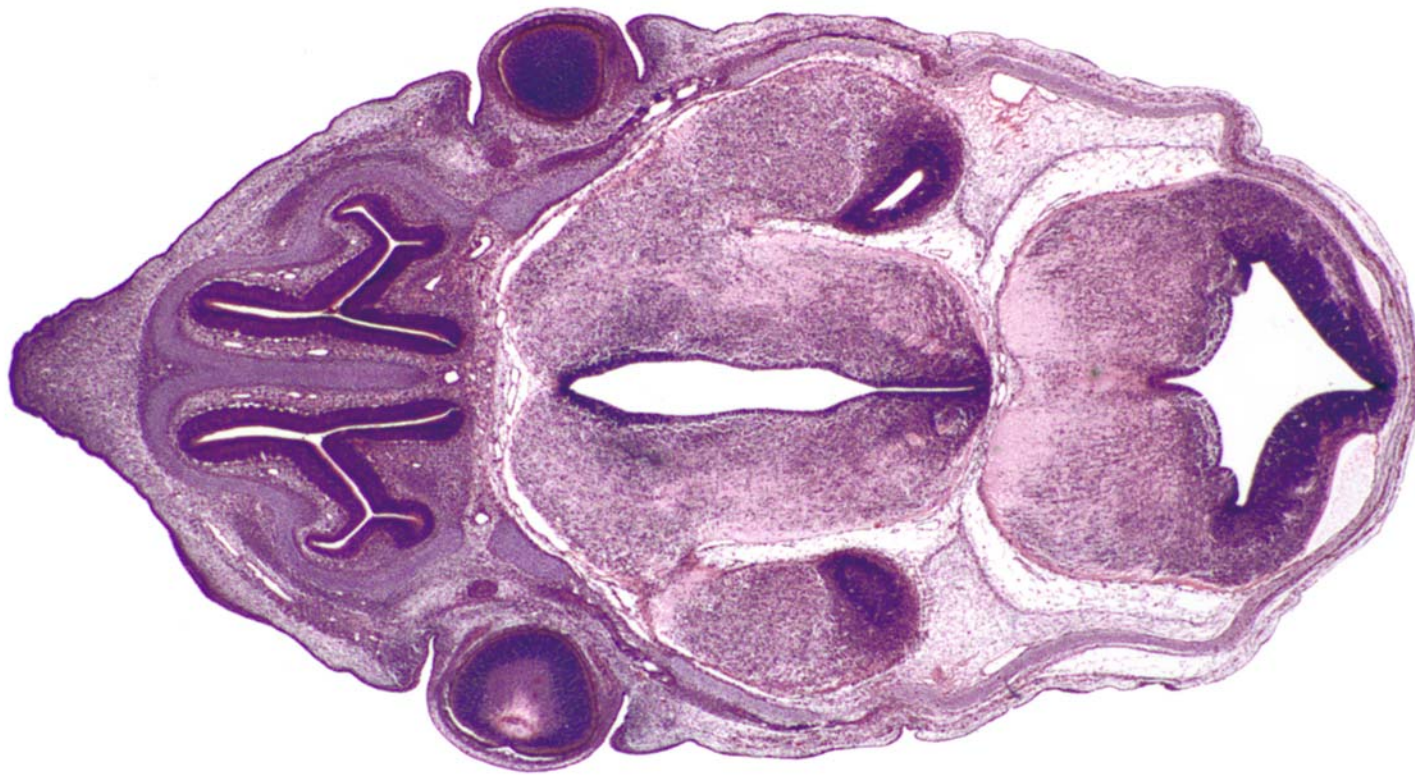





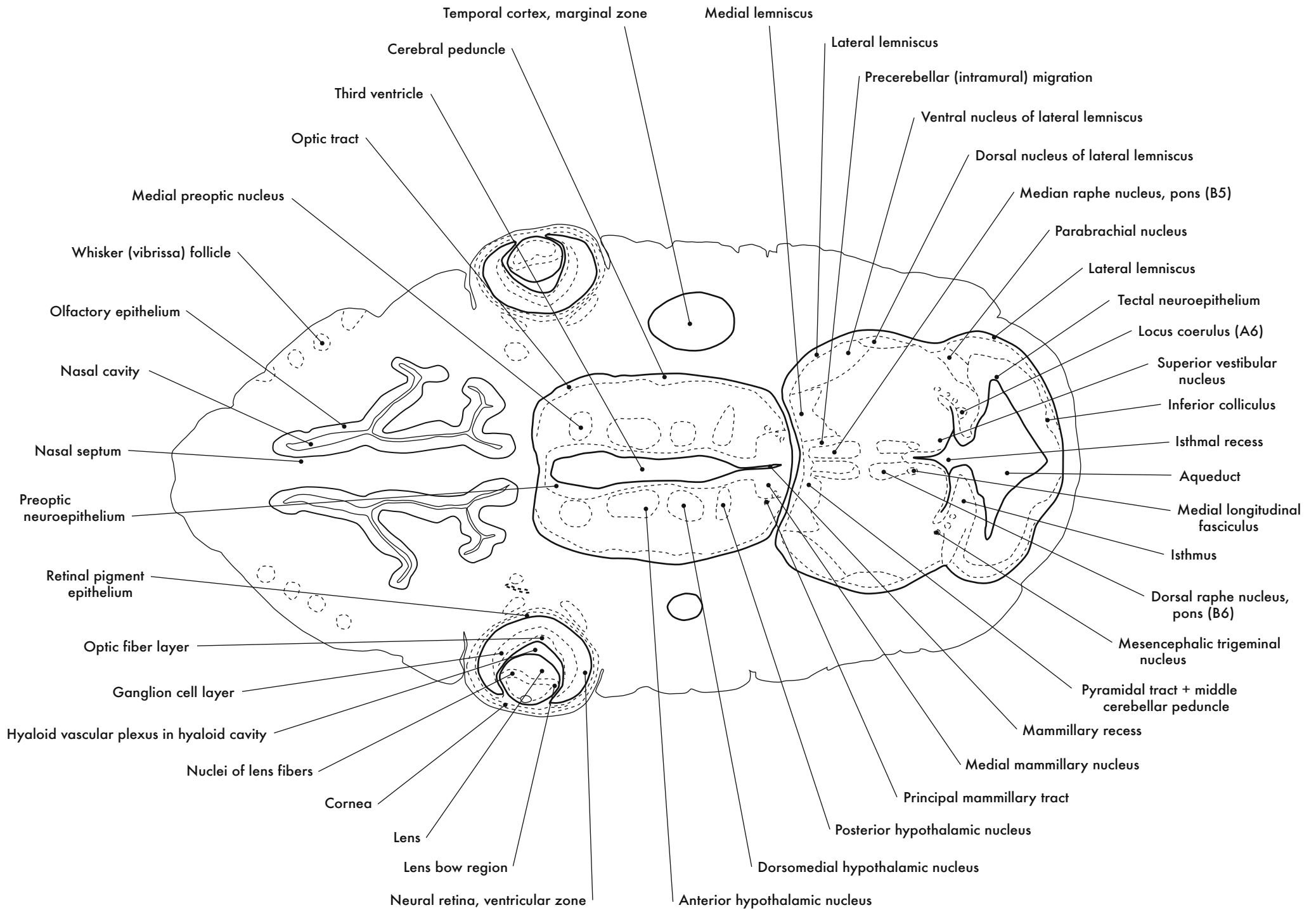
GD 14 HORIZONTAL 12

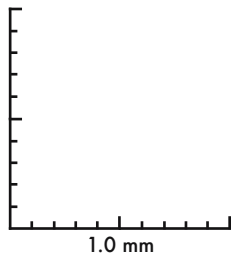
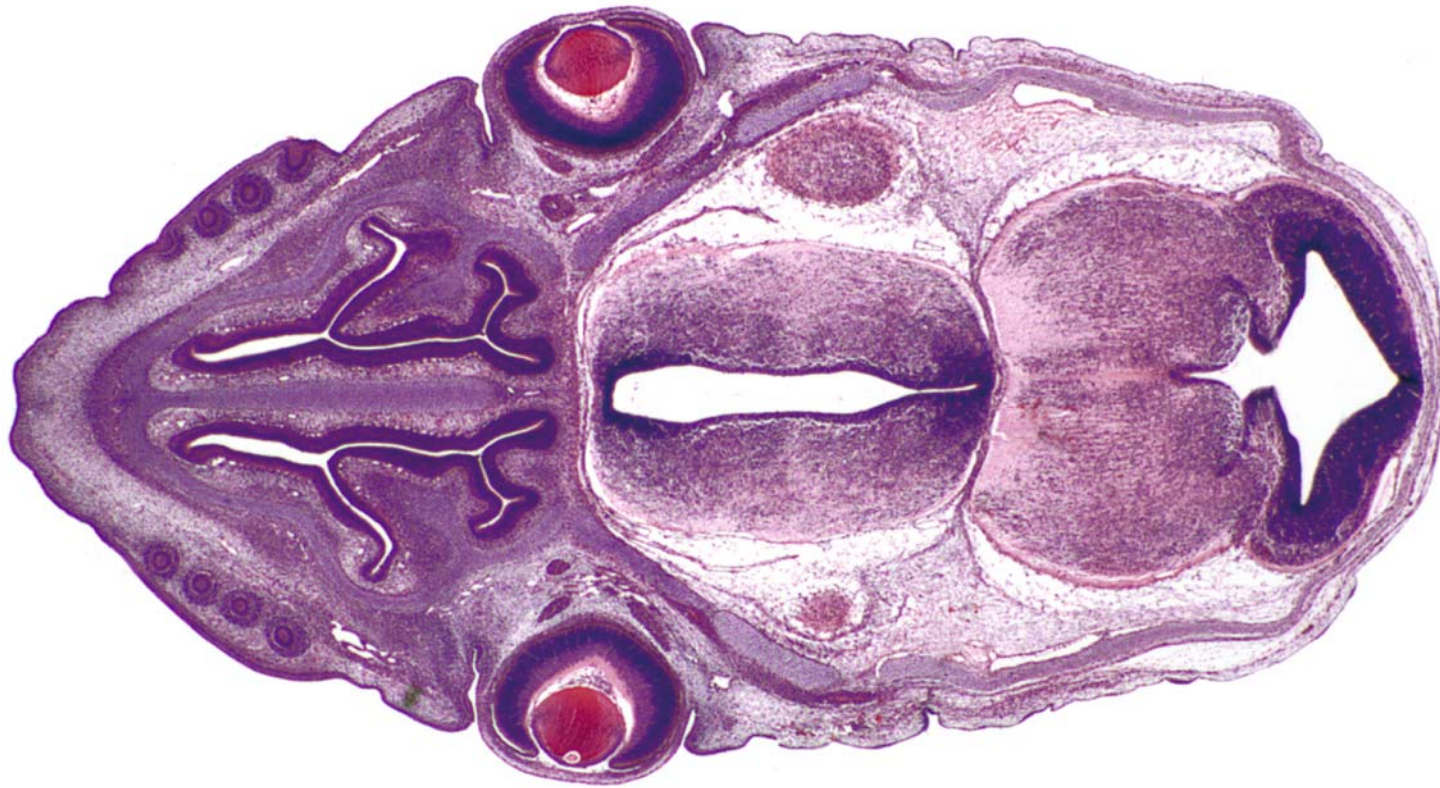






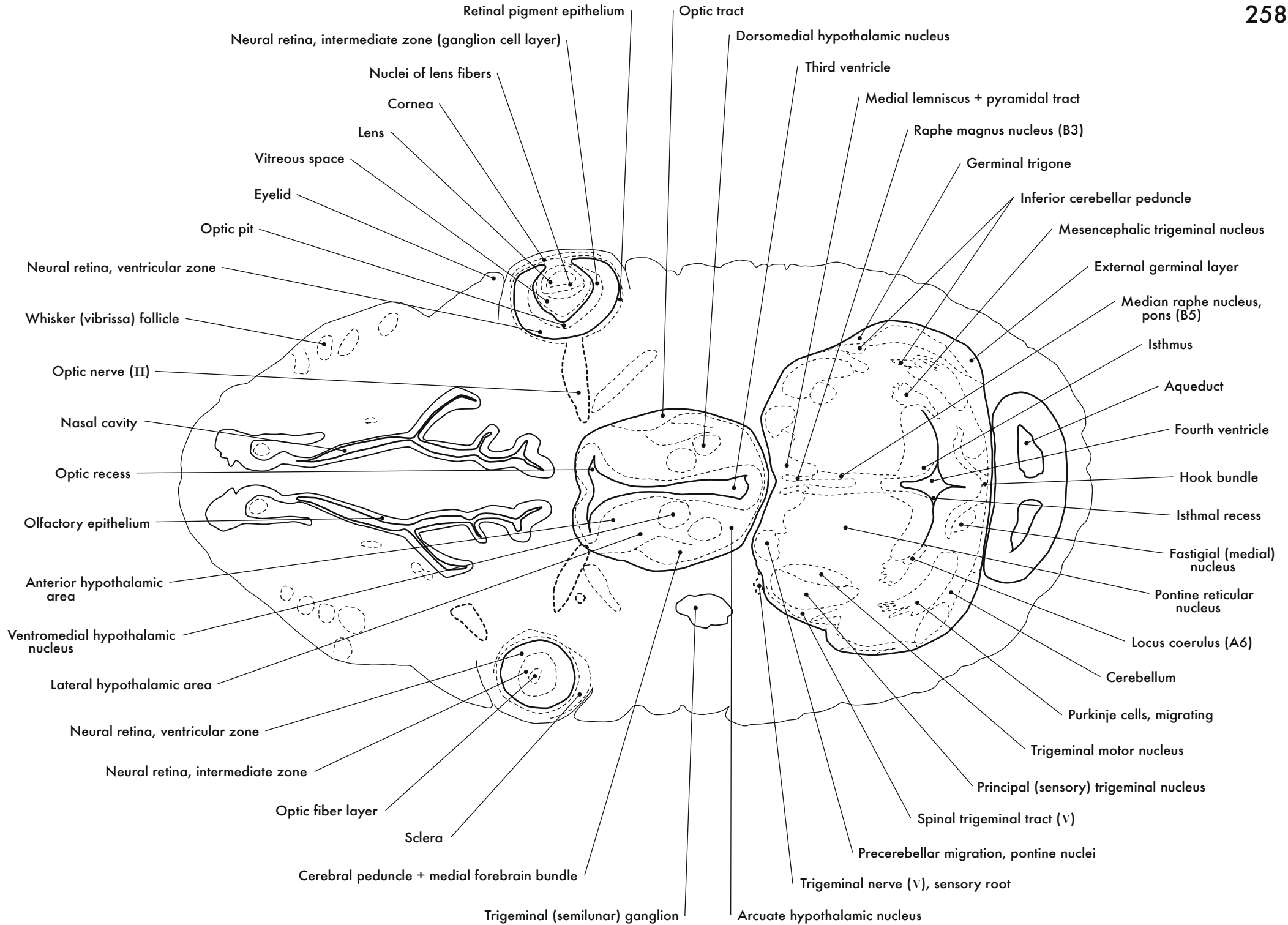
GD 14 HORIZONTAL 13



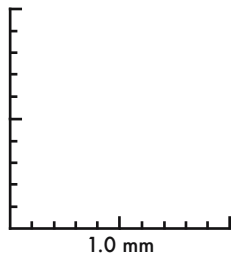
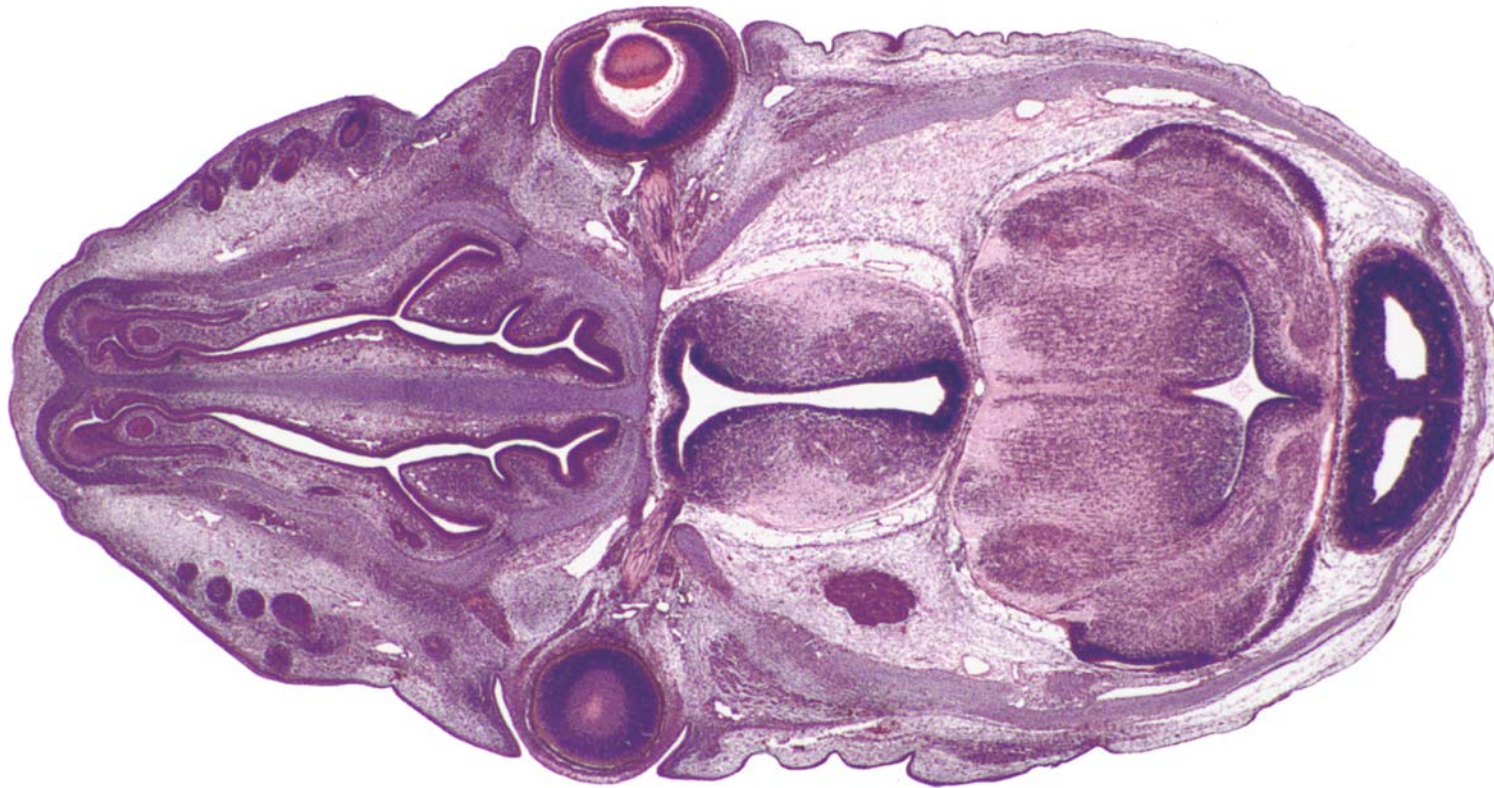



GD 14 HORIZONTAL 14

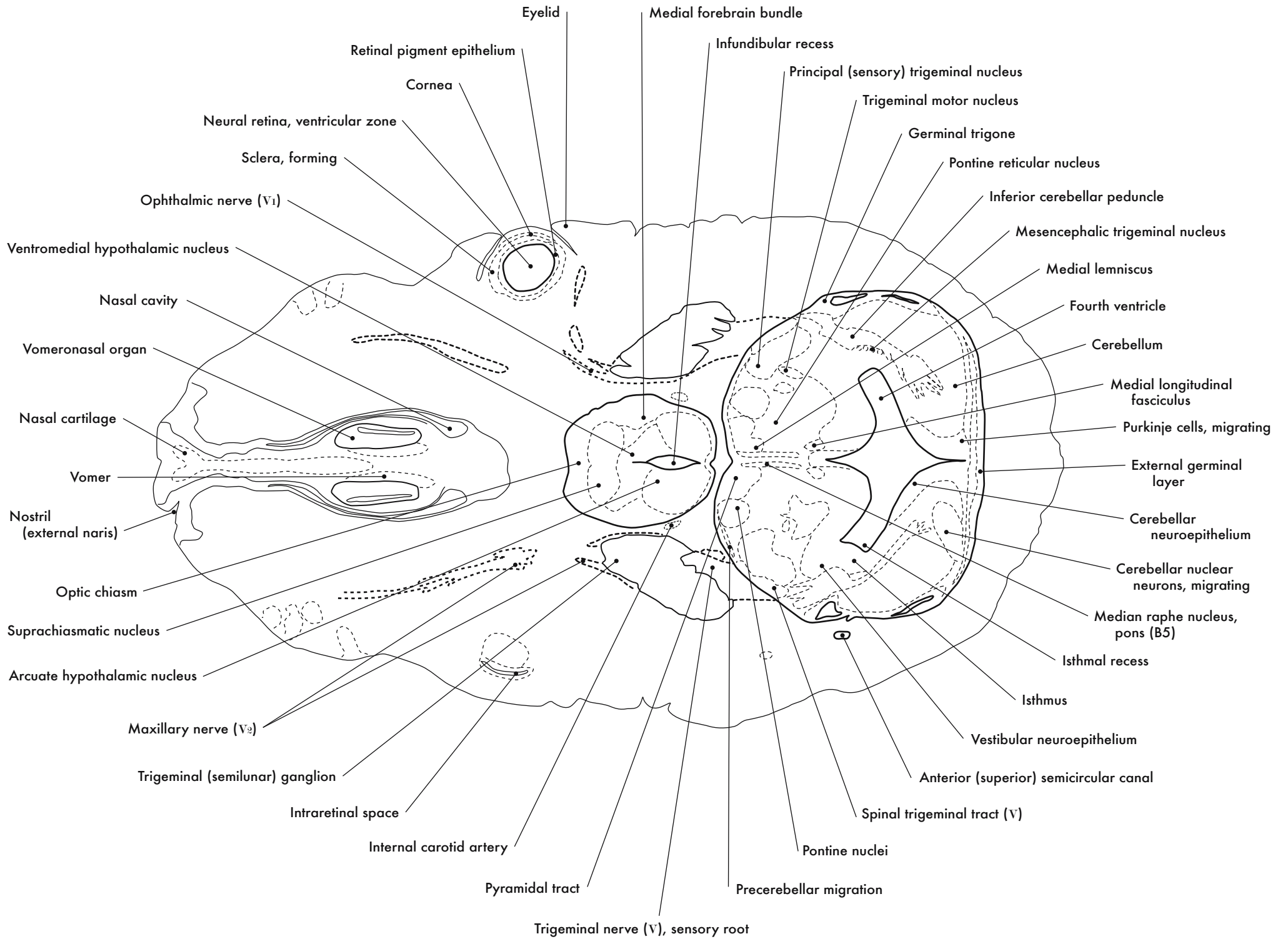


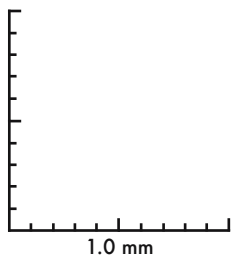
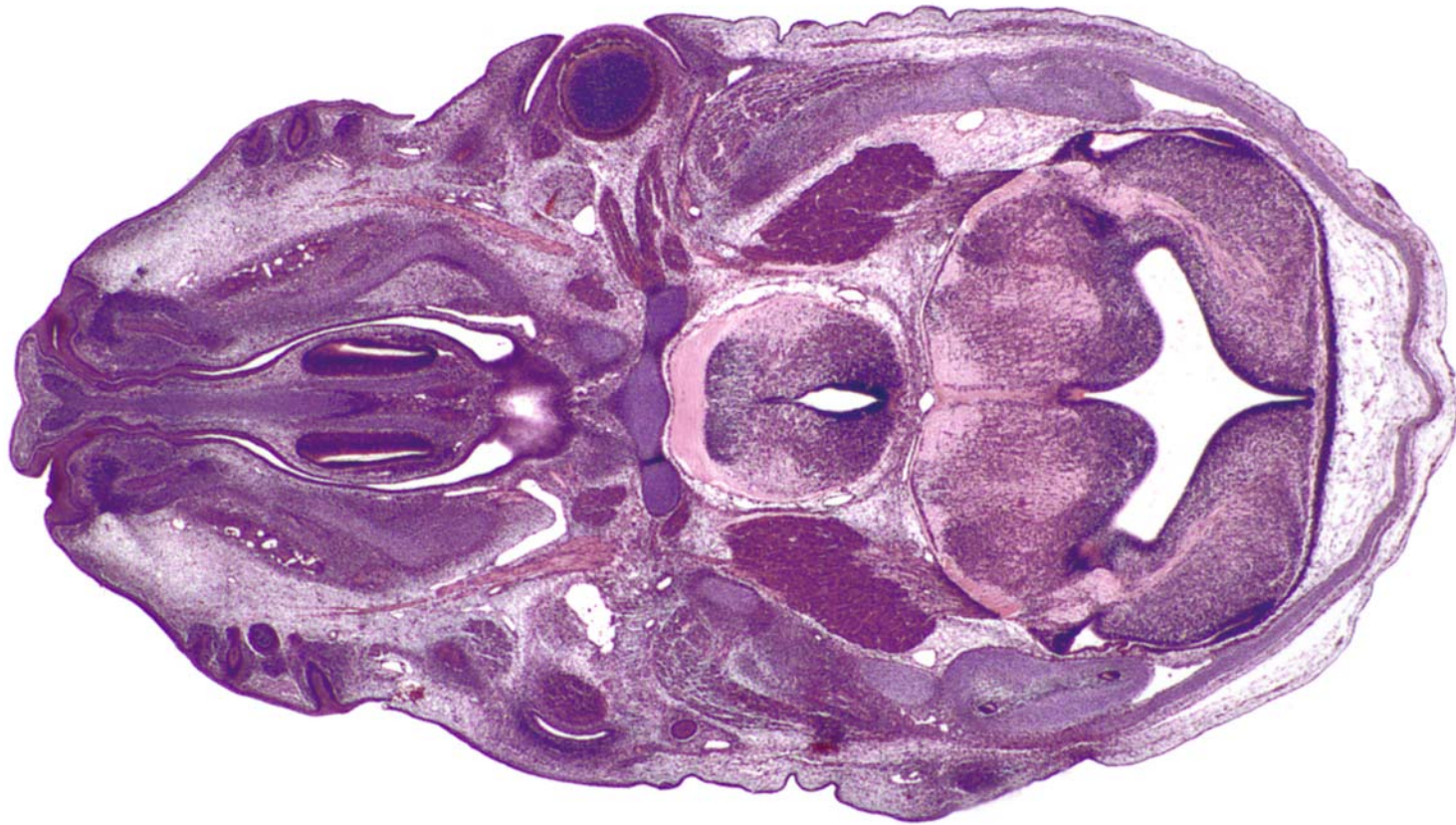






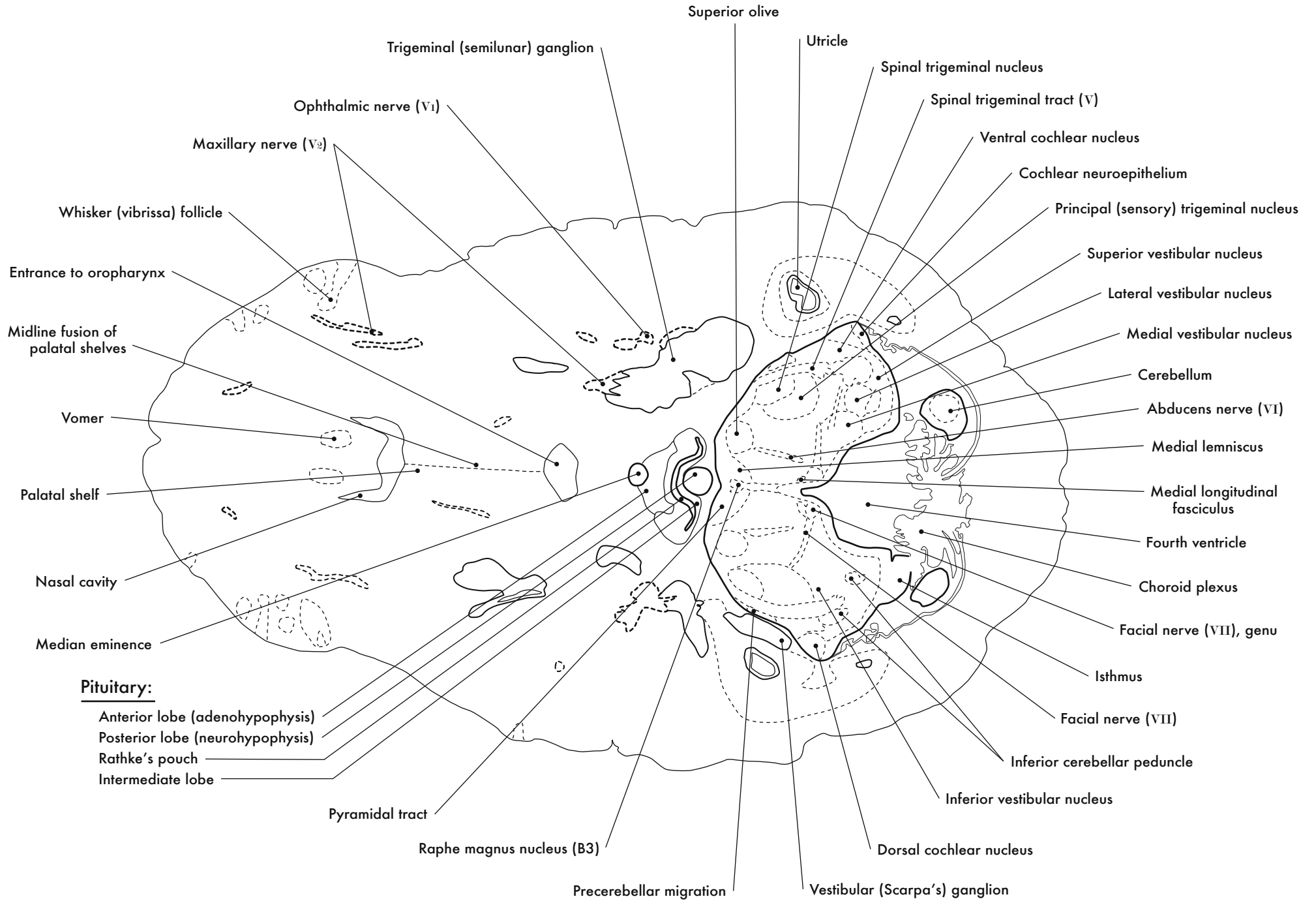
GD 14 HORIZONTAL 15



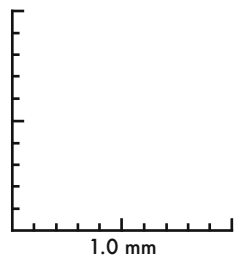
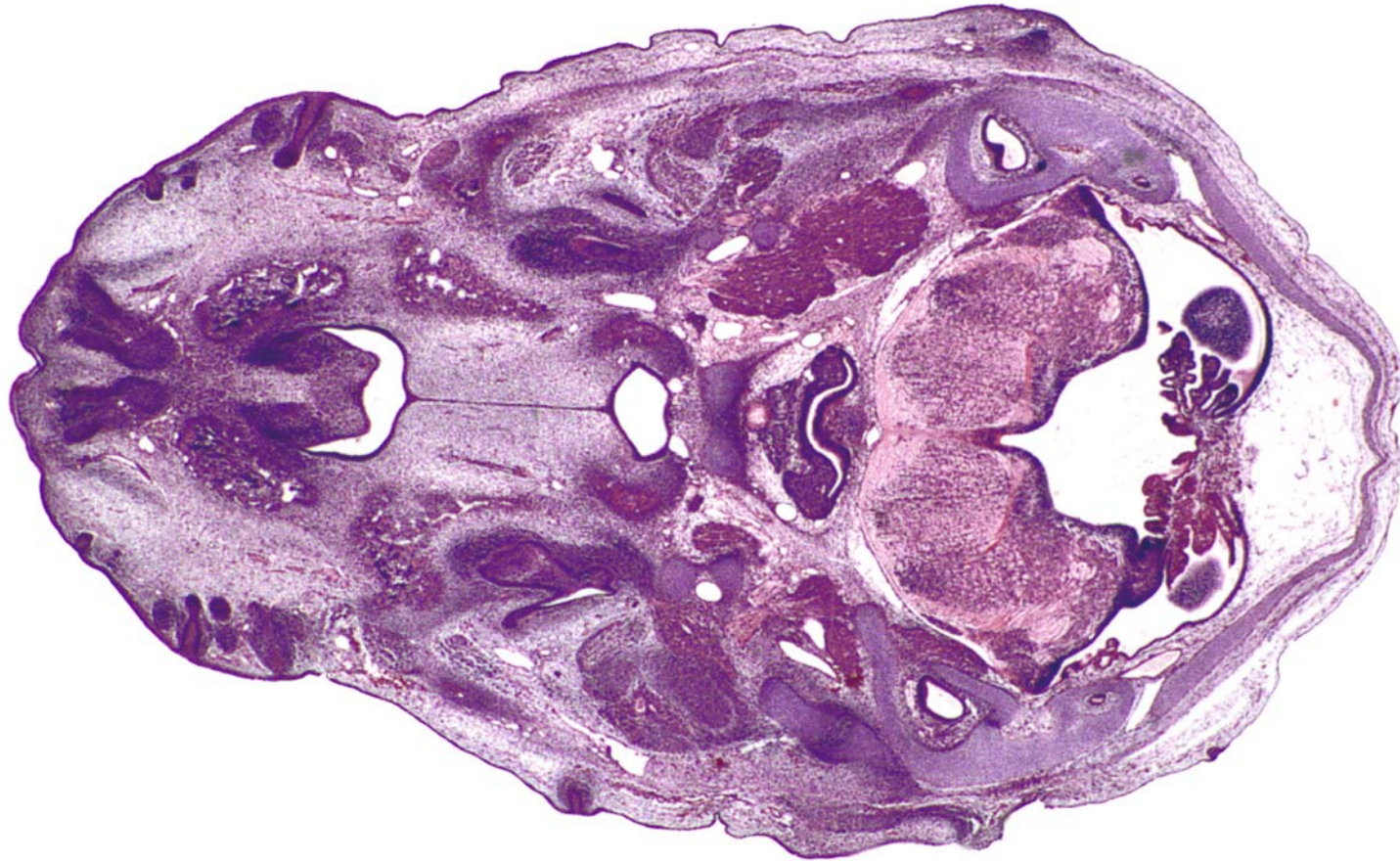
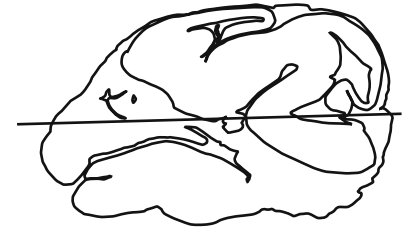


GD 14 HORIZONTAL 16

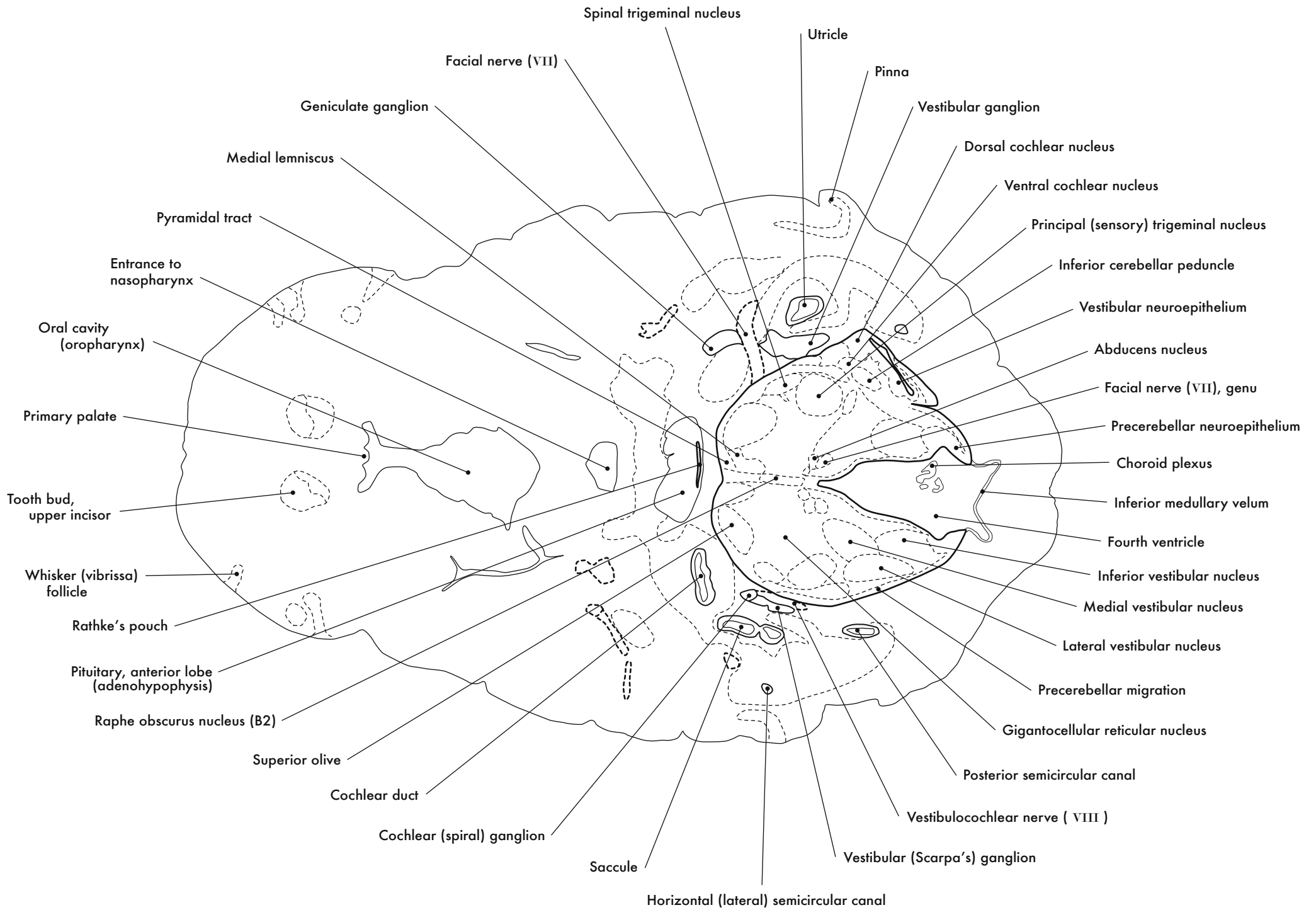




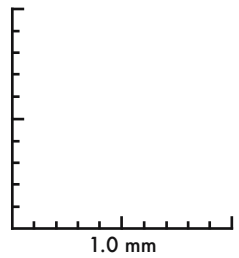
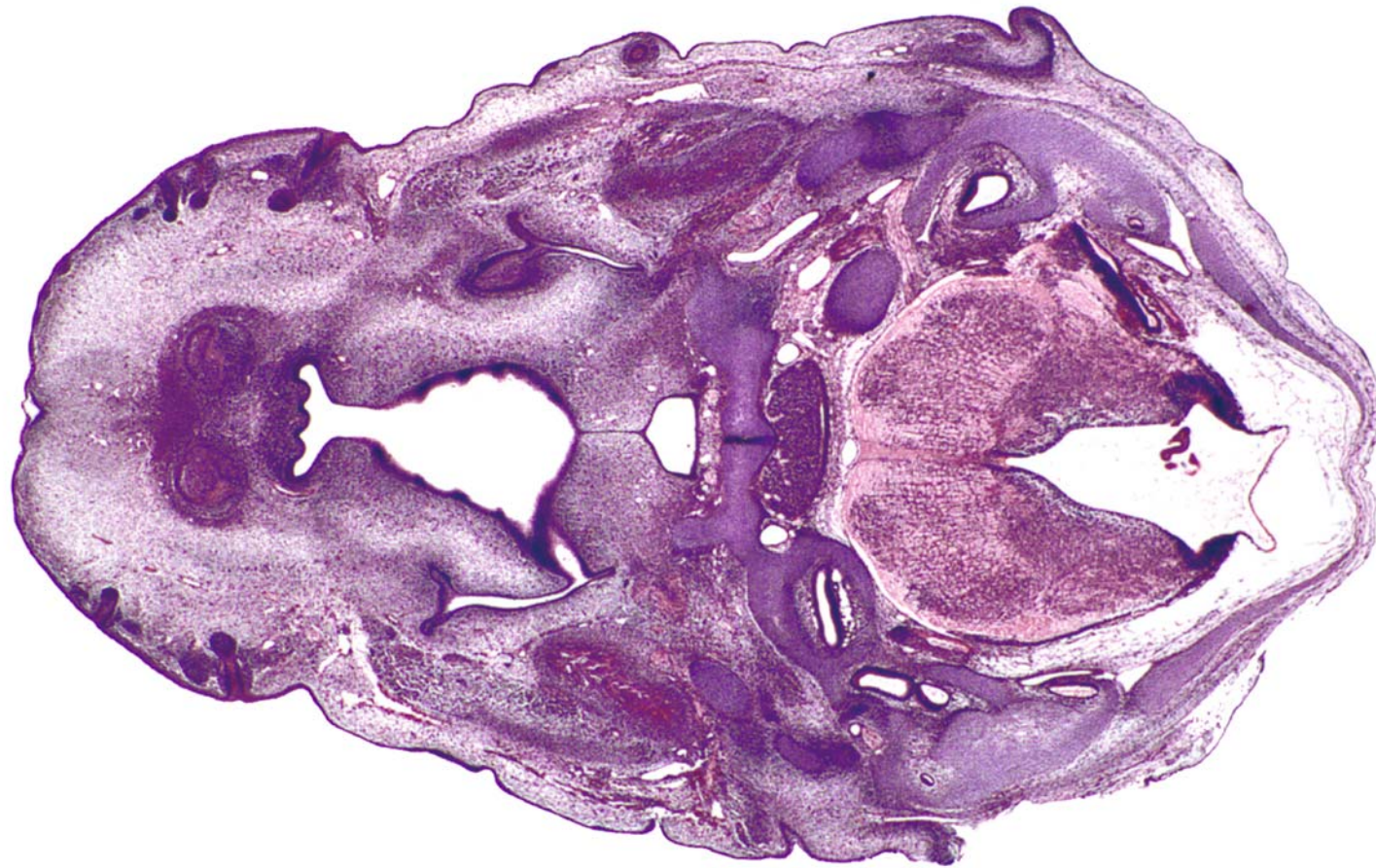
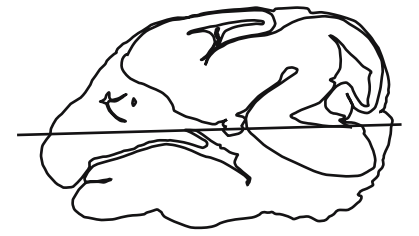




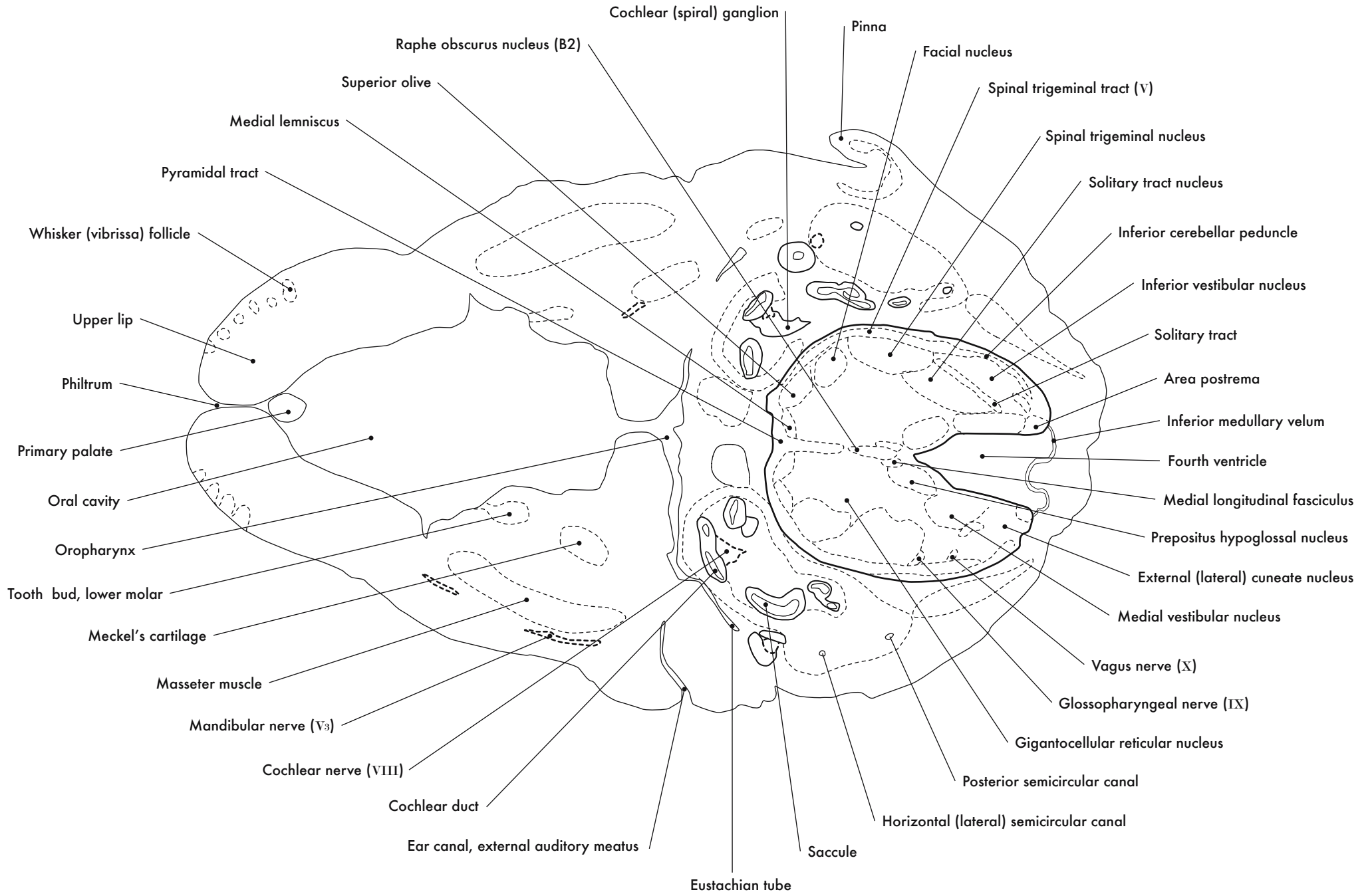
GD 14 HORIZONTAL 17



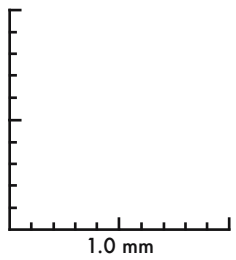
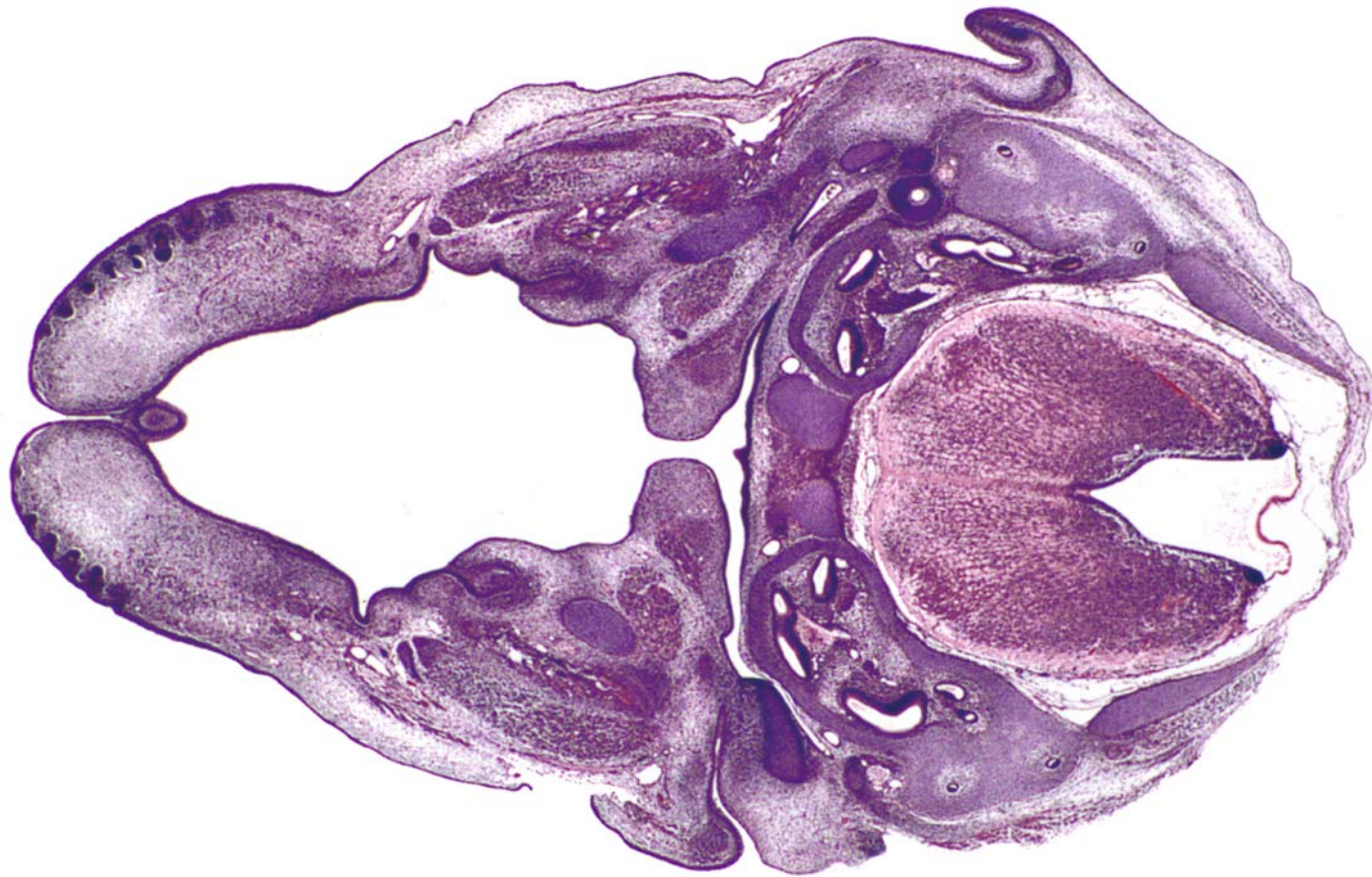
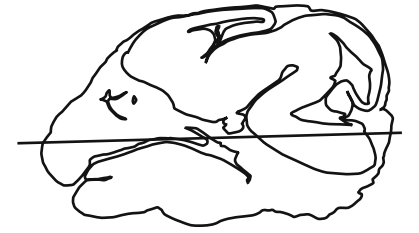


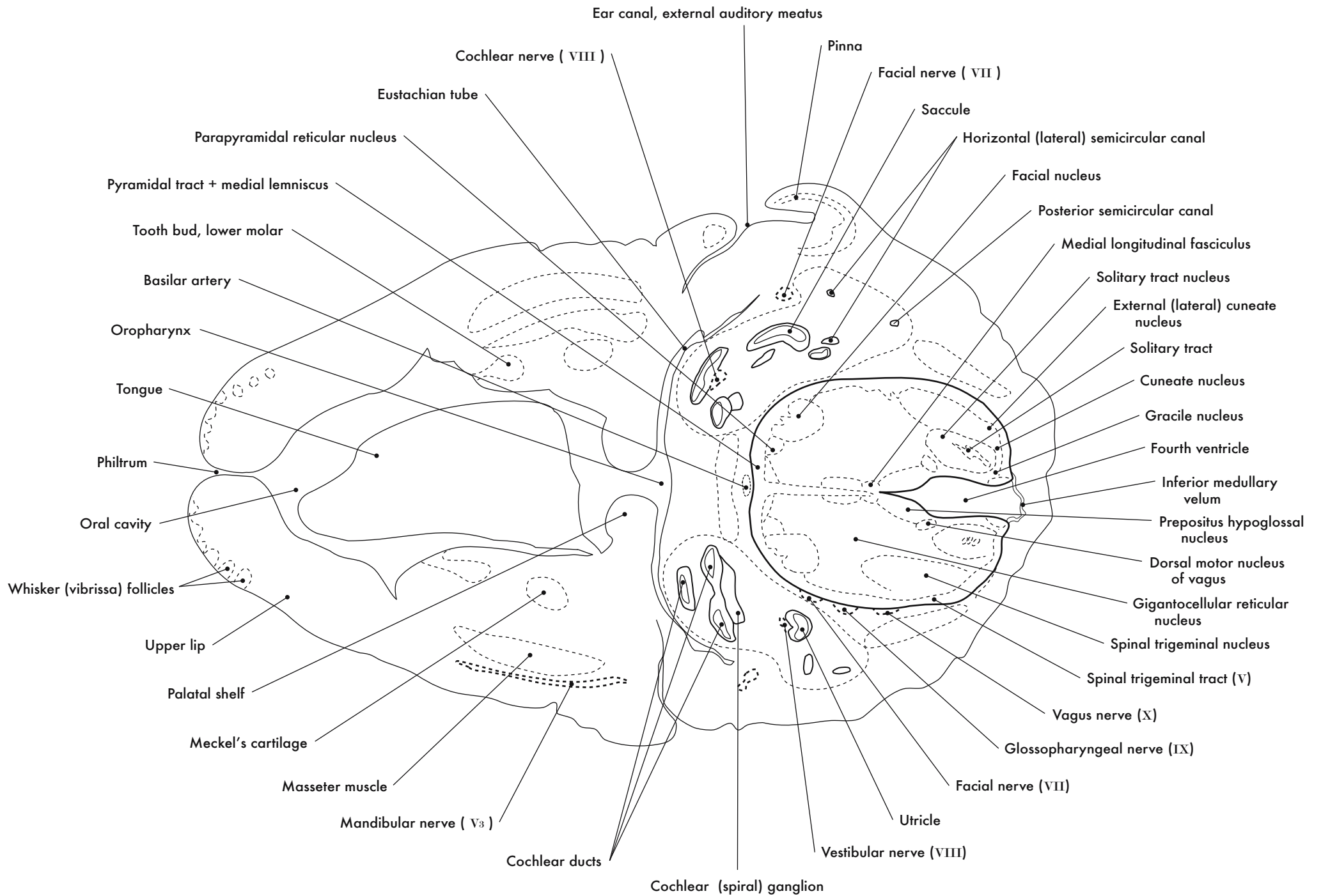
GD 14 HORIZONTAL 18

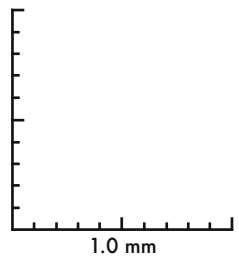
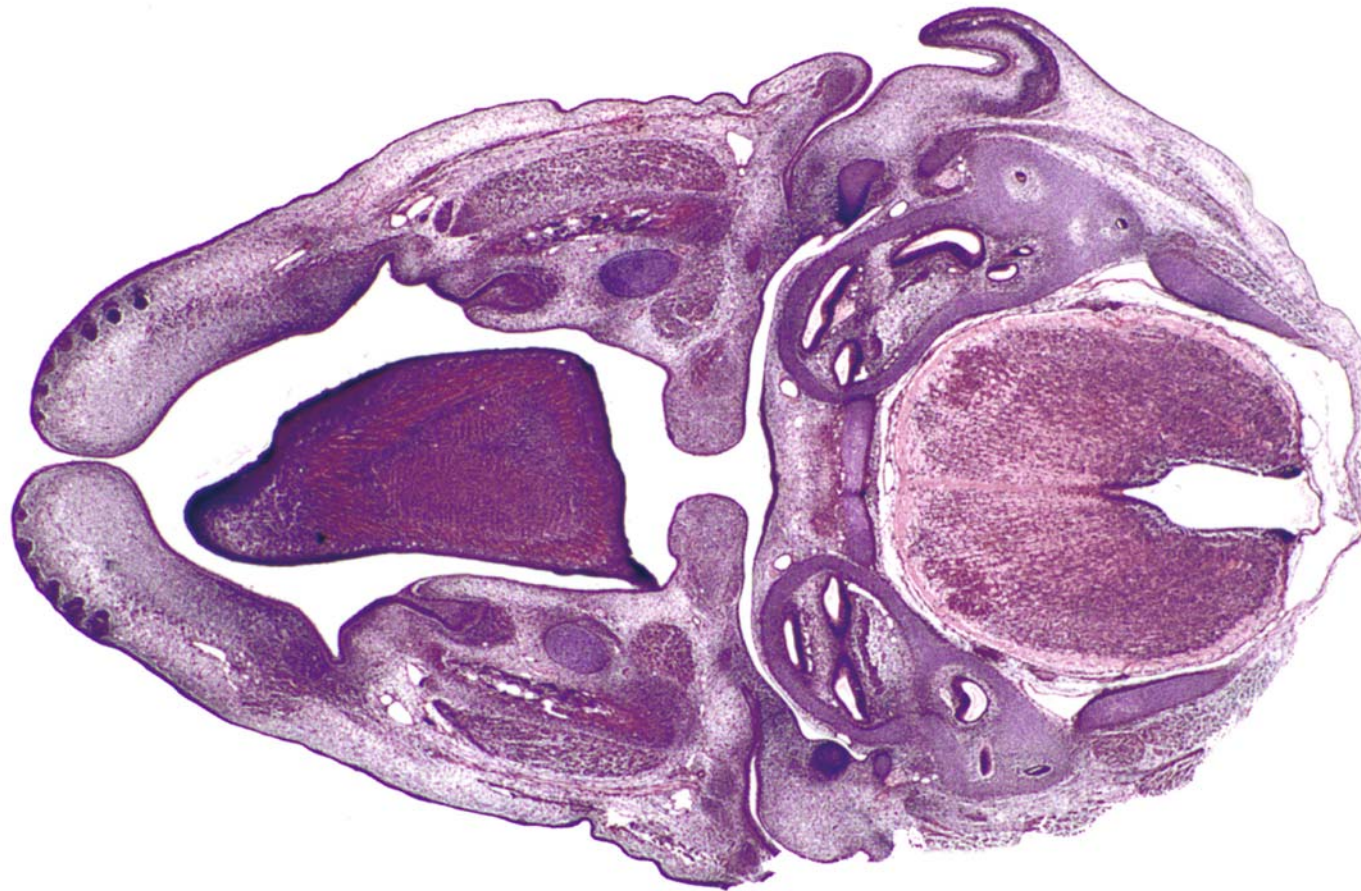
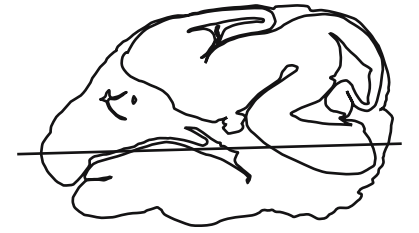




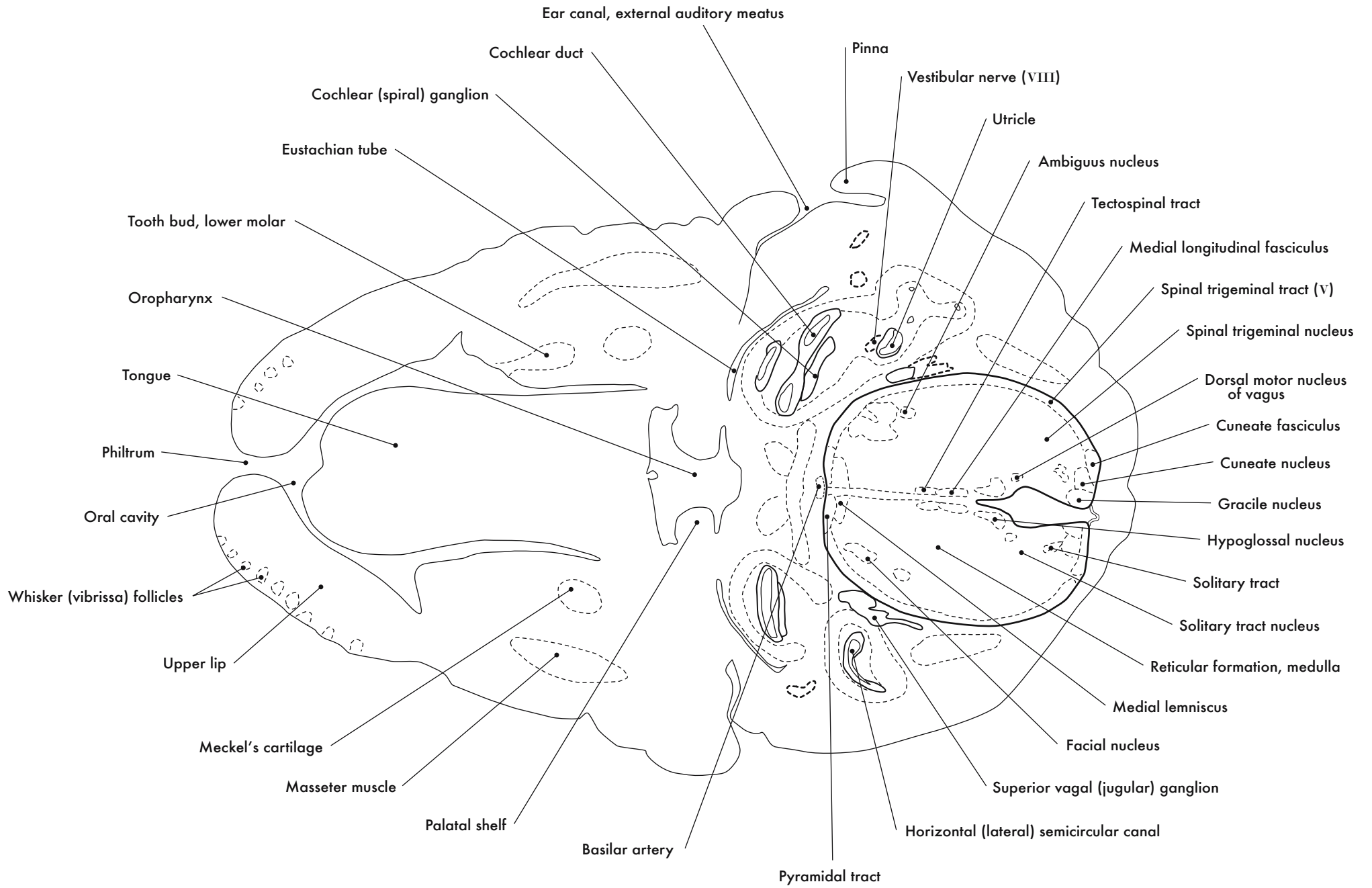
GD 14 HORIZONTAL 19



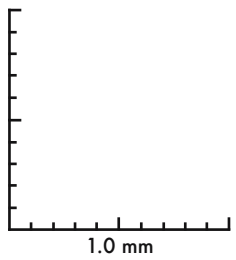
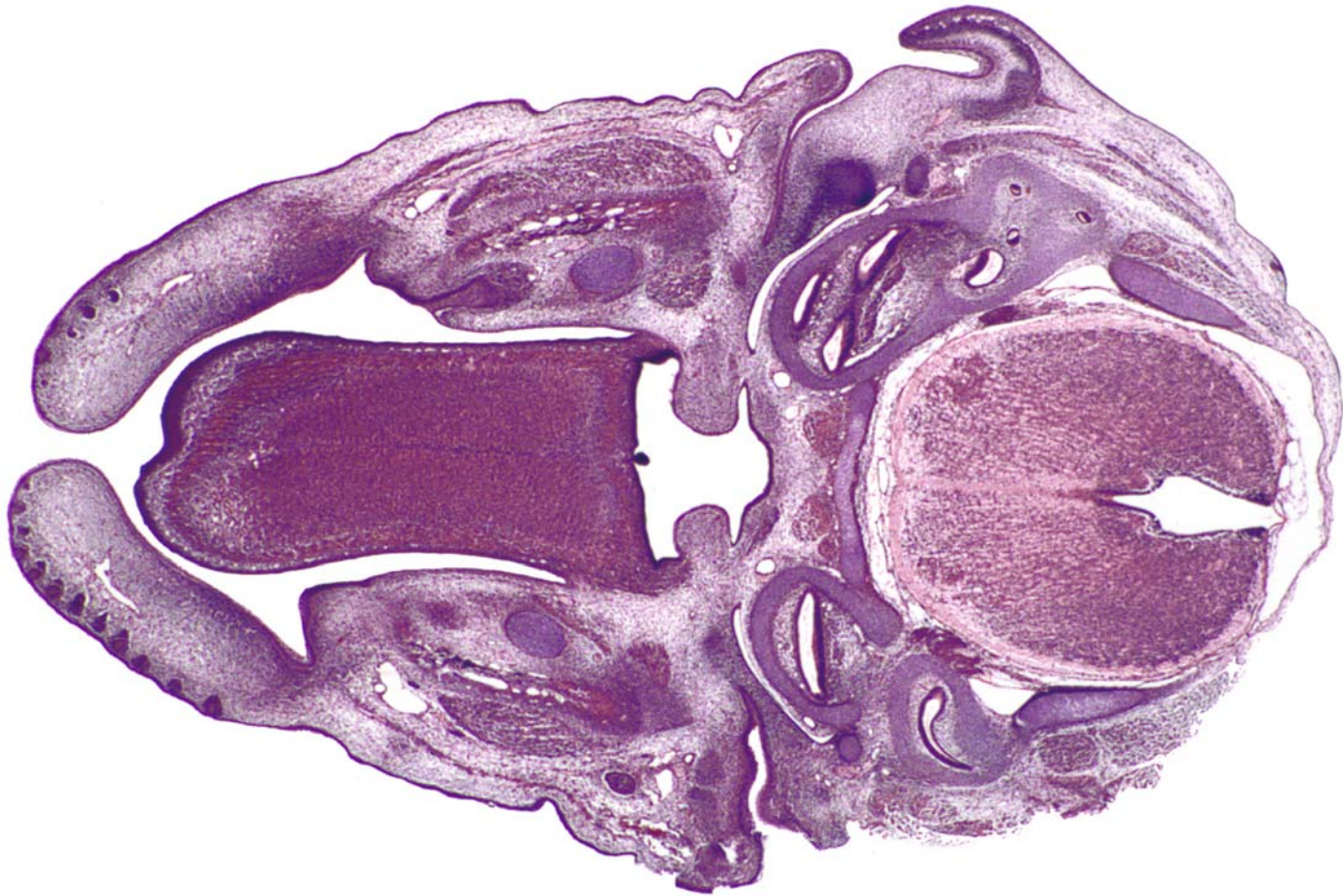
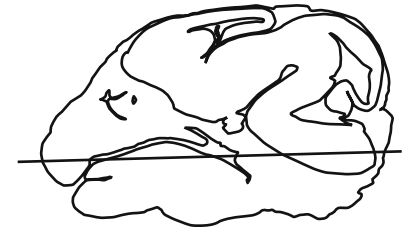
GD 14 HORIZONTAL 20

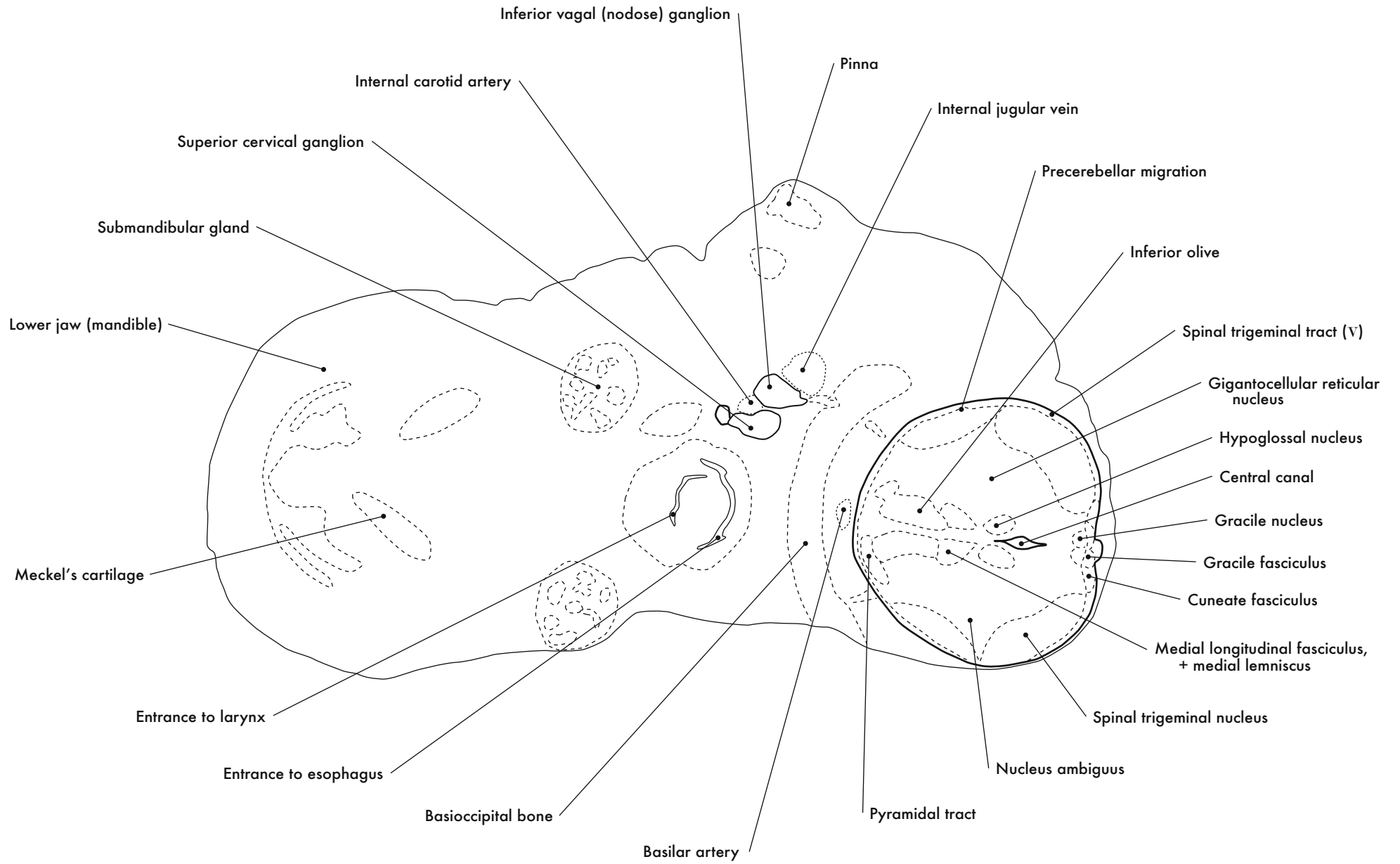


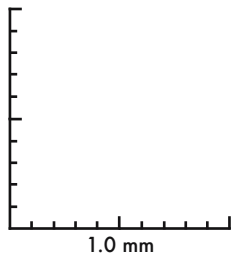
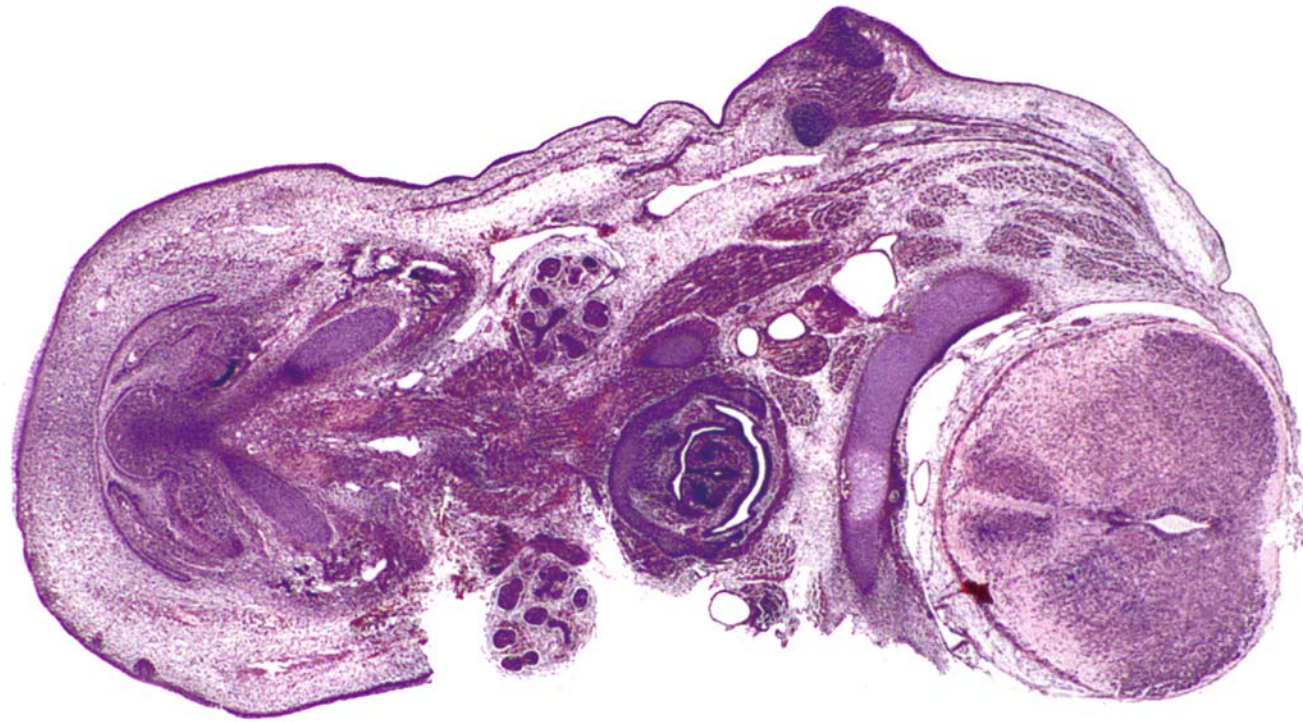
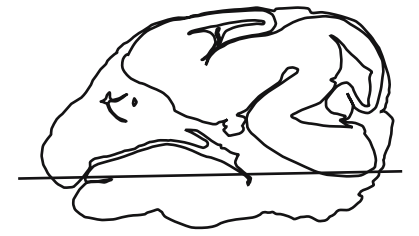




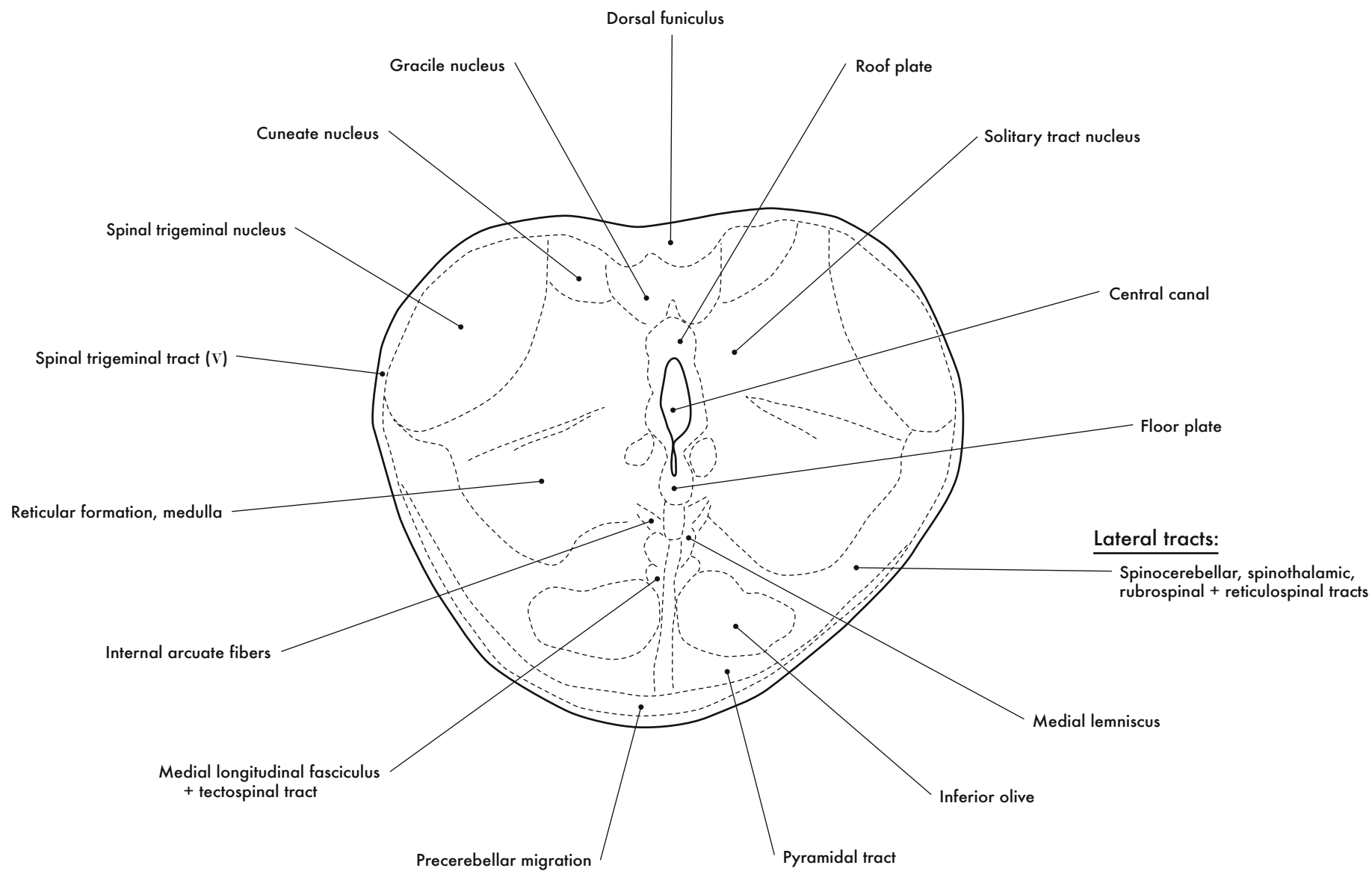


GD 14 HORIZONTAL 21





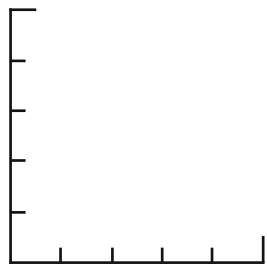
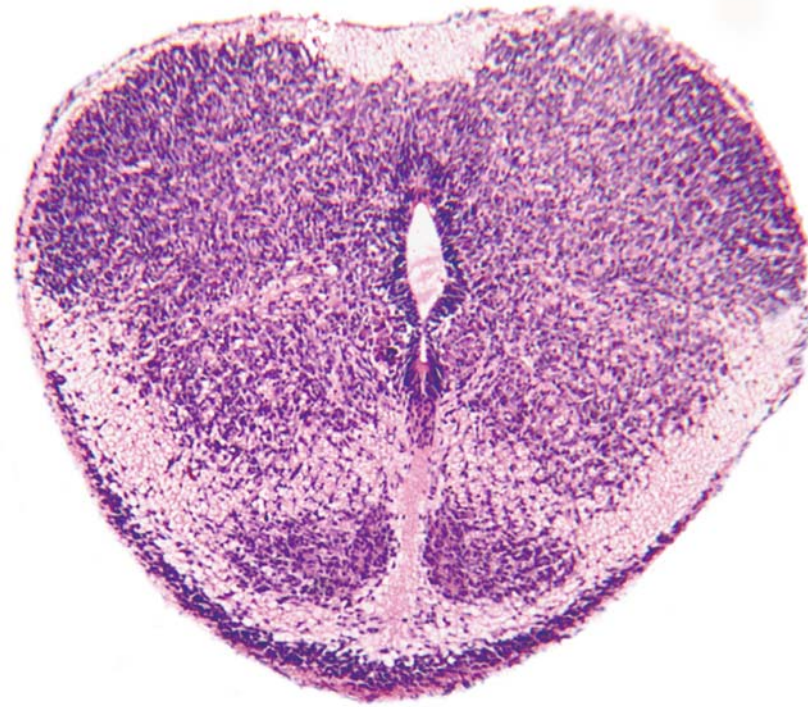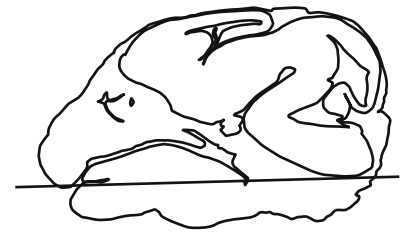
GD 14 HORIZONTAL 22



## Medulla

Note: Rotated 90° counterclockwise to present as coronal section

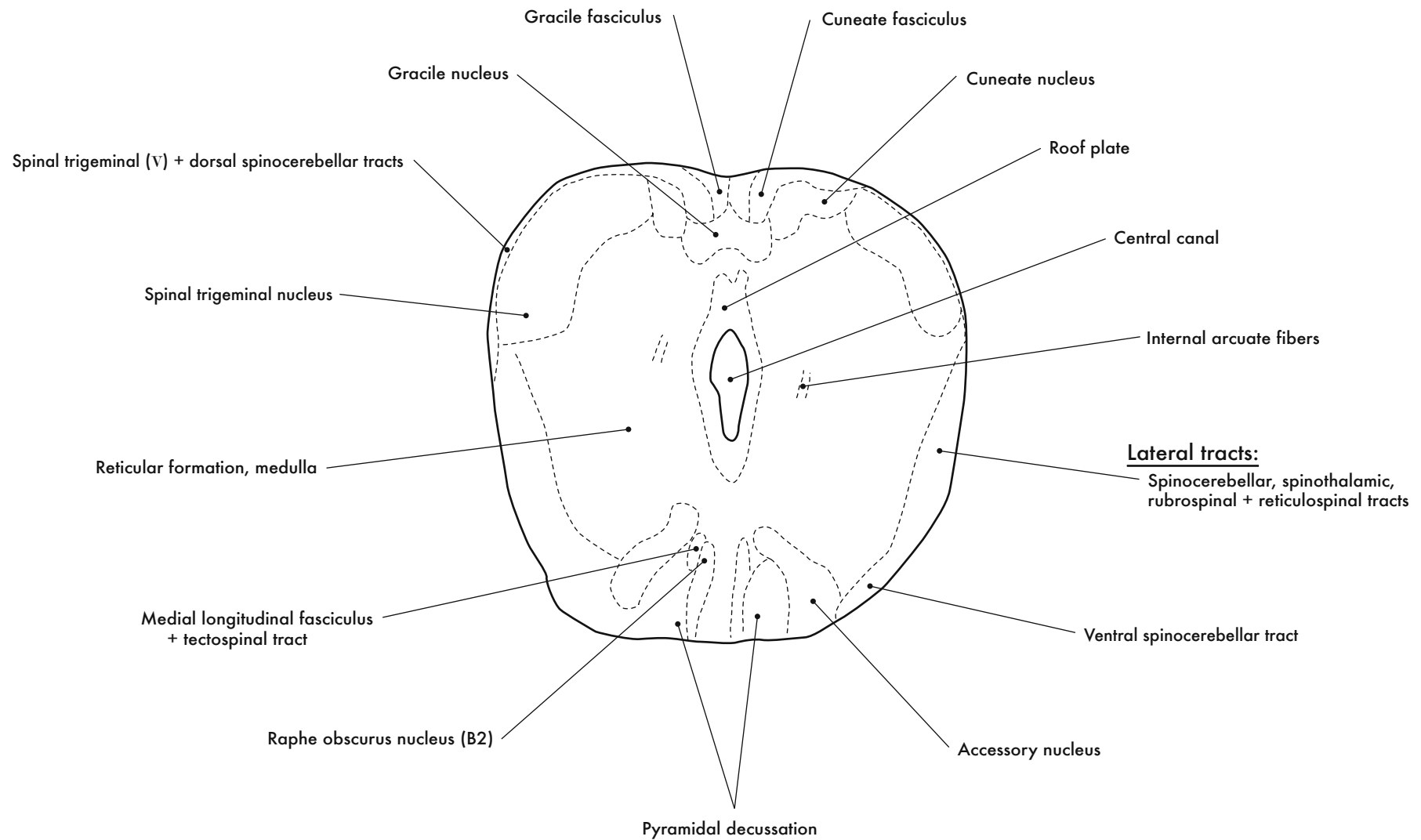




0.5 mm

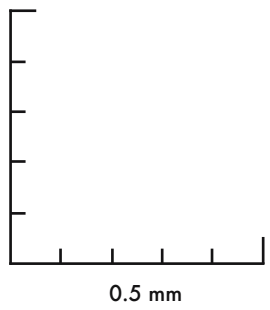
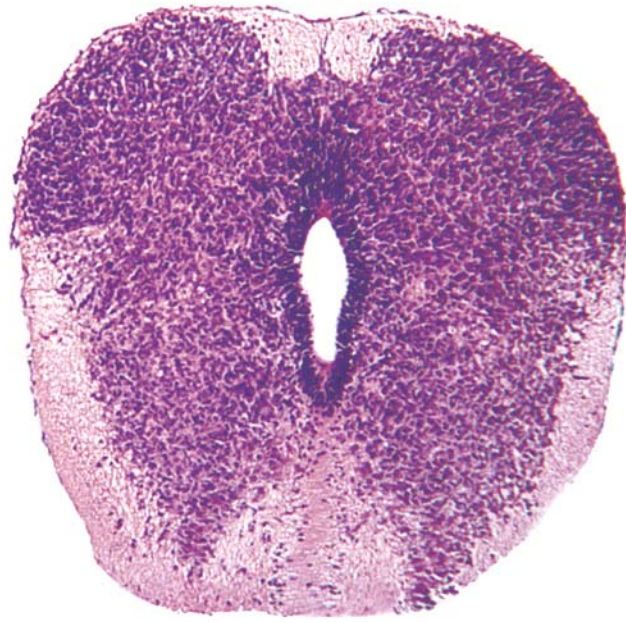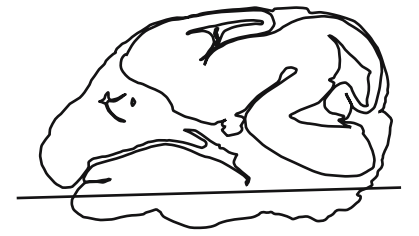GD 14 HORIZONTAL 23

275




Cervical Spinal Cord

Note: Rotated 90° counterclockwise to present as coronal section



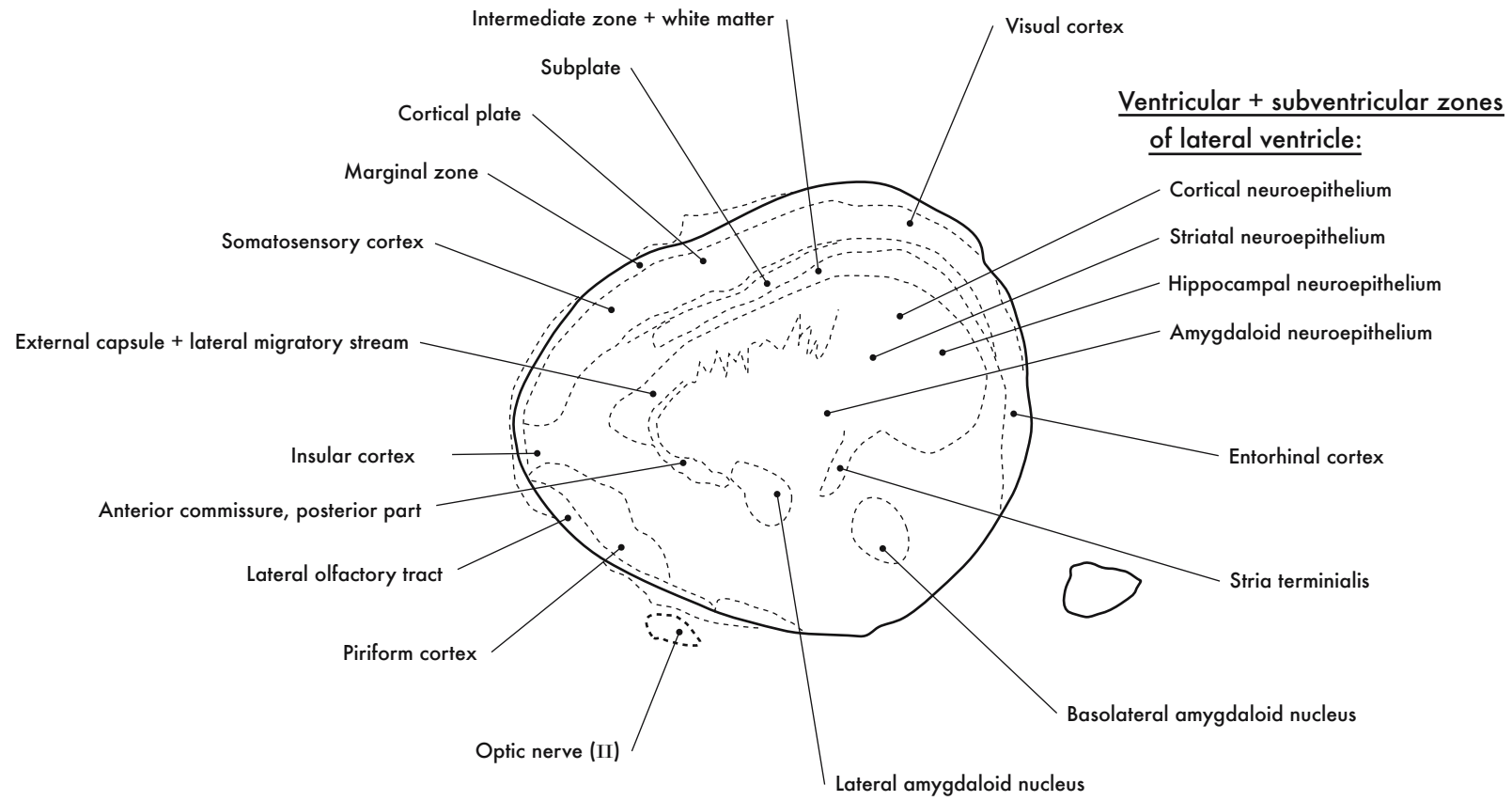
GD 14 HORIZONTAL 24

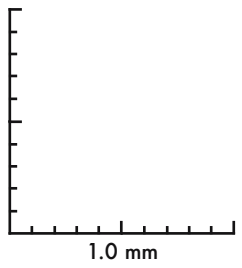
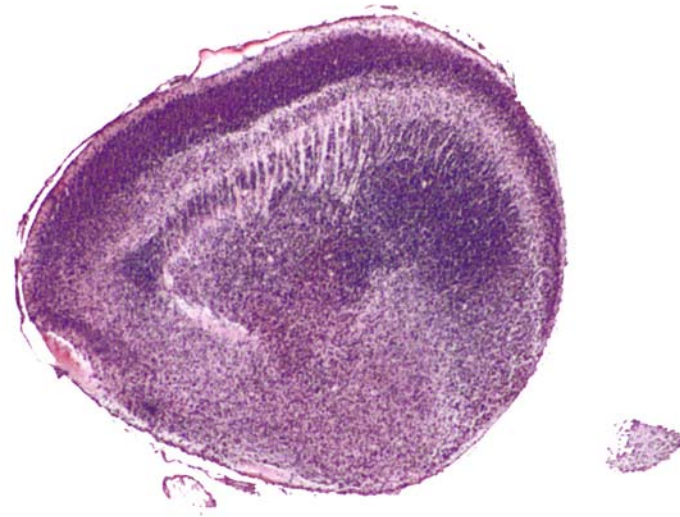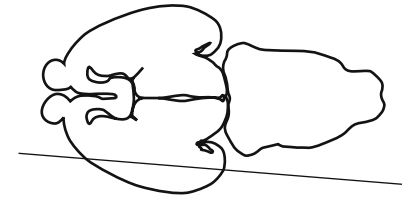
HP denotes image enlargement



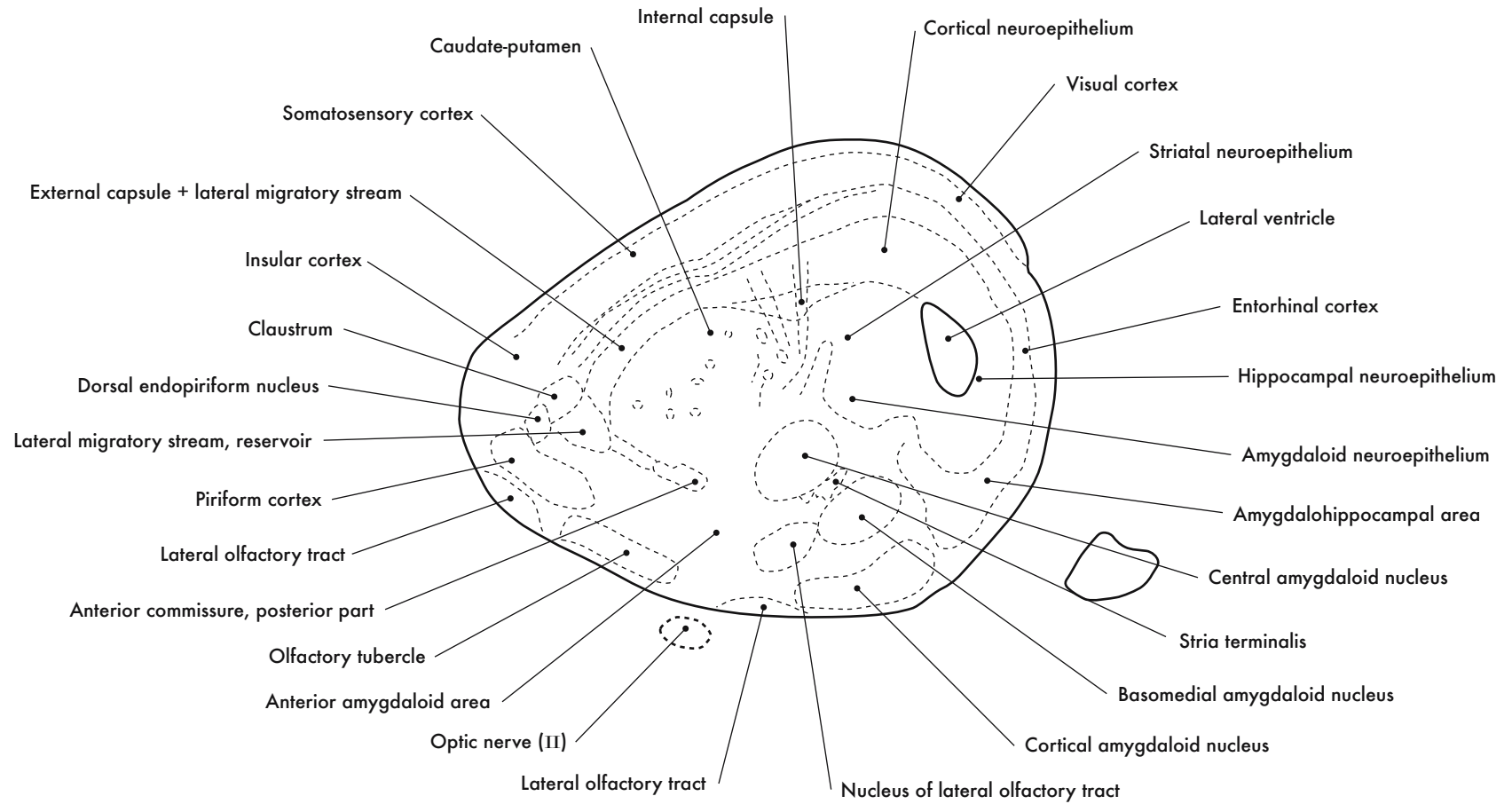
GESTATIONAL DAY 16 (GD 16)  
SAGITTAL SECTIONS

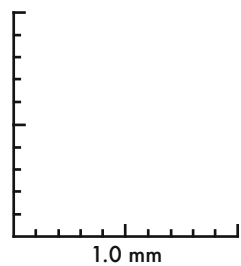
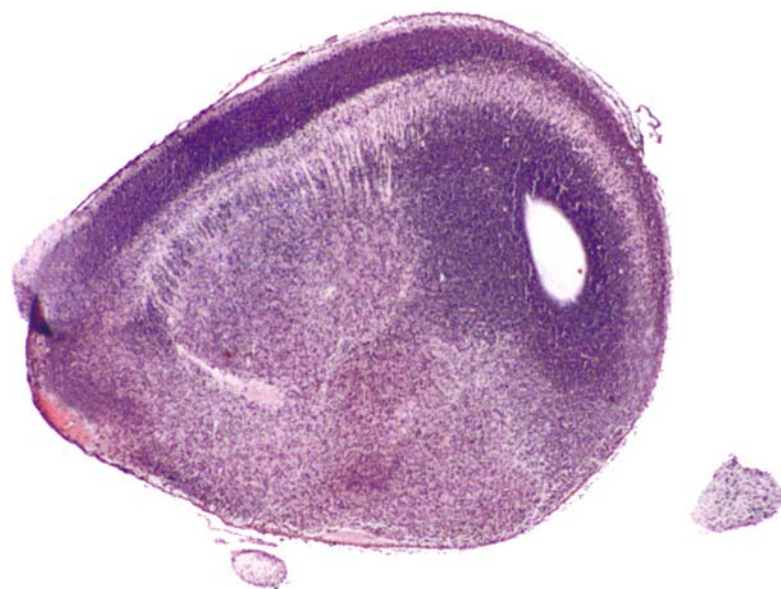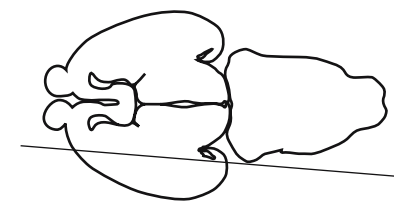






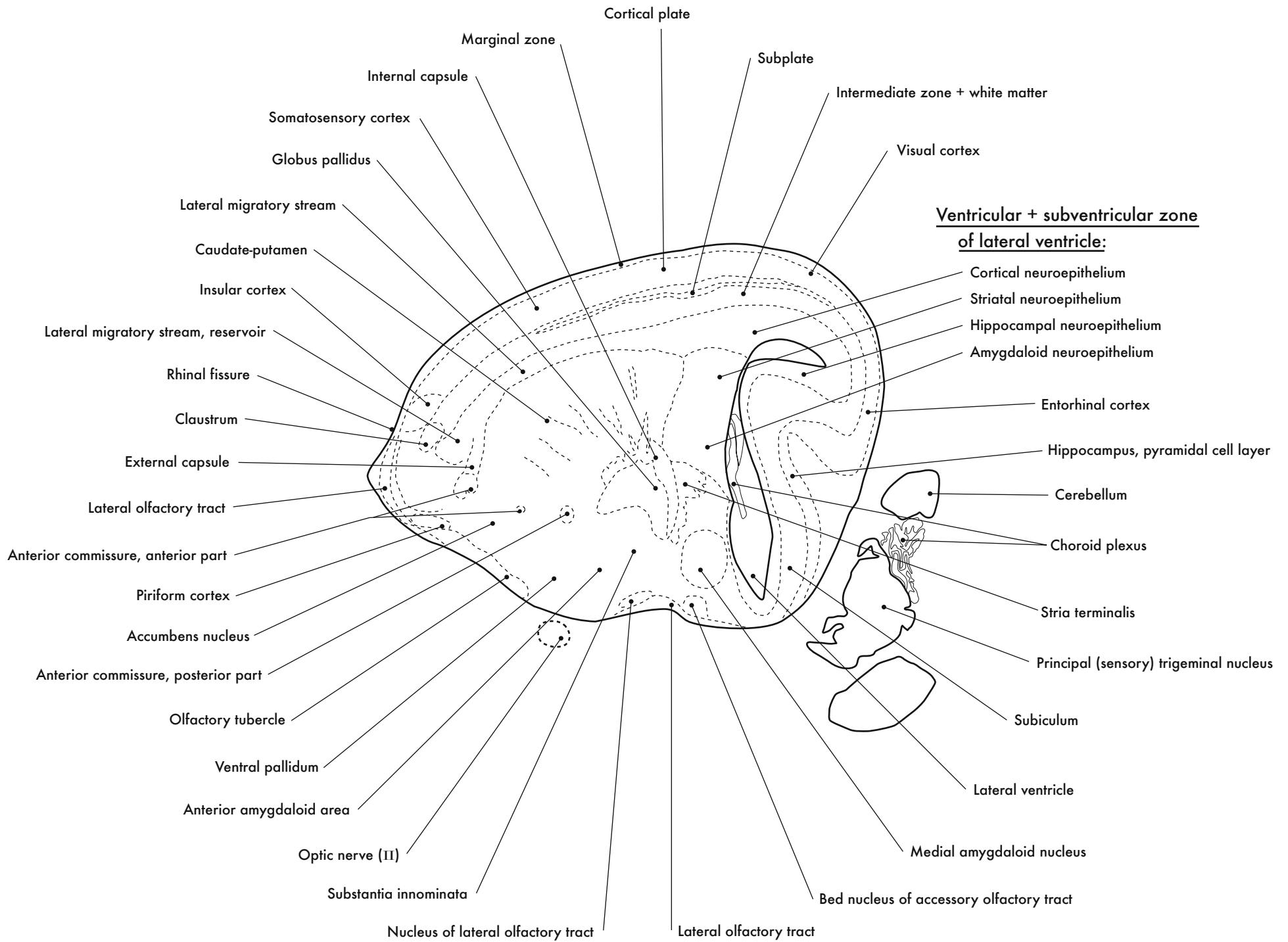
GD 16 SAGITTAL 1

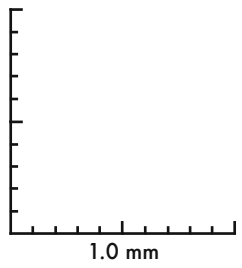
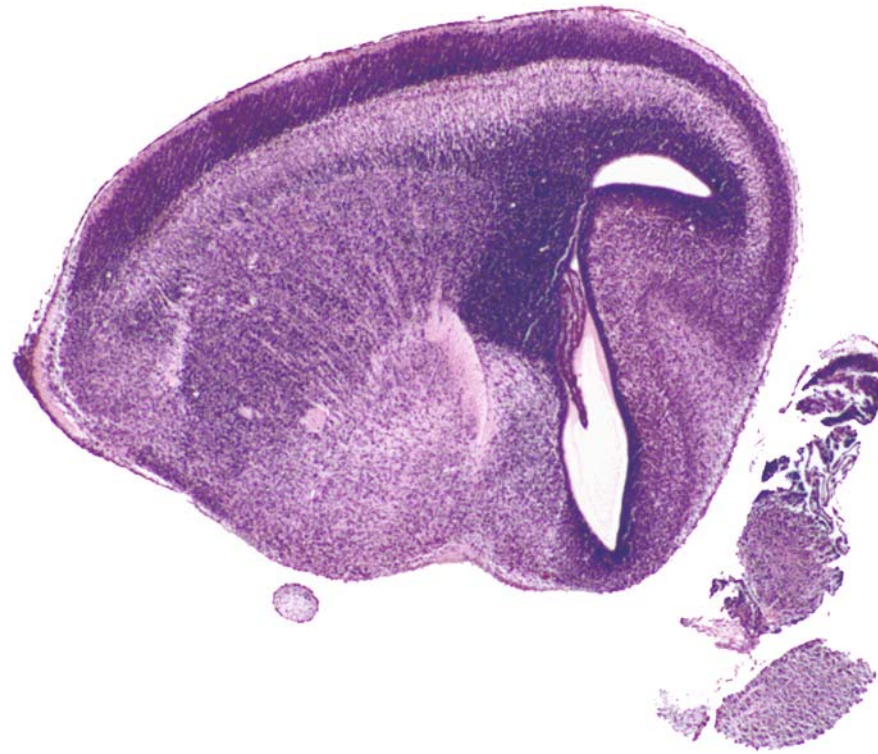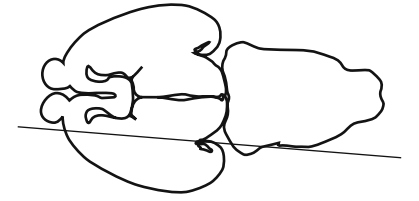




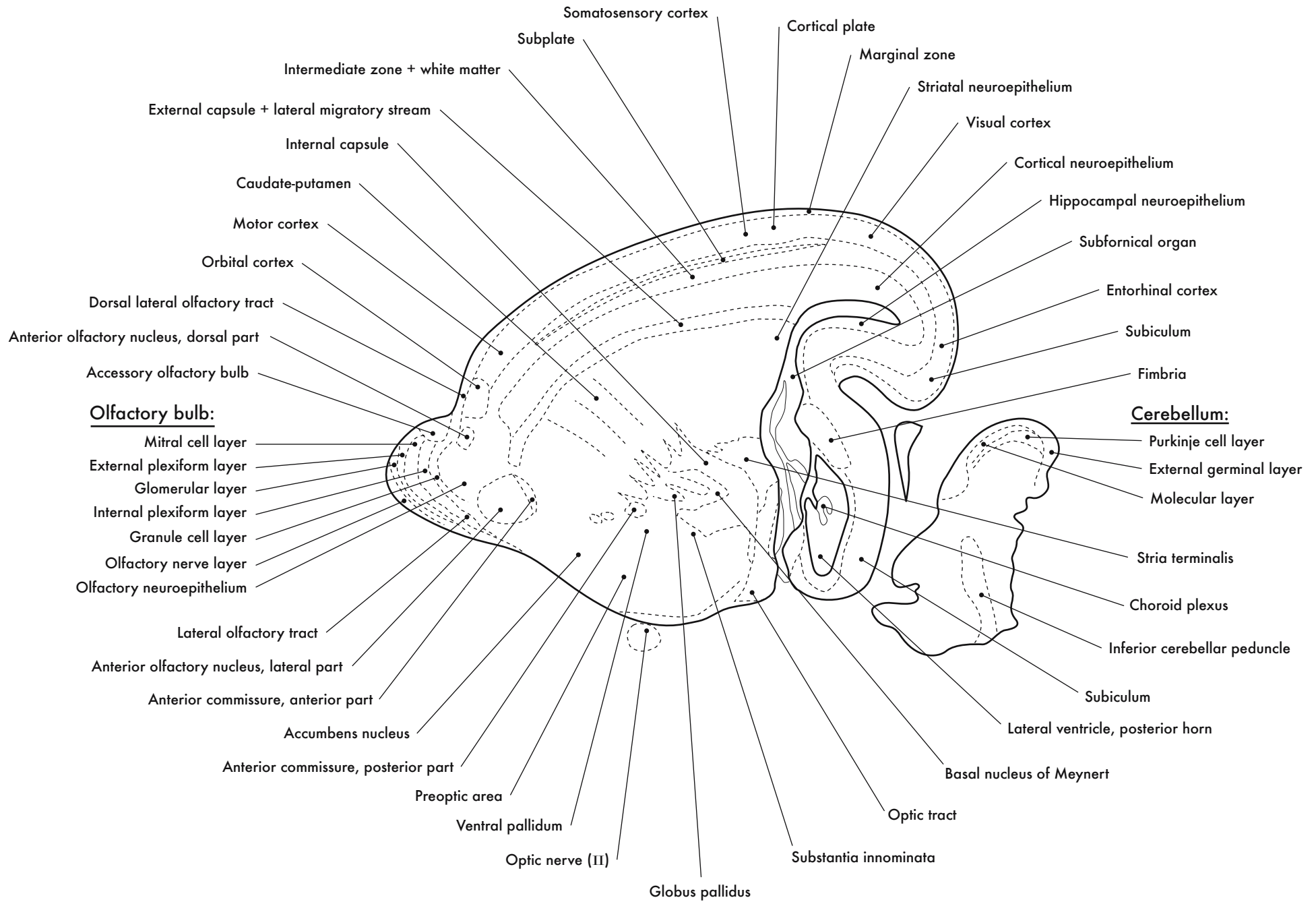
GD 16 SAGITTAL 2

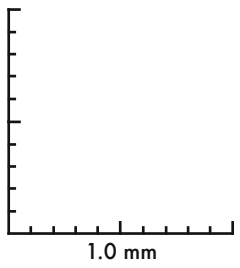
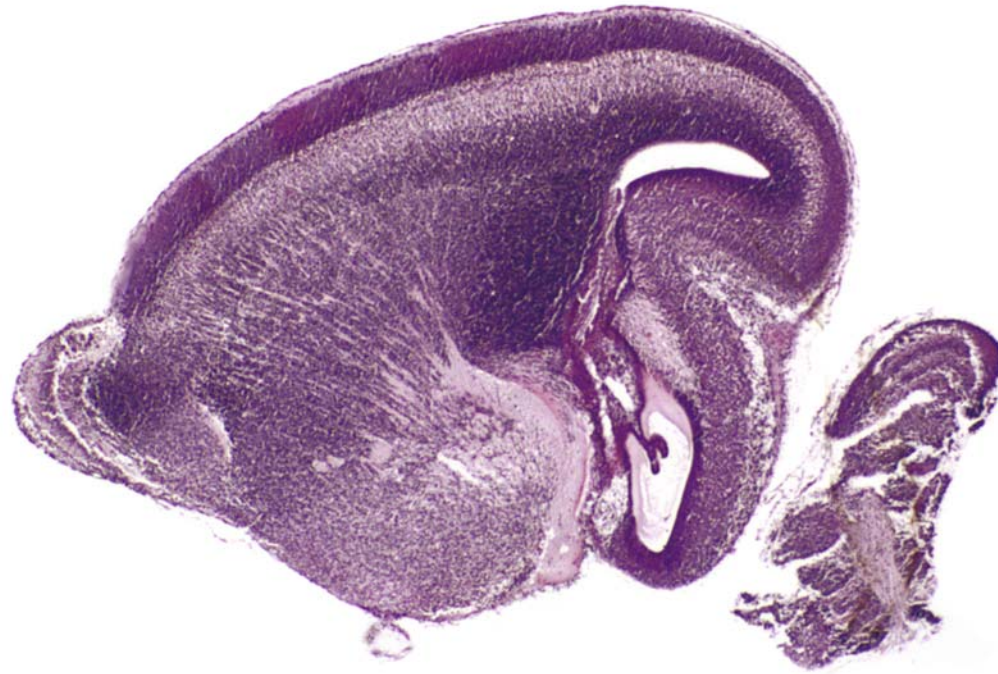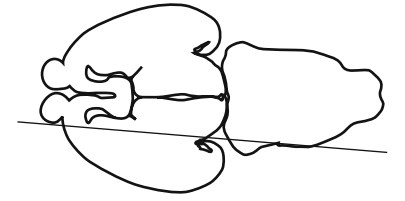






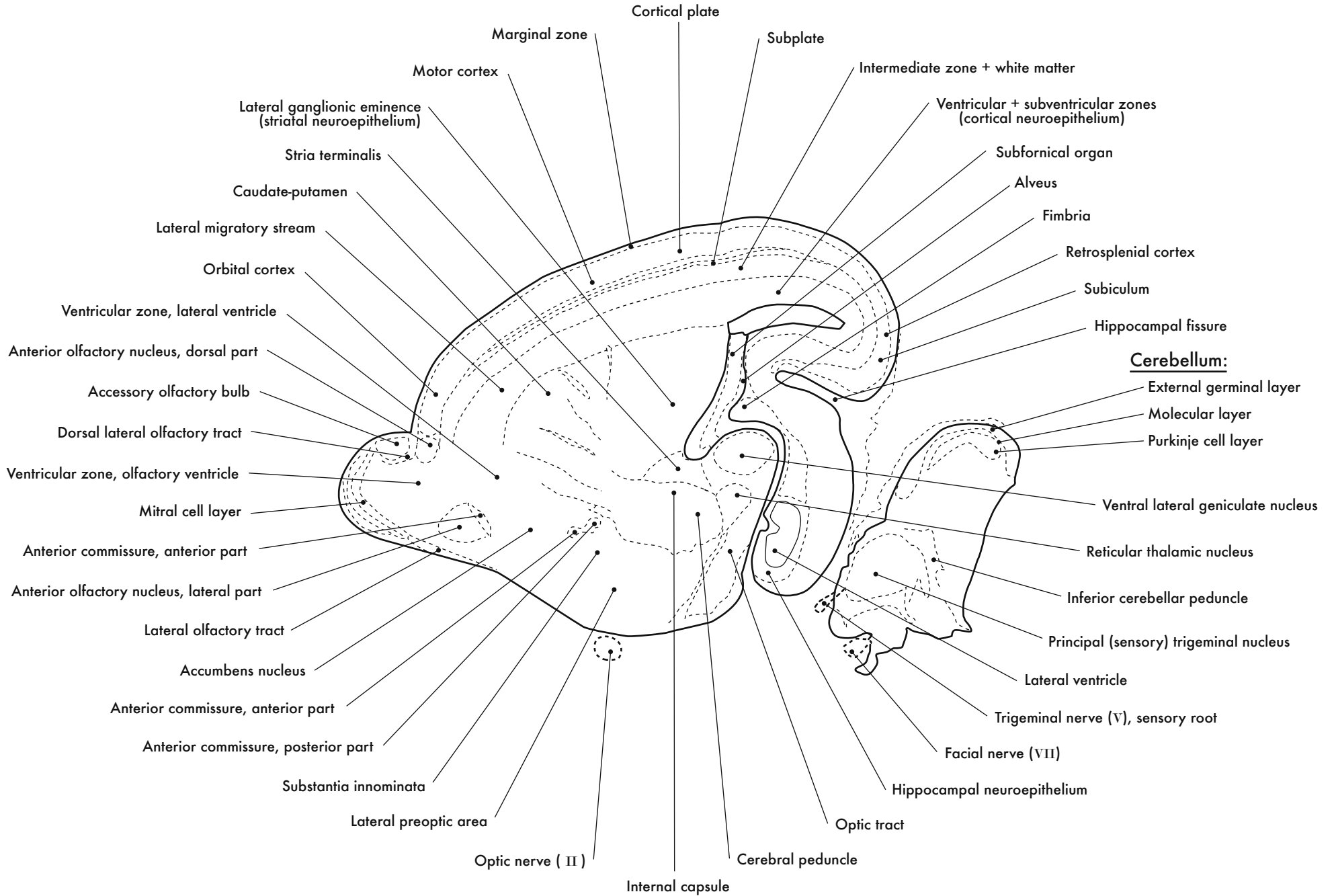
GD 16 SAGITTAL 3

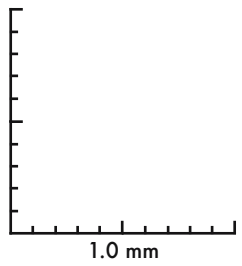
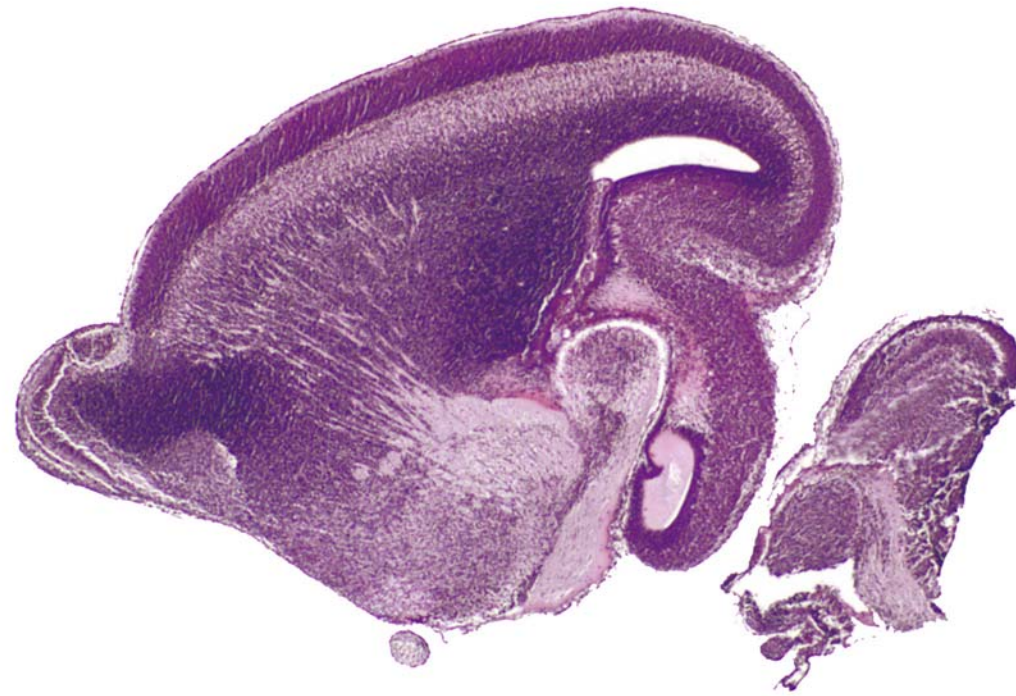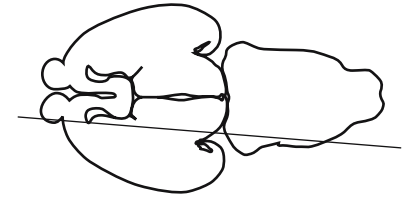




GD 16 SAGITTAL 4







GD 16 SAGITTAL 5

Hippocampal formation:

- Polymorph layer
- Pyramidal cell layer
- Dentate gyrus, granular cell layer
- Ventricular zone
- Molecular layer
- Alveus
- Fimbria

Motor cortex:

- Marginal zone
- Cortical plate
- Subplate
- Intermediate zone + white matter
- Ventricular + subventricular zones

Thalamus:

- Dorsal lateral geniculate nucleus
- Medial geniculate nucleus
- Ventral lateral geniculate nucleus
- External medullary lamina
- Reticular thalamic nucleus
- Ventral posterior lateral nucleus
- Medial lemniscus

Cerebellum:

- External germinal layer
- Molecular layer
- Purkinje cell layer
- Middle cerebellar peduncle
- Isthmus
- Mesencephalic trigeminal nucleus, migrating
- Mesencephalic trigeminal tract (V)
- Principal (sensory) trigeminal nucleus
- Dorsal cochlear nucleus
- Lateral vestibular nucleus
- Inferior cerebellar peduncle
- Trigeminal motor nucleus
- Pontine reticular nucleus
- Precerebellar migration
- Facial nerve (VI)

Accessory olfactory bulb:

- External plexiform layer
- Mitral cell layer
- Glomerular layer

Olfactory bulb:

- Mitral cell layer
- Glomerular + external plexiform layers
- Olfactory nerve layer
- Granule cell layer

Olfactory ventricle:

- Ventricular zone
- Subventricular zone

Anterior olfactory nucleus, posterior part

Anterior commissure, anterior part

Anterior commissure, posterior part

Lateral preoptic area

Optic nerve (I)

Internal capsule

Optic chiasm

Entopeduncular nucleus

Pontine nuclei

Optic tract

Facial nerve (VI)

Visual cortex

Retrosplenial cortex

Stria terminalis

Bed nucleus of stria terminalis

Lateral ganglionic eminence, ventricular + subventricular zones (striatal neuroepithelium)

Orbital cortex

Middle cerebellar peduncle

Isthmus

Mesencephalic trigeminal nucleus, migrating

Mesencephalic trigeminal tract (V)

Principal (sensory) trigeminal nucleus

Dorsal cochlear nucleus

Lateral vestibular nucleus

Inferior cerebellar peduncle

Trigeminal motor nucleus

Pontine reticular nucleus

Precerebellar migration

Facial nerve (VI)

Pontine nuclei

Optic tract

Entopeduncular nucleus

Optic nerve (I)

Internal capsule

Optic chiasm

Entopeduncular nucleus

Pontine nuclei

Optic tract

Facial nerve (VI)

Middle cerebellar peduncle

Isthmus

Mesencephalic trigeminal nucleus, migrating

Mesencephalic trigeminal tract (V)

Principal (sensory) trigeminal nucleus

Dorsal cochlear nucleus

Lateral vestibular nucleus

Inferior cerebellar peduncle

Trigeminal motor nucleus

Pontine reticular nucleus

Precerebellar migration

Facial nerve (VI)

Pontine nuclei

Optic tract

Entopeduncular nucleus

Optic nerve (I)

Internal capsule

Optic chiasm

Entopeduncular nucleus

Pontine nuclei

Optic tract

Facial nerve (VI)

Middle cerebellar peduncle

Isthmus

Mesencephalic trigeminal nucleus, migrating

Mesencephalic trigeminal tract (V)

Principal (sensory) trigeminal nucleus

Dorsal cochlear nucleus

Lateral vestibular nucleus

Inferior cerebellar peduncle

Trigeminal motor nucleus

Pontine reticular nucleus

Precerebellar migration

Facial nerve (VI)

Pontine nuclei

Optic tract

Entopeduncular nucleus

Optic nerve (I)

Internal capsule

Optic chiasm

Entopeduncular nucleus

Pontine nuclei

Optic tract

Facial nerve (VI)

Middle cerebellar peduncle

Isthmus

Mesencephalic trigeminal nucleus, migrating

Mesencephalic trigeminal tract (V)

Principal (sensory) trigeminal nucleus

Dorsal cochlear nucleus

Lateral vestibular nucleus

Inferior cerebellar peduncle

Trigeminal motor nucleus

Pontine reticular nucleus

Precerebellar migration

Facial nerve (VI)

Pontine nuclei

Optic tract

Entopeduncular nucleus

Optic nerve (I)

Internal capsule

Optic chiasm

Entopeduncular nucleus

Pontine nuclei

Optic tract

Facial nerve (VI)

Middle cerebellar peduncle

Isthmus

Mesencephalic trigeminal nucleus, migrating

Mesencephalic trigeminal tract (V)

Principal (sensory) trigeminal nucleus

Dorsal cochlear nucleus

Lateral vestibular nucleus

Inferior cerebellar peduncle

Trigeminal motor nucleus

Pontine reticular nucleus

Precerebellar migration

Facial nerve (VI)

Pontine nuclei

Optic tract

Entopeduncular nucleus

Optic nerve (I)

Internal capsule

Optic chiasm

Entopeduncular nucleus

Pontine nuclei

Optic tract

Facial nerve (VI)

Middle cerebellar peduncle

Isthmus

Mesencephalic trigeminal nucleus, migrating

Mesencephalic trigeminal tract (V)

Principal (sensory) trigeminal nucleus

Dorsal cochlear nucleus

Lateral vestibular nucleus

Inferior cerebellar peduncle

Trigeminal motor nucleus

Pontine reticular nucleus

Precerebellar migration

Facial nerve (VI)

Pontine nuclei

Optic tract

Entopeduncular nucleus

Optic nerve (I)

Internal capsule

Optic chiasm

Entopeduncular nucleus

Pontine nuclei

Optic tract

Facial nerve (VI)

Middle cerebellar peduncle

Isthmus

Mesencephalic trigeminal nucleus, migrating

Mesencephalic trigeminal tract (V)

Principal (sensory) trigeminal nucleus

Dorsal cochlear nucleus

Lateral vestibular nucleus

Inferior cerebellar peduncle

Trigeminal motor nucleus

Pontine reticular nucleus

Precerebellar migration

Facial nerve (VI)

Pontine nuclei

Optic tract

Entopeduncular nucleus

Optic nerve (I)

Internal capsule

Optic chiasm

Entopeduncular nucleus

Pontine nuclei

Optic tract

Facial nerve (VI)

Middle cerebellar peduncle

Isthmus

Mesencephalic trigeminal nucleus, migrating

Mesencephalic trigeminal tract (V)

Principal (sensory) trigeminal nucleus

Dorsal cochlear nucleus

Lateral vestibular nucleus

Inferior cerebellar peduncle

Trigeminal motor nucleus

Pontine reticular nucleus

Precerebellar migration

Facial nerve (VI)

Pontine nuclei

Optic tract

Entopeduncular nucleus

Optic nerve (I)

Internal capsule

Optic chiasm

Entopeduncular nucleus

Pontine nuclei

Optic tract

Facial nerve (VI)

Middle cerebellar peduncle

Isthmus

Mesencephalic trigeminal nucleus, migrating

Mesencephalic trigeminal tract (V)

Principal (sensory) trigeminal nucleus

Dorsal cochlear nucleus

Lateral vestibular nucleus

Inferior cerebellar peduncle

Trigeminal motor nucleus

Pontine reticular nucleus

Precerebellar migration

Facial nerve (VI)

Pontine nuclei

Optic tract

Entopeduncular nucleus

Optic nerve (I)

Internal capsule

Optic chiasm

Entopeduncular nucleus

Pontine nuclei

Optic tract

Facial nerve (VI)

Middle cerebellar peduncle

Isthmus

Mesencephalic trigeminal nucleus, migrating

Mesencephalic trigeminal tract (V)

Principal (sensory) trigeminal nucleus

Dorsal cochlear nucleus

Lateral vestibular nucleus

Inferior cerebellar peduncle

Trigeminal motor nucleus

Pontine reticular nucleus

Precerebellar migration

Facial nerve (VI)

Pontine nuclei

Optic tract

Entopeduncular nucleus

Optic nerve (I)

Internal capsule

Optic chiasm

Entopeduncular nucleus

Pontine nuclei

Optic tract

Facial nerve (VI)

Middle cerebellar peduncle

Isthmus

Mesencephalic trigeminal nucleus, migrating

Mesencephalic trigeminal tract (V)

Principal (sensory) trigeminal nucleus

Dorsal cochlear nucleus

Lateral vestibular nucleus

Inferior cerebellar peduncle

Trigeminal motor nucleus

Pontine reticular nucleus

Precerebellar migration

Facial nerve (VI)

Pontine nuclei

Optic tract

Entopeduncular nucleus

Optic nerve (I)

Internal capsule

Optic chiasm

Entopeduncular nucleus

Pontine nuclei

Optic tract

Facial nerve (VI)

Middle cerebellar peduncle

Isthmus

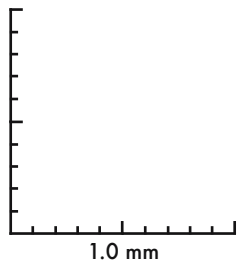
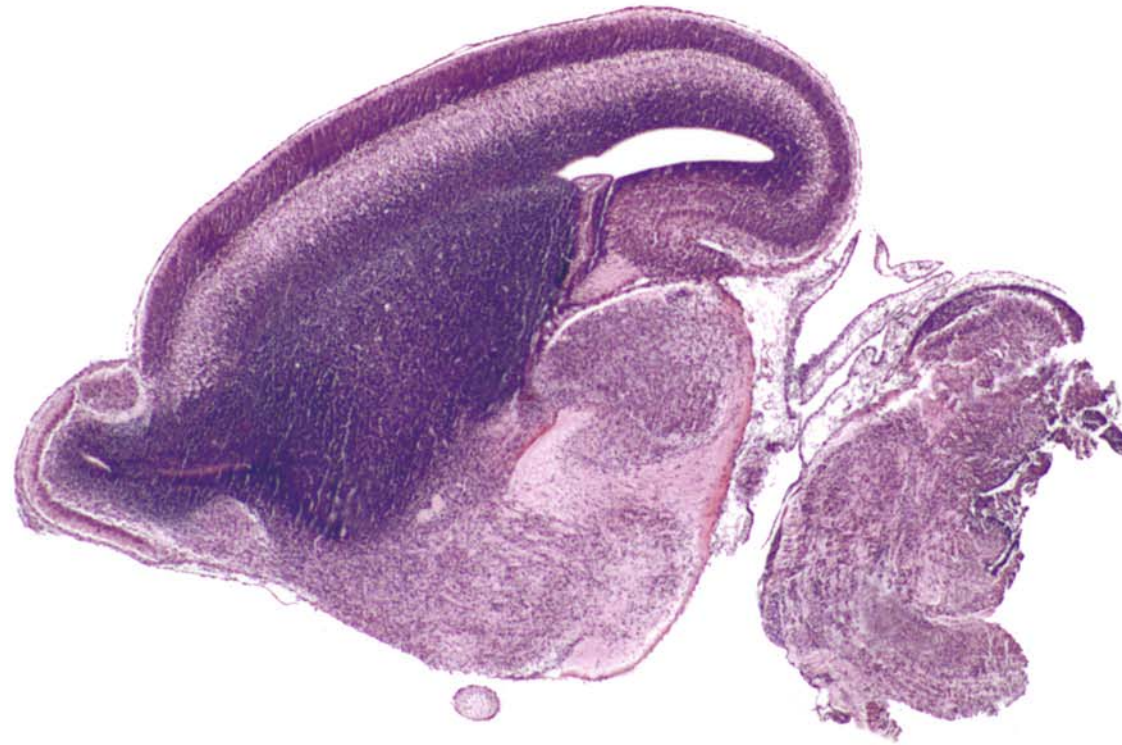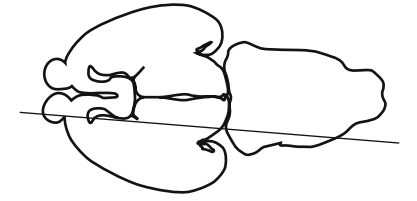
Mesencephalic trigeminal nucleus, migrating

Mesencephalic trigeminal tract (V)

Principal (sensory) trigeminal nucleus

Dorsal cochlear nucleus

Lateral vestibular nucleus



GD 16 SAGITTAL 6



**Accessory olfactory bulb:**

- Vomeronasal nerve
- External plexiform layer
- Mitral cell layer
- Granule cell layer

Dorsal lateral olfactory tract

**Olfactory bulb:**

- Olfactory nerve layer
- Glomerular + external plexiform layers
- Mitral cell layer
- Internal plexiform layer
- Granule cell layer

Olfactory ventricle

Ventricular zone

Subventricular zone

Pia mater

**Orbital cortex:**

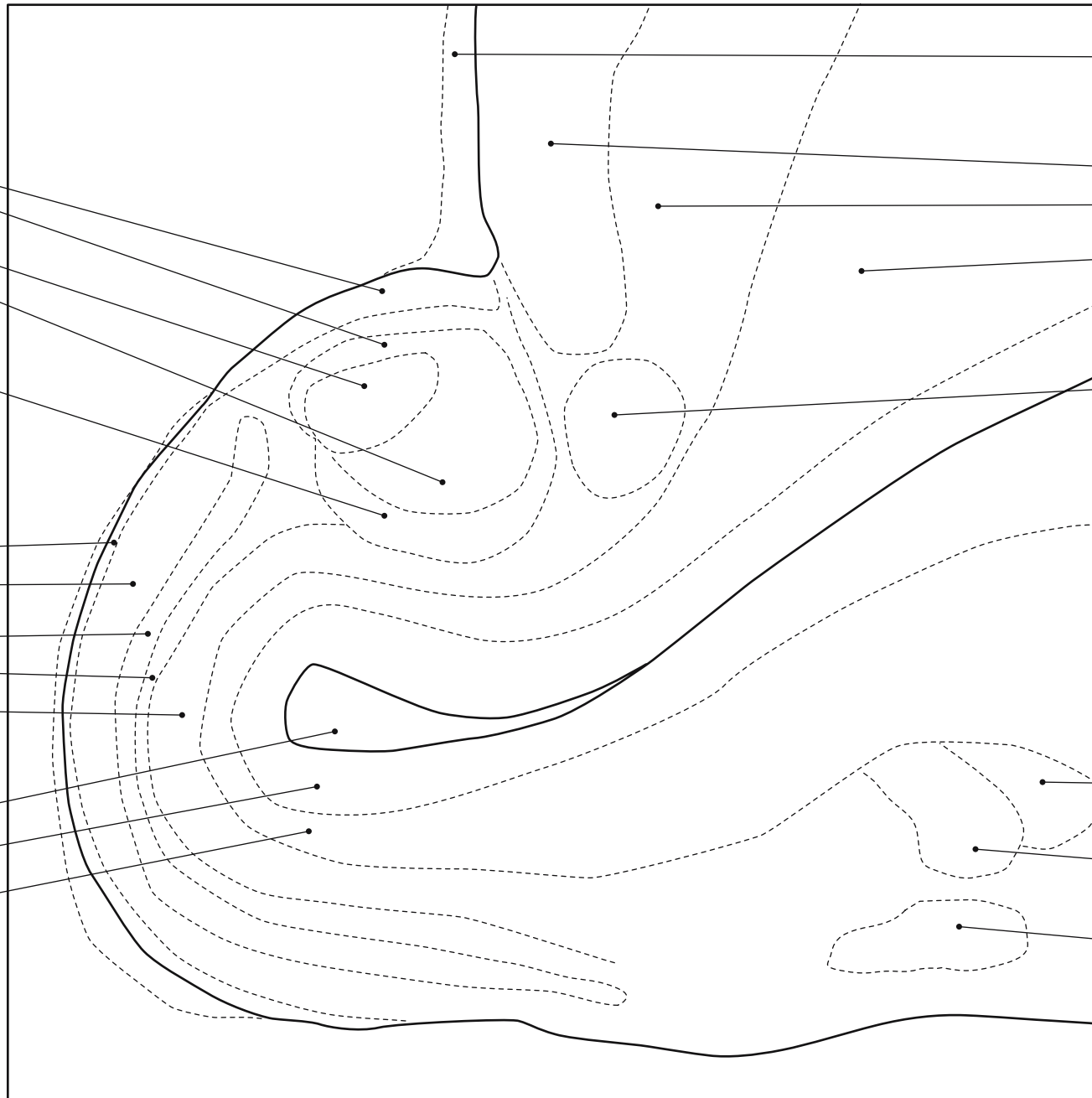
- Cortical plate
- Intermediate zone + white matter
- Subventricular zone

Anterior olfactory nucleus, dorsal part

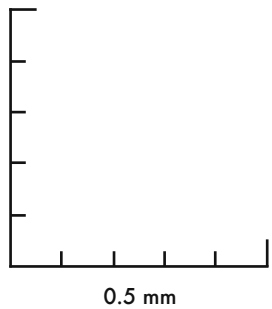
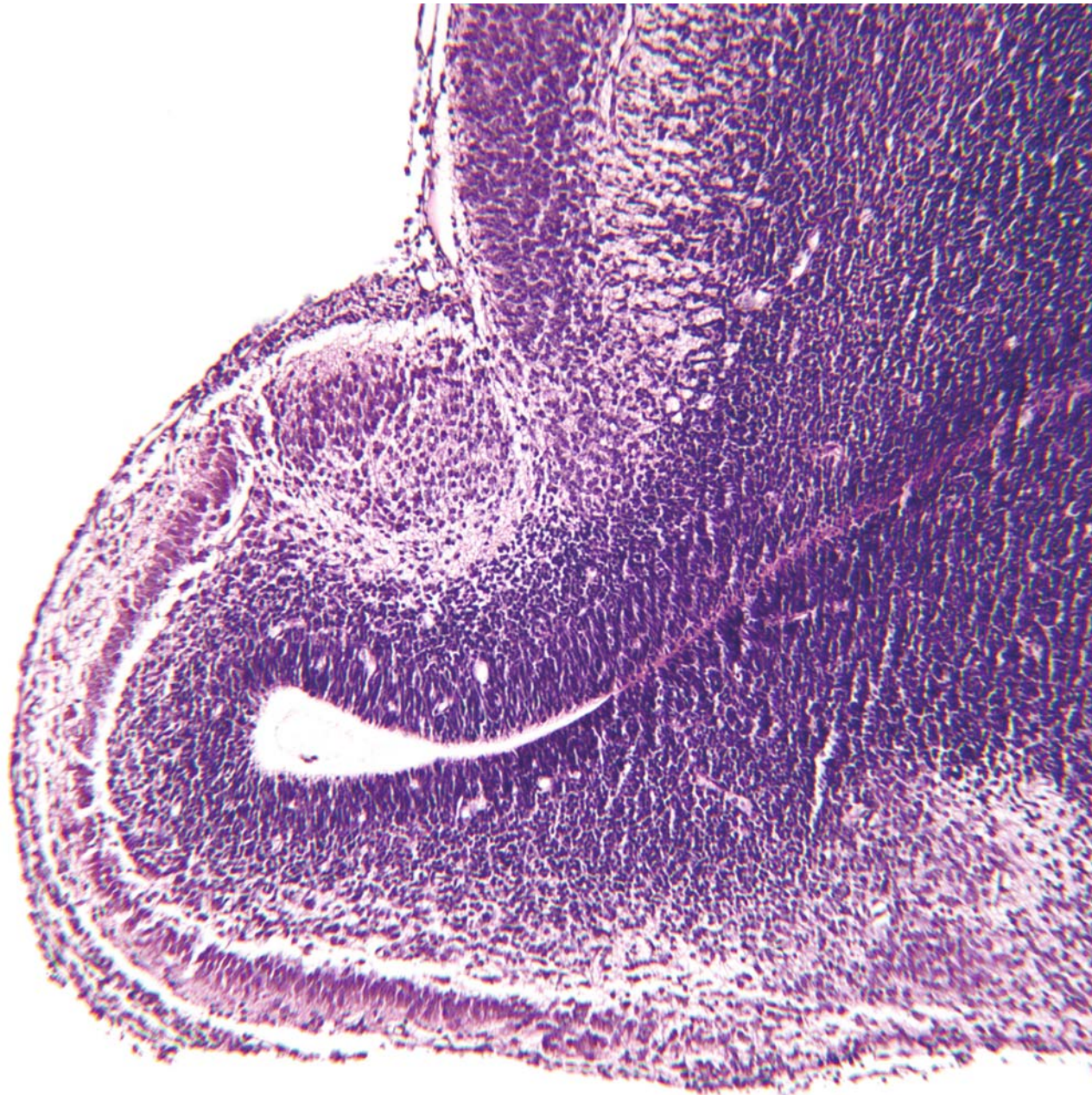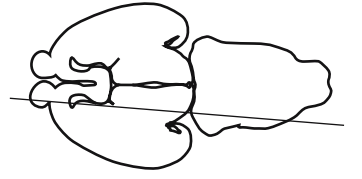
Anterior commissure, anterior part

Anterior olfactory nucleus, posterior part

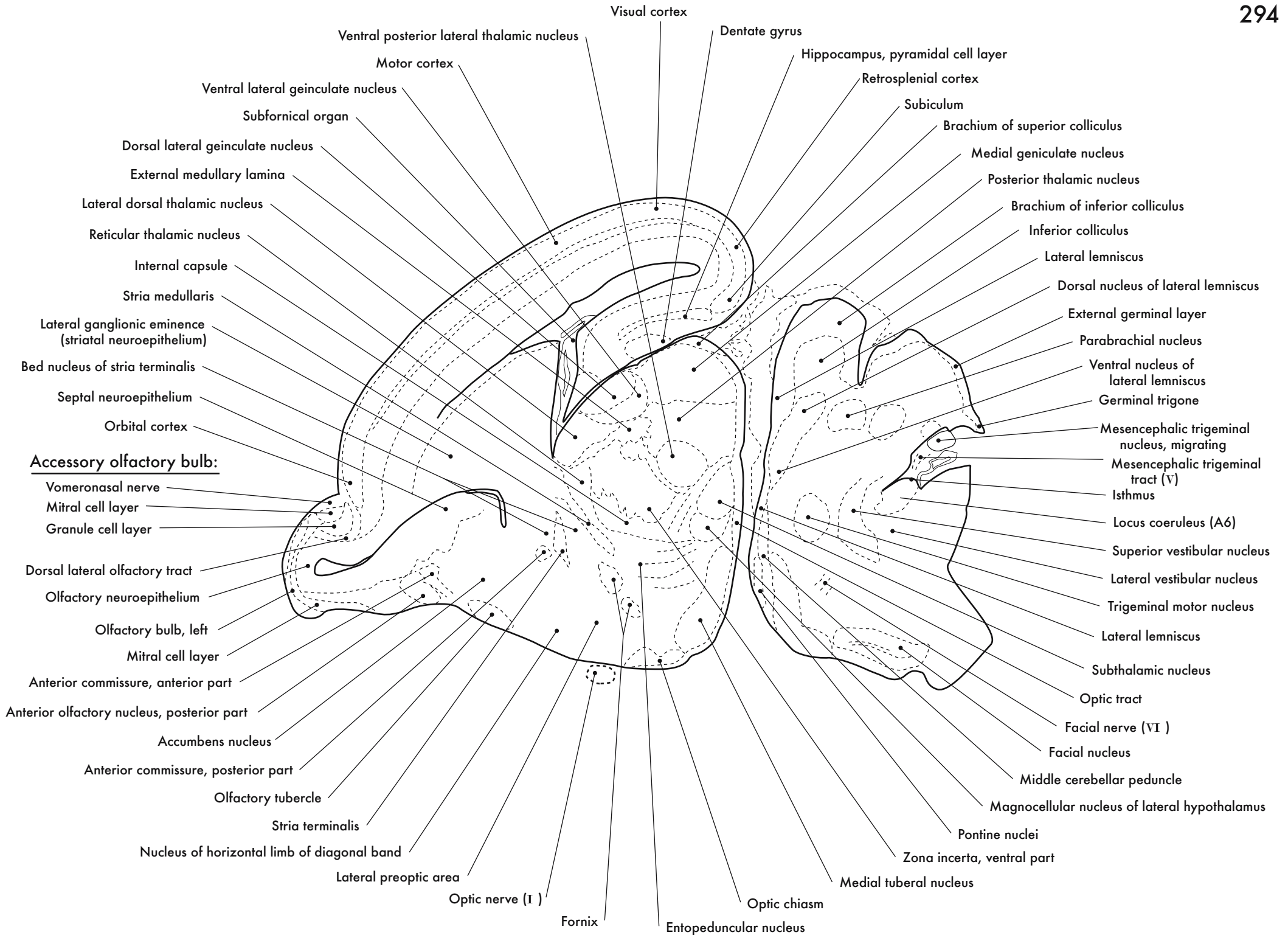
Anterior olfactory nucleus, ventral part



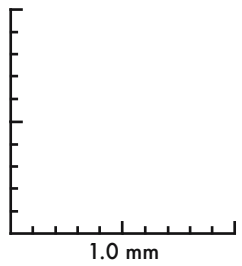
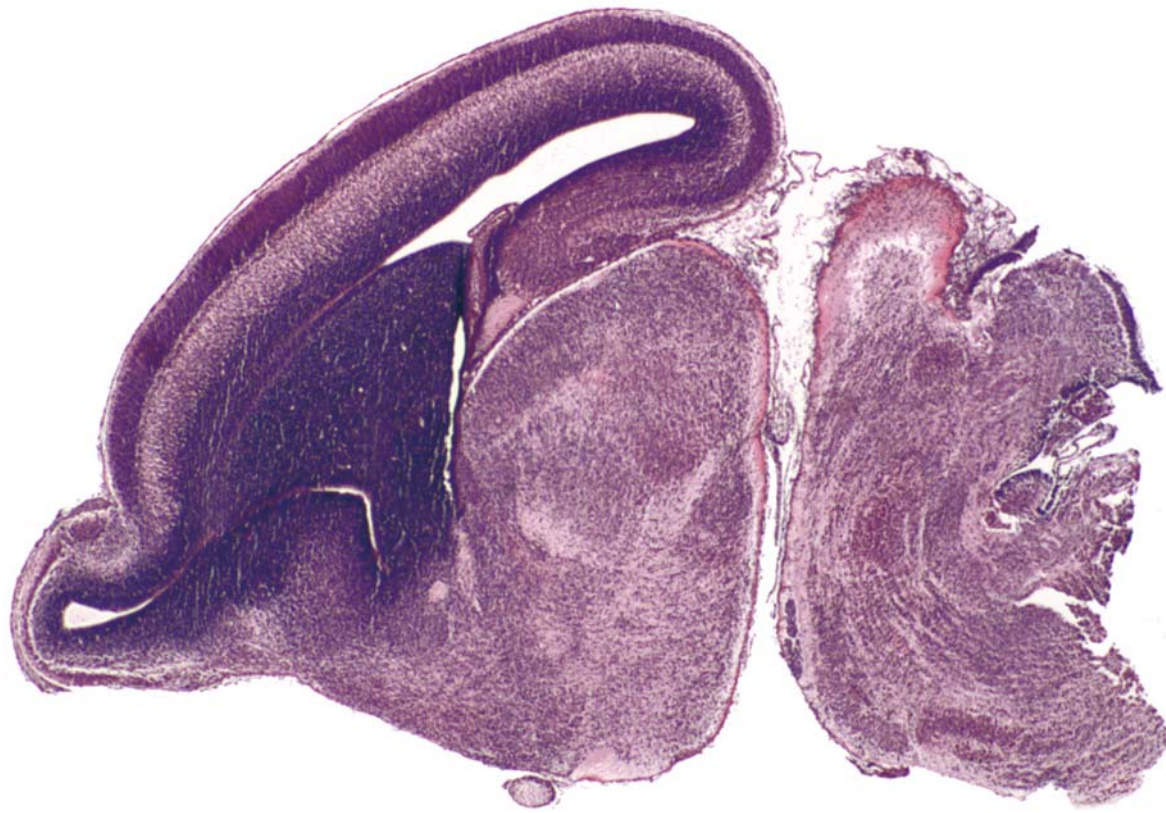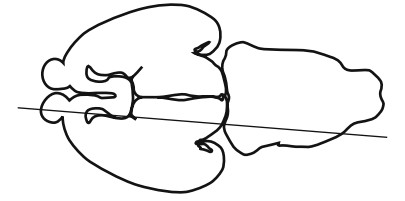
Olfactory Bulb



GD 16 SAGITTAL 7

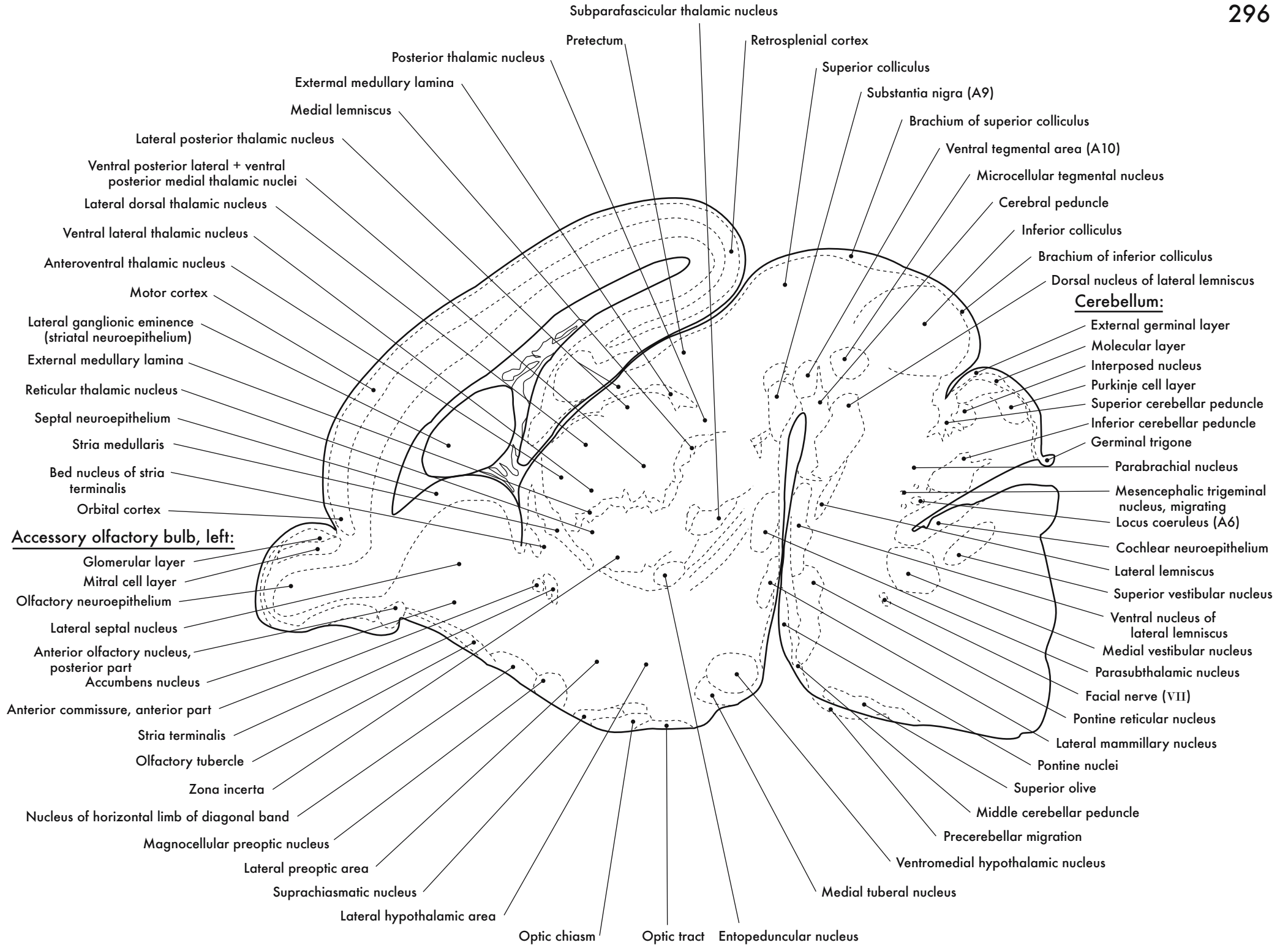


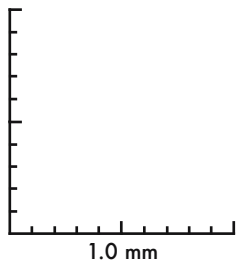
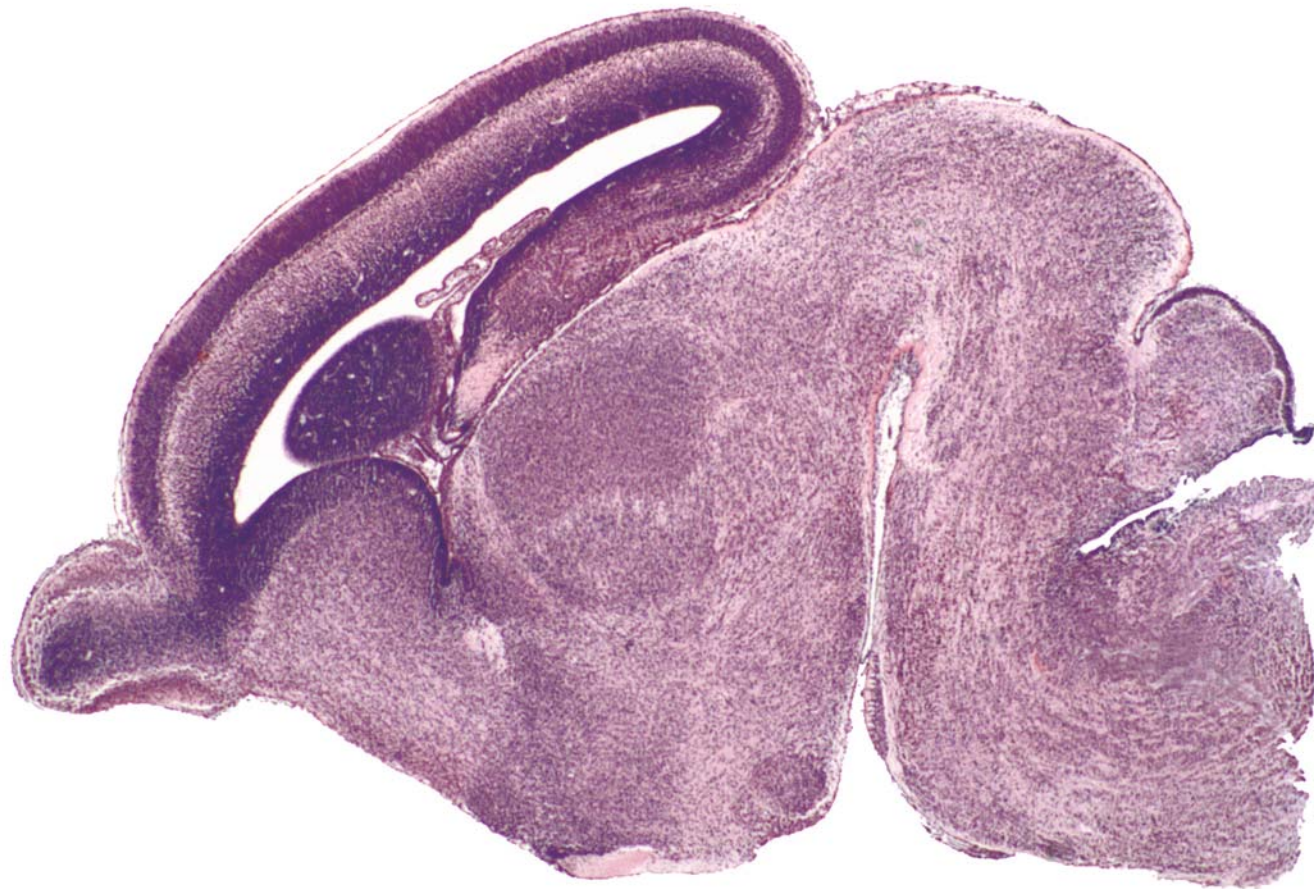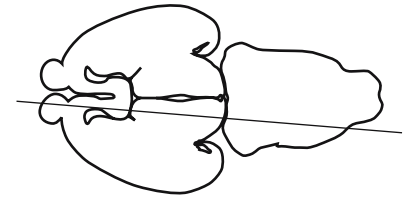




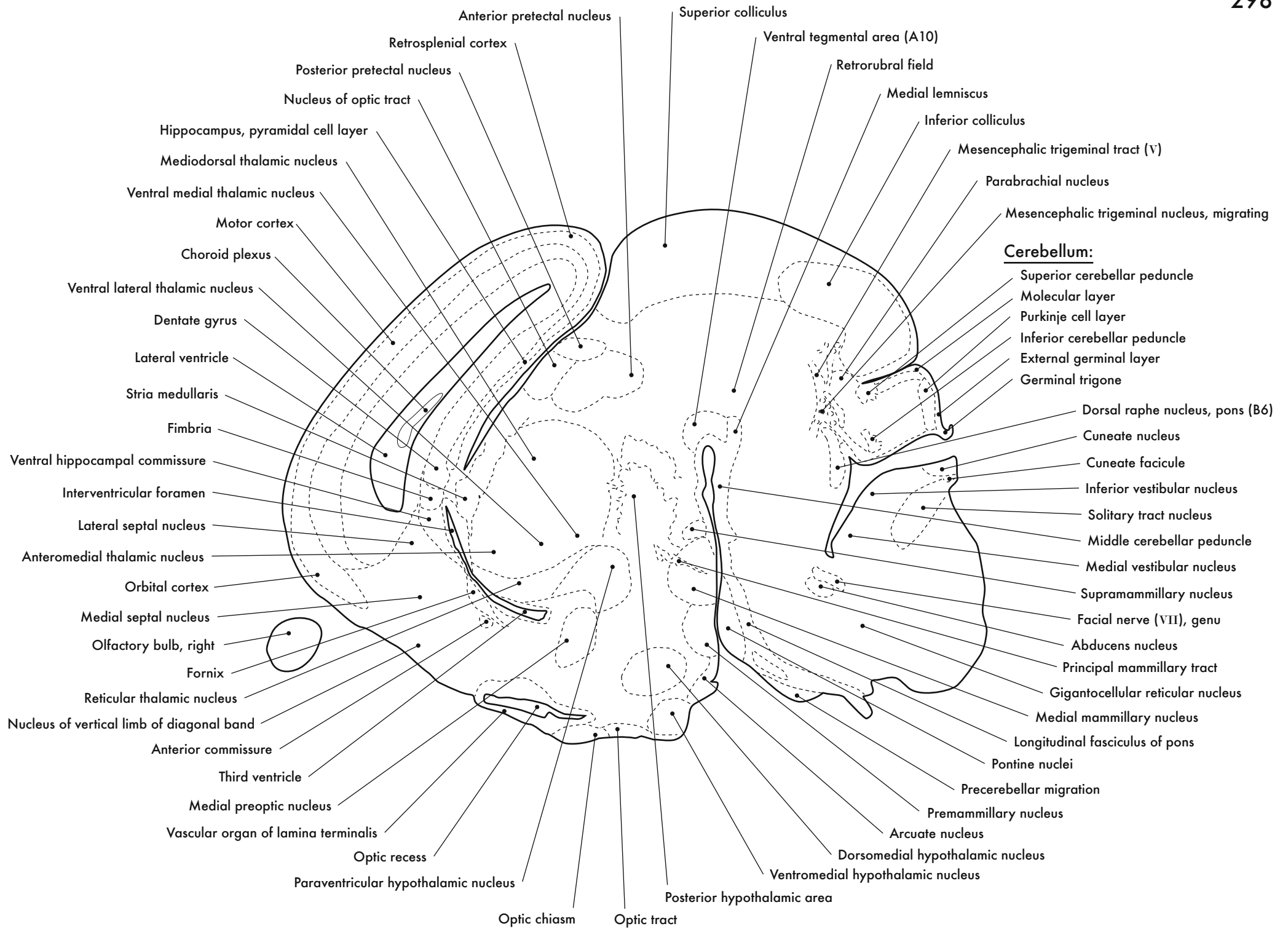
GD 16 SAGITTAL 8



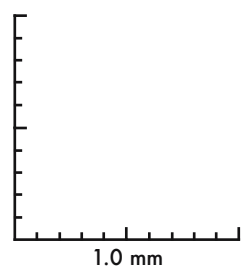
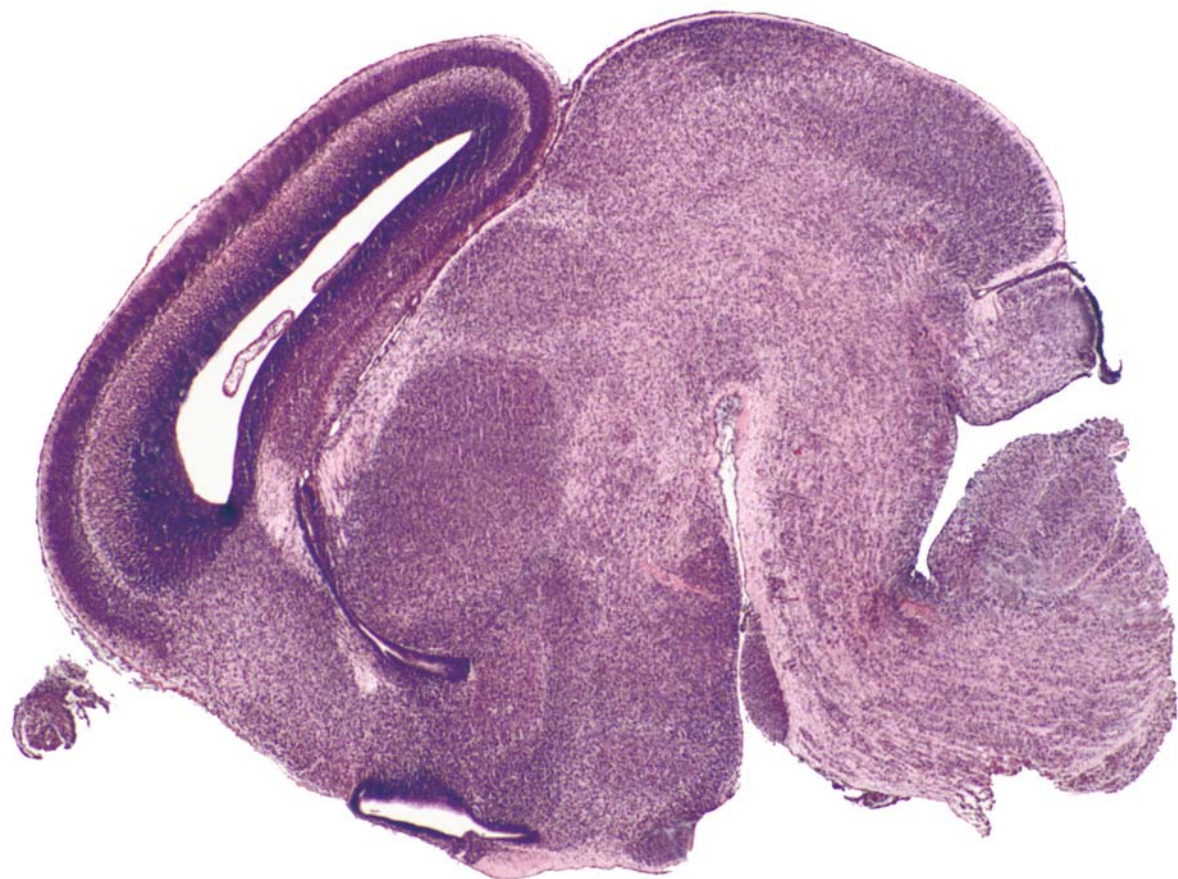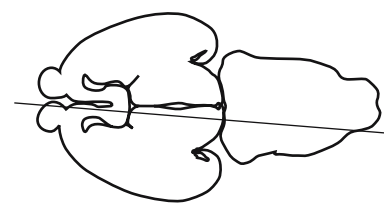




GD 16 SAGITTAL 9

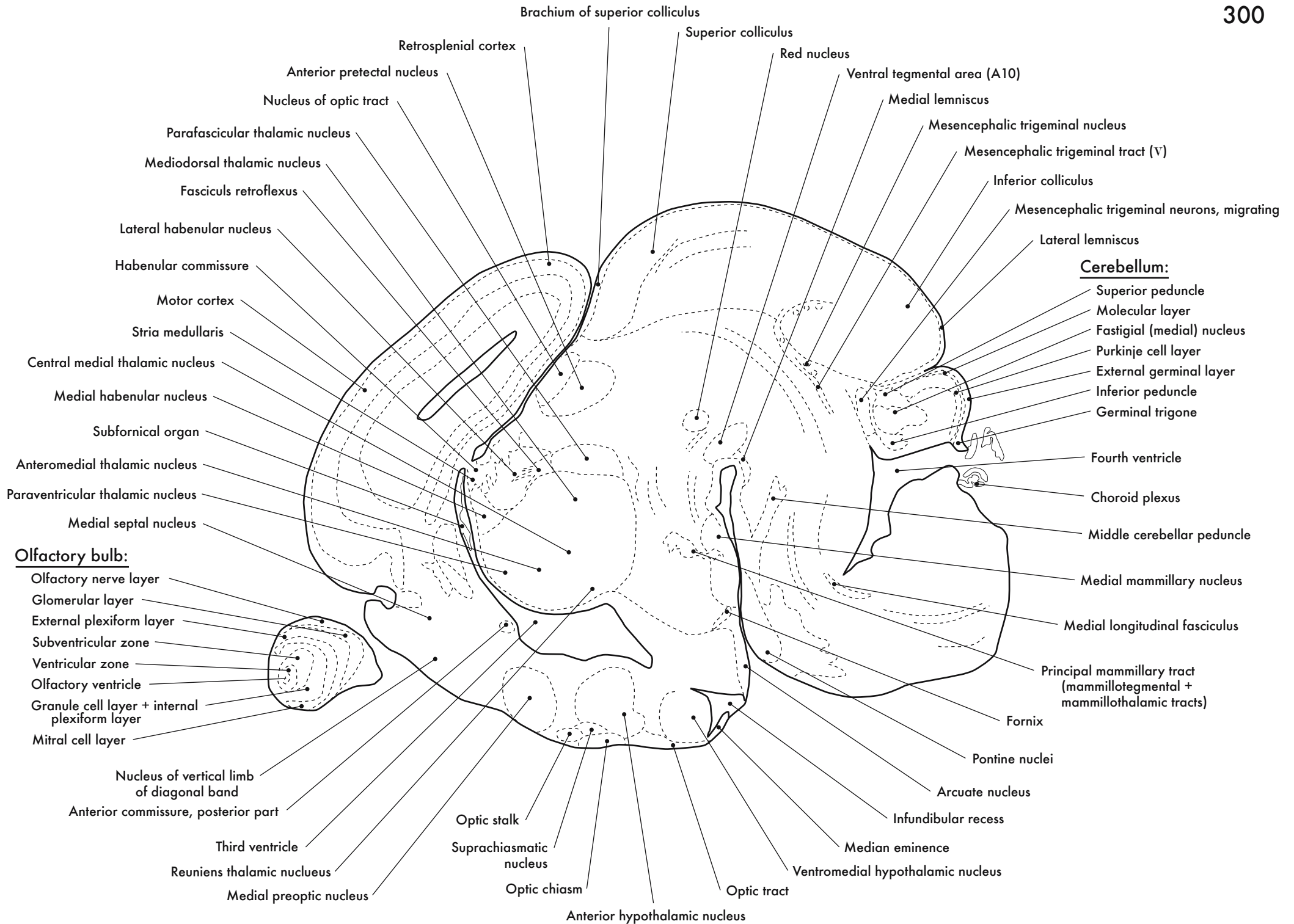


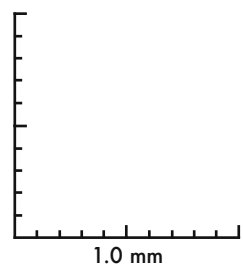
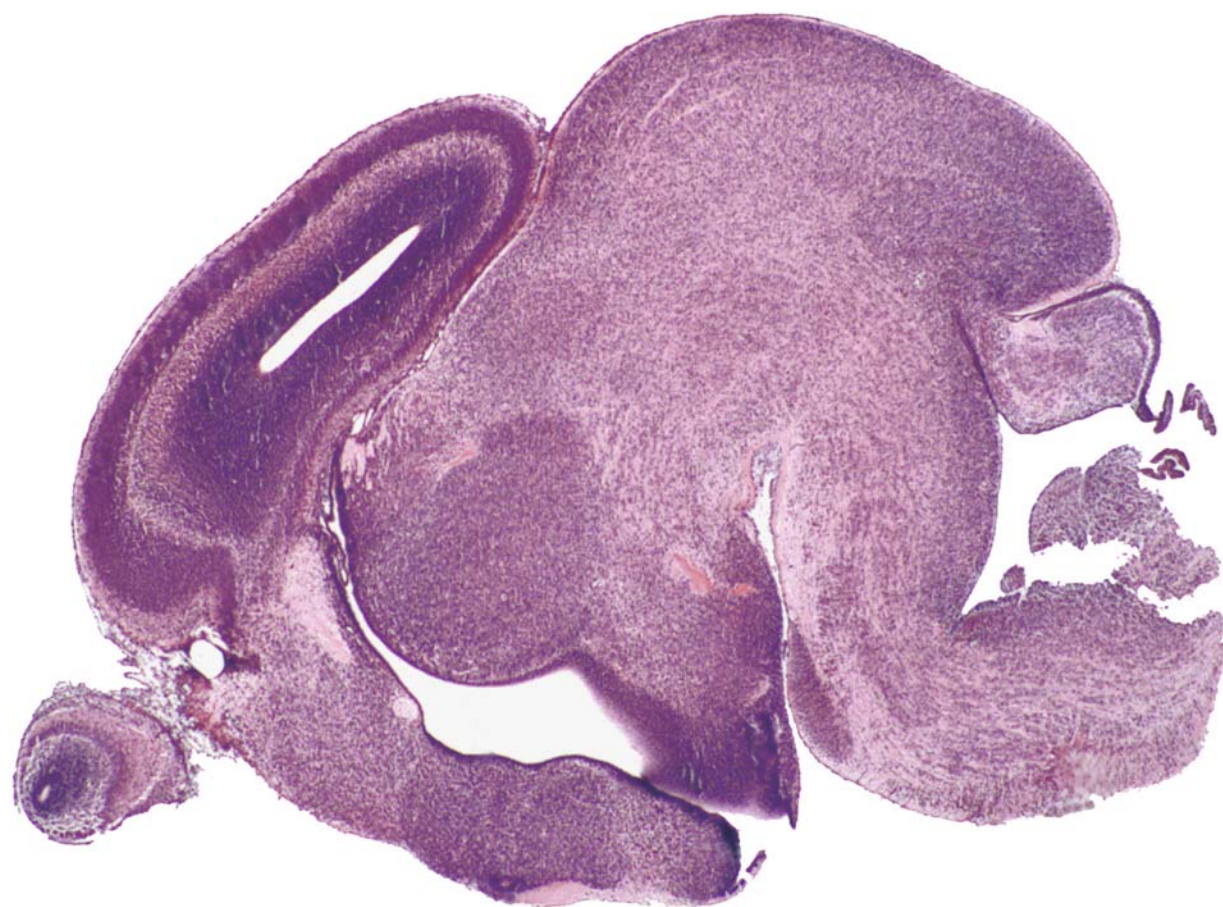
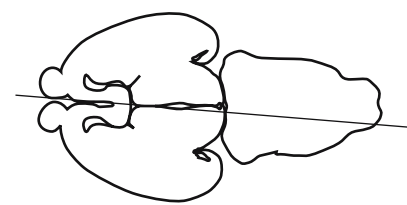




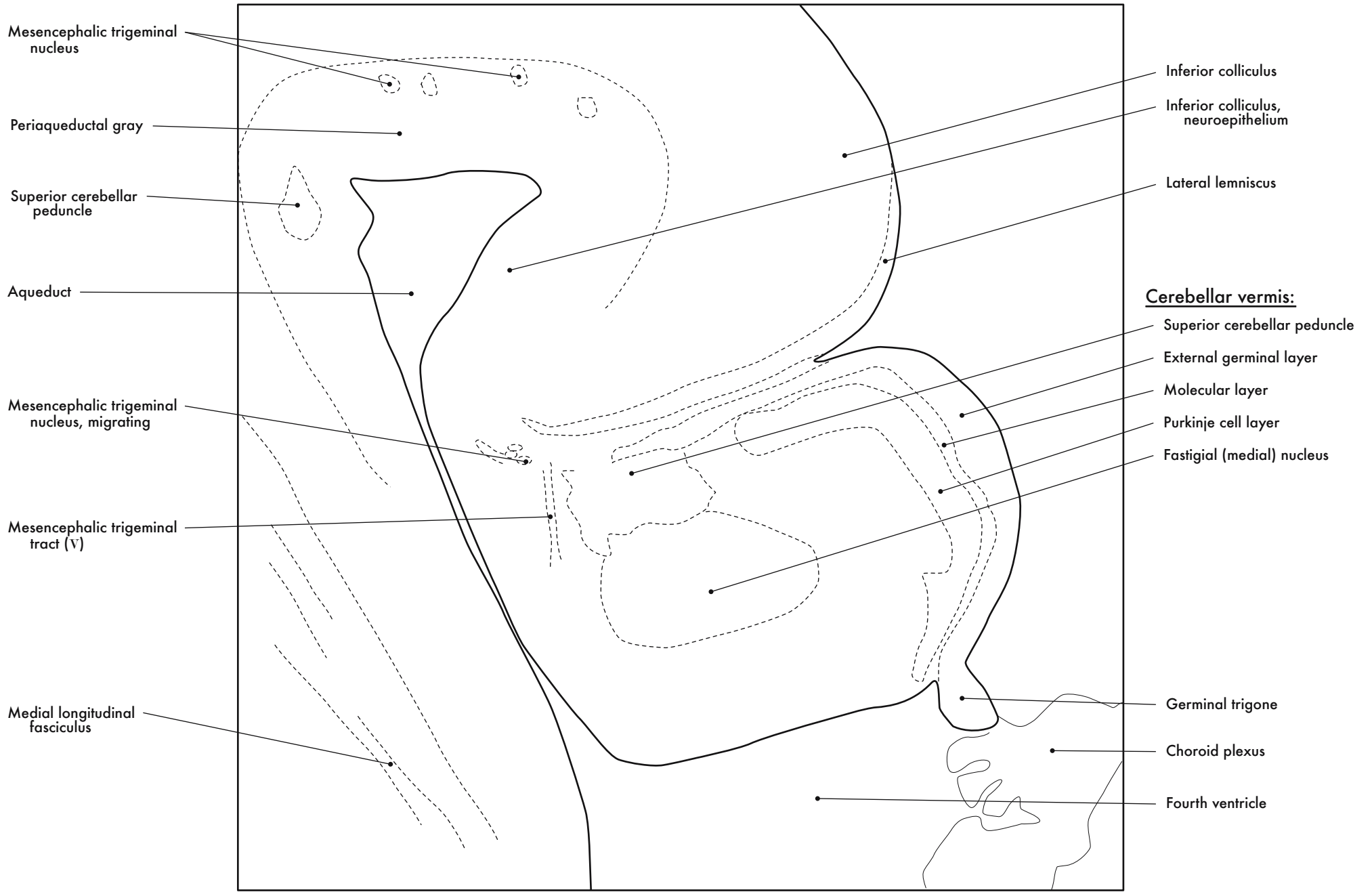
GD 16 SAGITTAL 10





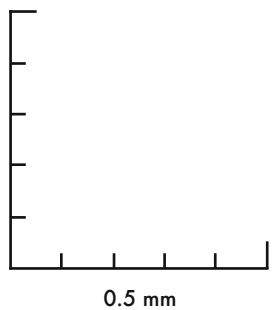
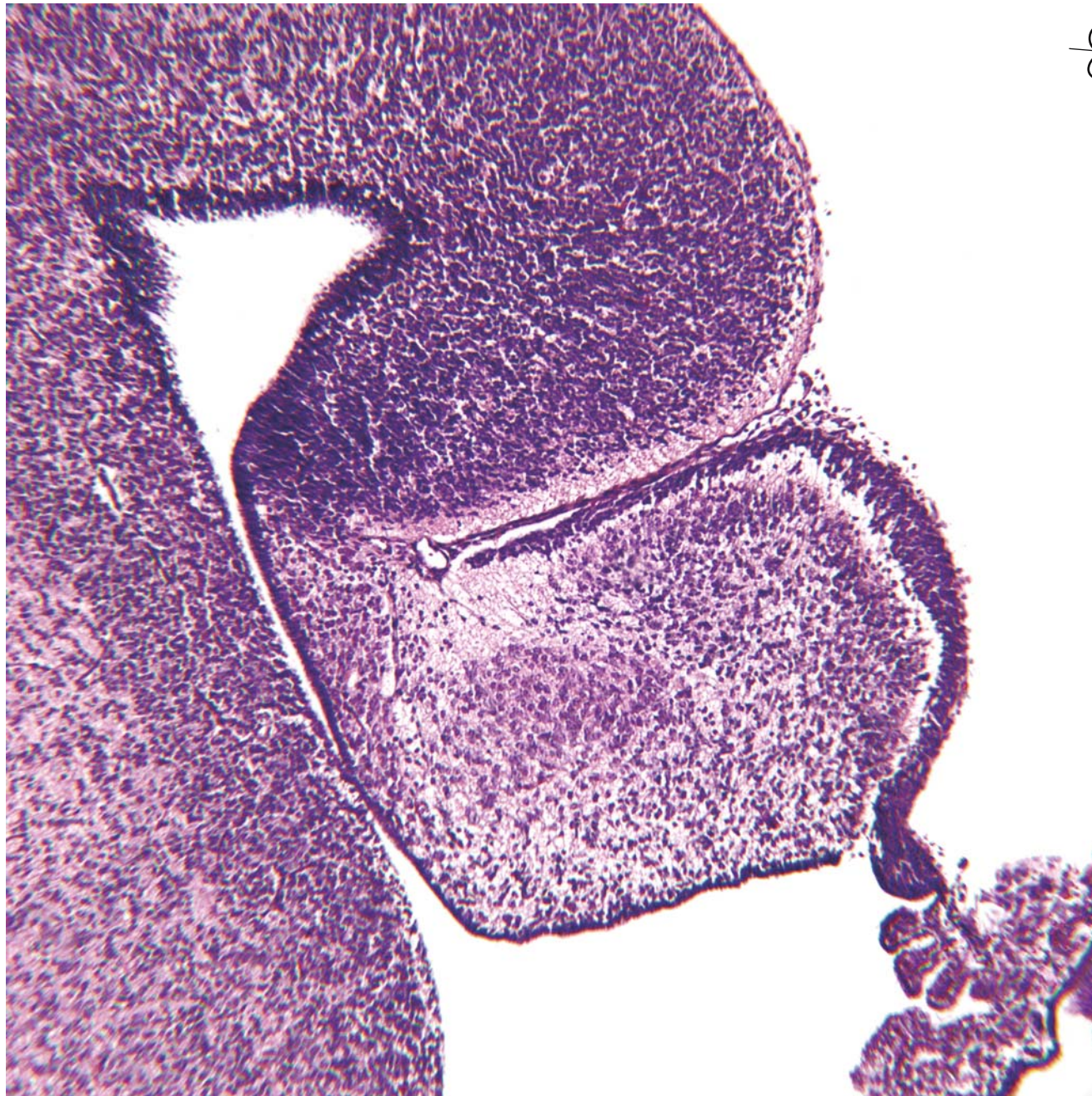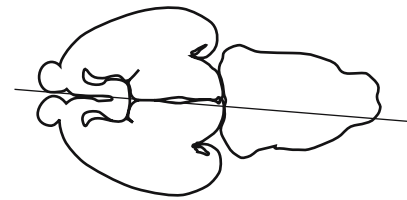
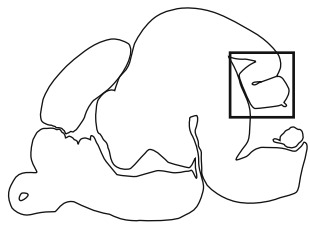


GD 16 SAGITTAL 11



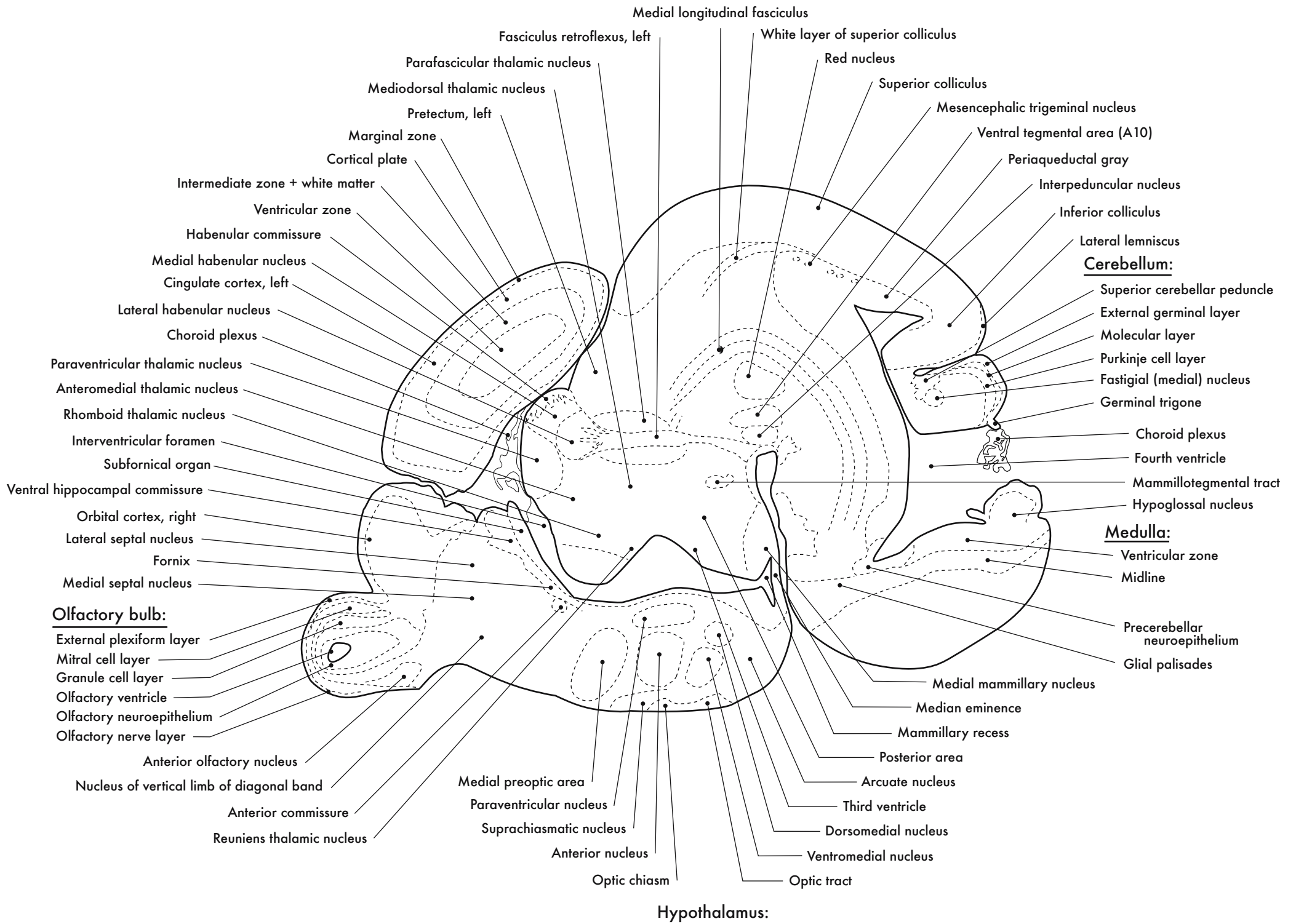
Cerebellum

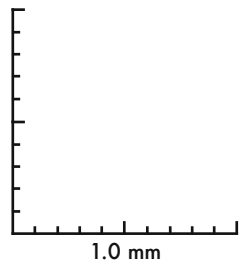
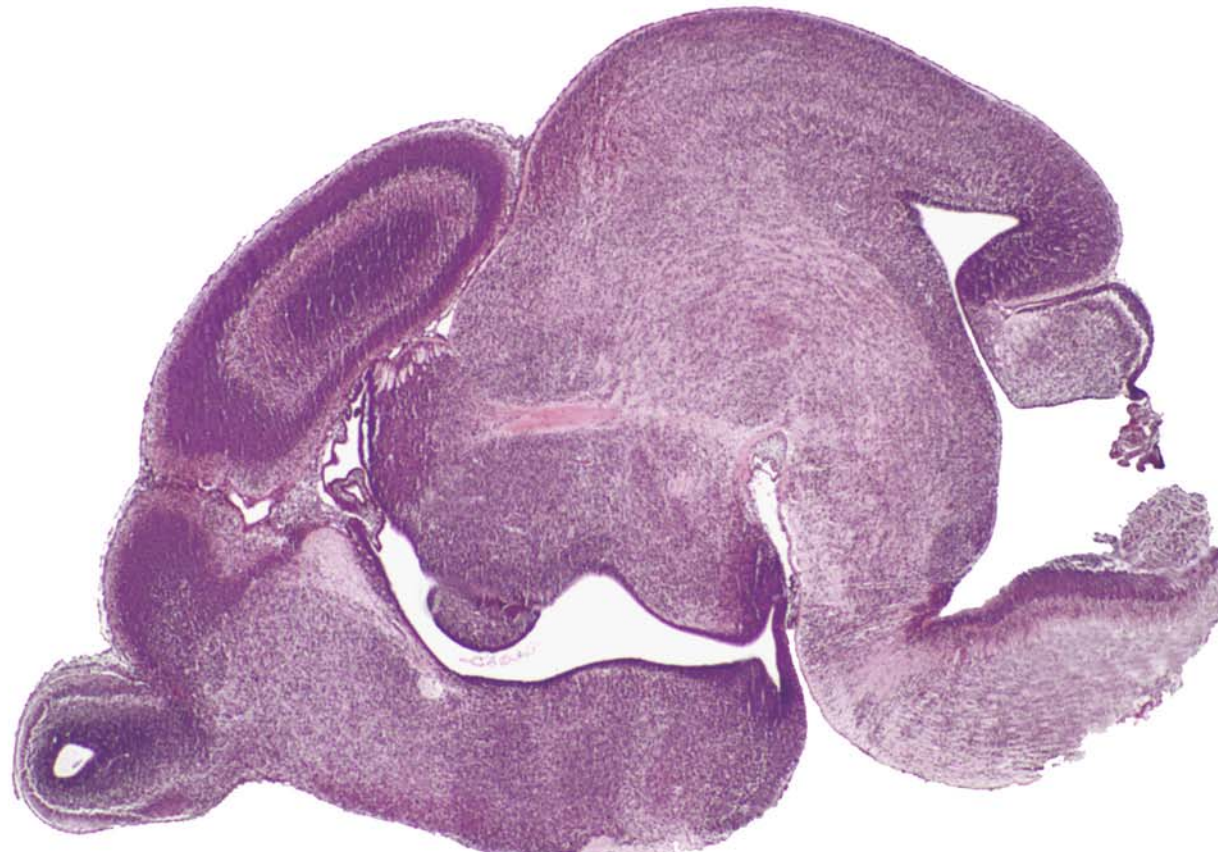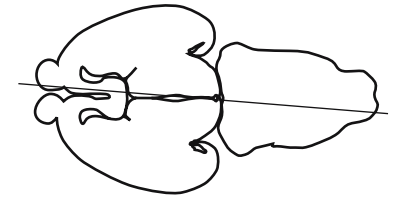




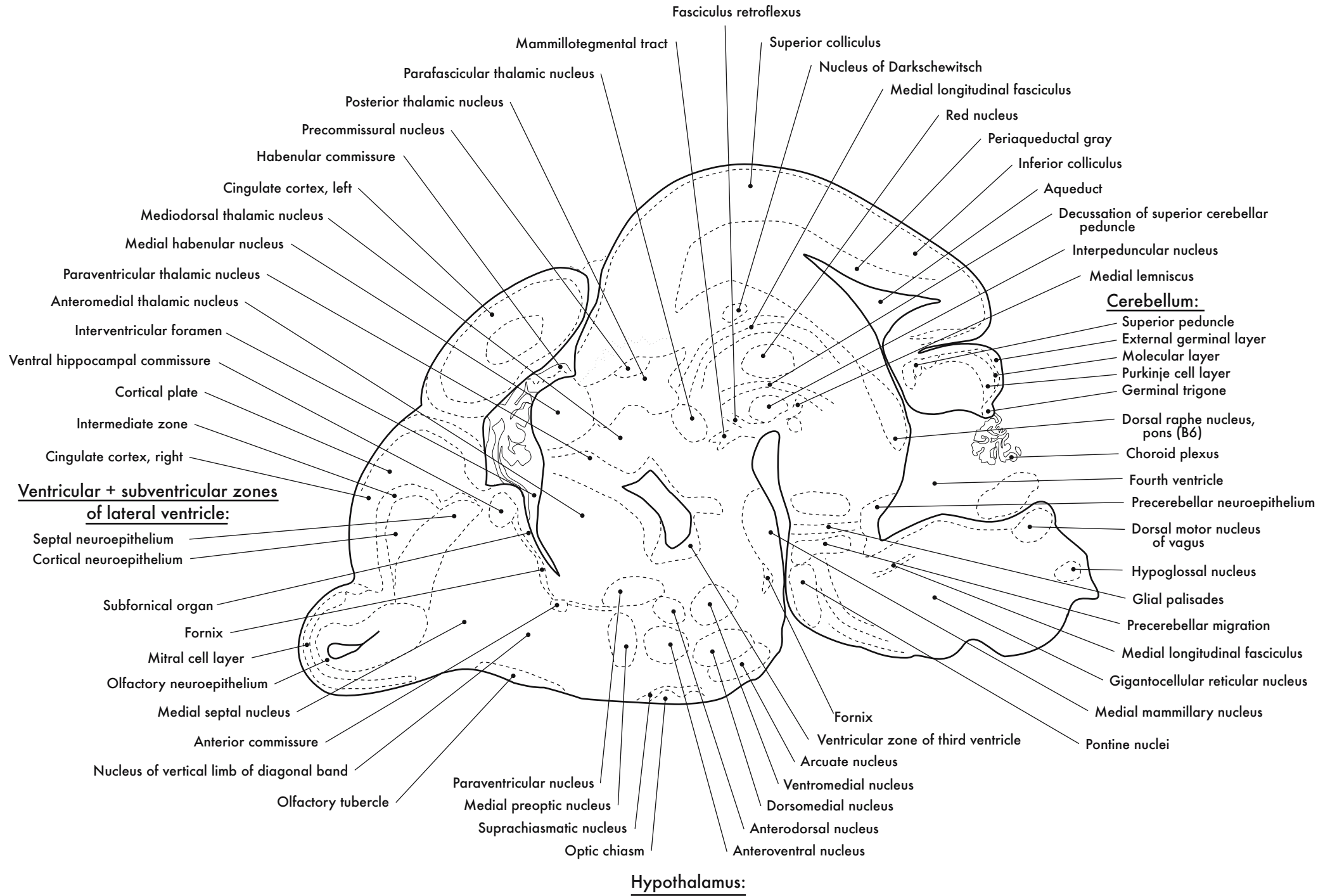
GD 16 SAGITTAL 12

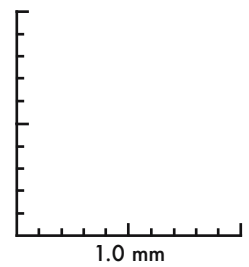
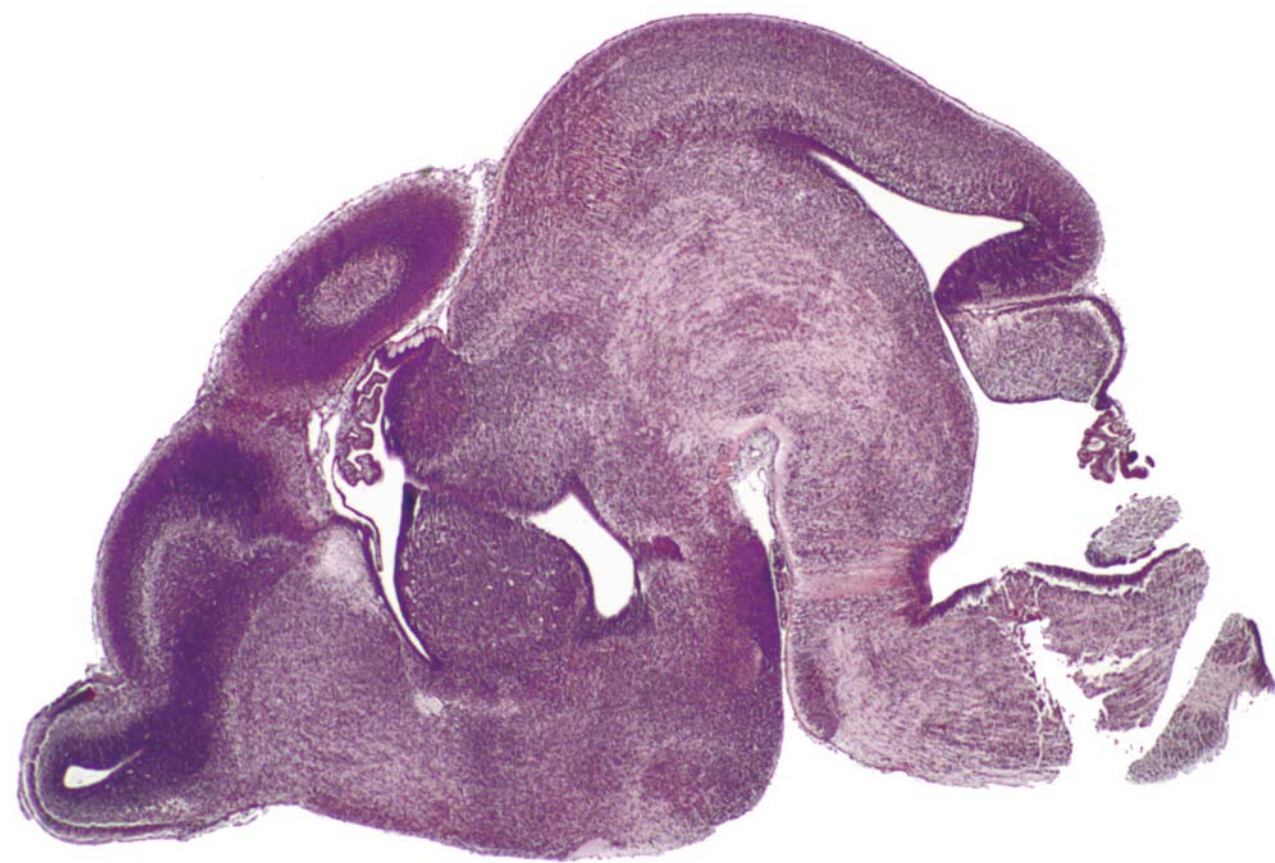
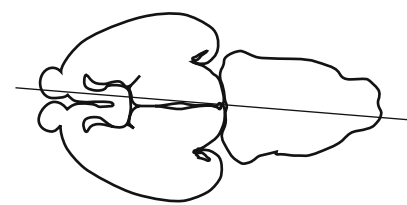






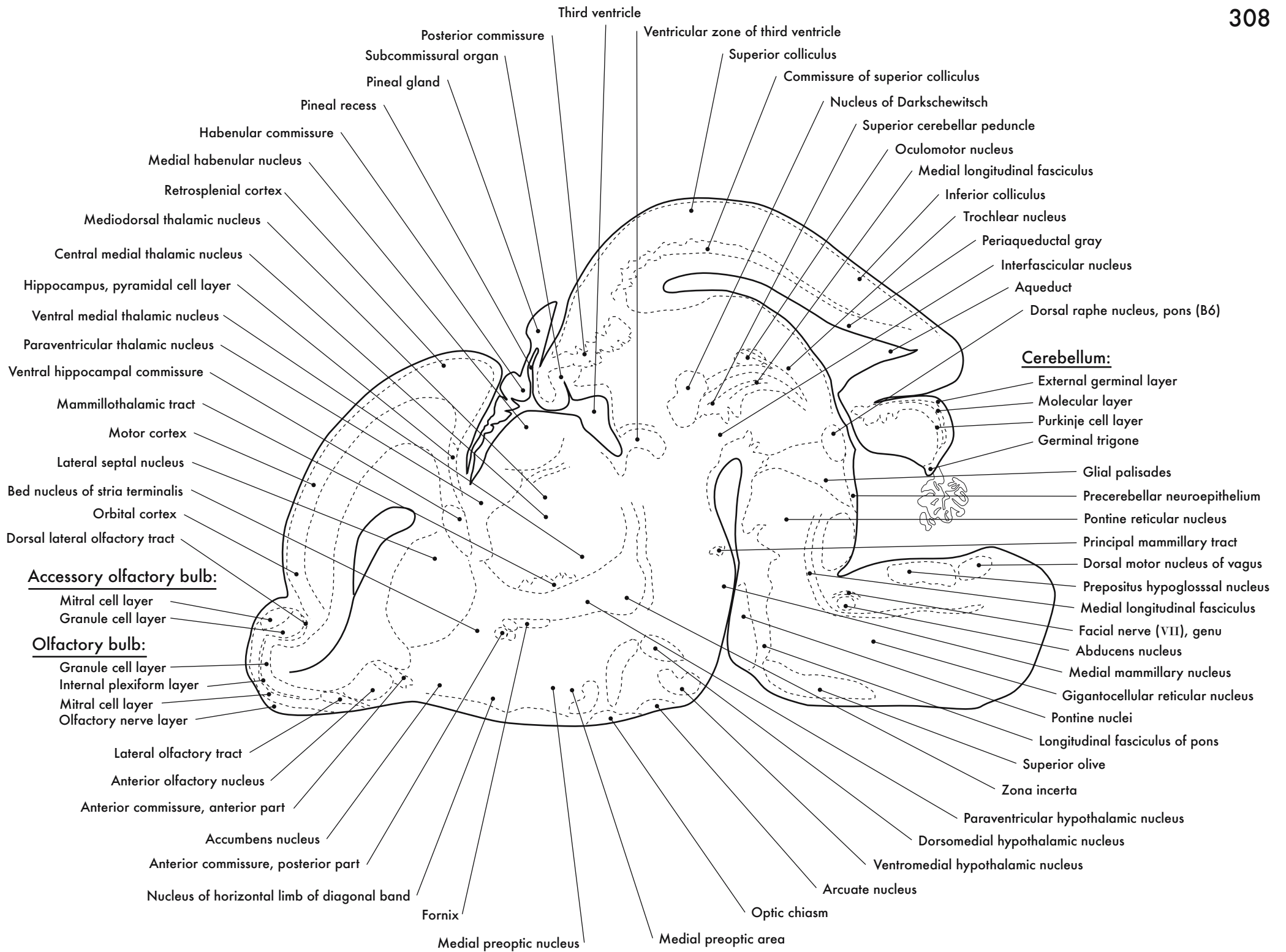
GD 16 SAGITTAL 13

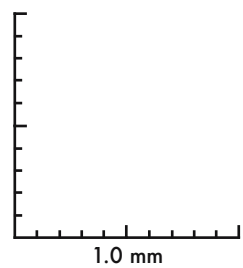
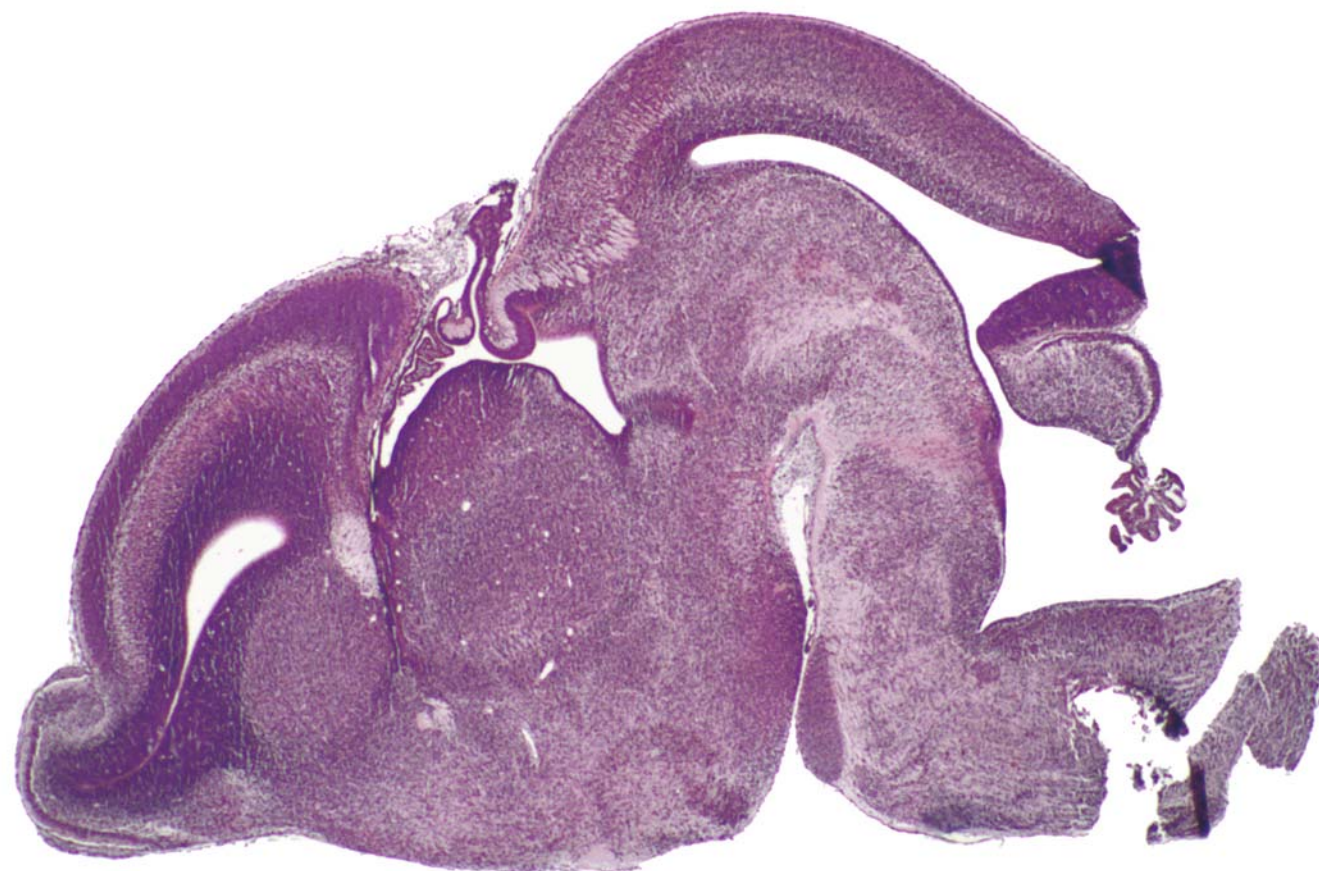
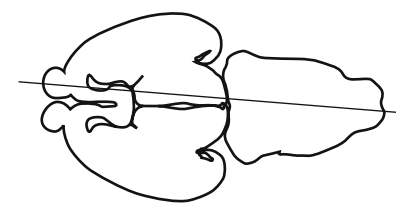




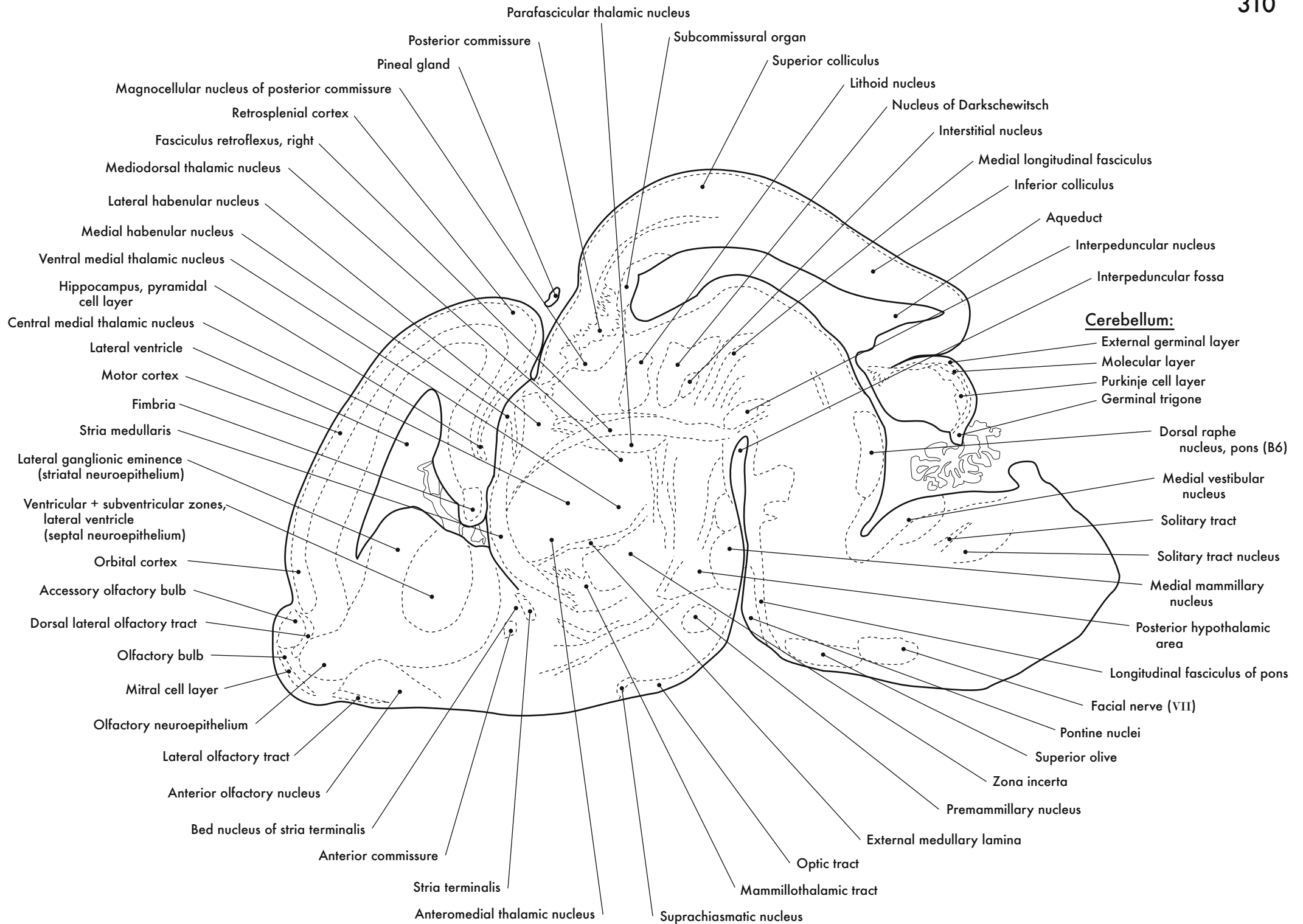
GD 16 SAGITTAL 14



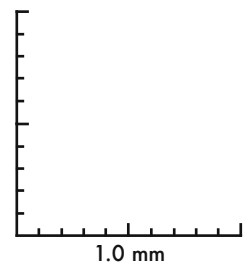
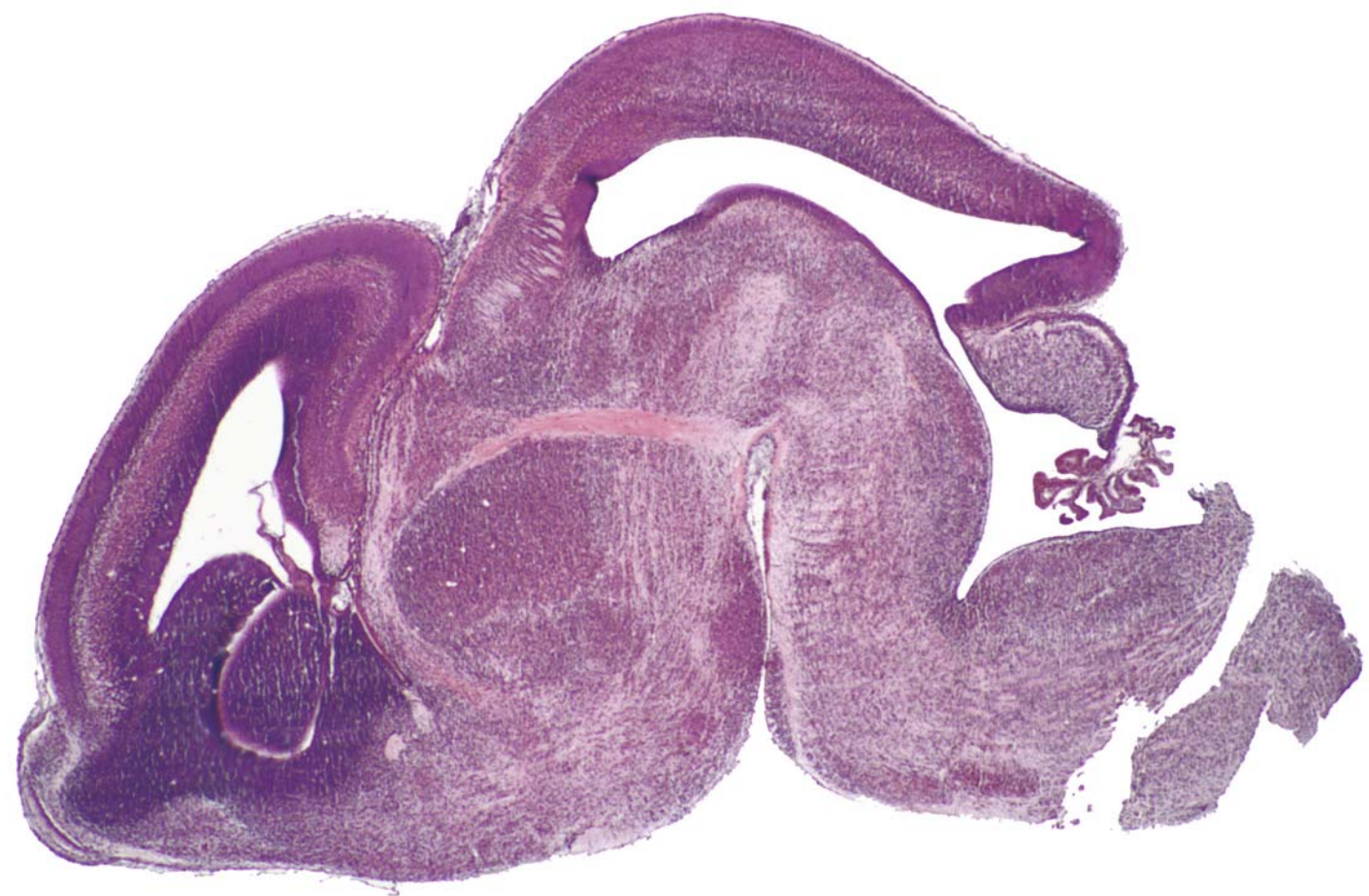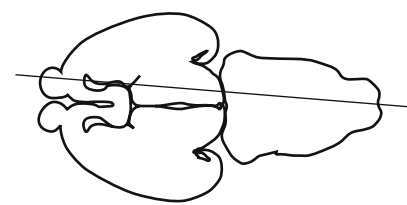




GD 16 SAGITTAL 15



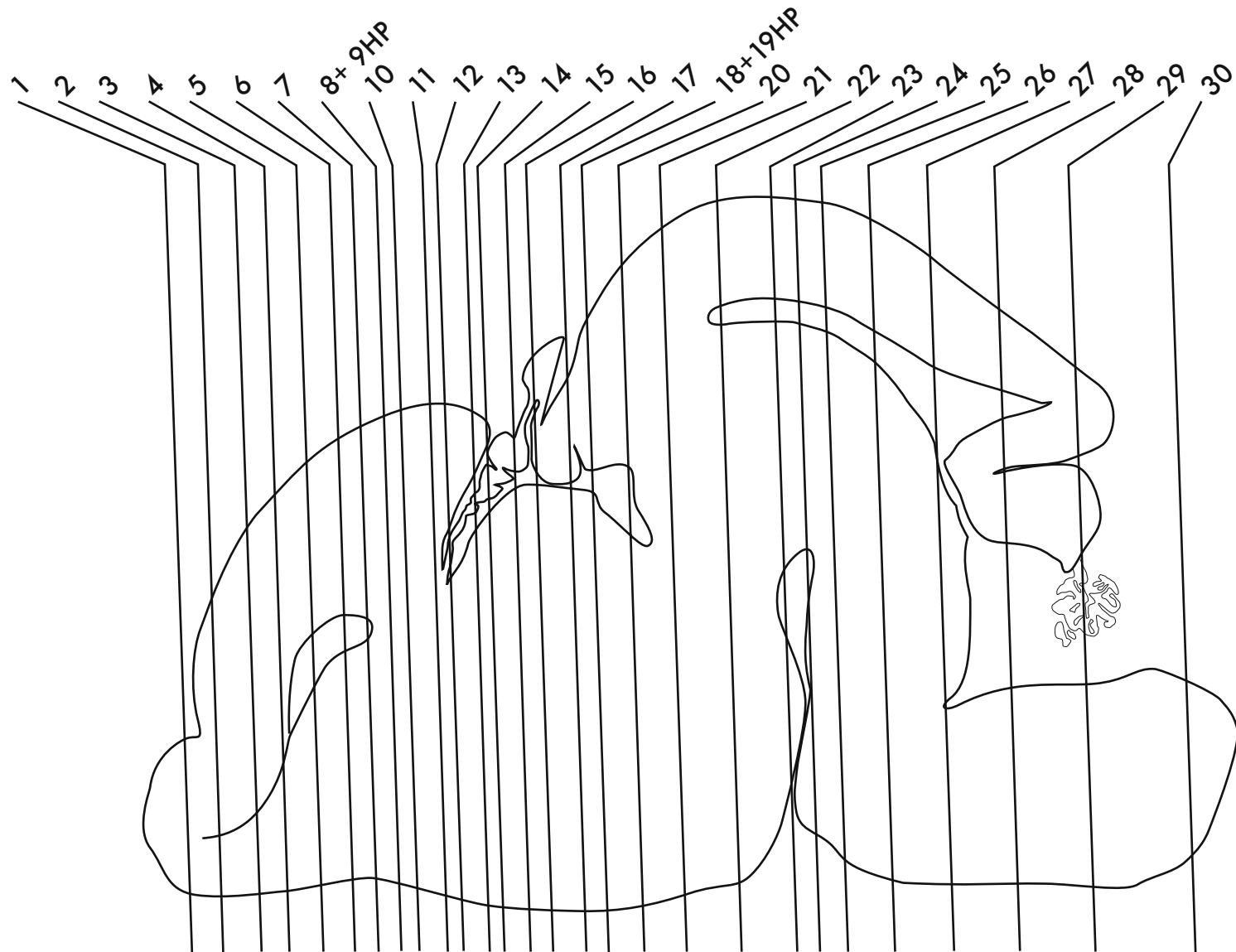




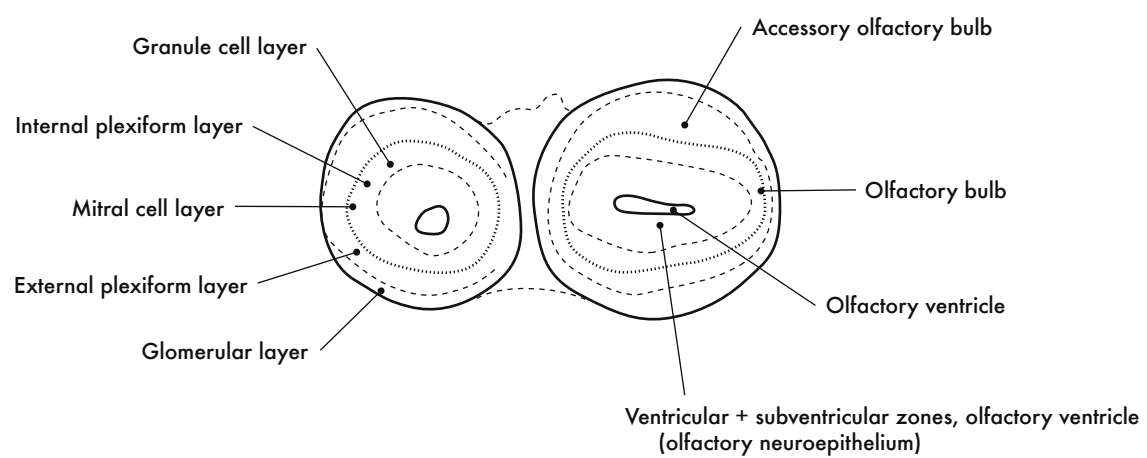
GD 16 SAGITTAL 16

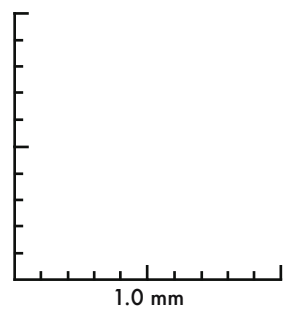
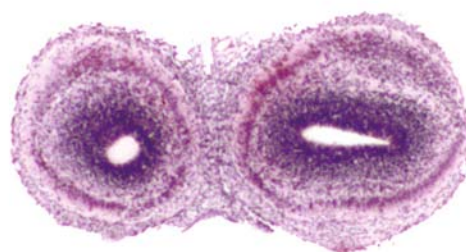
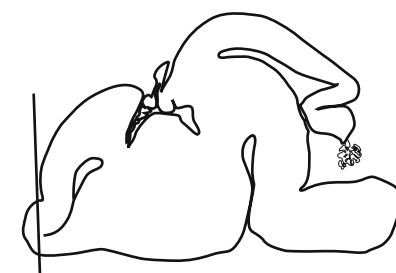

HP denotes image enlargement

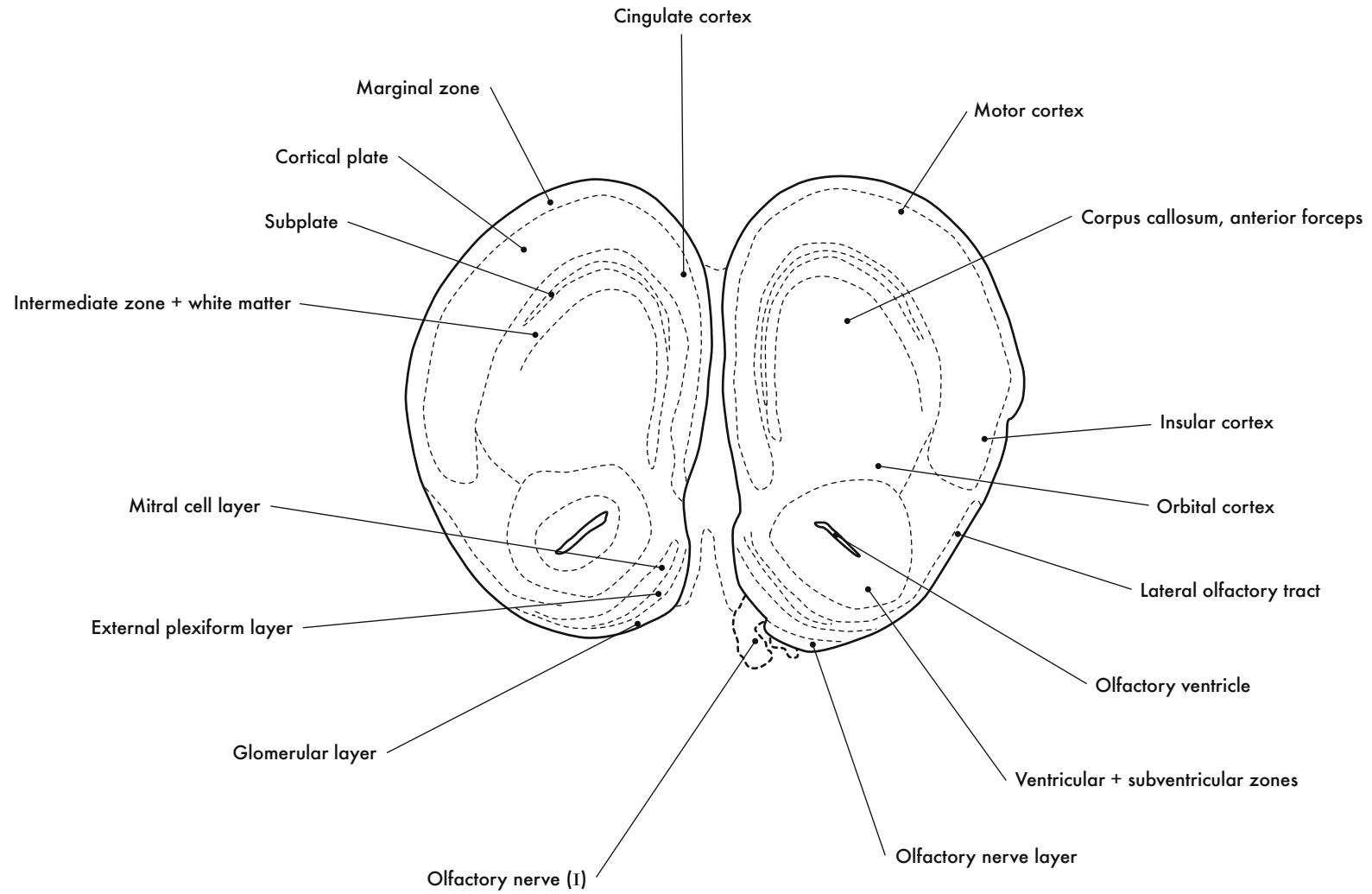


**GESTATIONAL DAY 16 (GD 16)  
CORONAL SECTIONS**

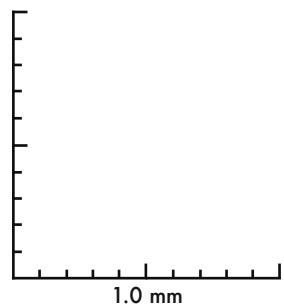
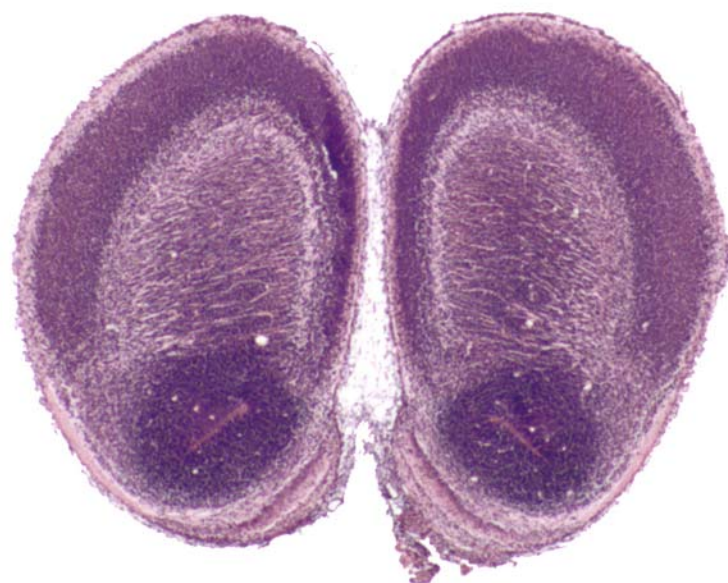
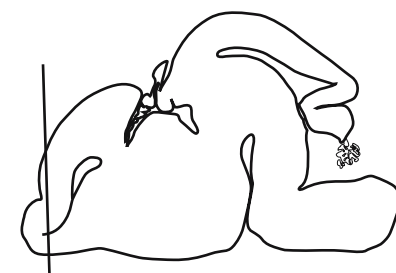


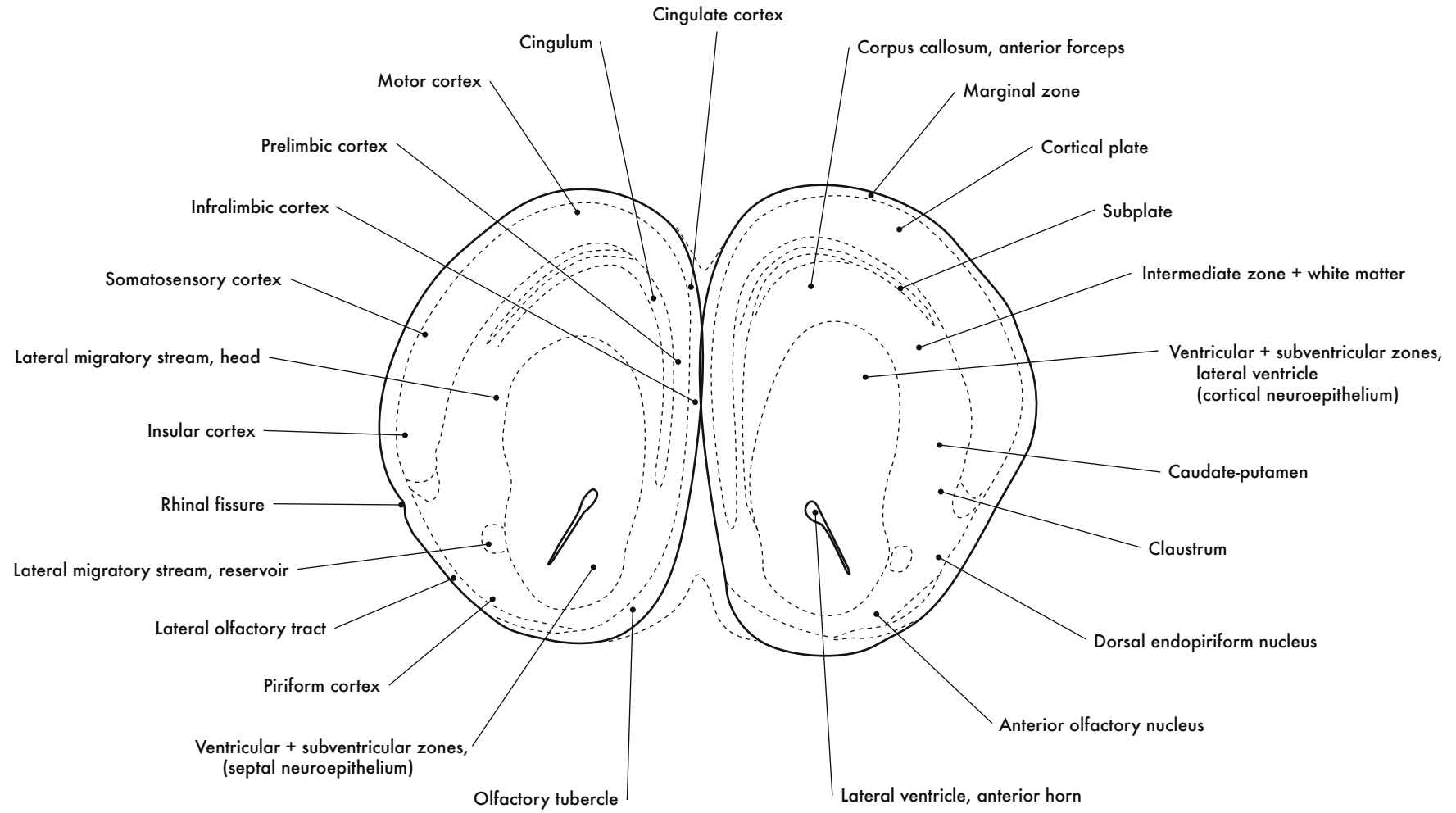
GD 16 CORONAL 1

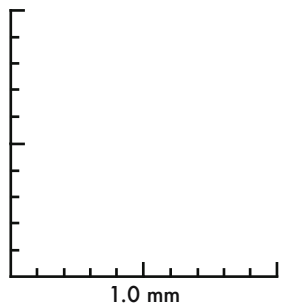
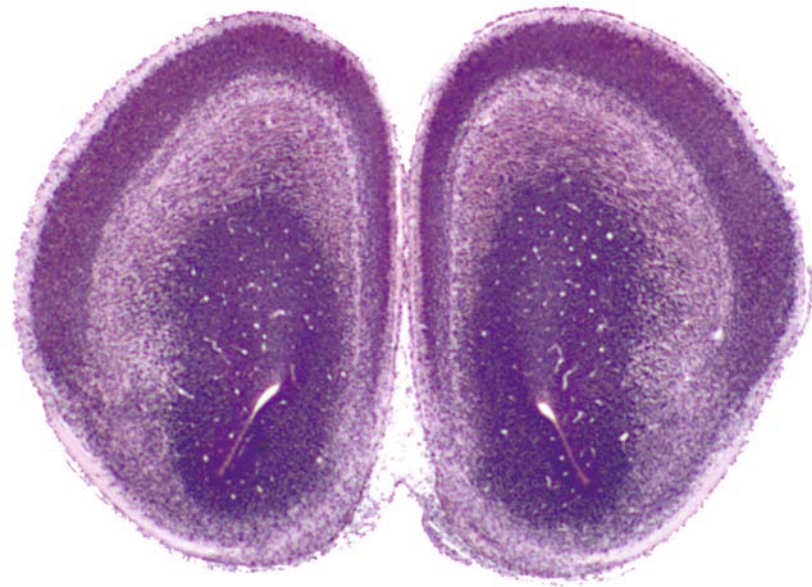
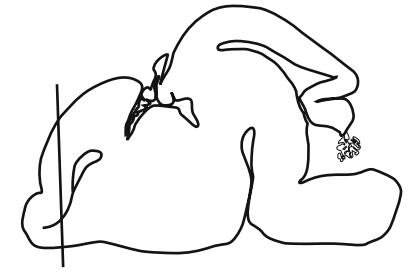



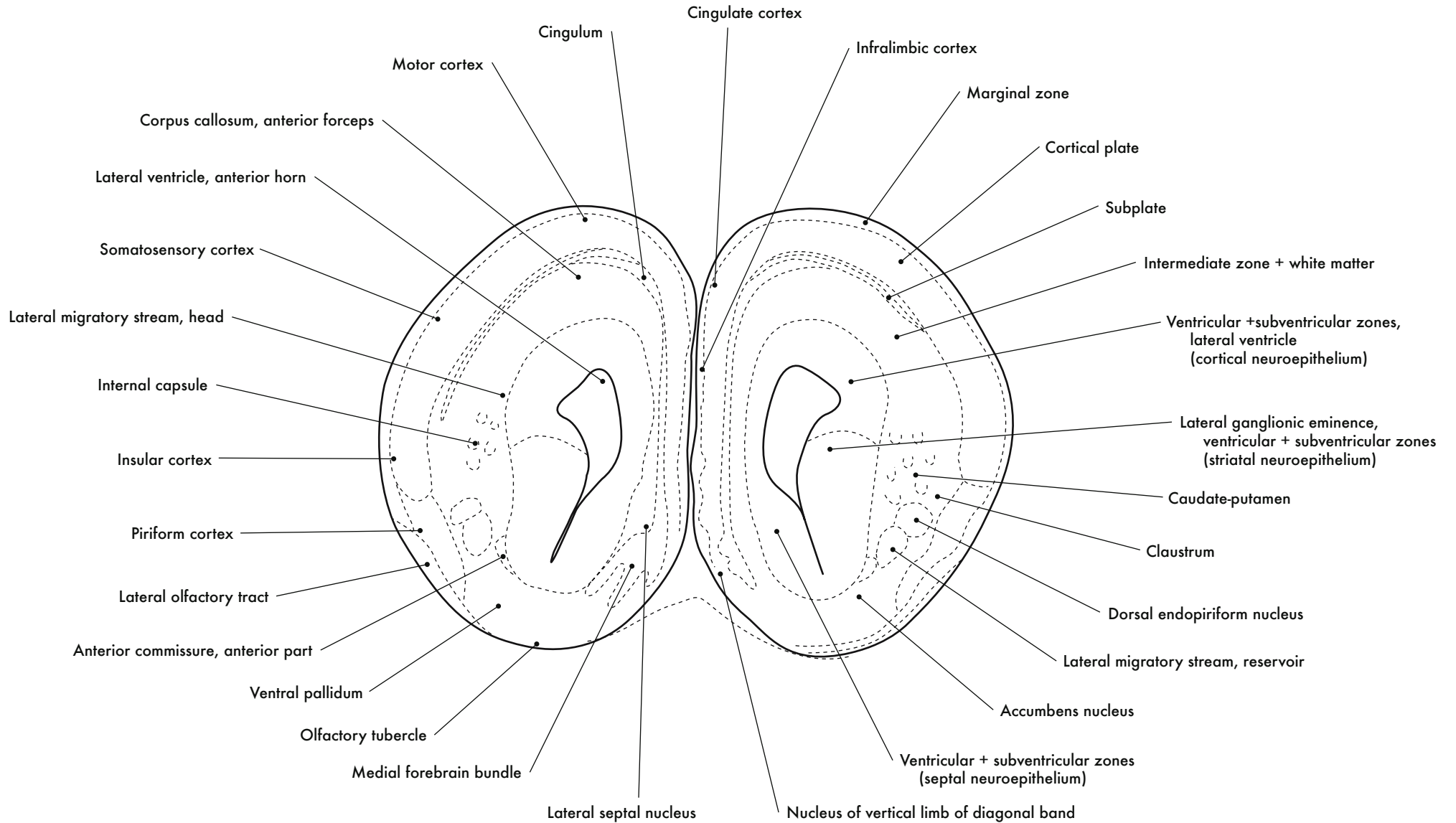


GD 16 CORONAL 2

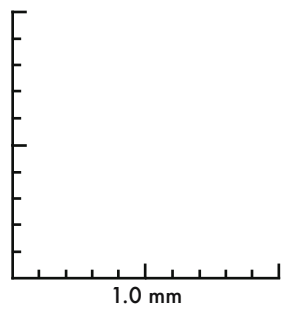
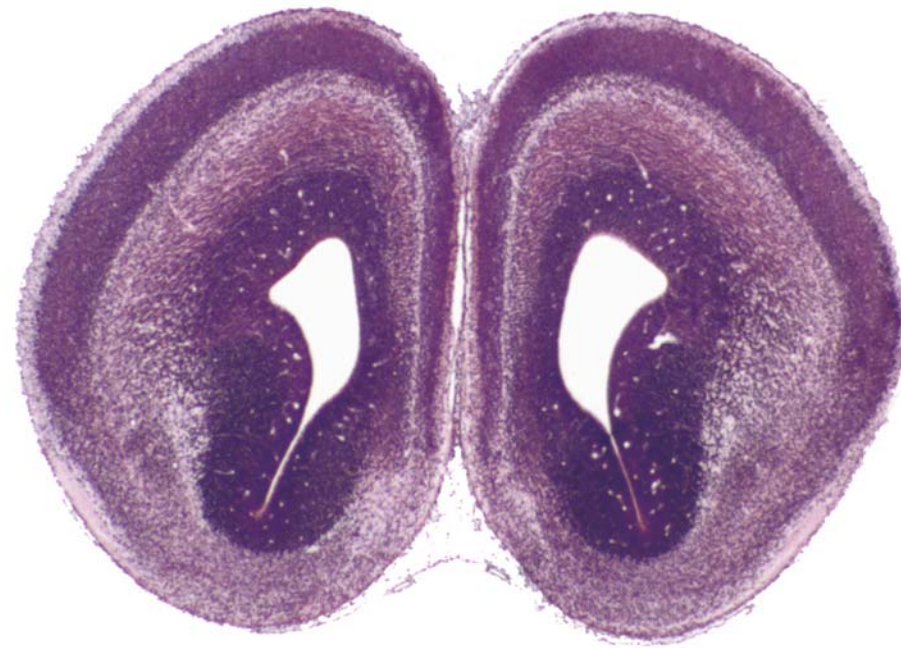
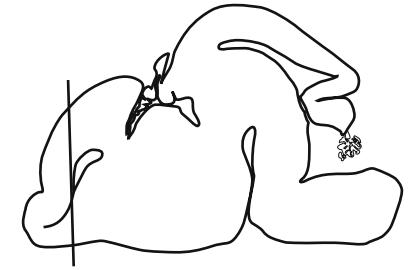



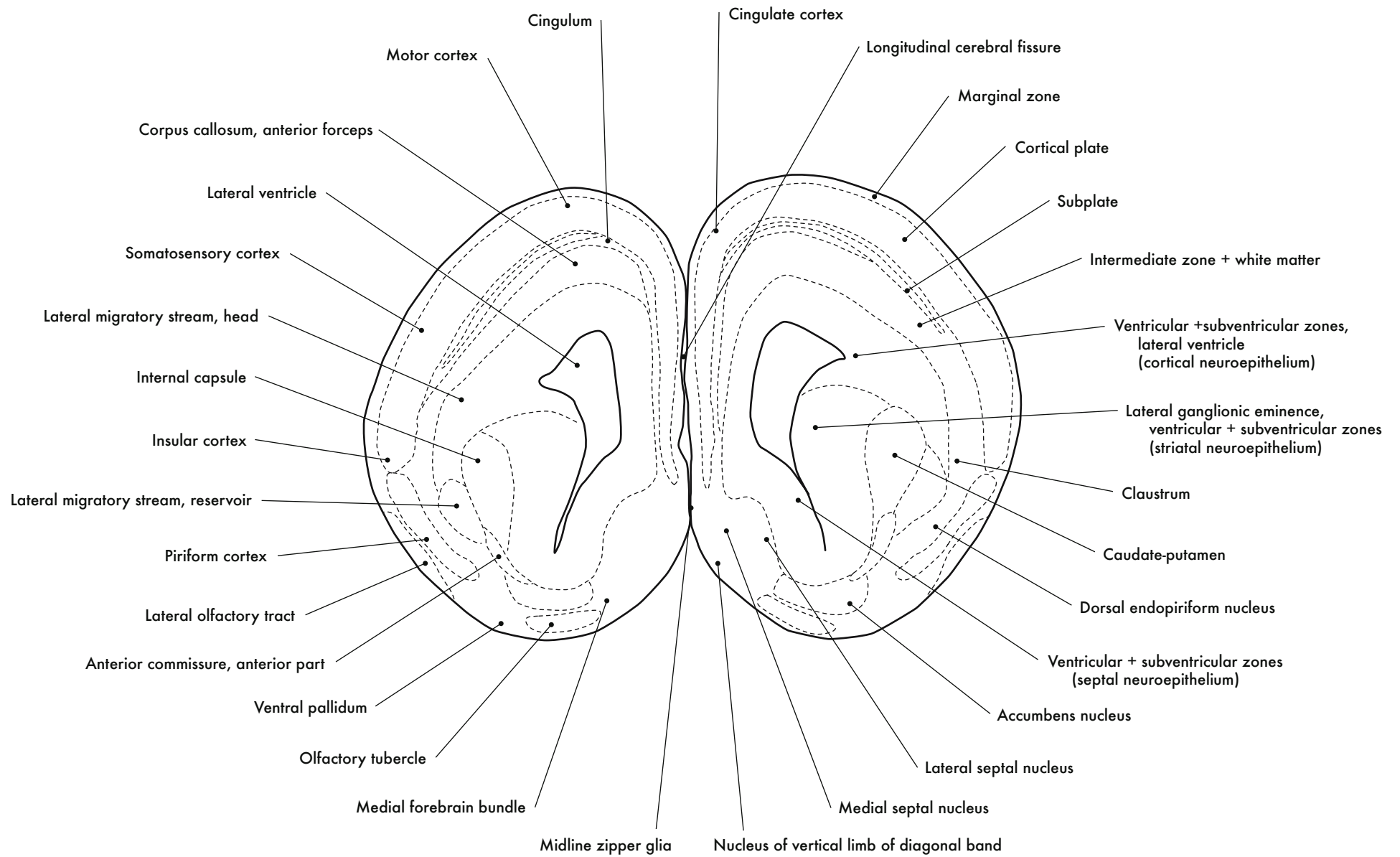
GD 16 CORONAL 3

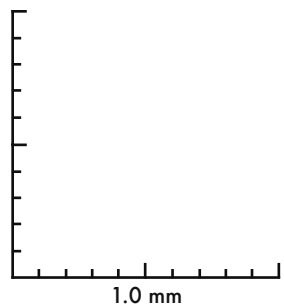
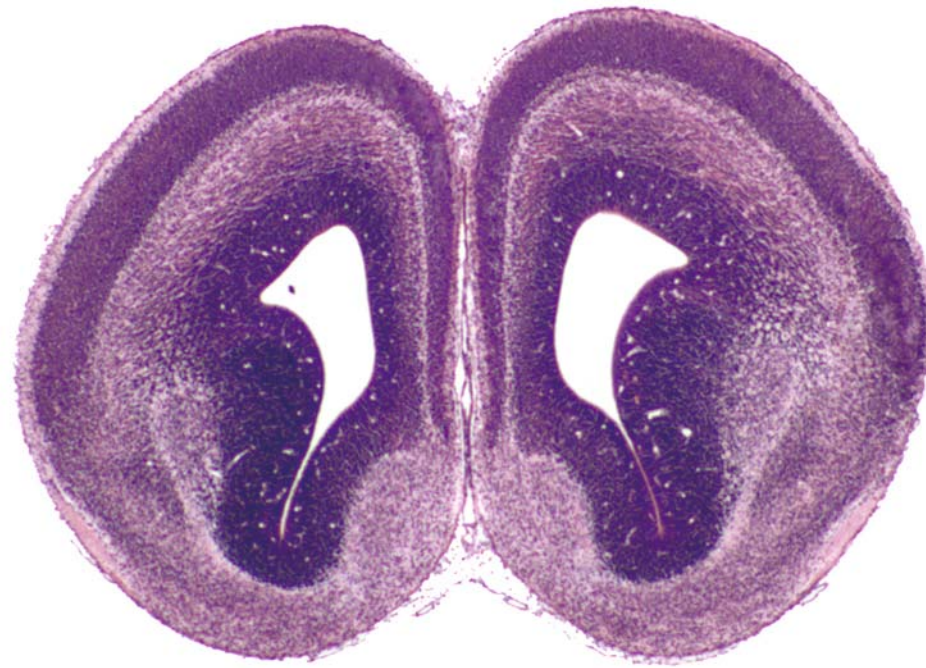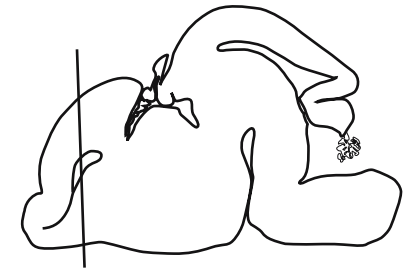




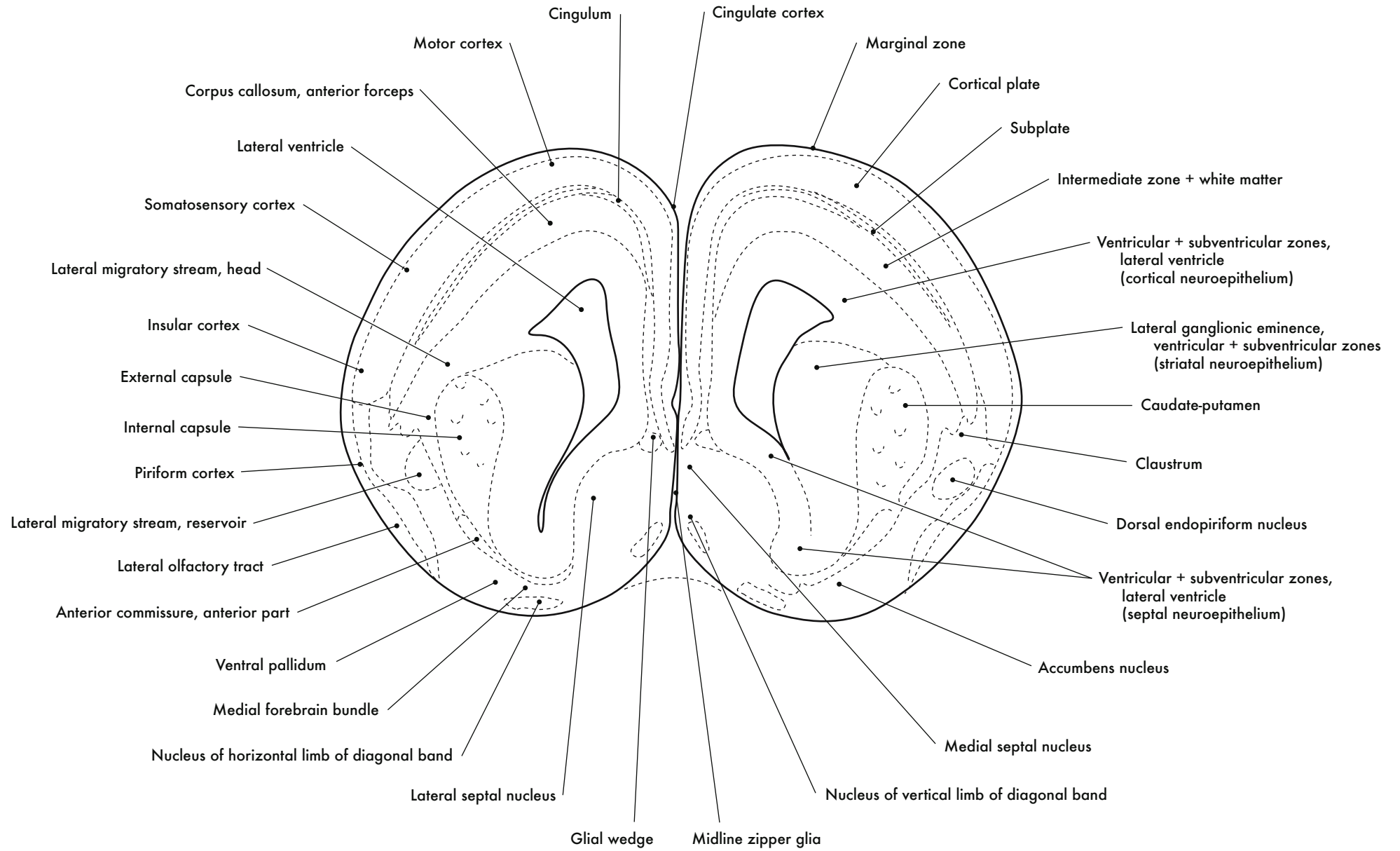


GD 16 CORONAL 4

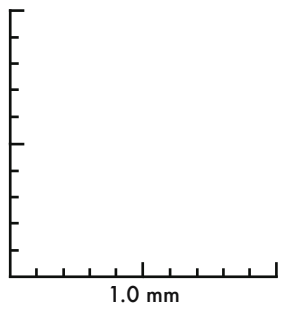
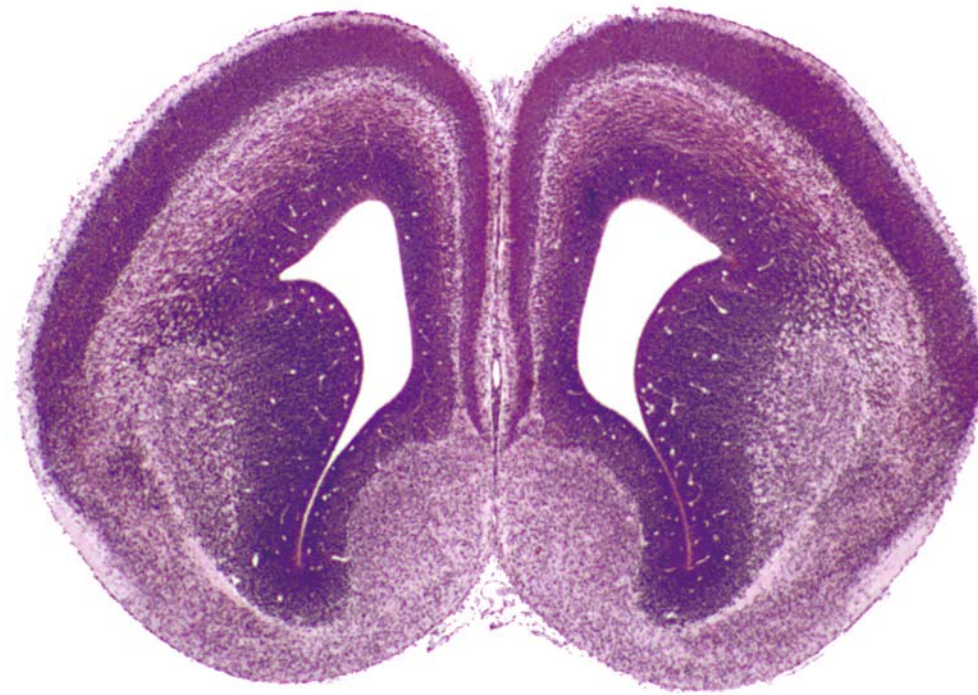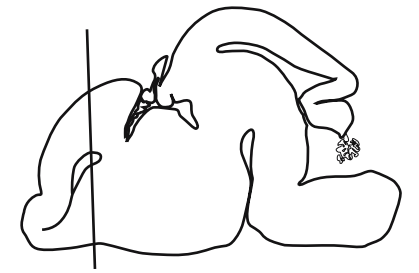




GD 16 CORONAL 5

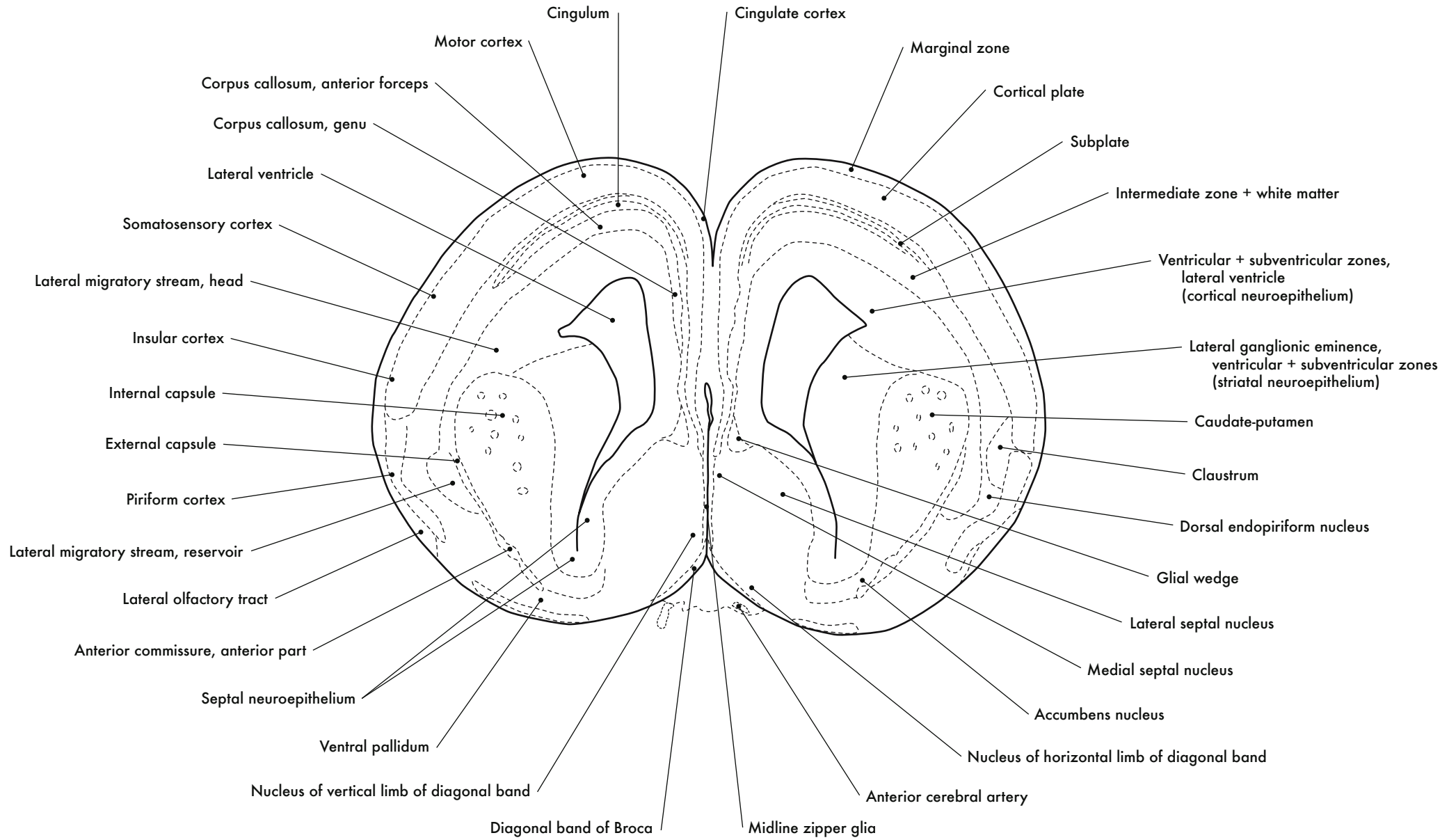


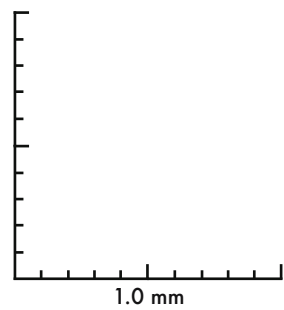
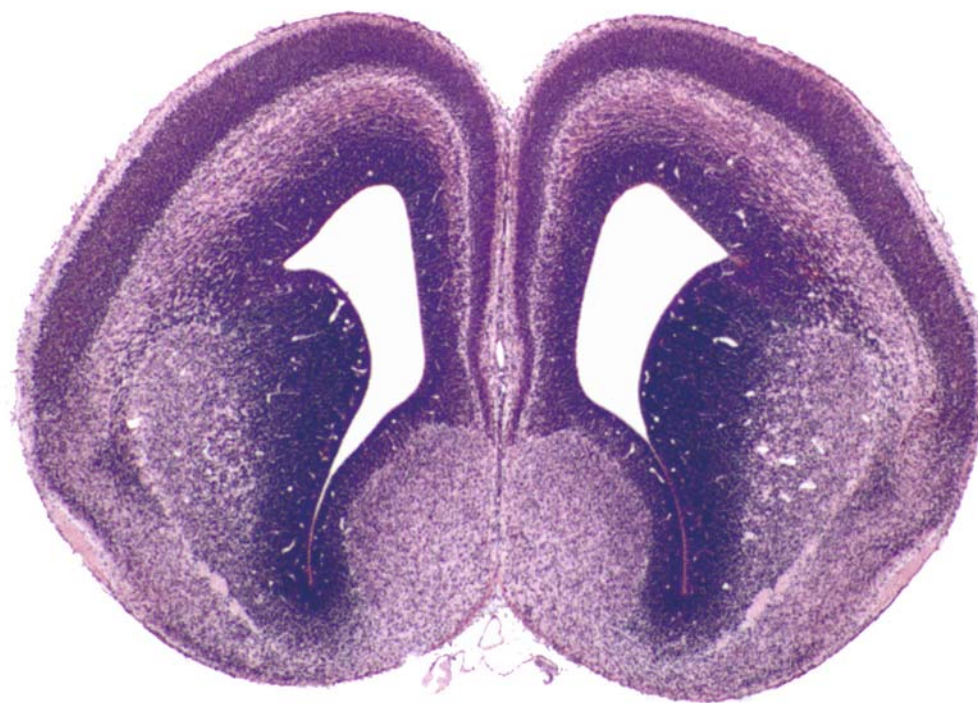



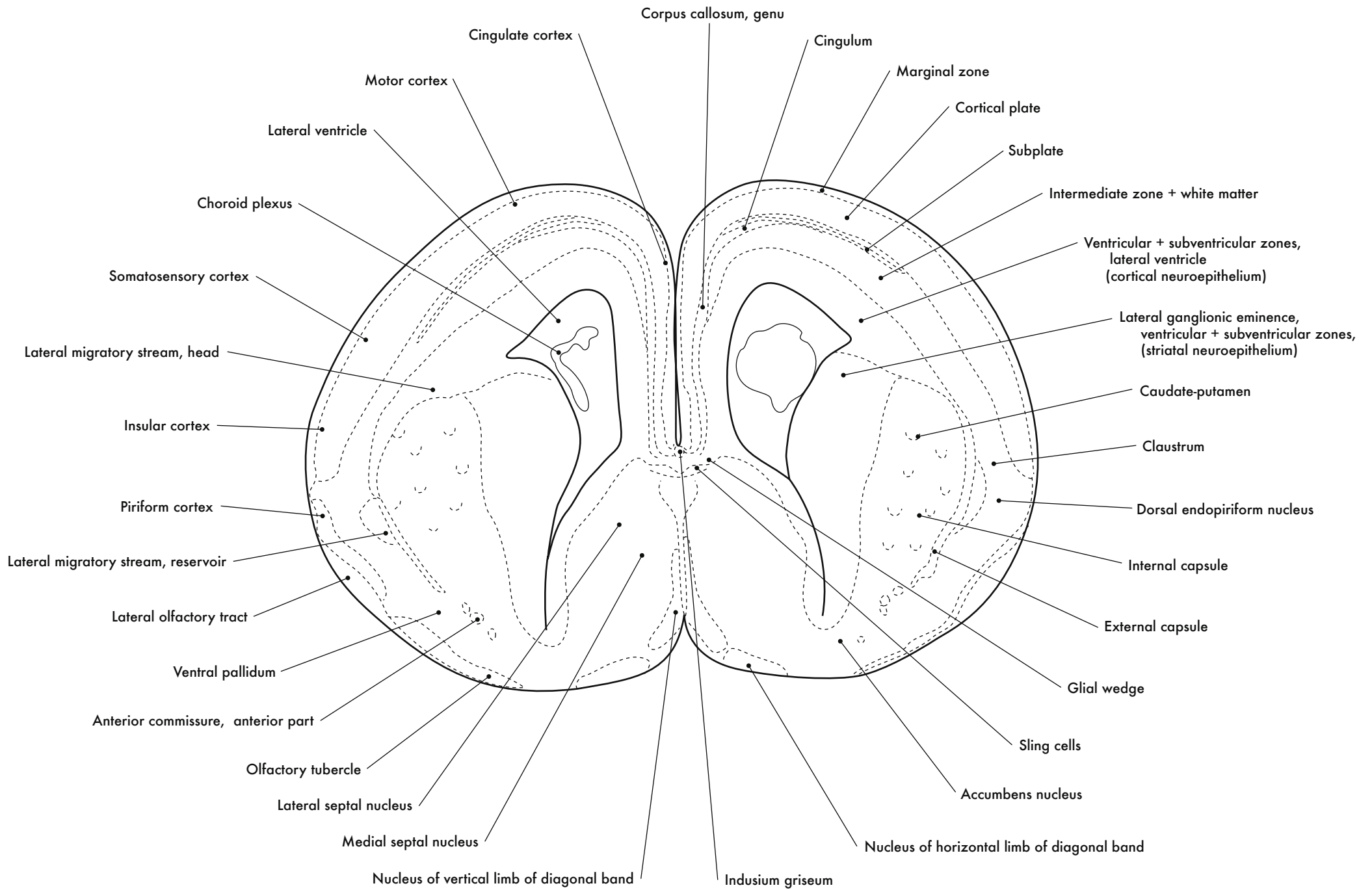
GD 16 CORONAL 6

325

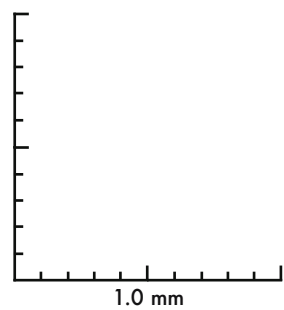
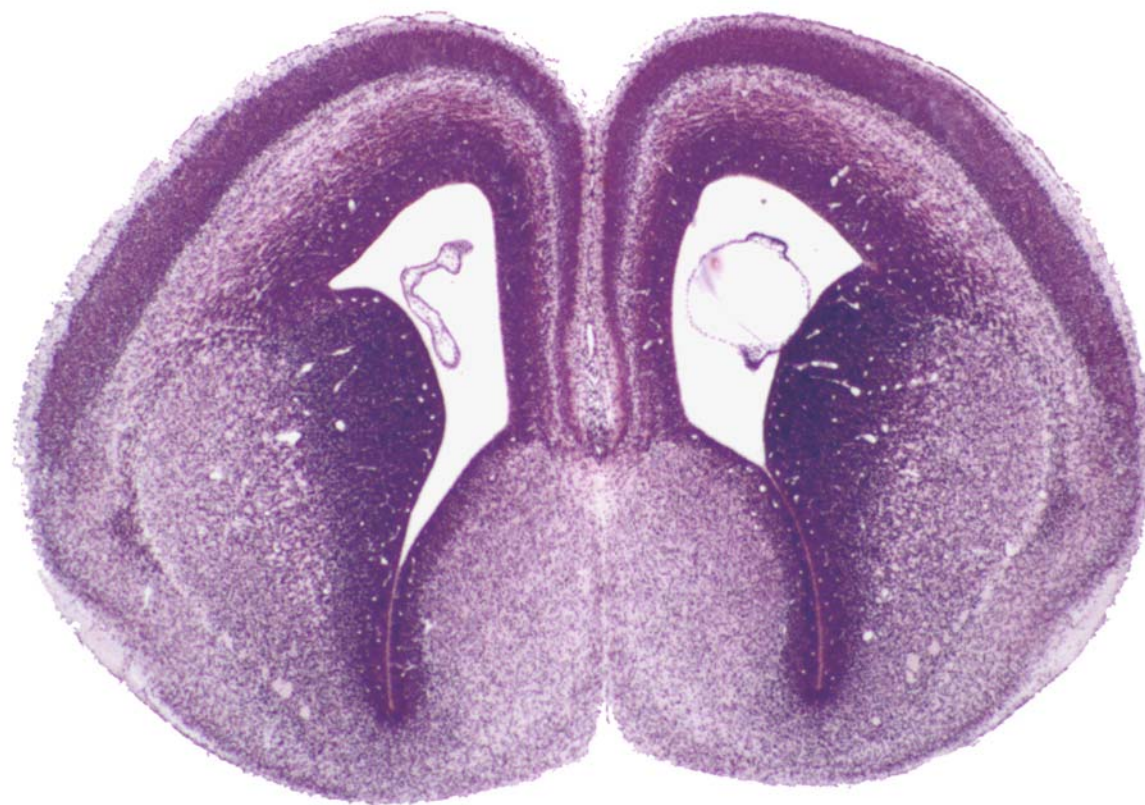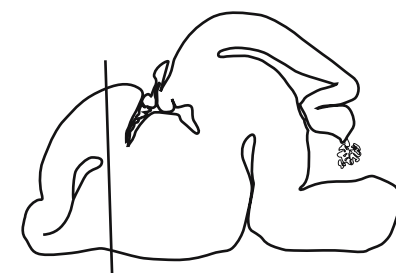




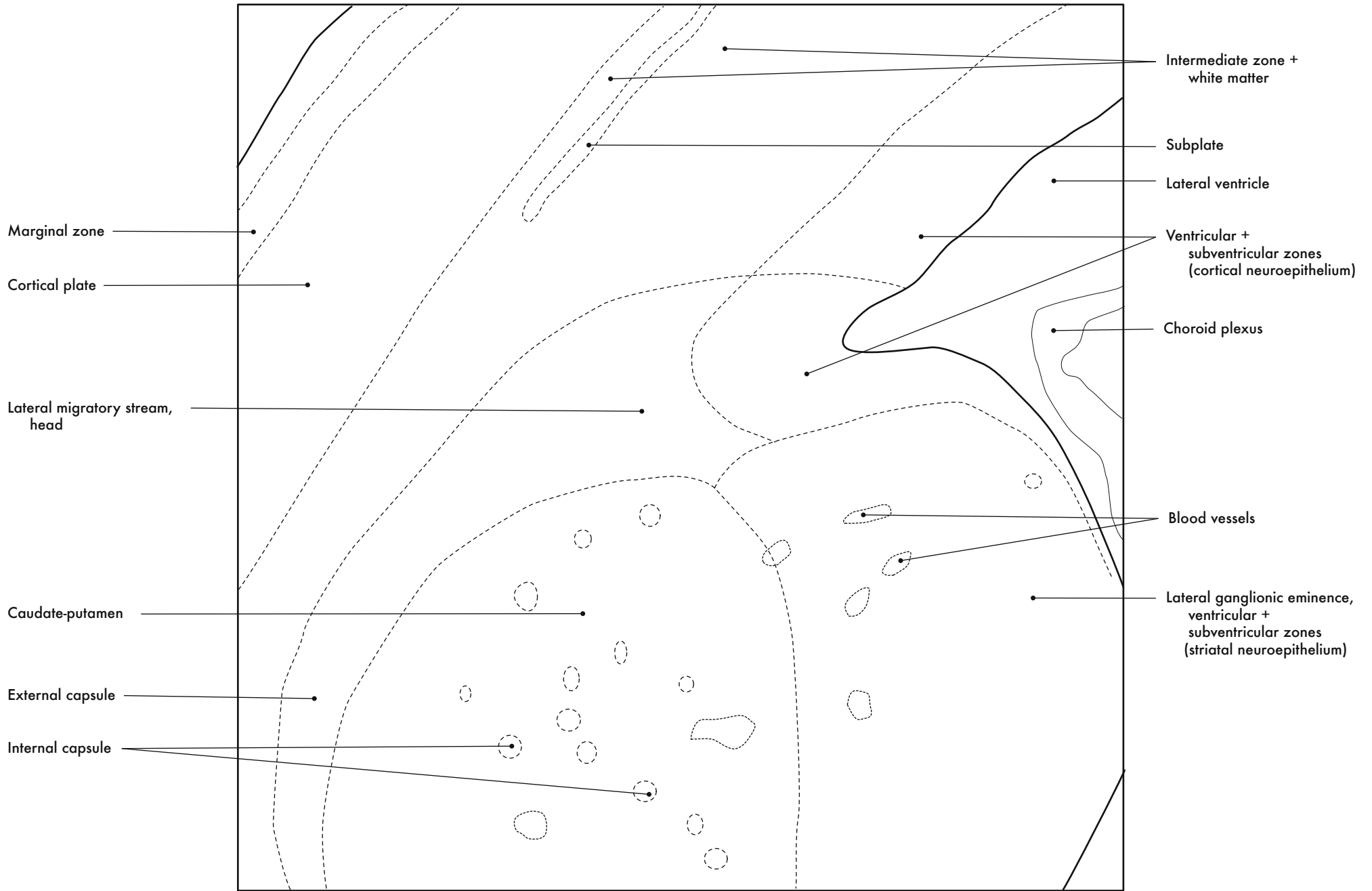
GD 16 CORONAL 7





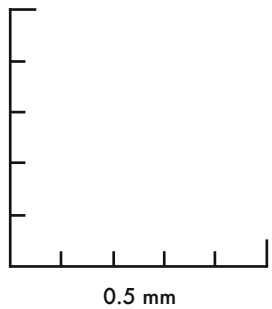
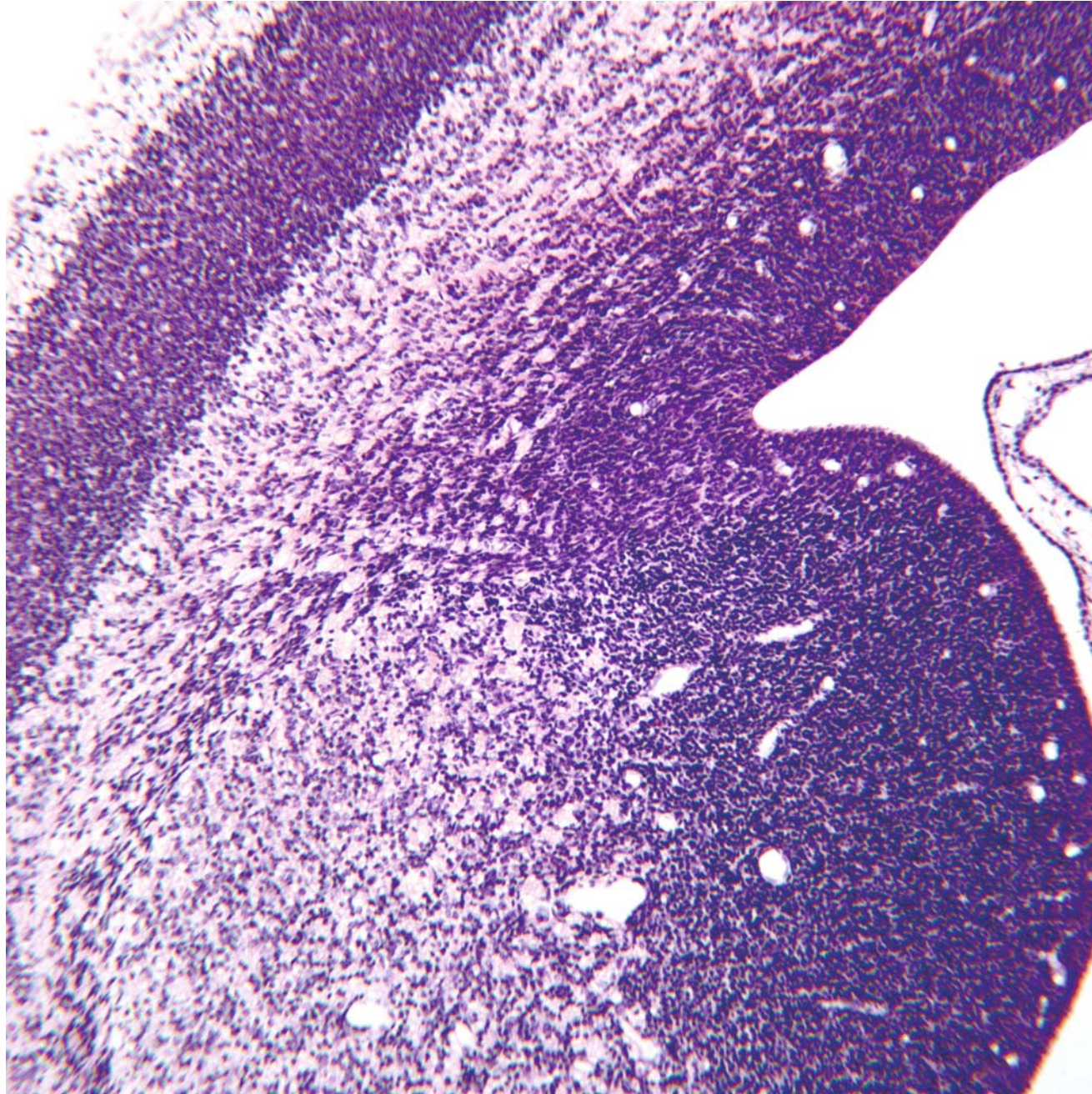
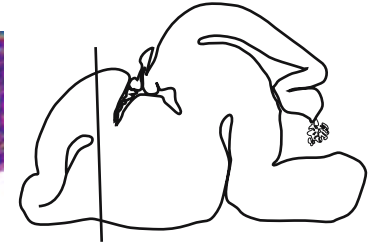
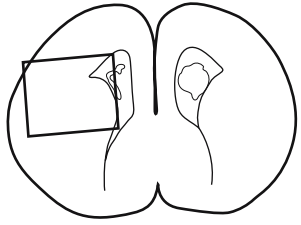


GD 16 CORONAL 8



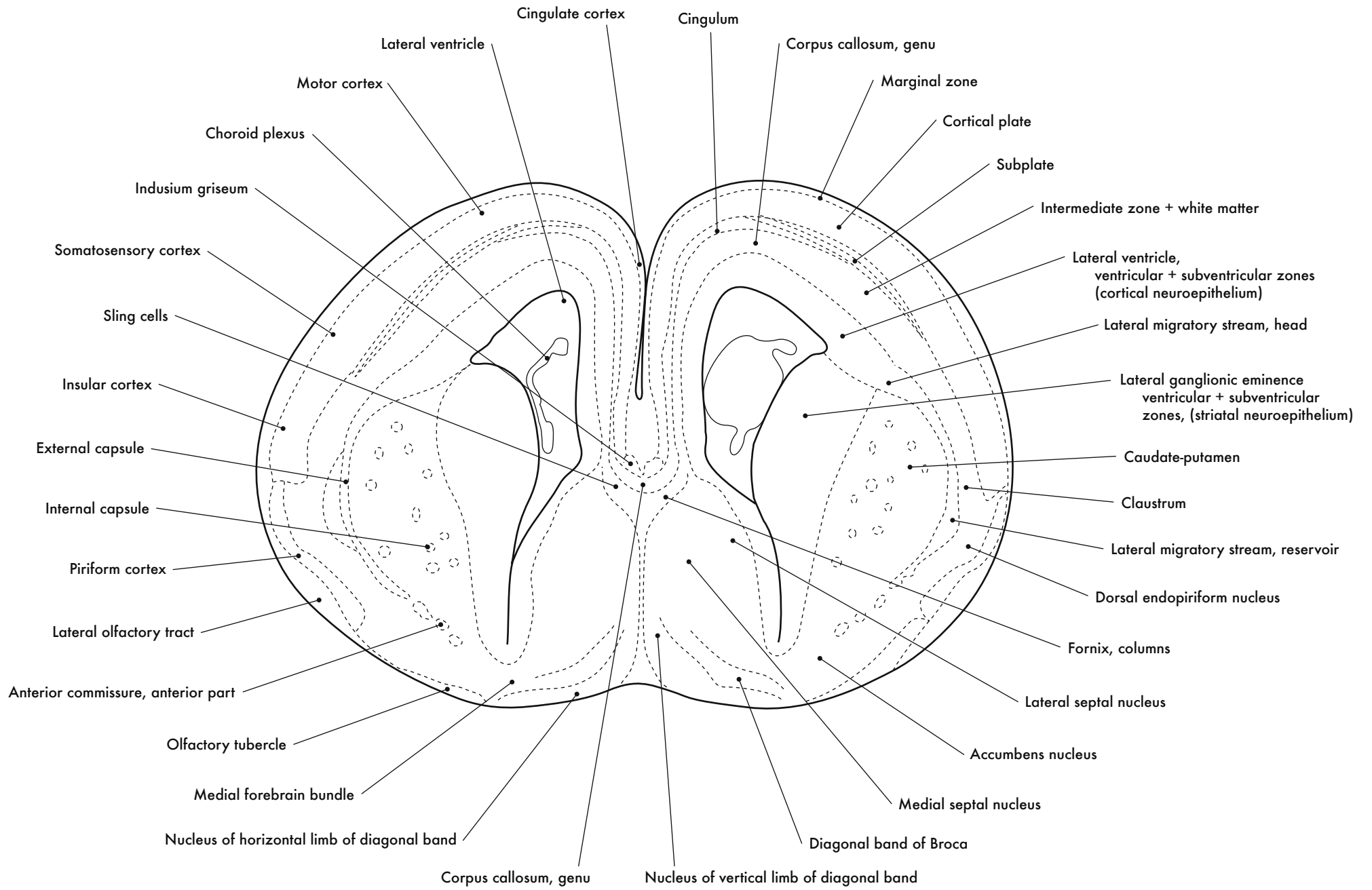
Cortex and Lateral Ganglionic Eminence



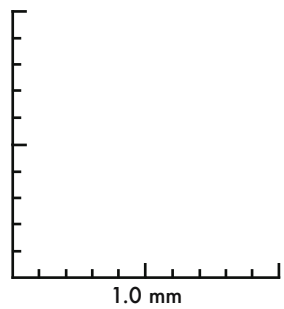
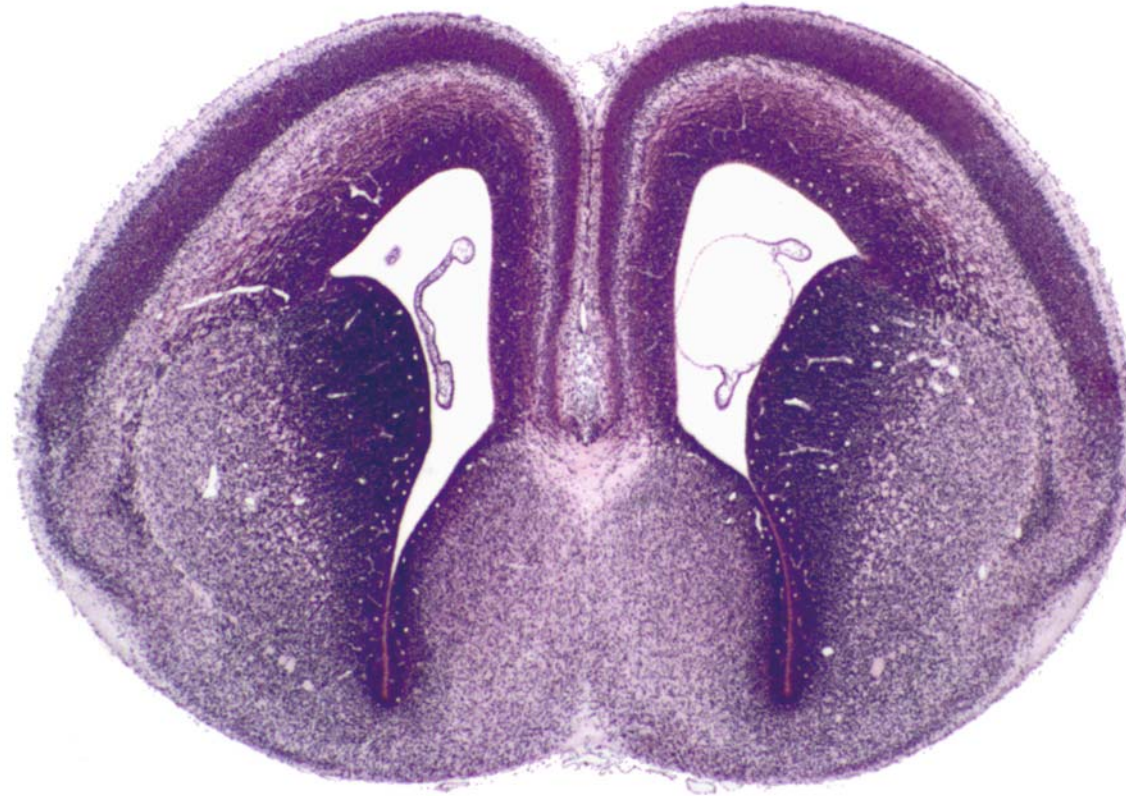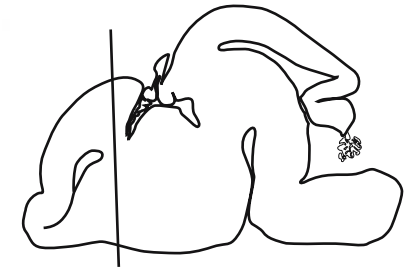


GD 16 CORONAL 9

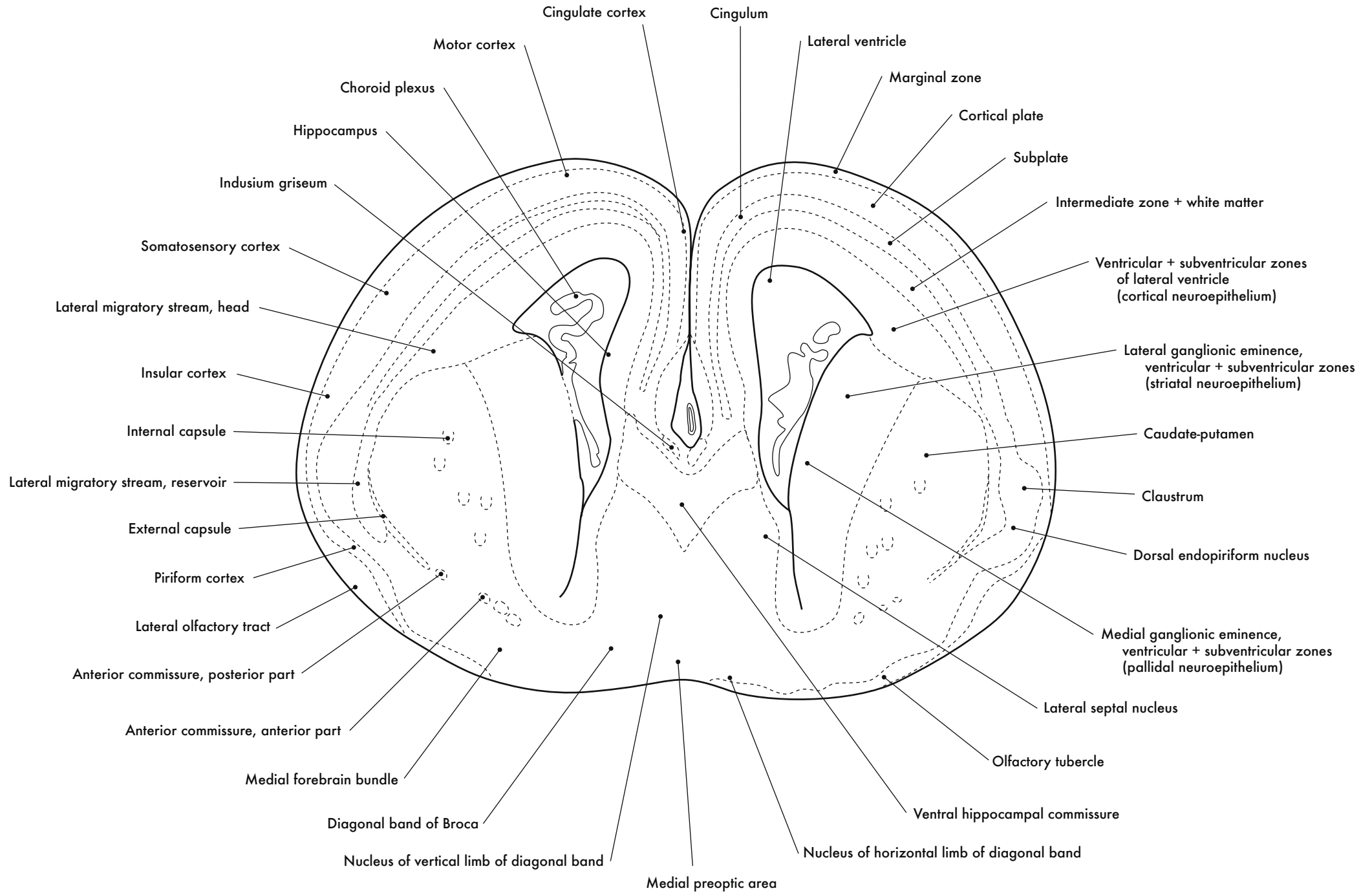
331

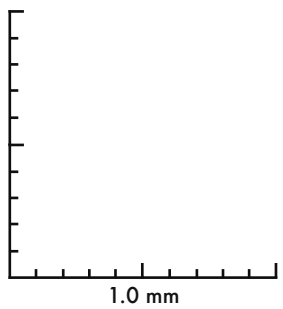
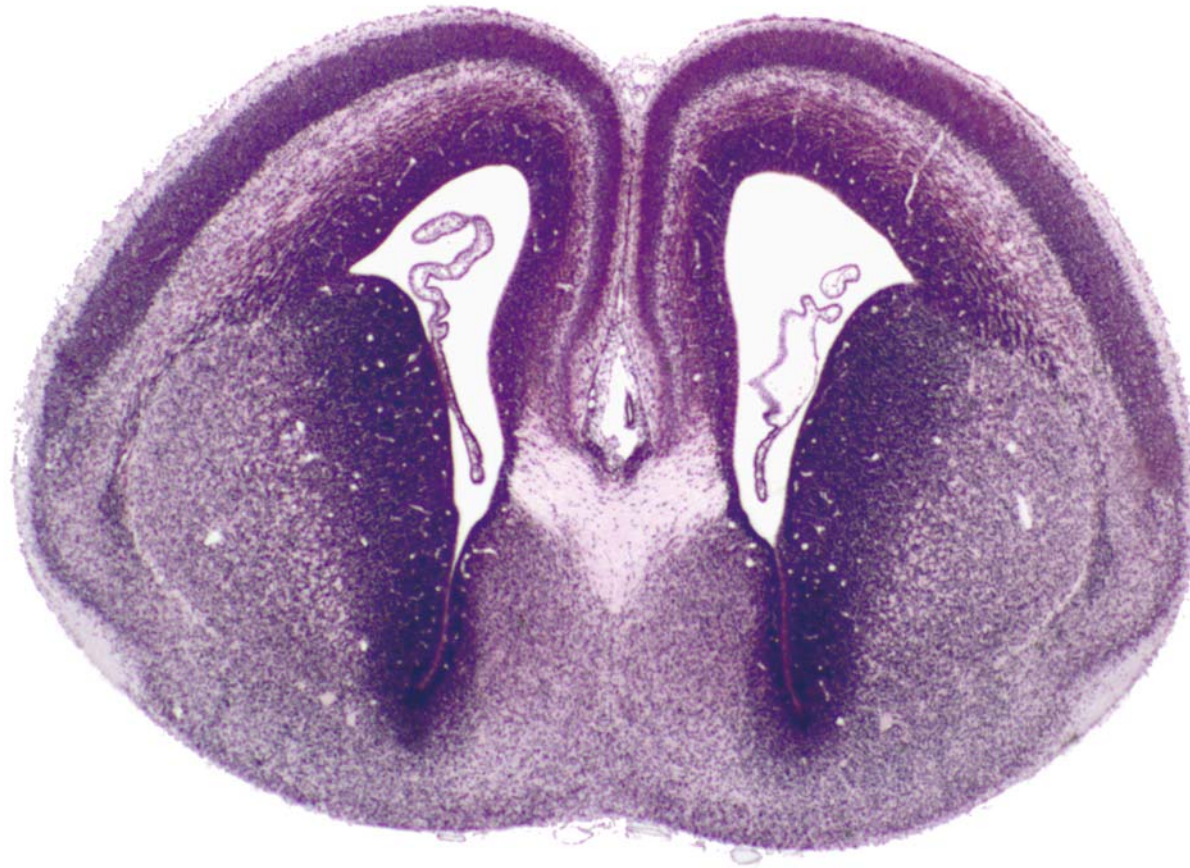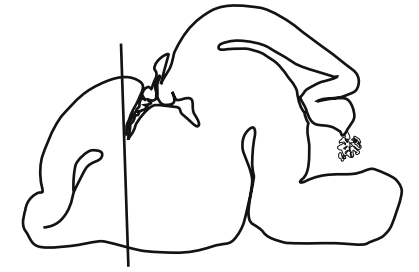




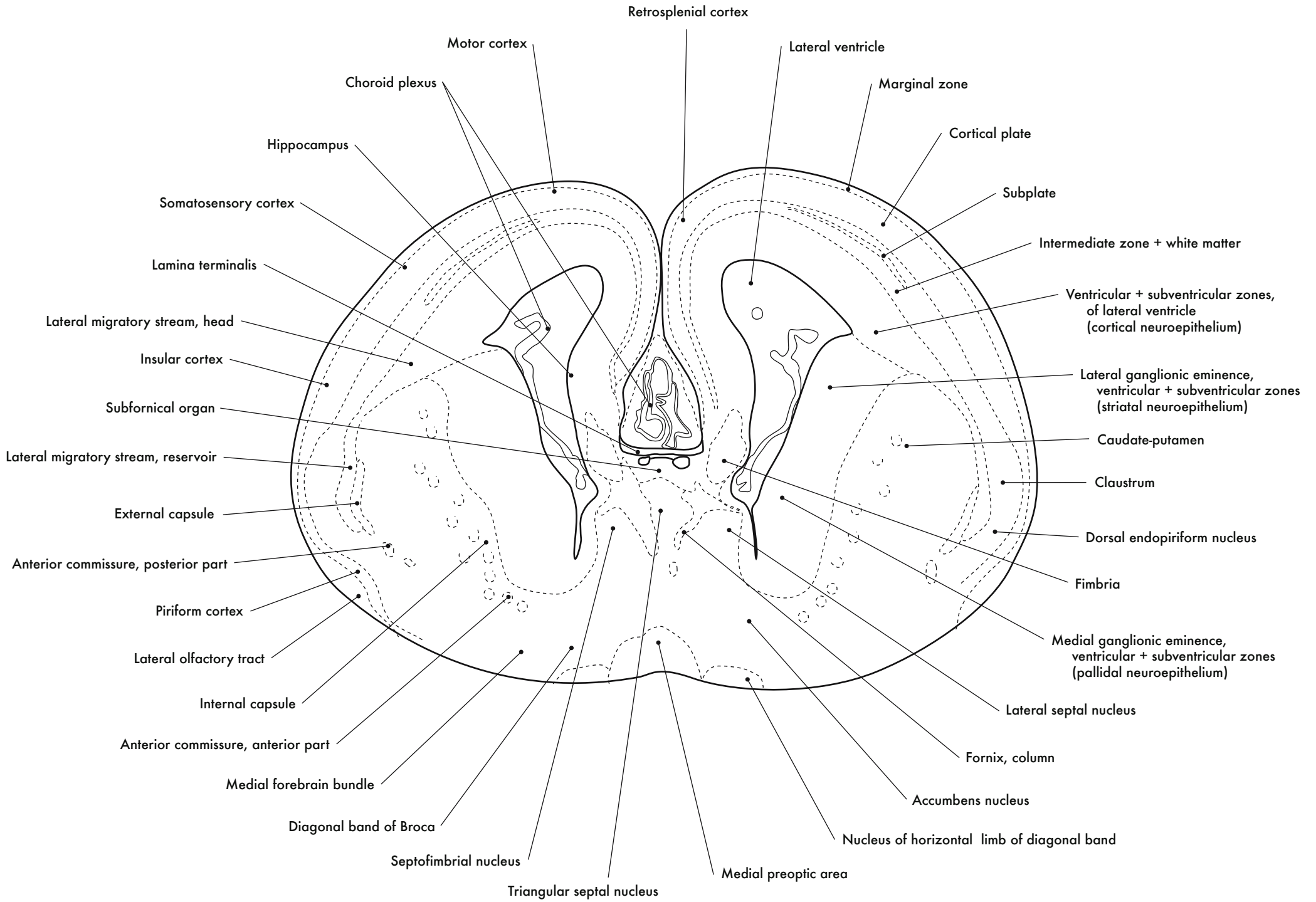


GD 16 CORONAL 10

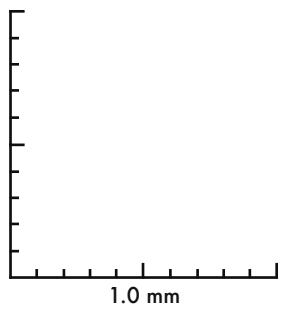
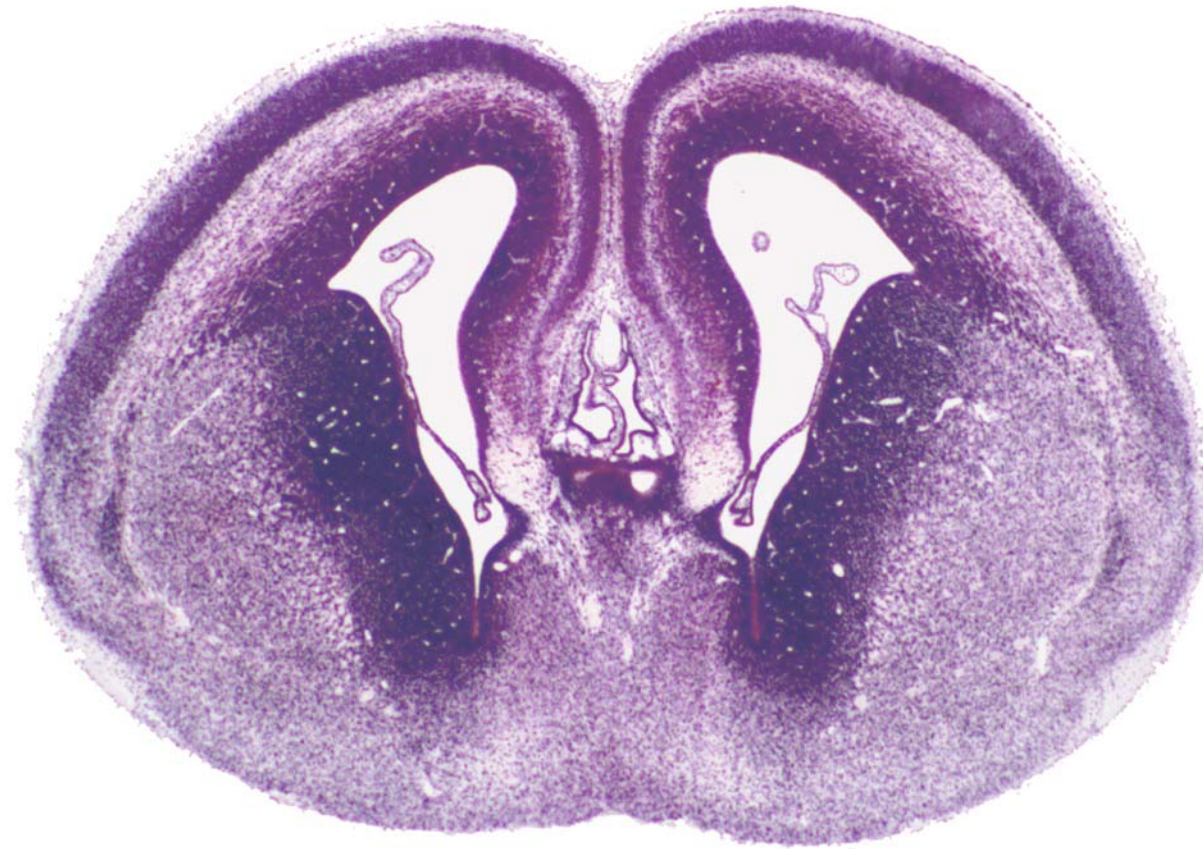
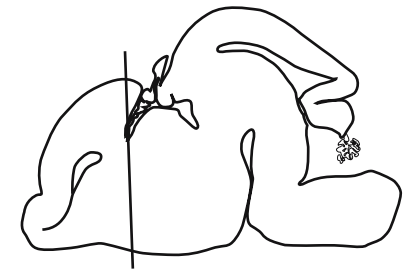




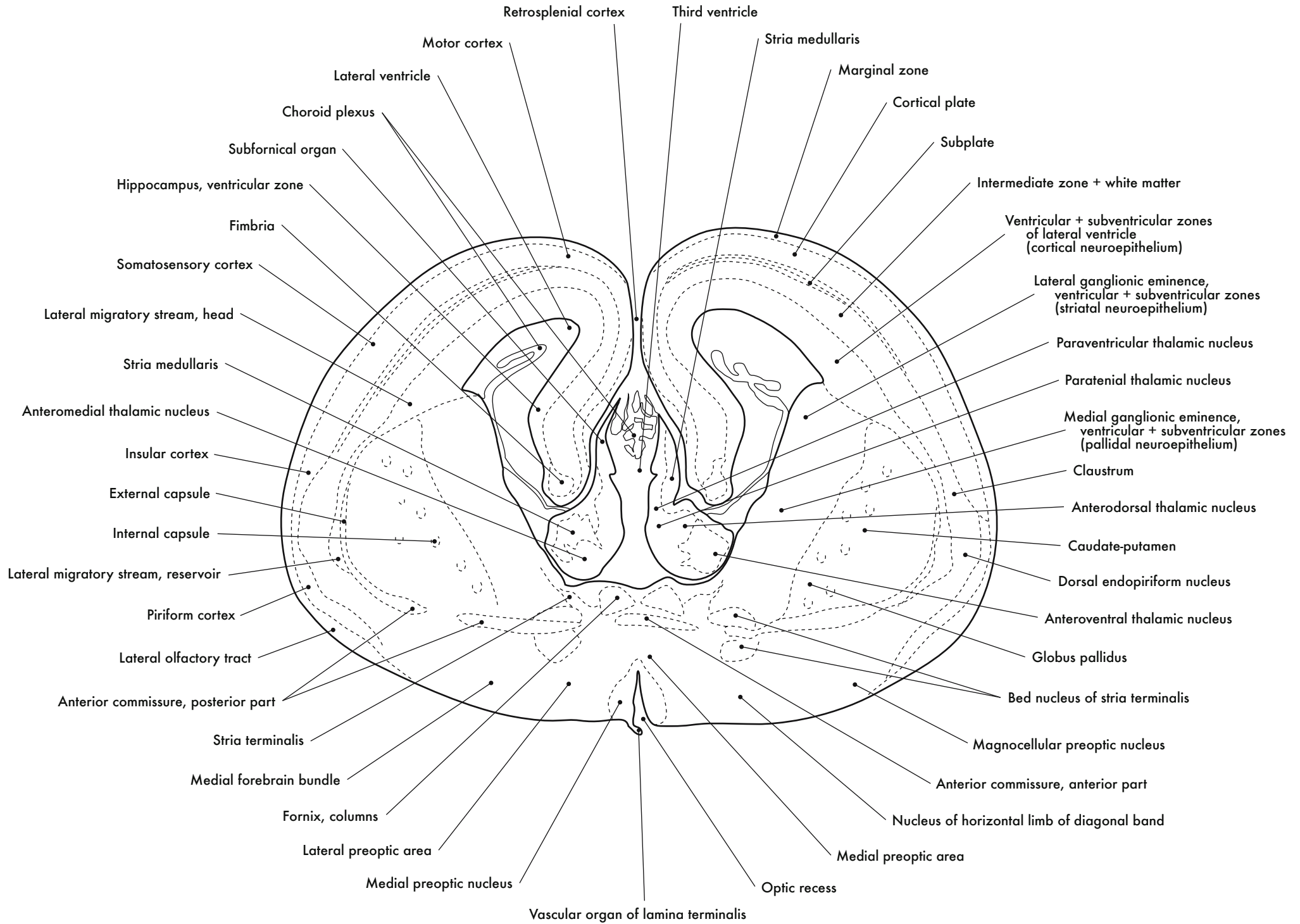
GD 16 CORONAL 11

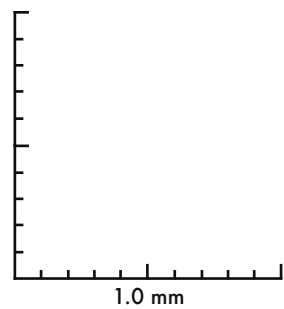
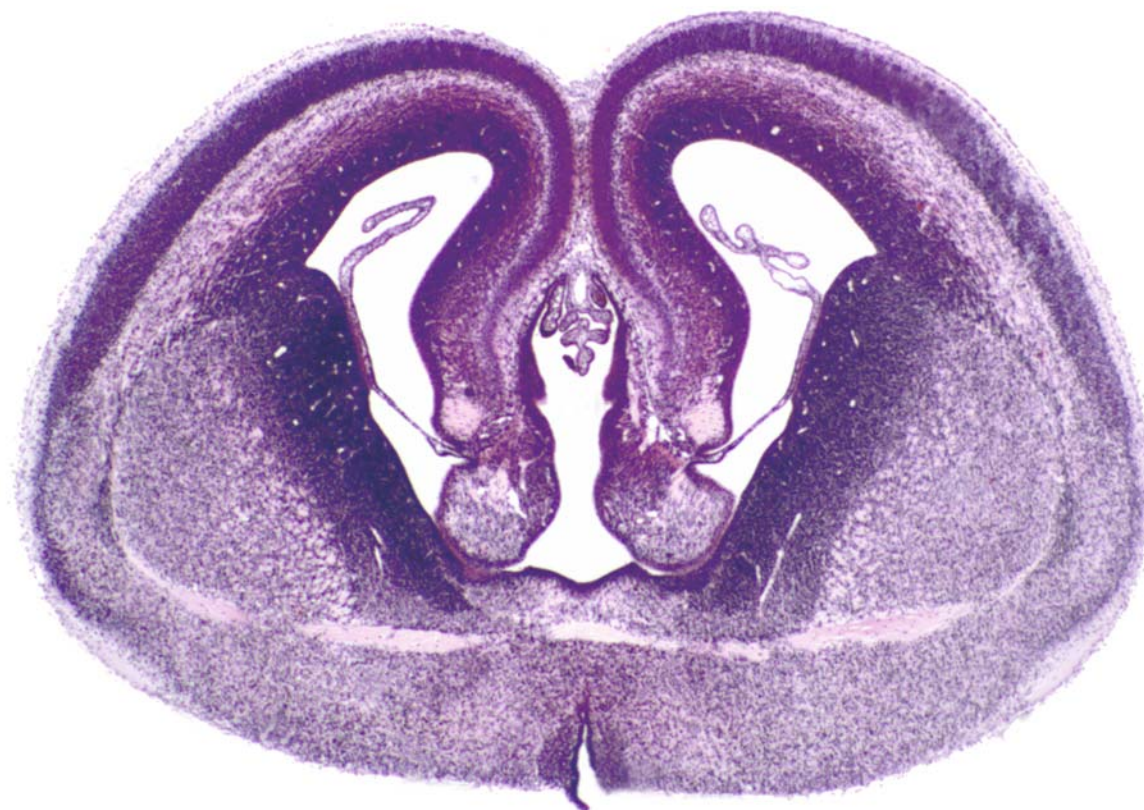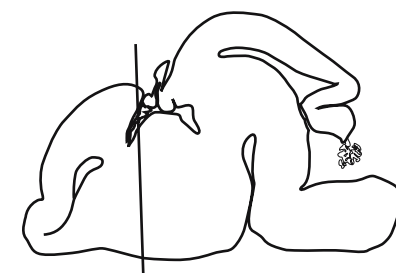




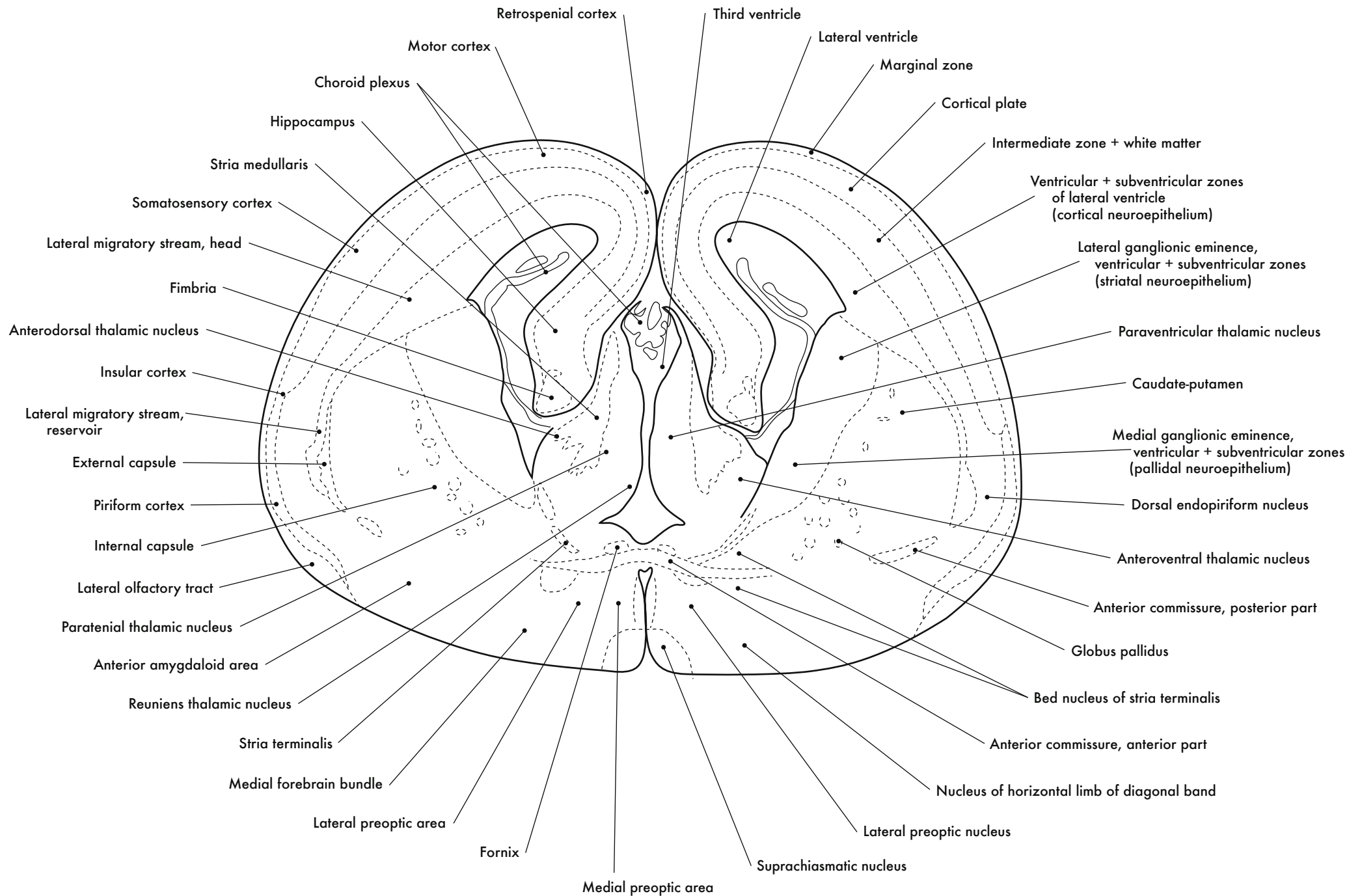


GD 16 CORONAL 12

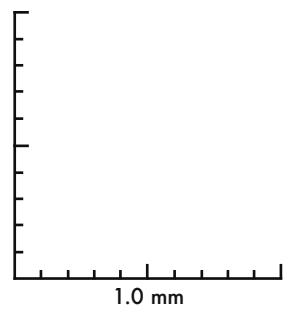
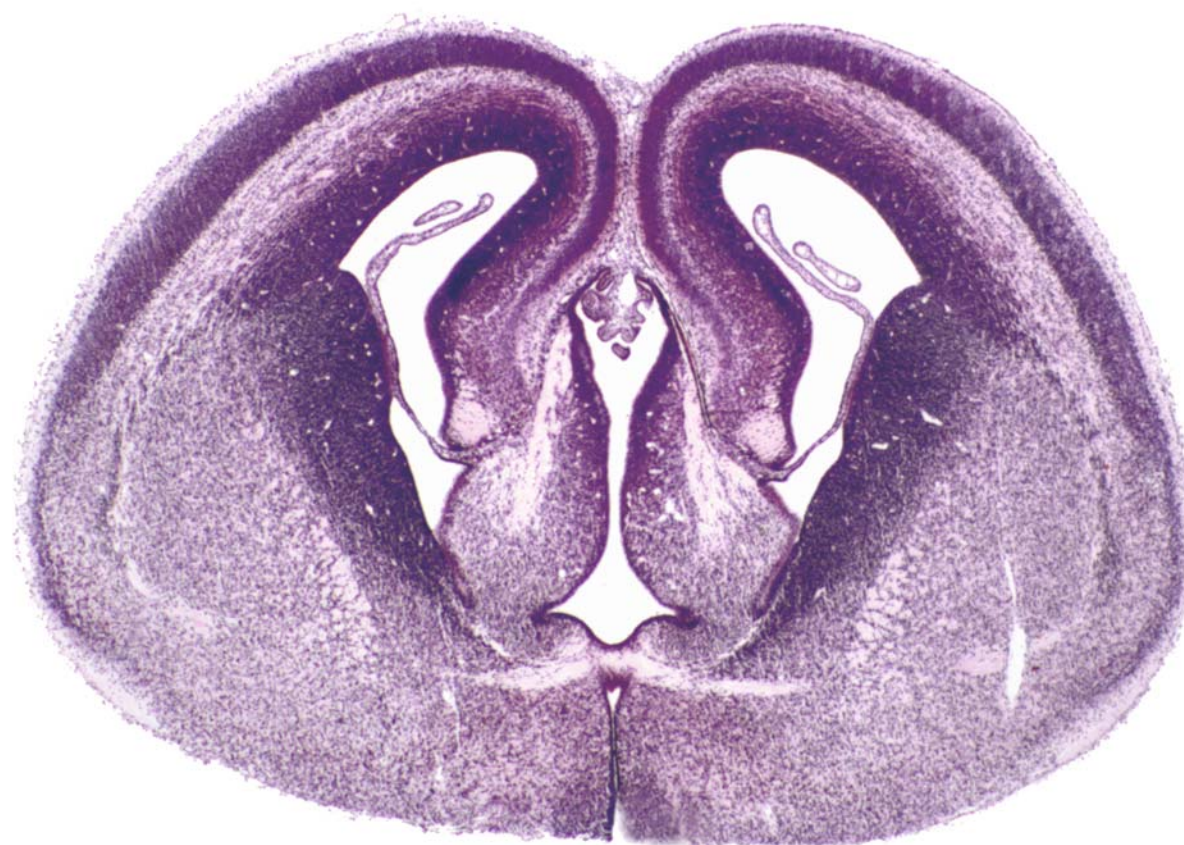
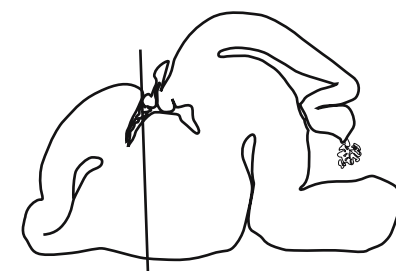




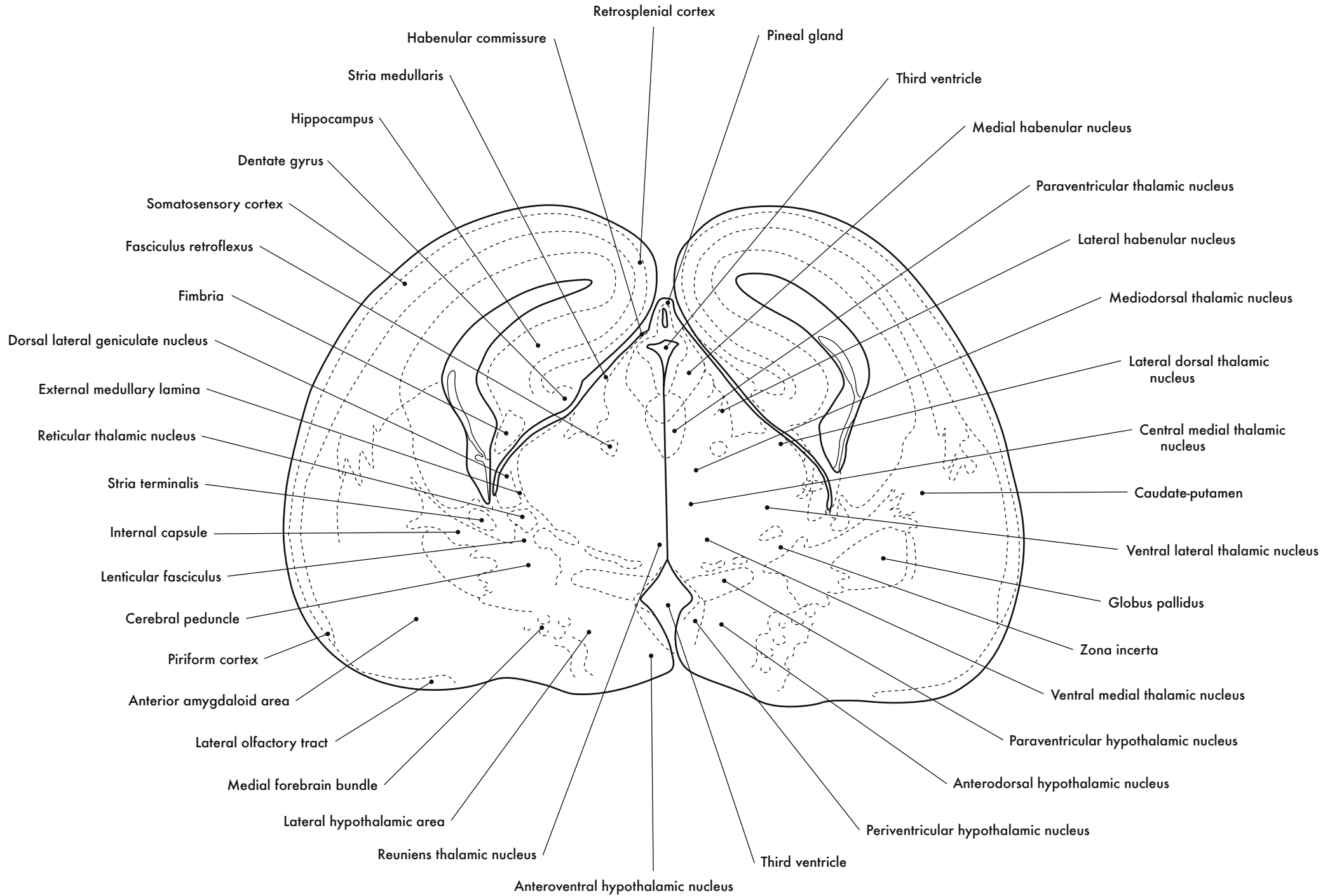
GD 16 CORONAL 13

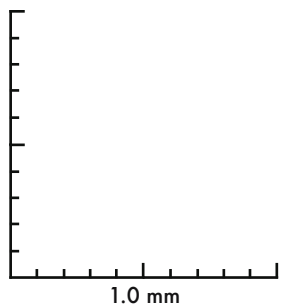
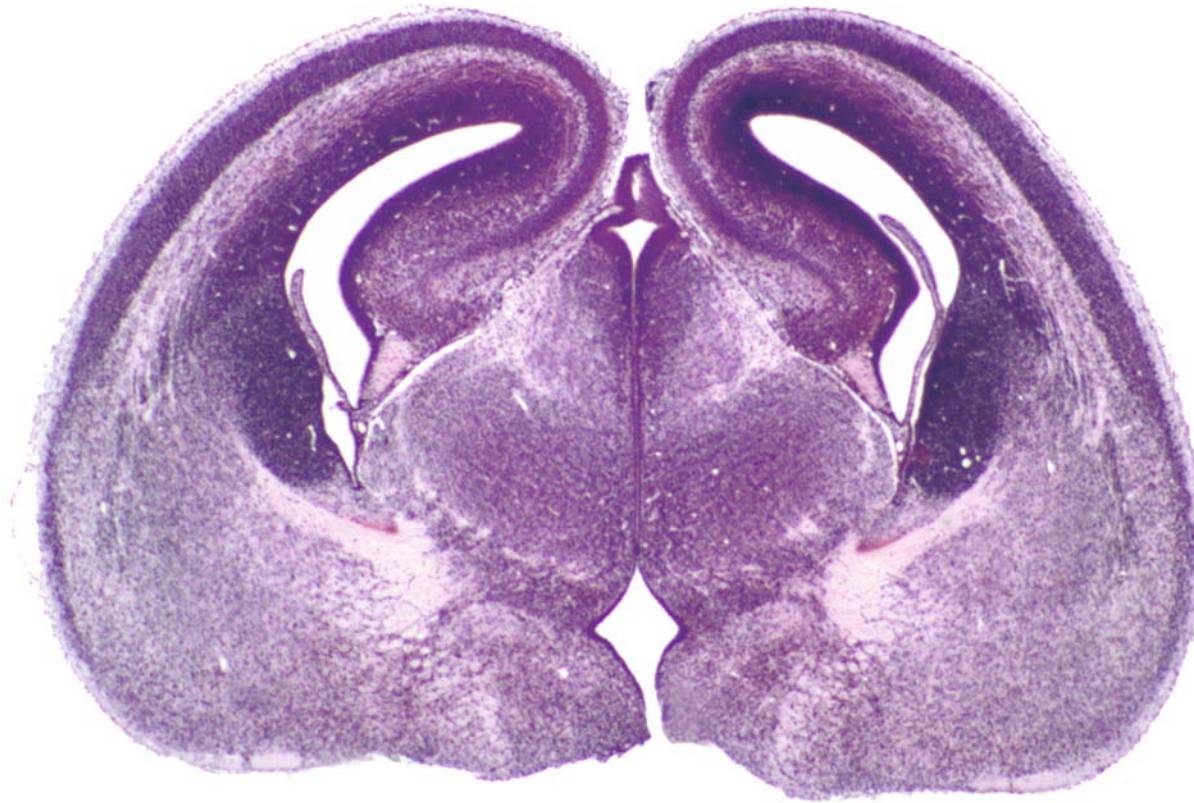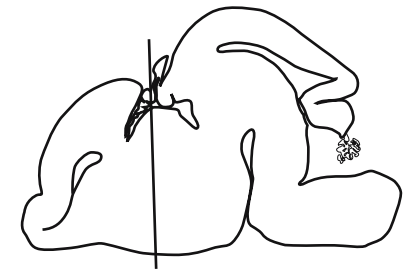




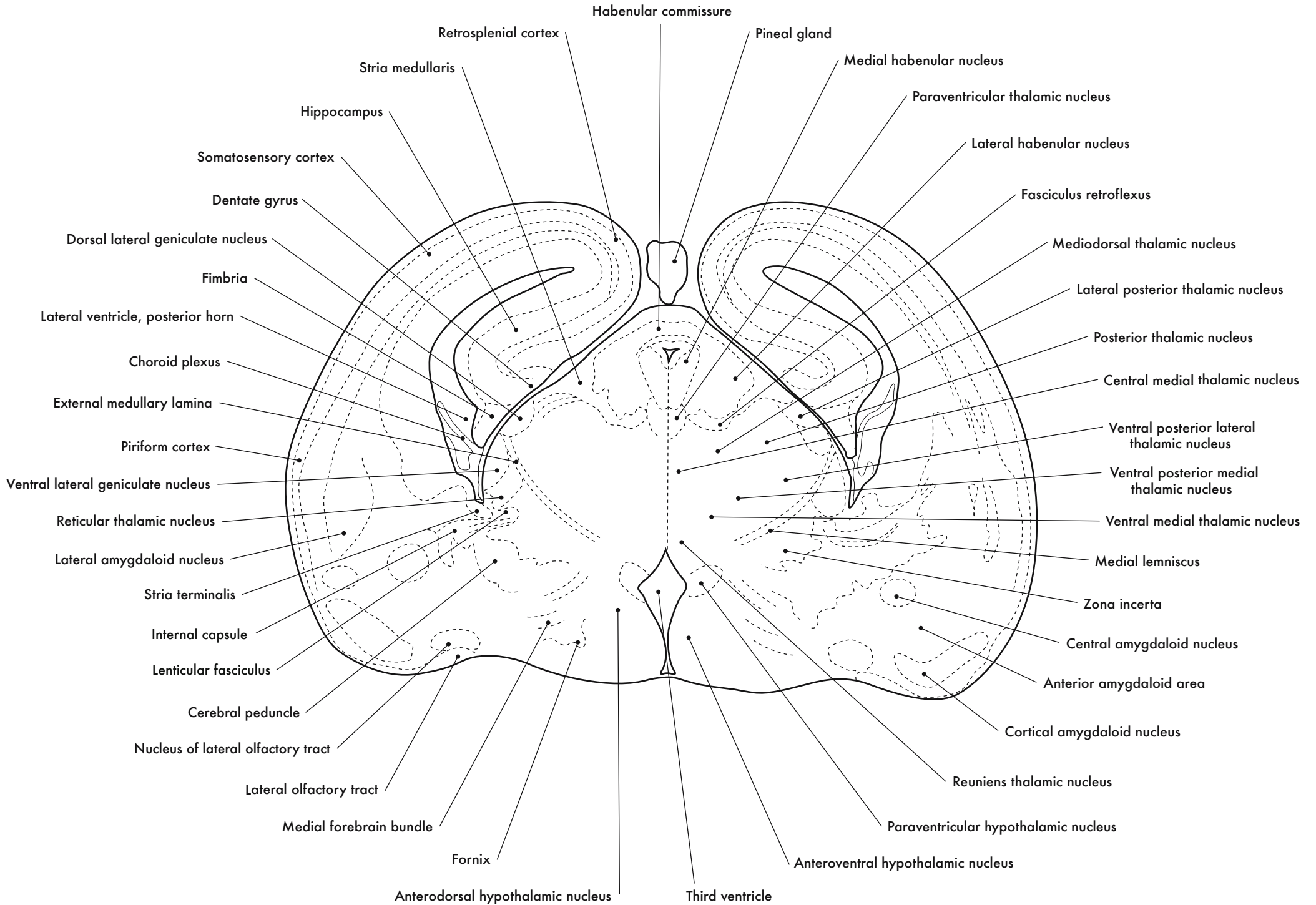


GD 16 CORONAL 14

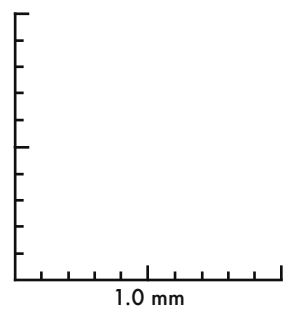
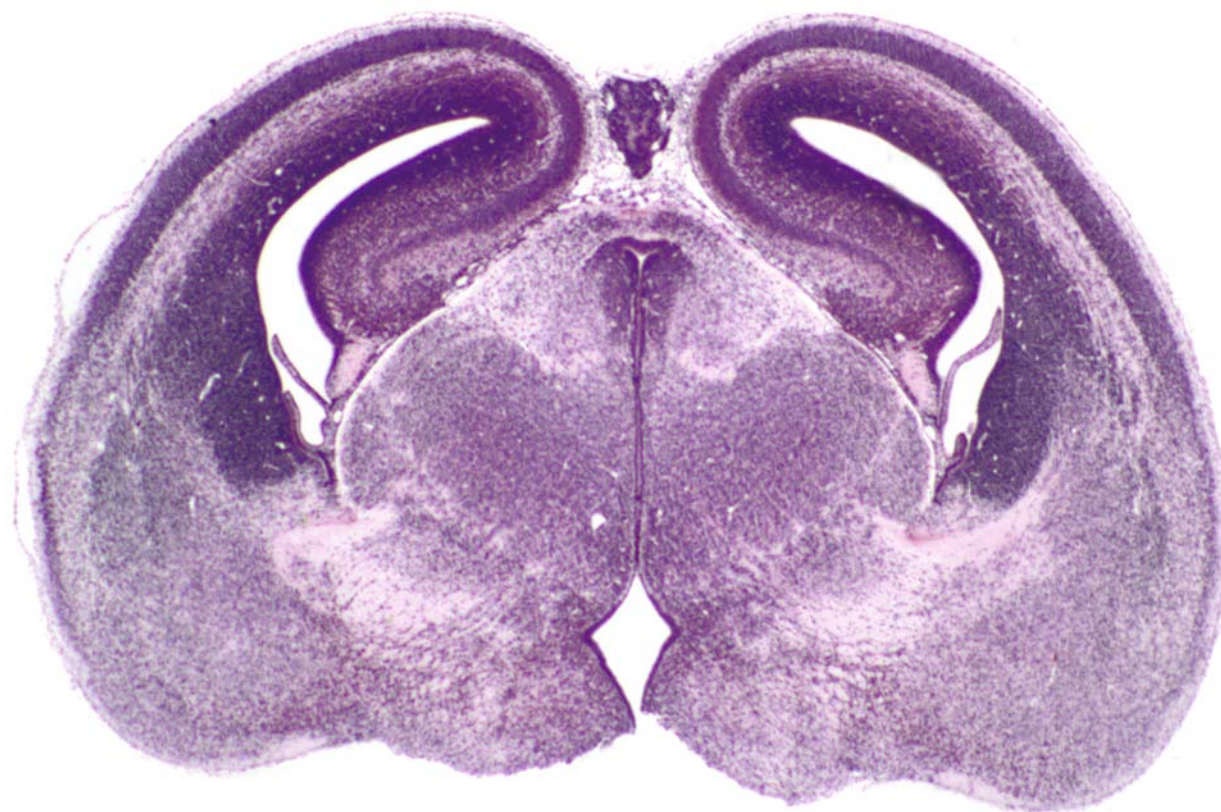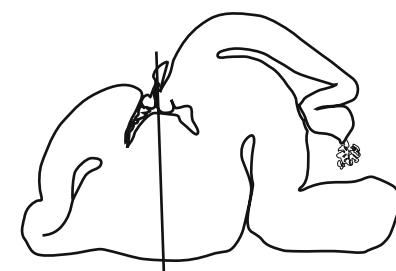




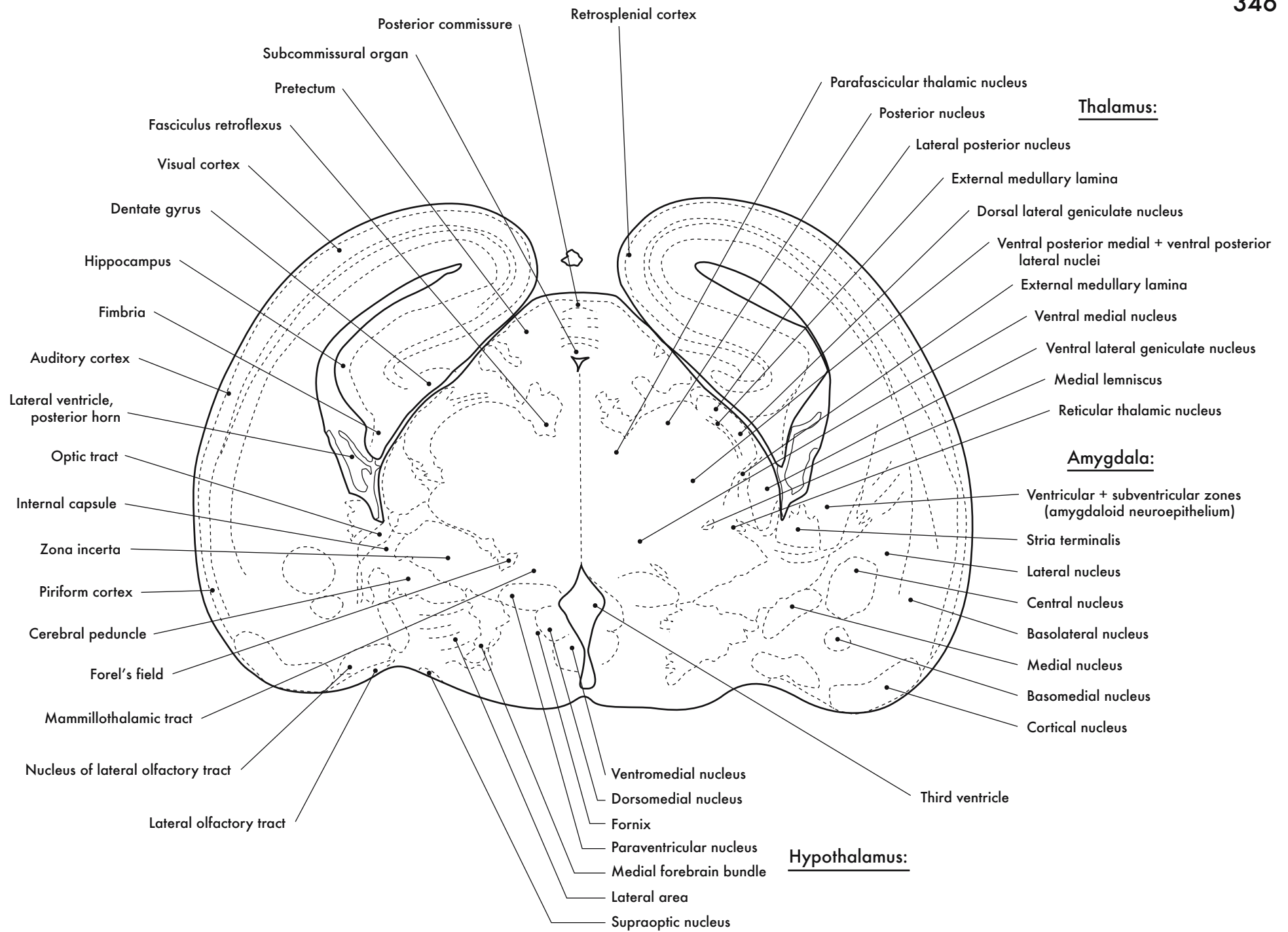
GD 16 CORONAL 15

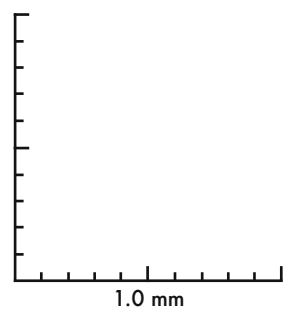
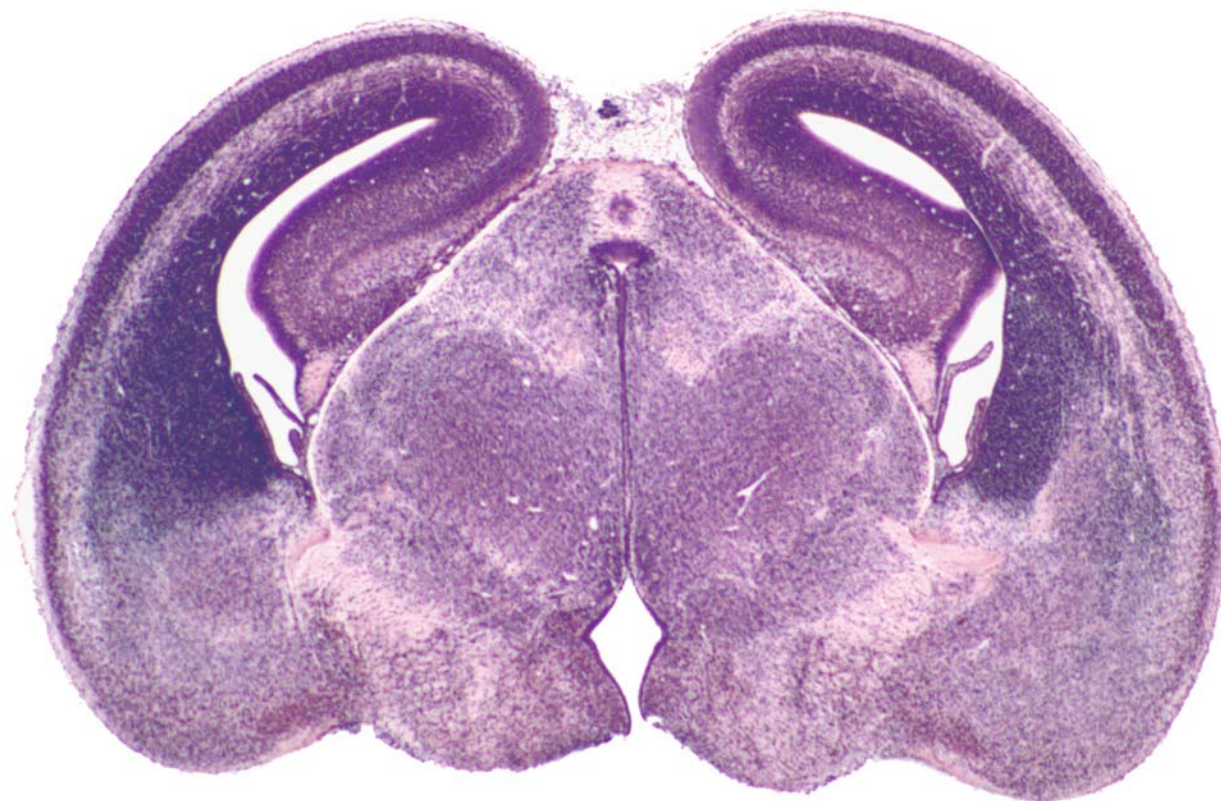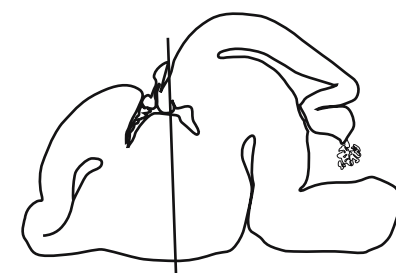




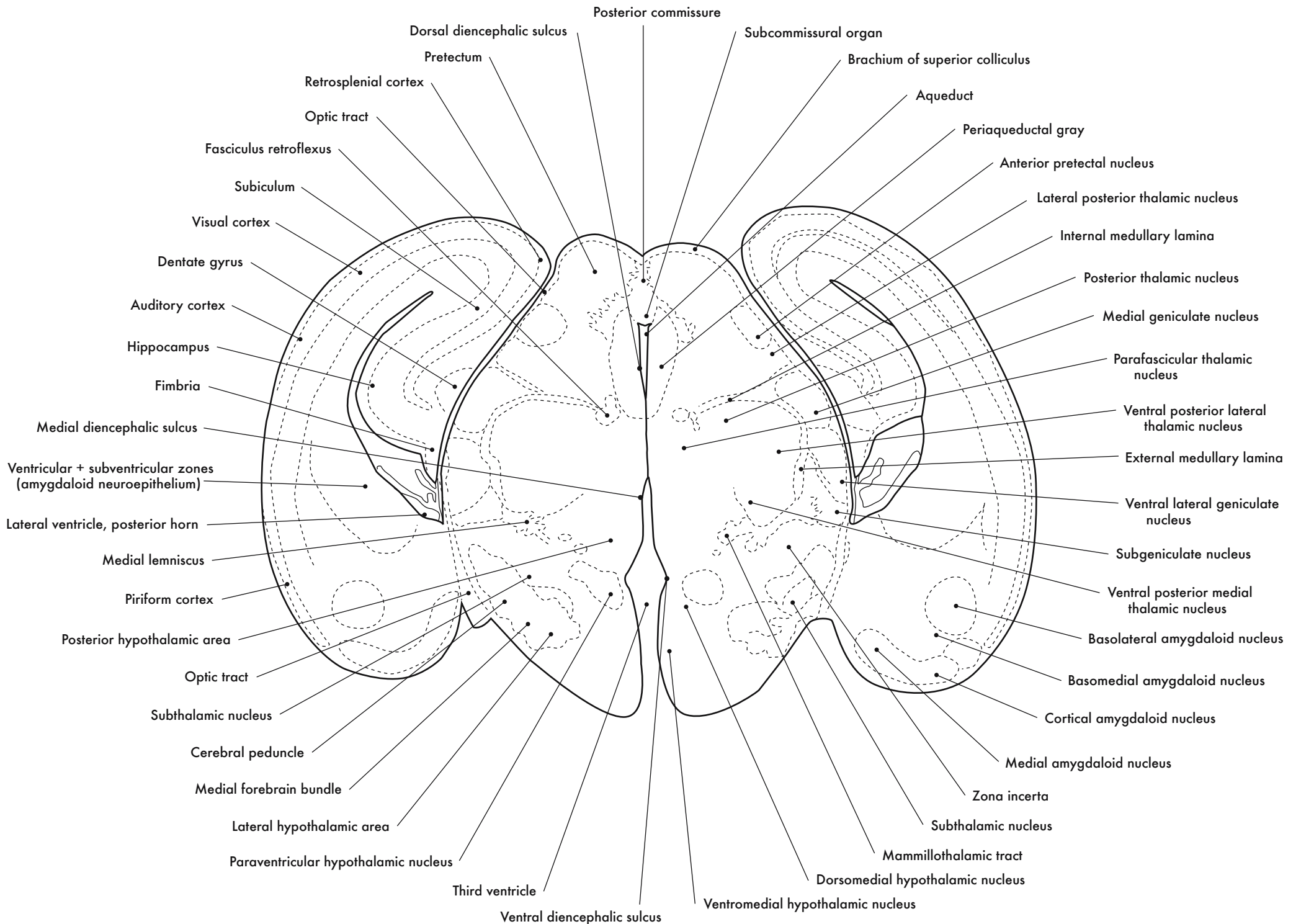


GD 16 CORONAL 16

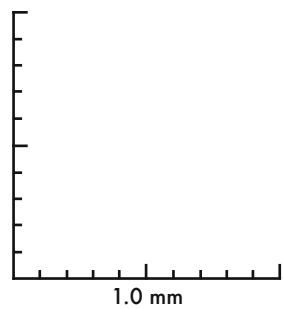
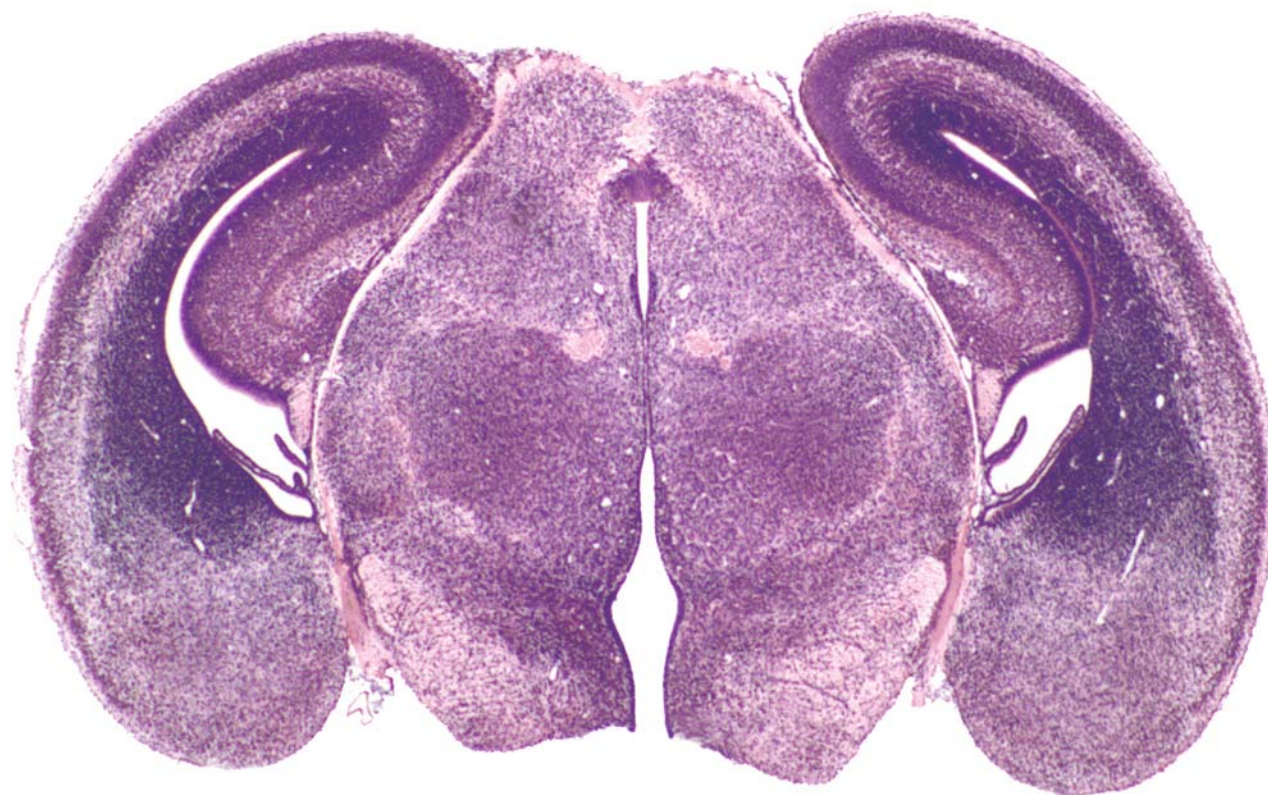
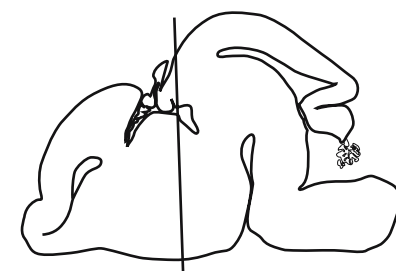




GD 16 CORONAL 17







GD 16 CORONAL 18

349

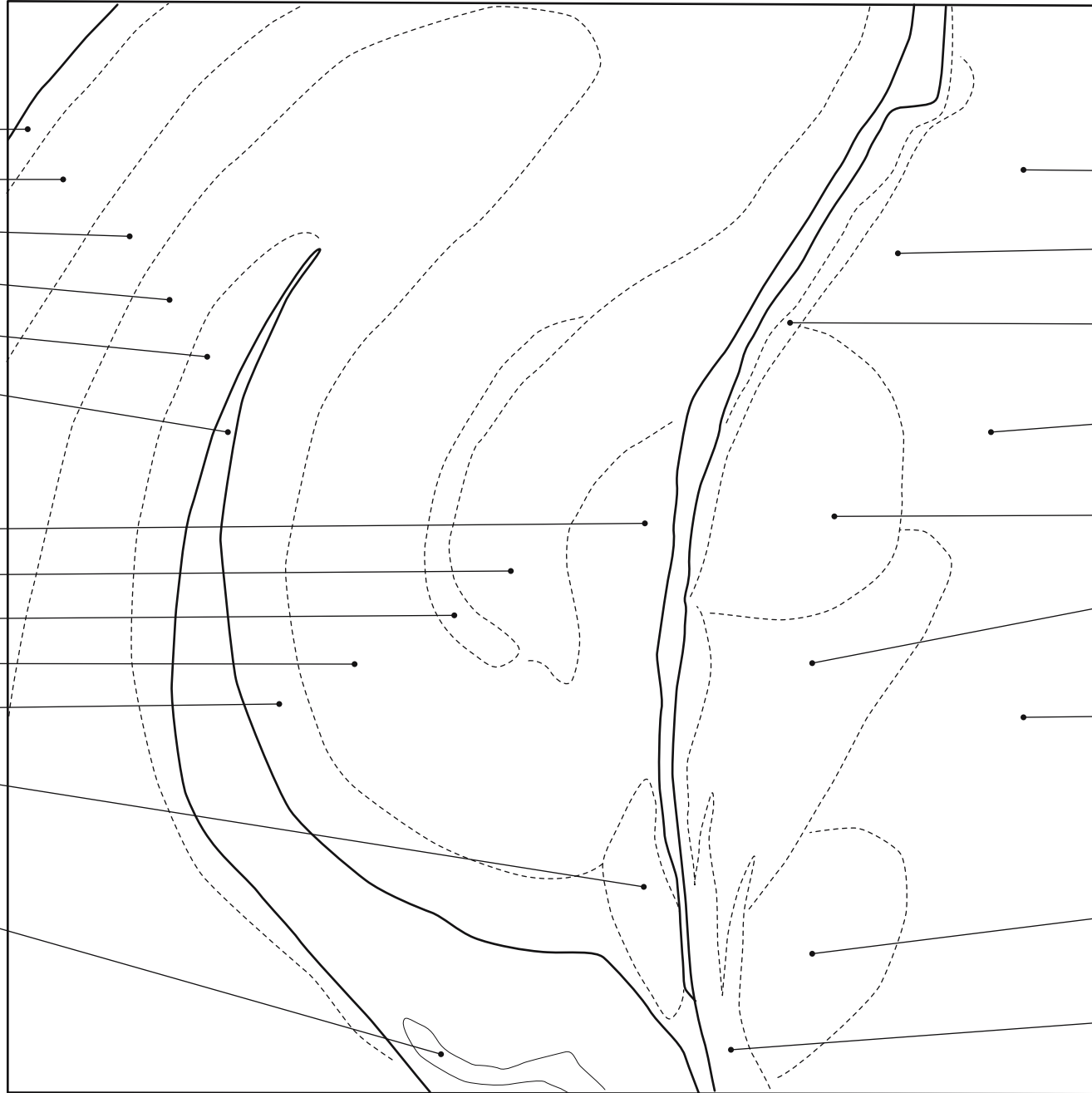
**Auditory cortex:**

- Marginal zone
- Cortical plate
- Intermediate zone
- Subventricular zone
- Ventricular zone
- Lateral ventricle

**Hippocampal formation:**

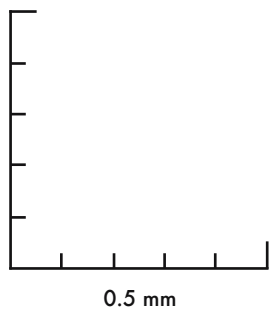
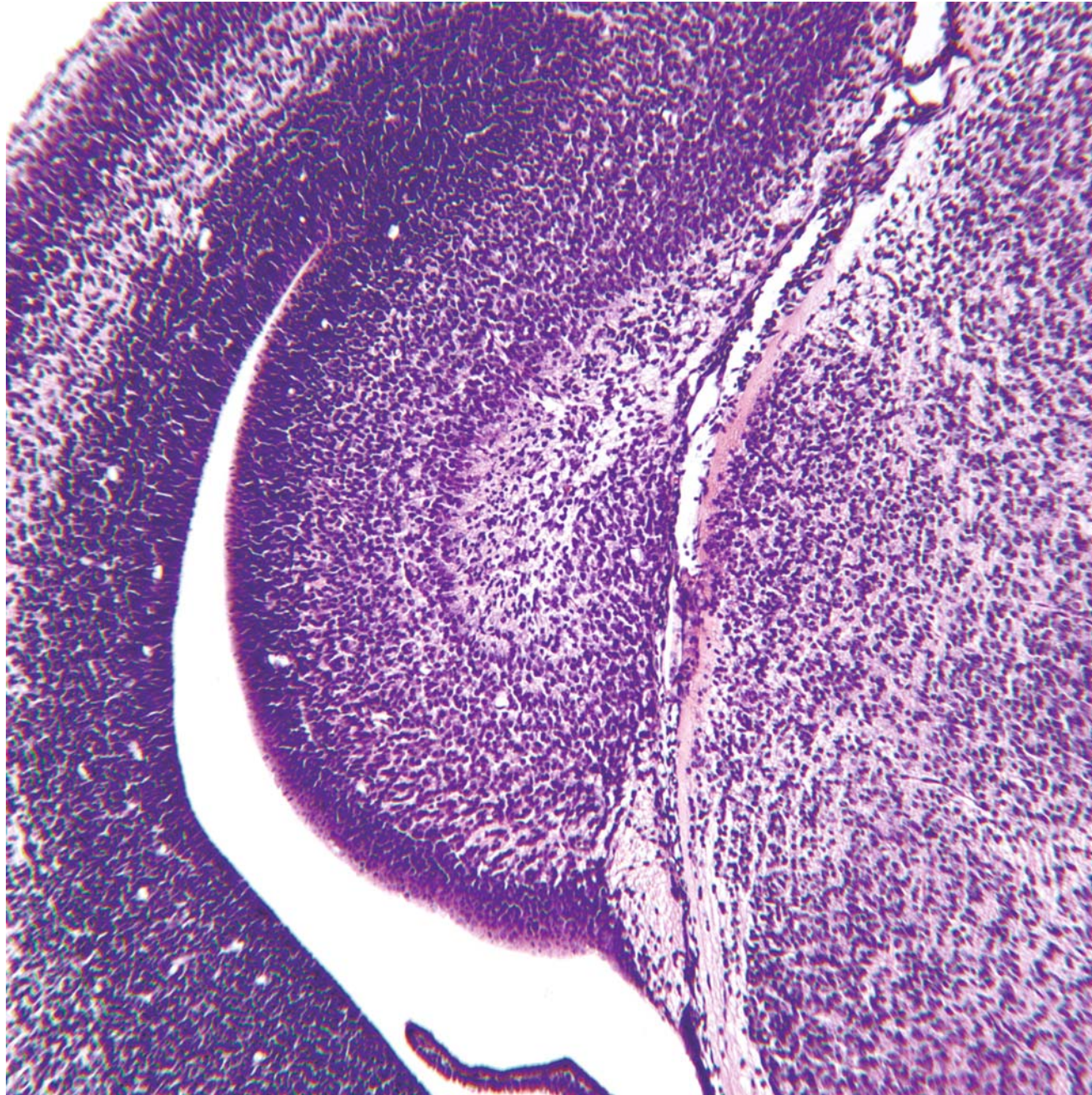
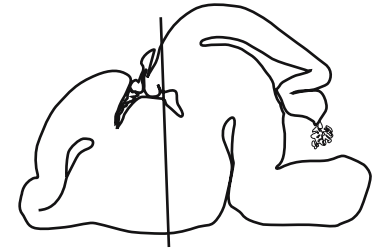
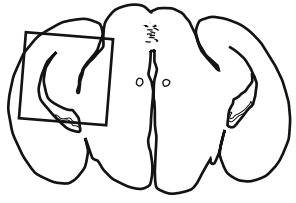
- Dentate gyrus
- Molecular layer
- Pyramidal cell layer
- Polymorph layer
- Hippocampal neuroepithelium
- Fimbria
- Choroid plexus

- Anterior pretectal nucleus
- Lateral posterior thalamic nucleus
- Brachium of superior colliculus
- Medial geniculate nucleus
- Dorsal lateral geniculate nucleus
- Ventral lateral geniculate nucleus
- Zona incerta
- Subgeniculate nucleus
- Optic tract

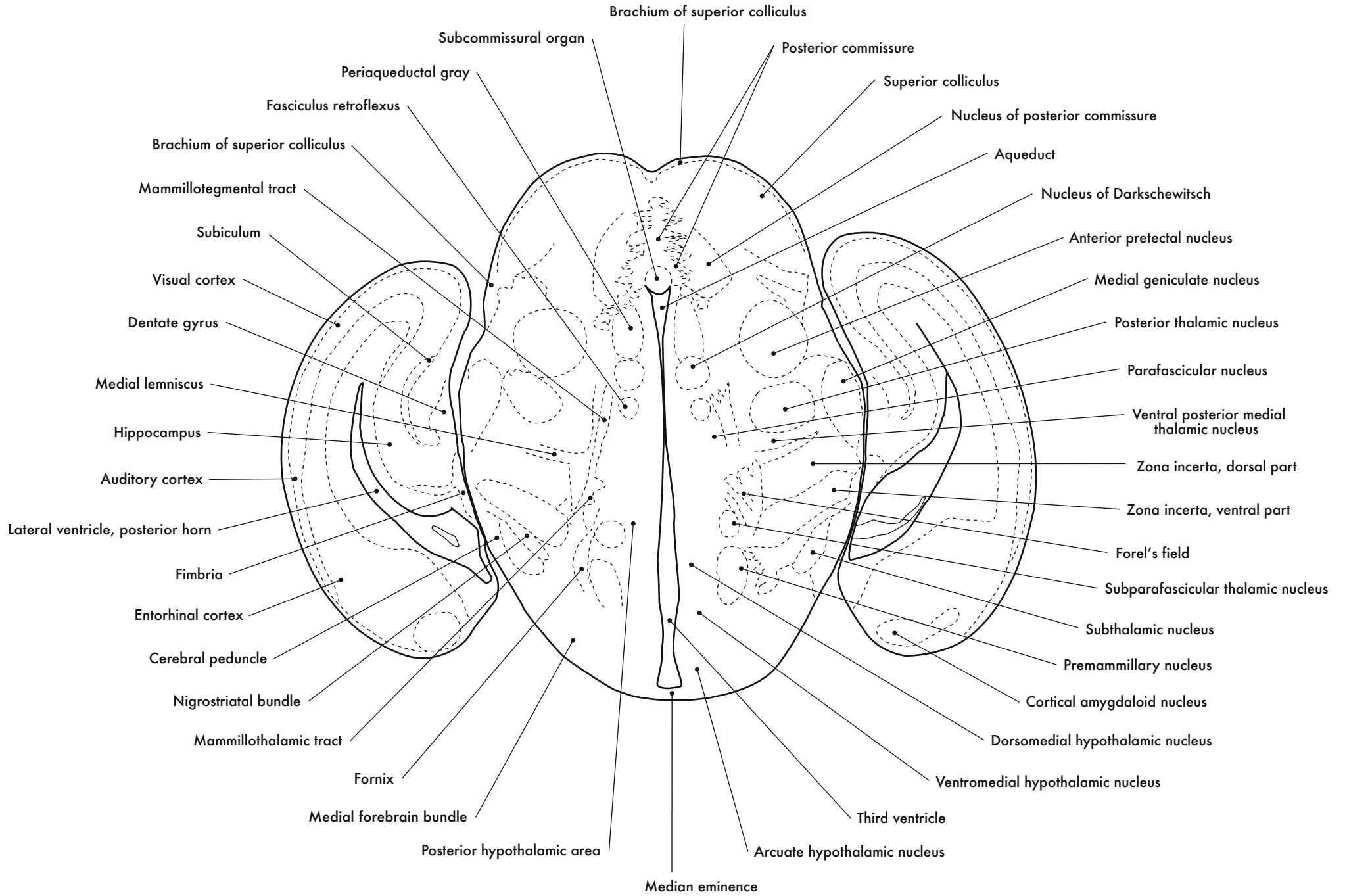


**Hippocampus and Thalamus**

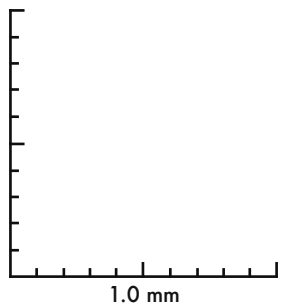
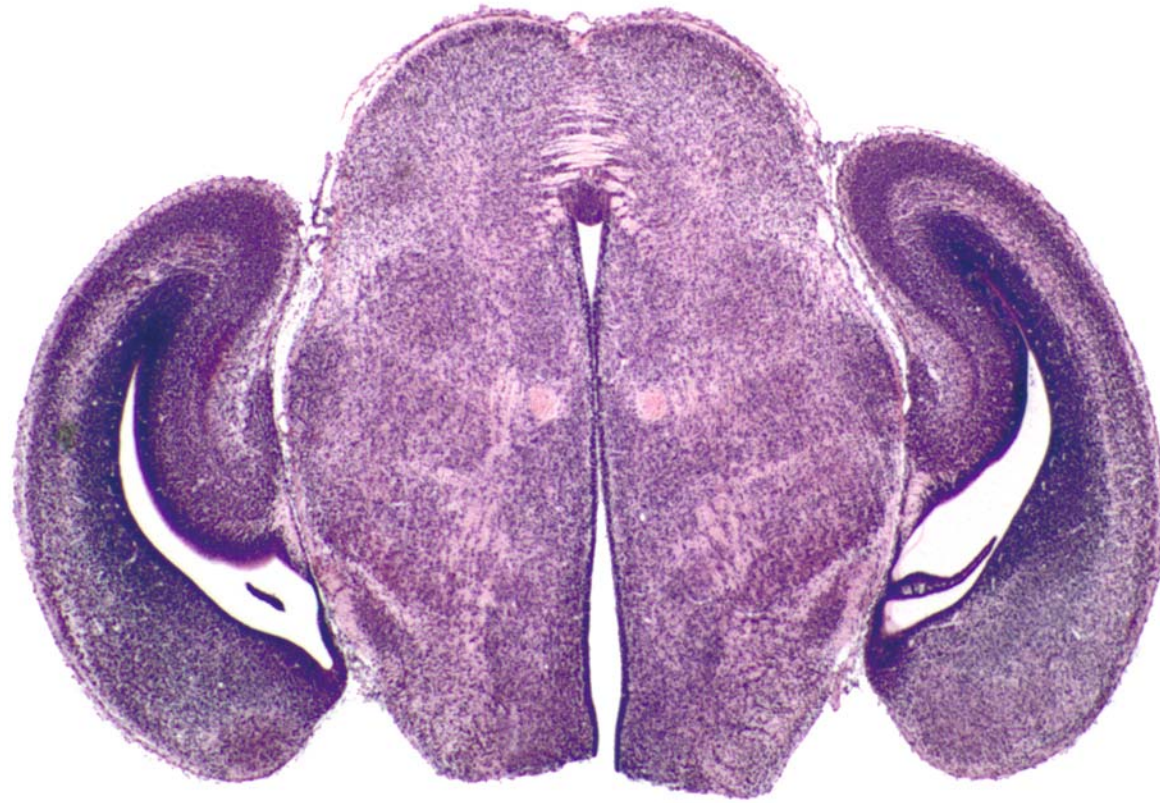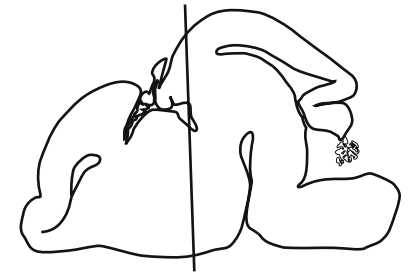




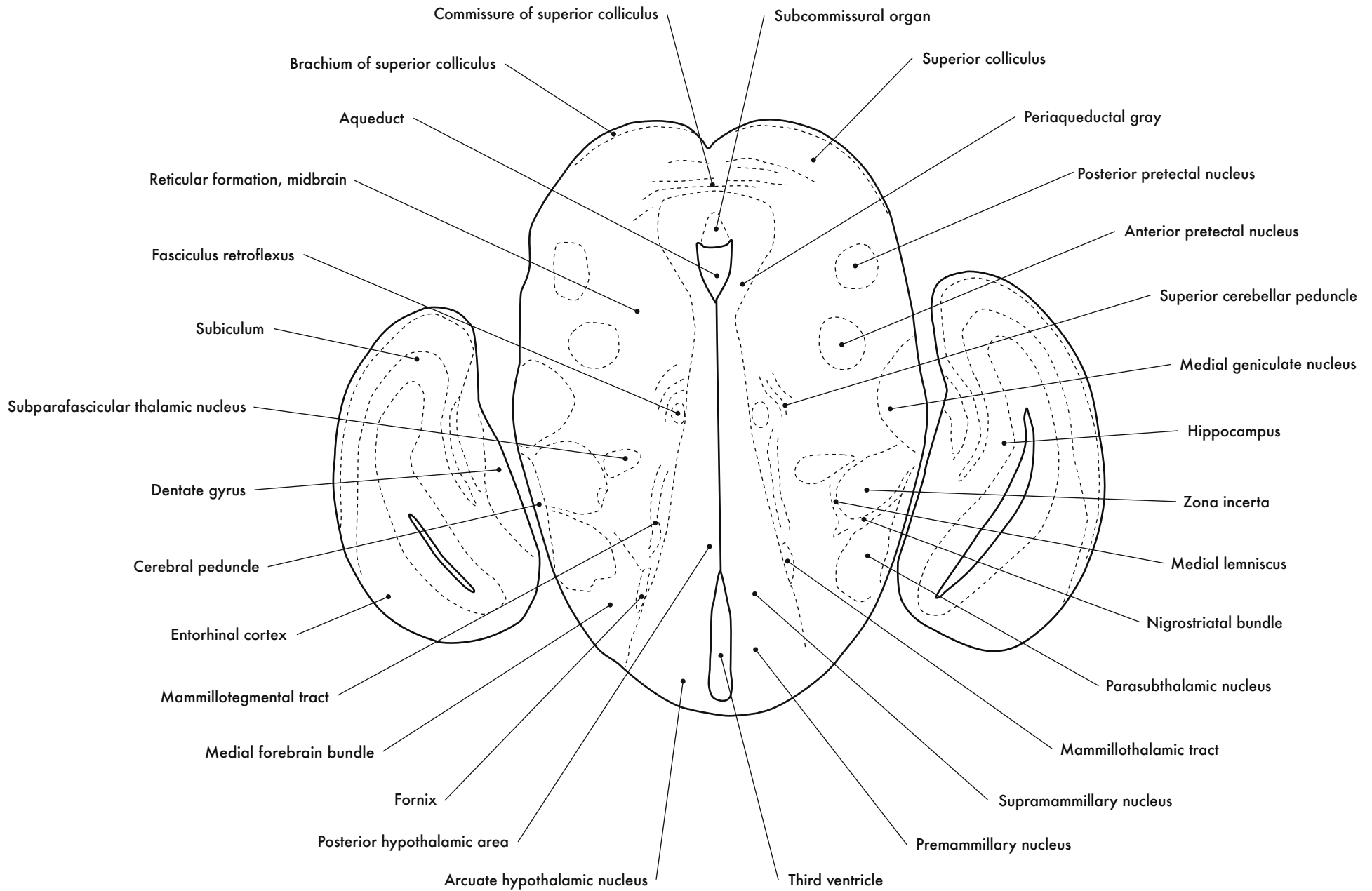
GD 16 CORONAL 19







GD 16 CORONAL 20



Commissure of superior colliculus

Subcommissural organ

Brachium of superior colliculus

Superior colliculus

Aqueduct

Periaqueductal gray

Reticular formation, midbrain

Posterior pretectal nucleus

Fasciculus retroflexus

Anterior pretectal nucleus

Subiculum

Superior cerebellar peduncle

Subparafascicular thalamic nucleus

Medial geniculate nucleus

Dentate gyrus

Hippocampus

Cerebral peduncle

Zona incerta

Entorhinal cortex

Medial lemniscus

Mammillotegmental tract

Nigrostriatal bundle

Medial forebrain bundle

Parasubthalamic nucleus

Fornix

Mammillothalamic tract

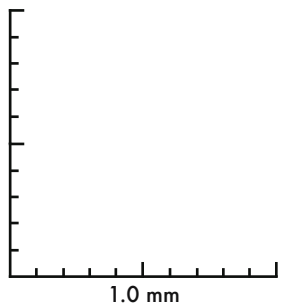
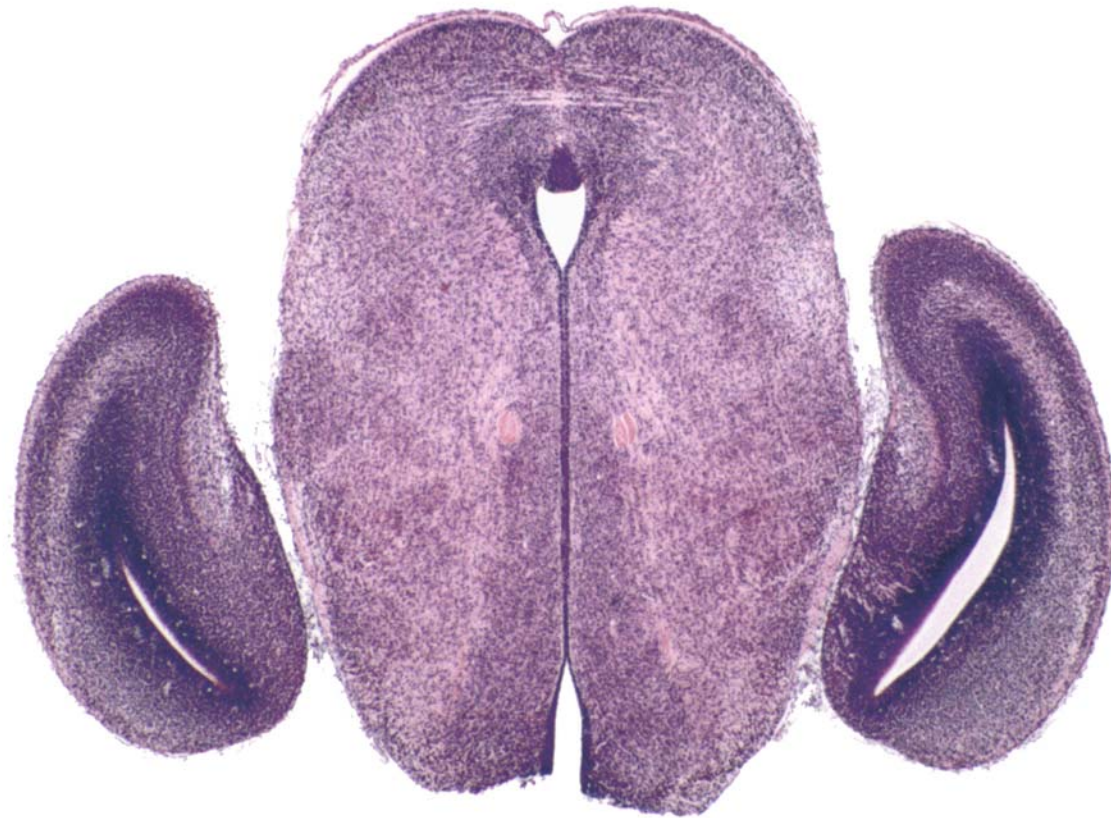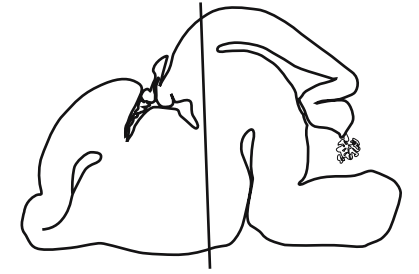
Posterior hypothalamic area

Supramammillary nucleus

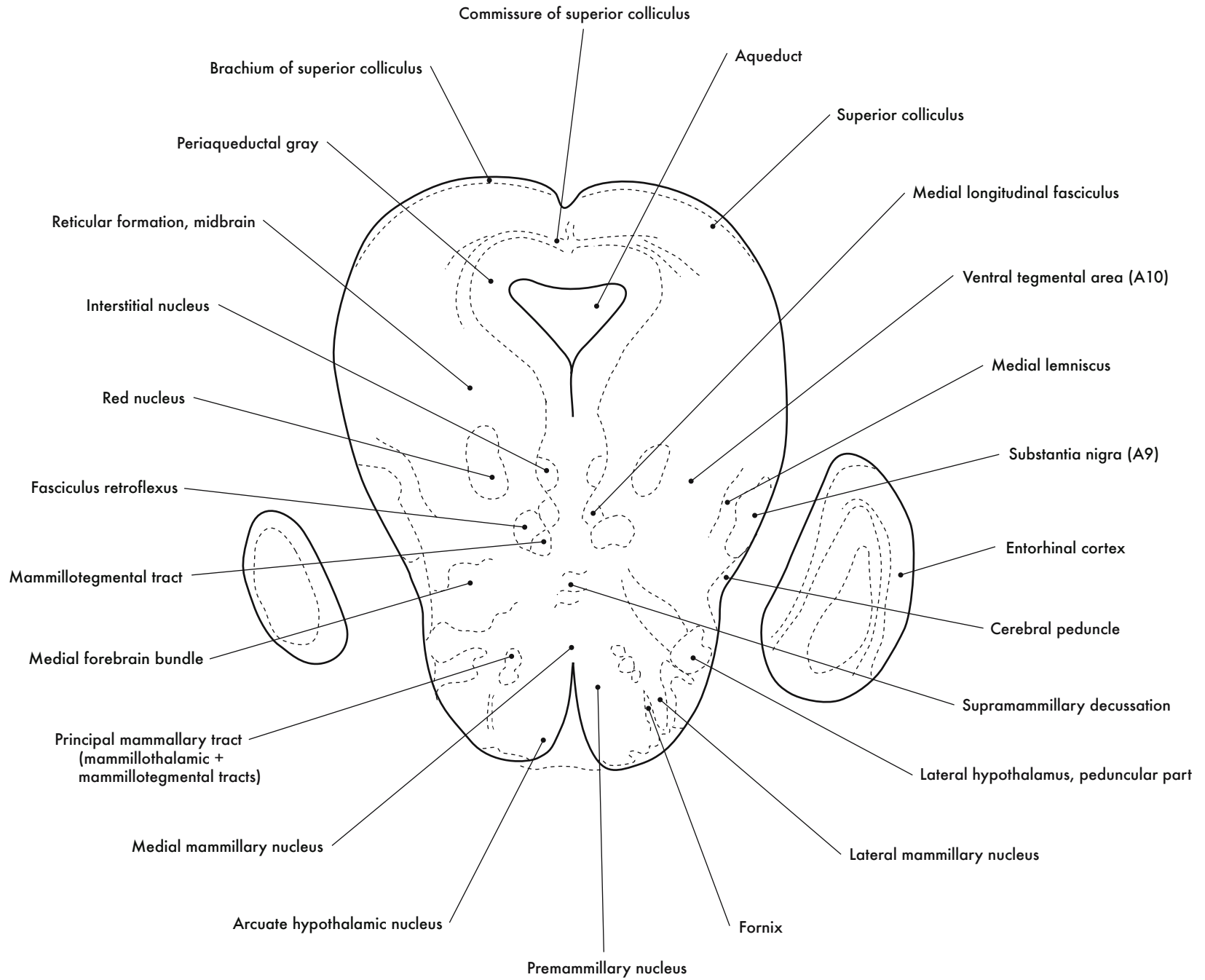
Arcuate hypothalamic nucleus

Third ventricle

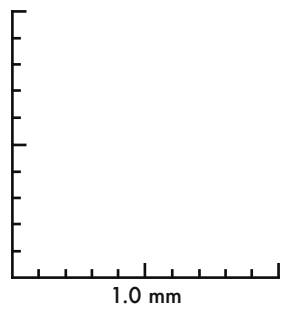
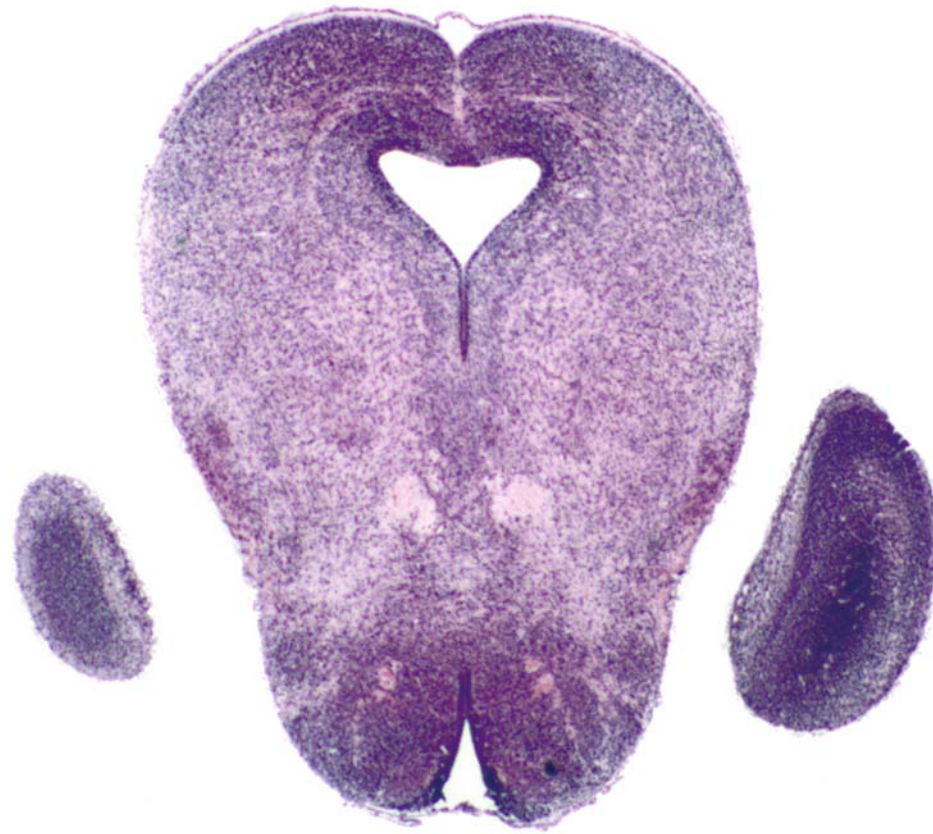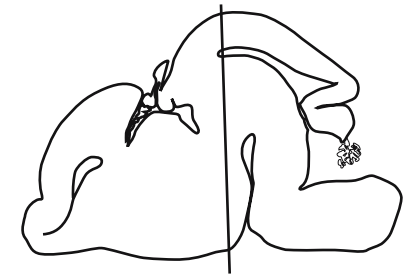
Premammillary nucleus



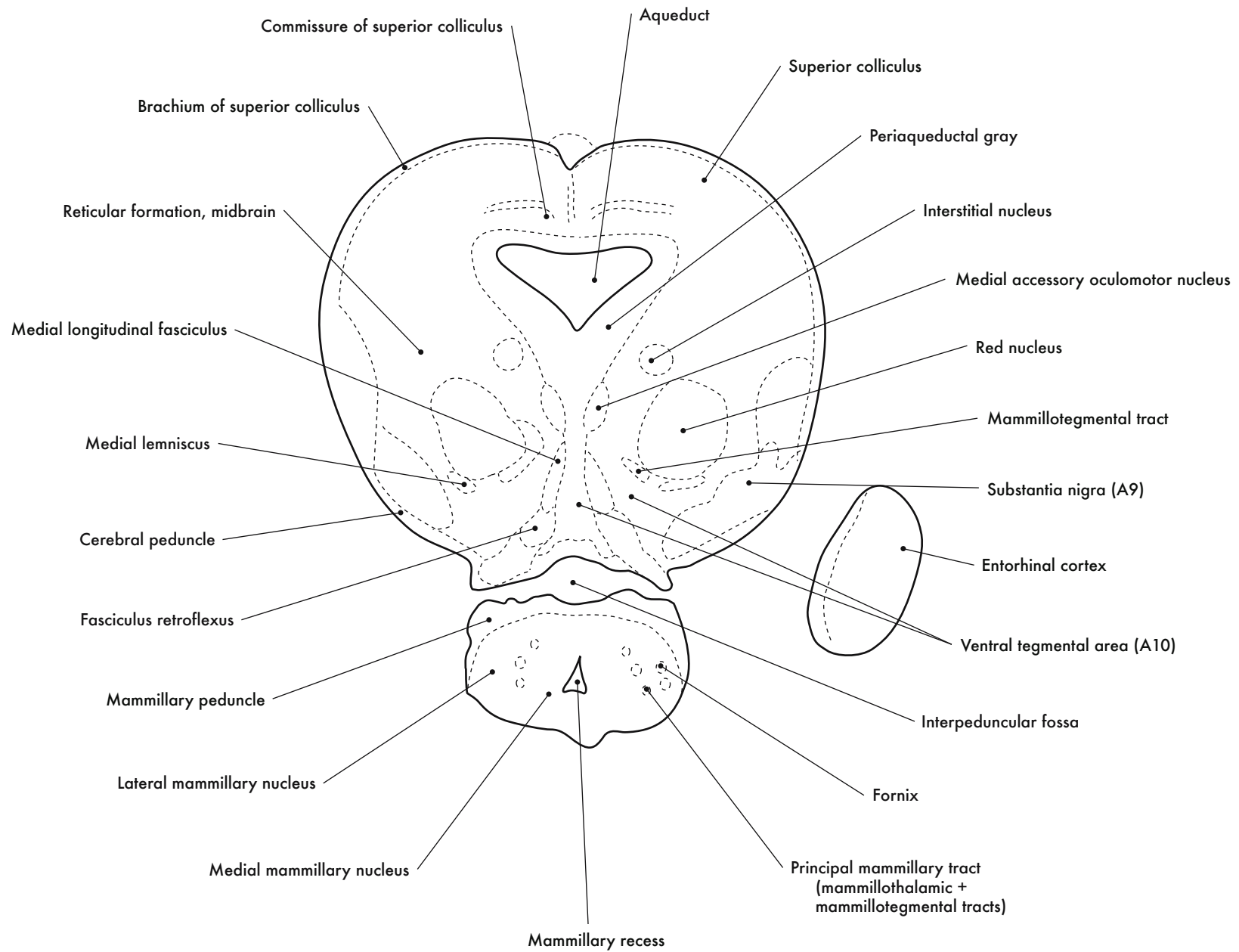
GD 16 CORONAL 21

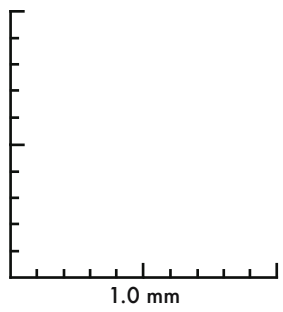
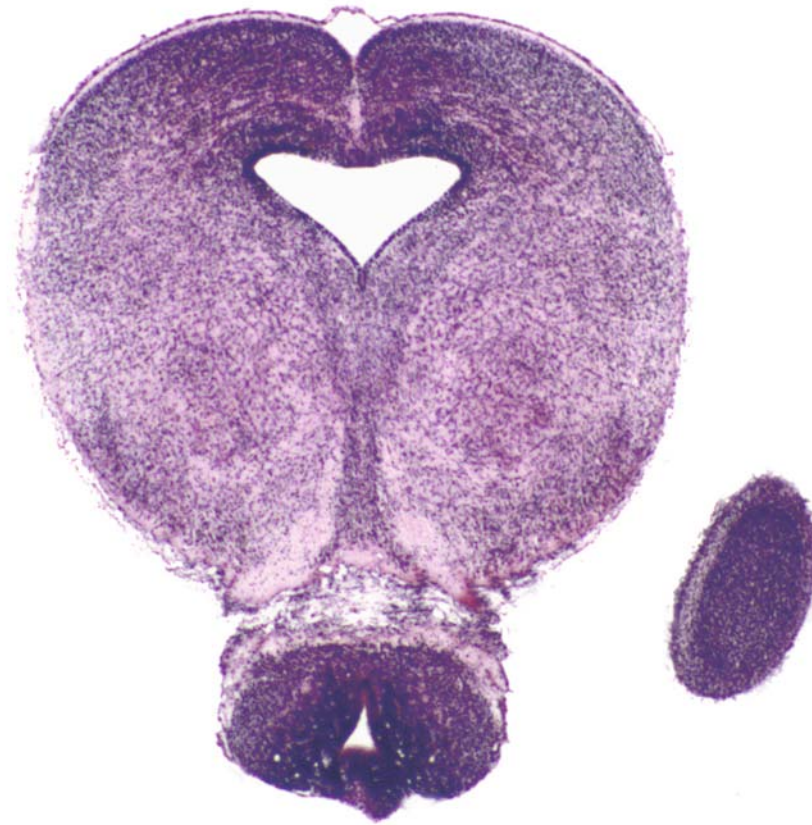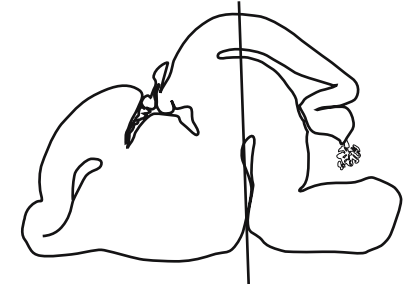




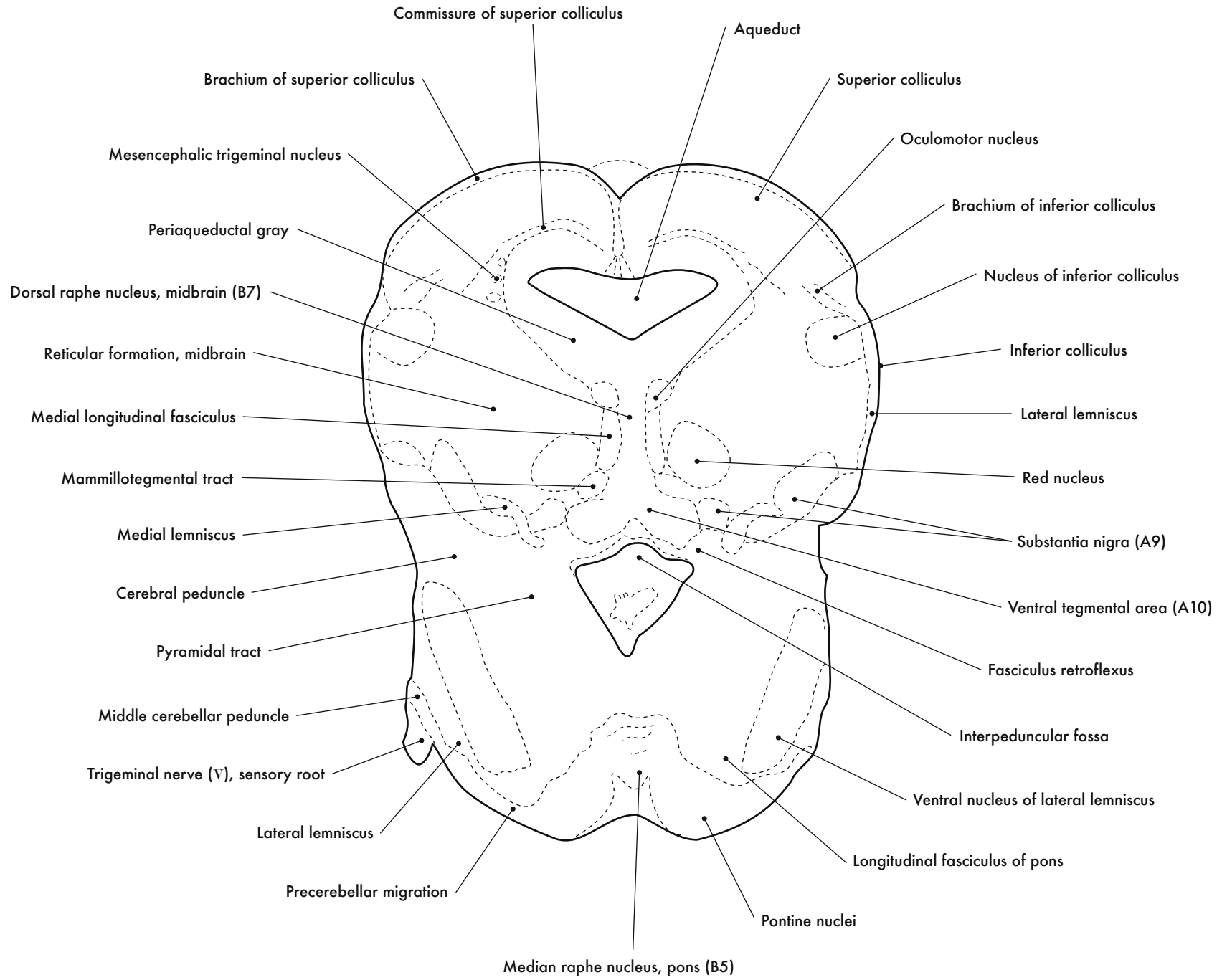


GD 16 CORONAL 22

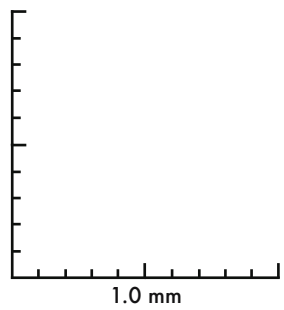
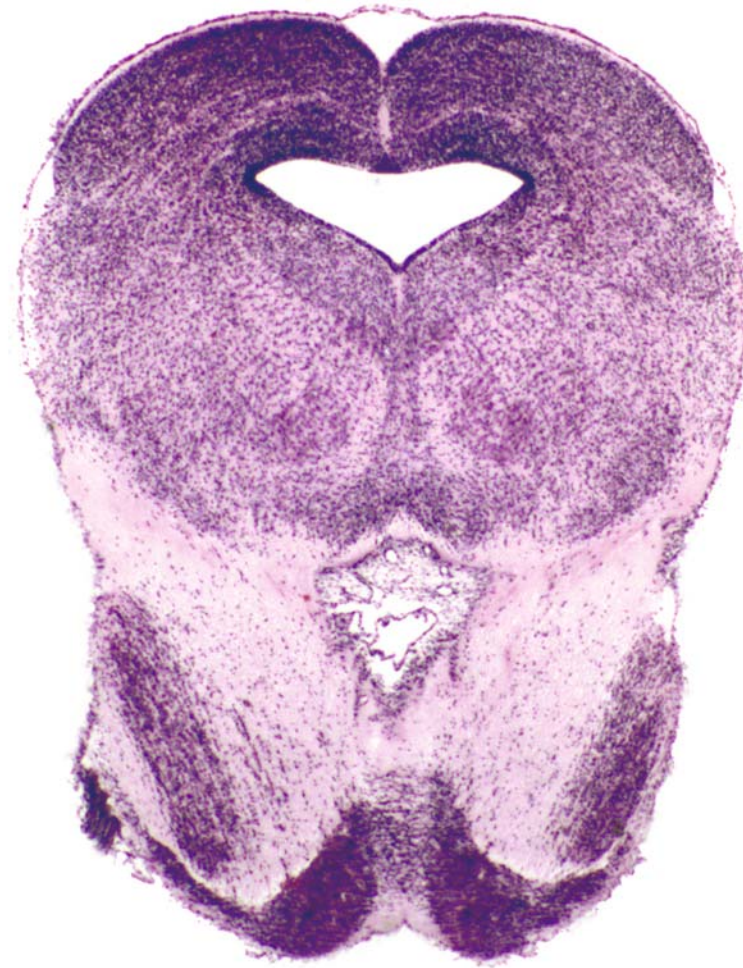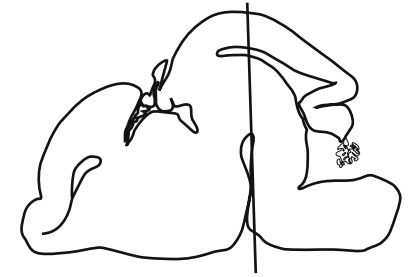




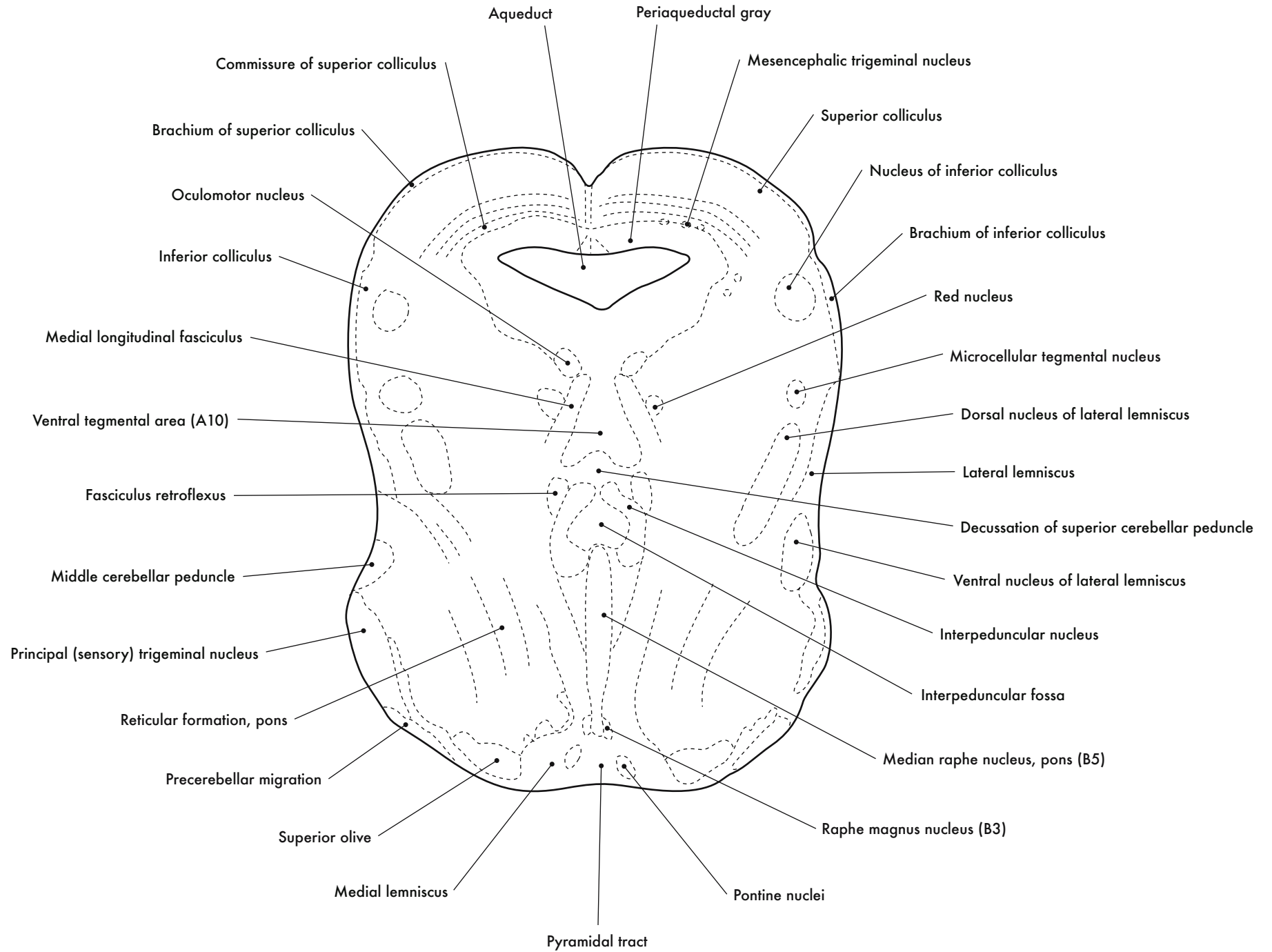
GD 16 CORONAL 23

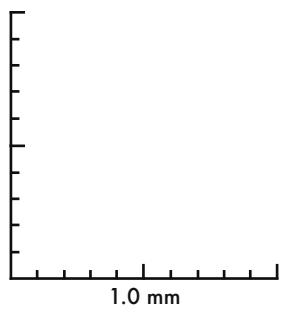
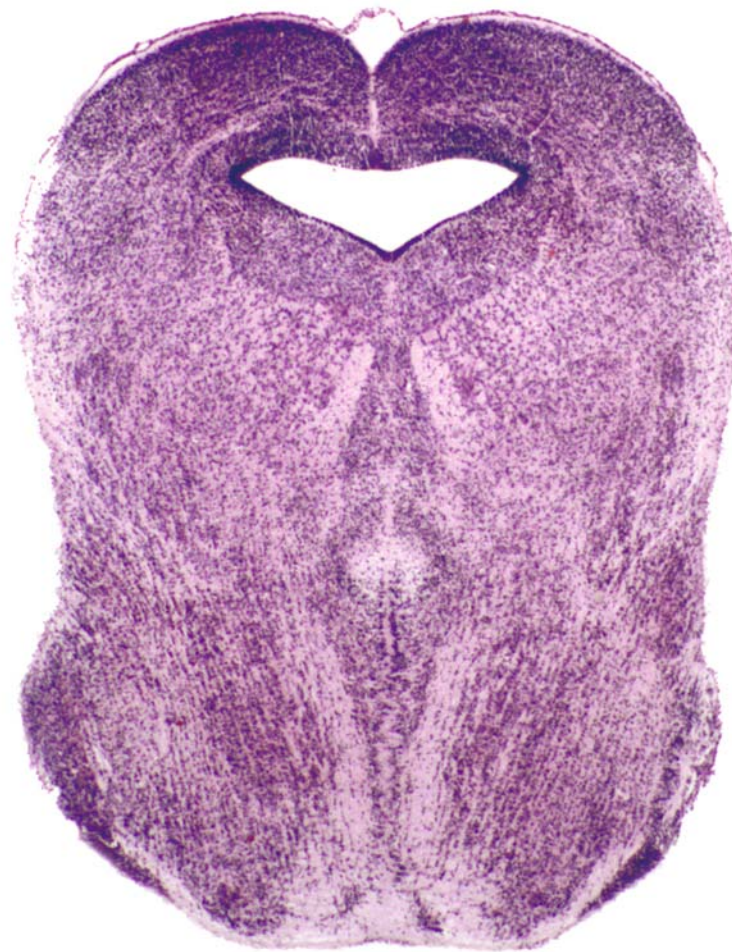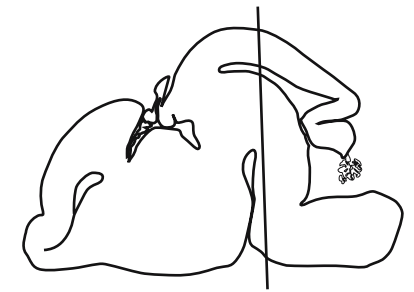




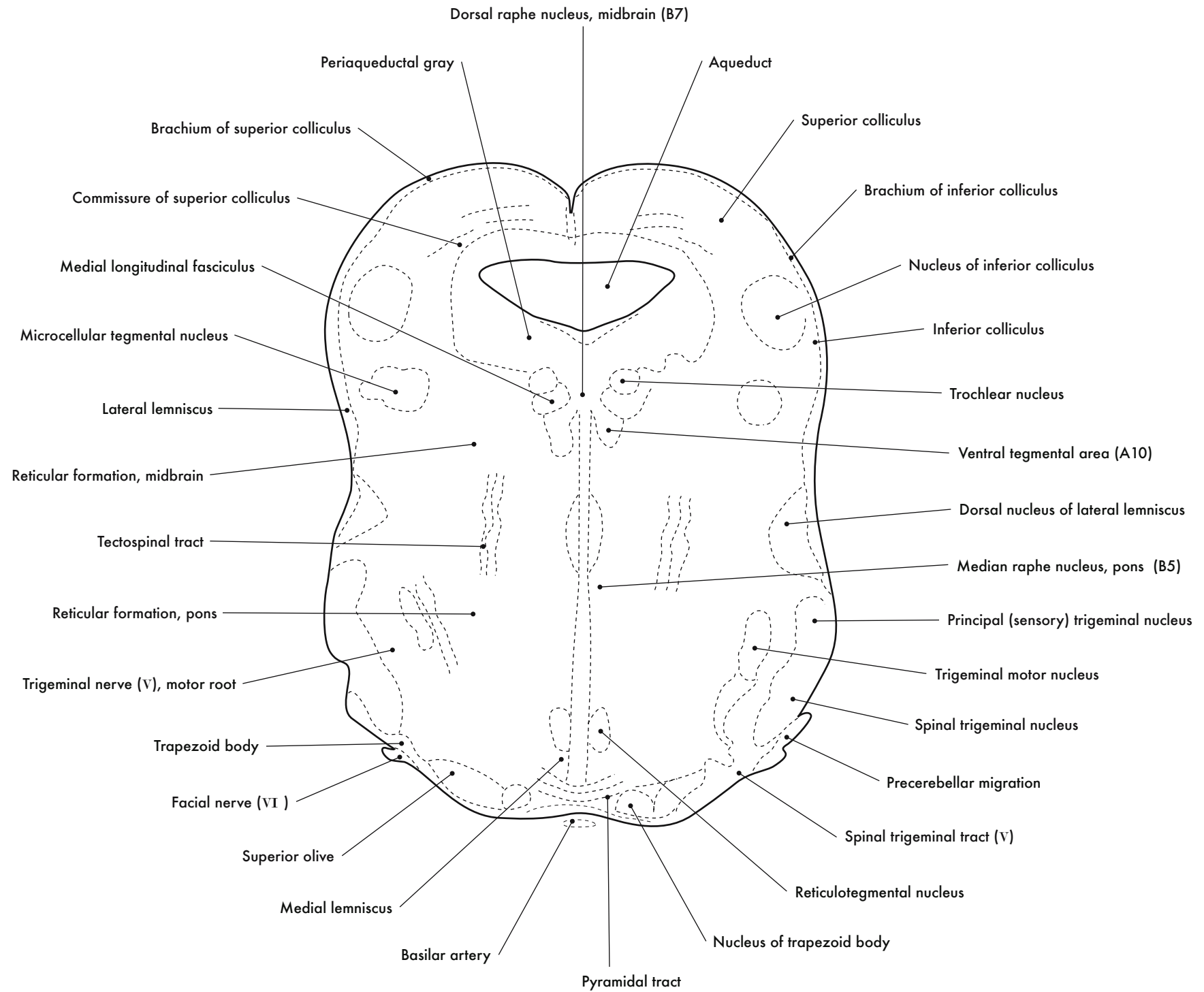


GD 16 CORONAL 24

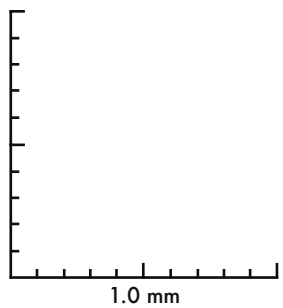
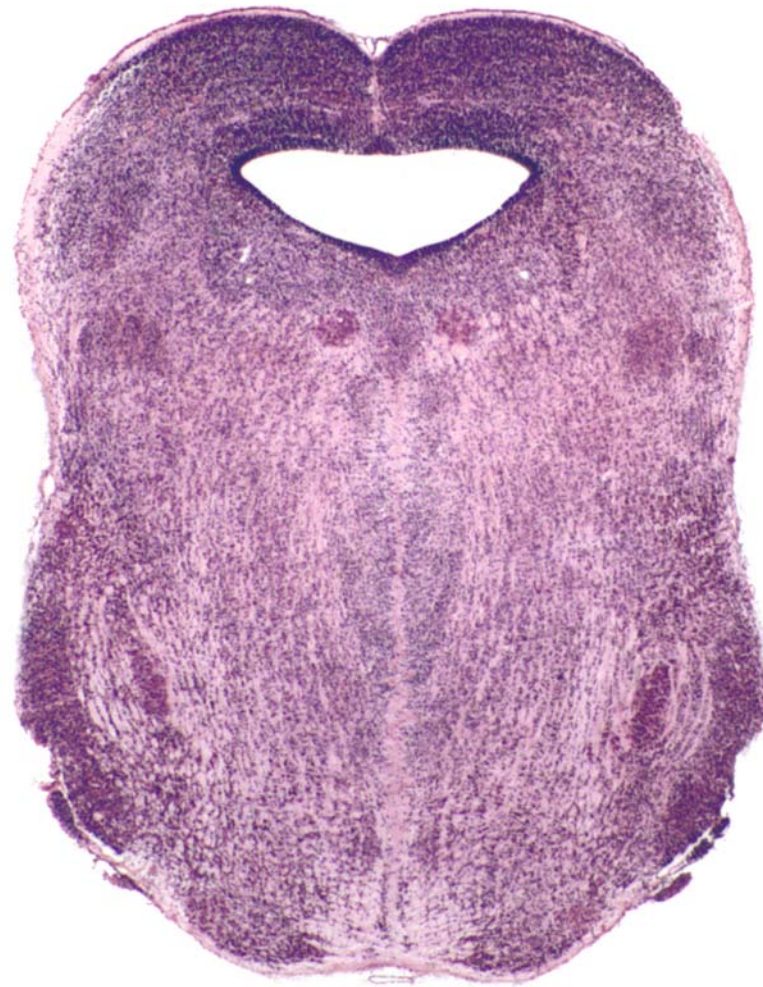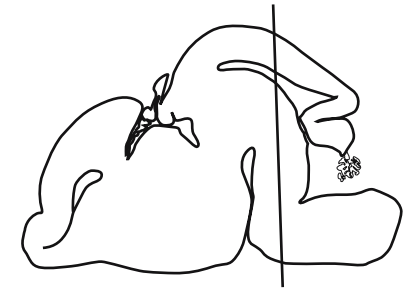




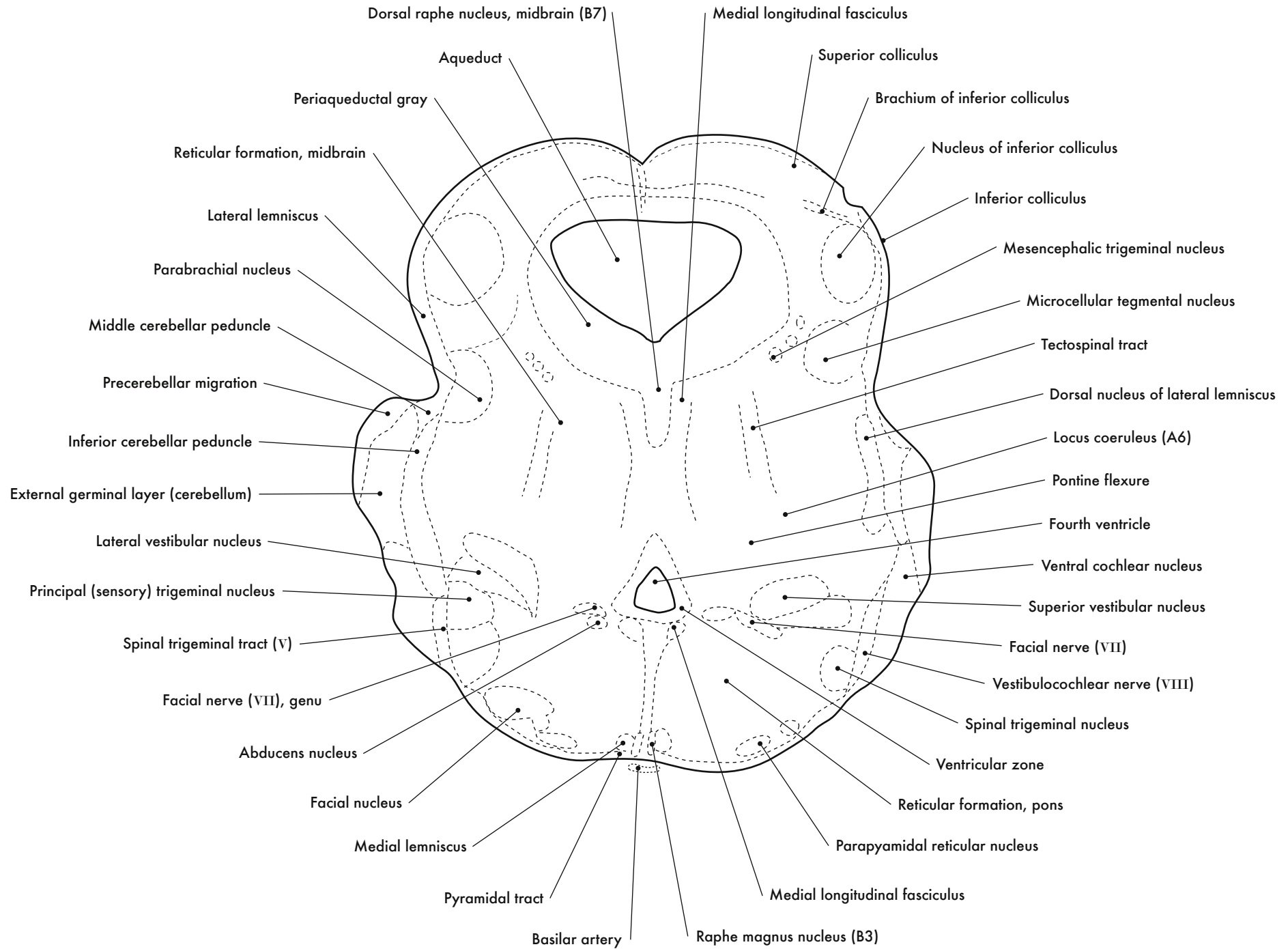
GD 16 CORONAL 25

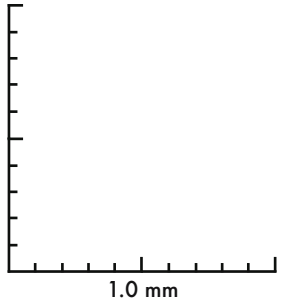
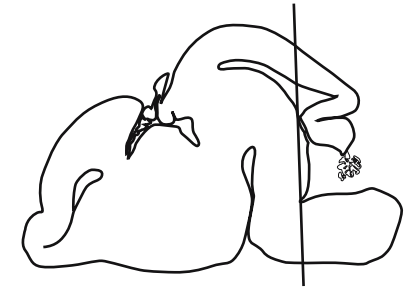
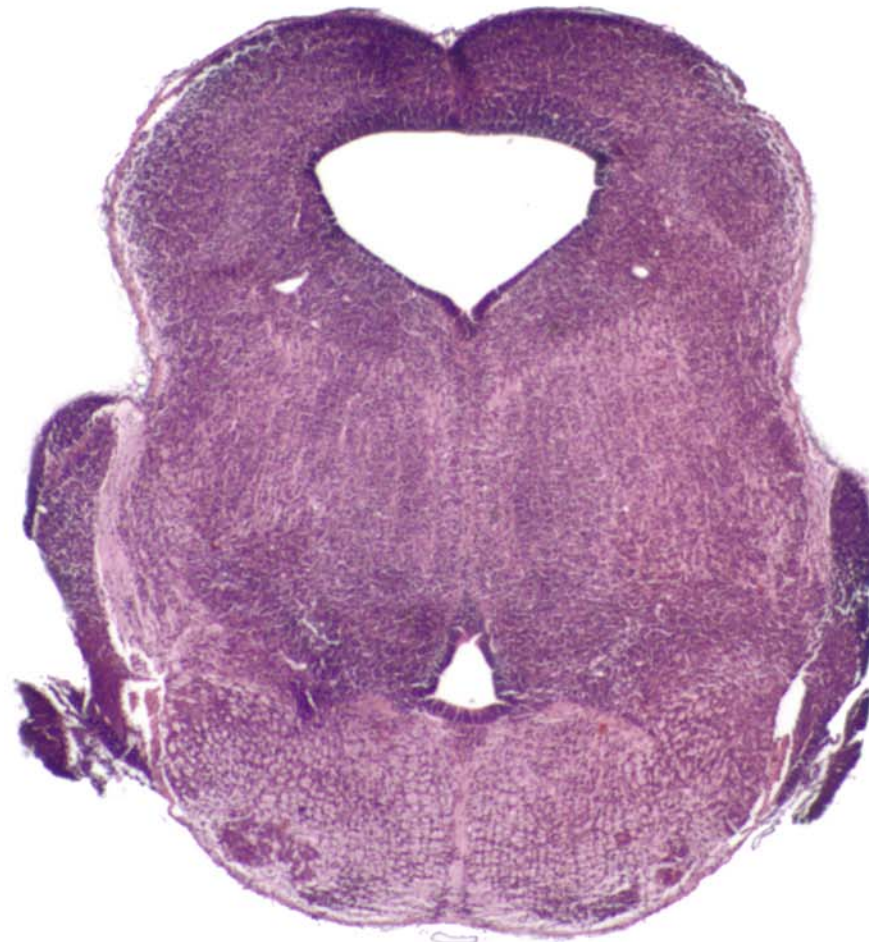




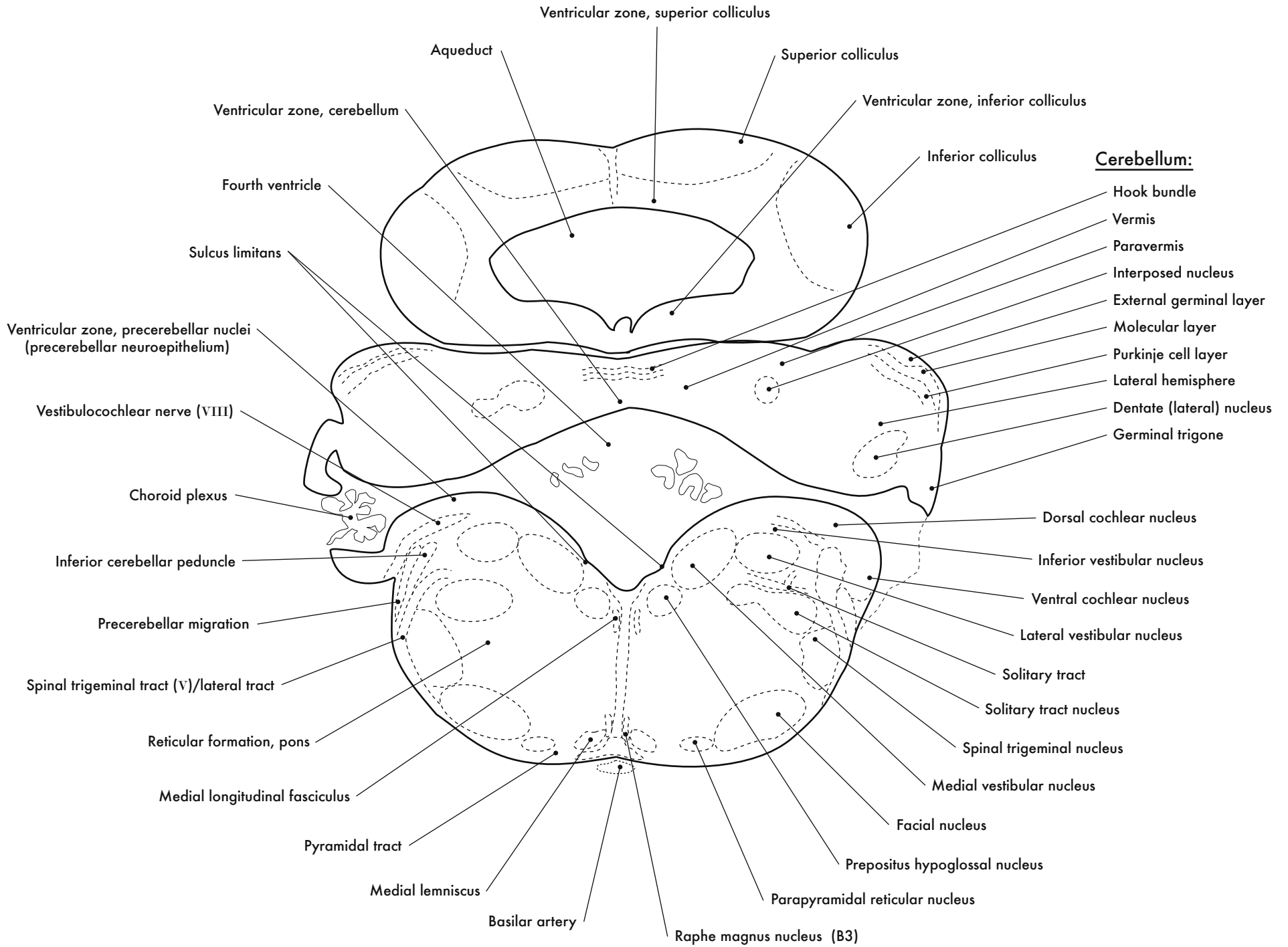


GD 16 CORONAL 26

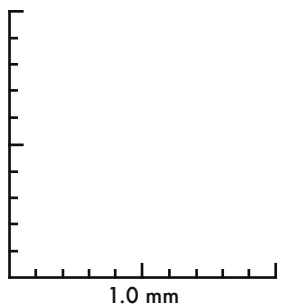
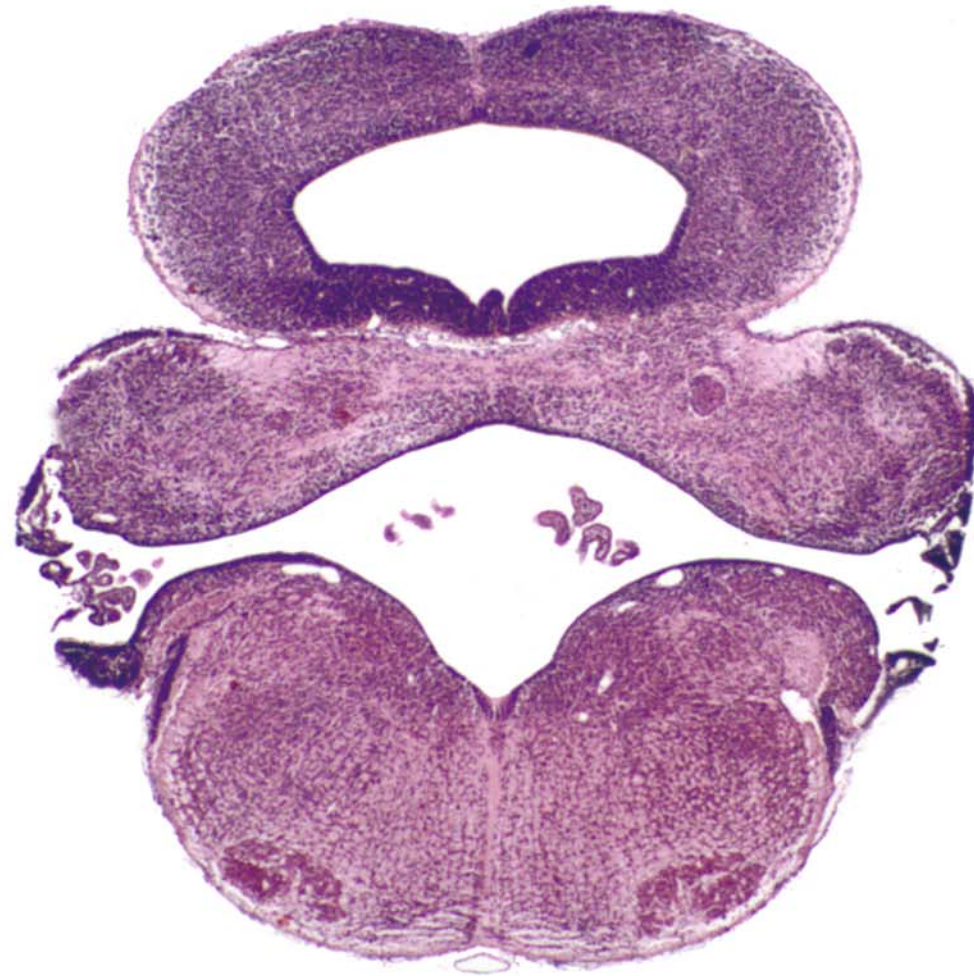
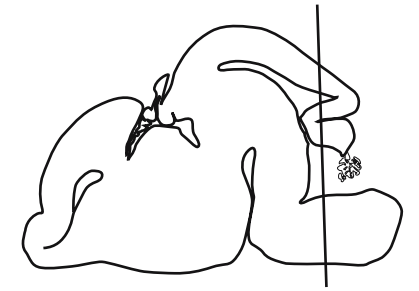




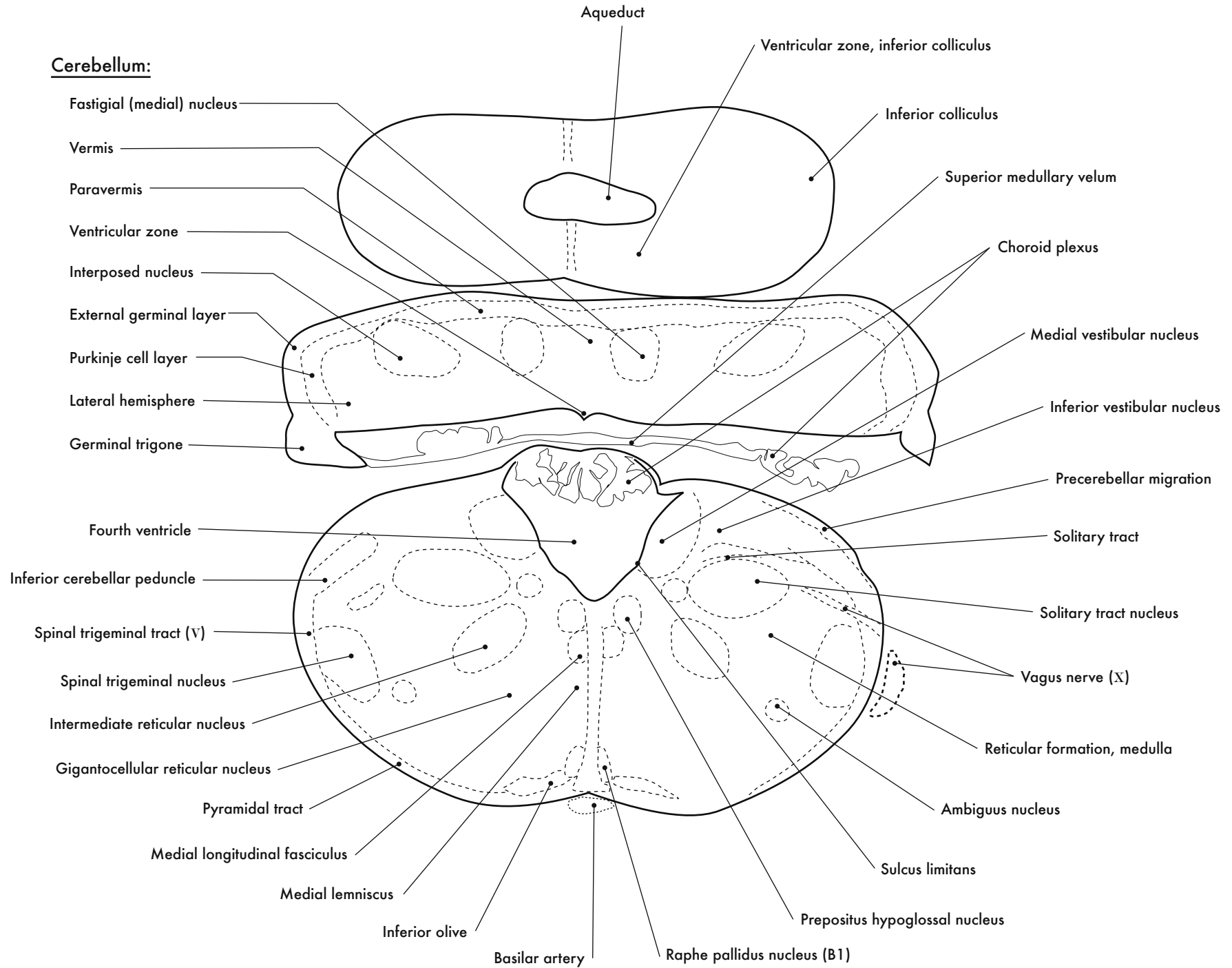
GD 16 CORONAL 27

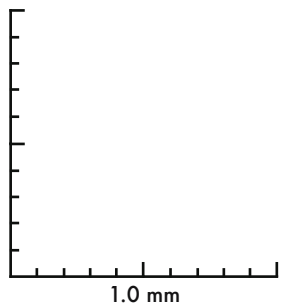
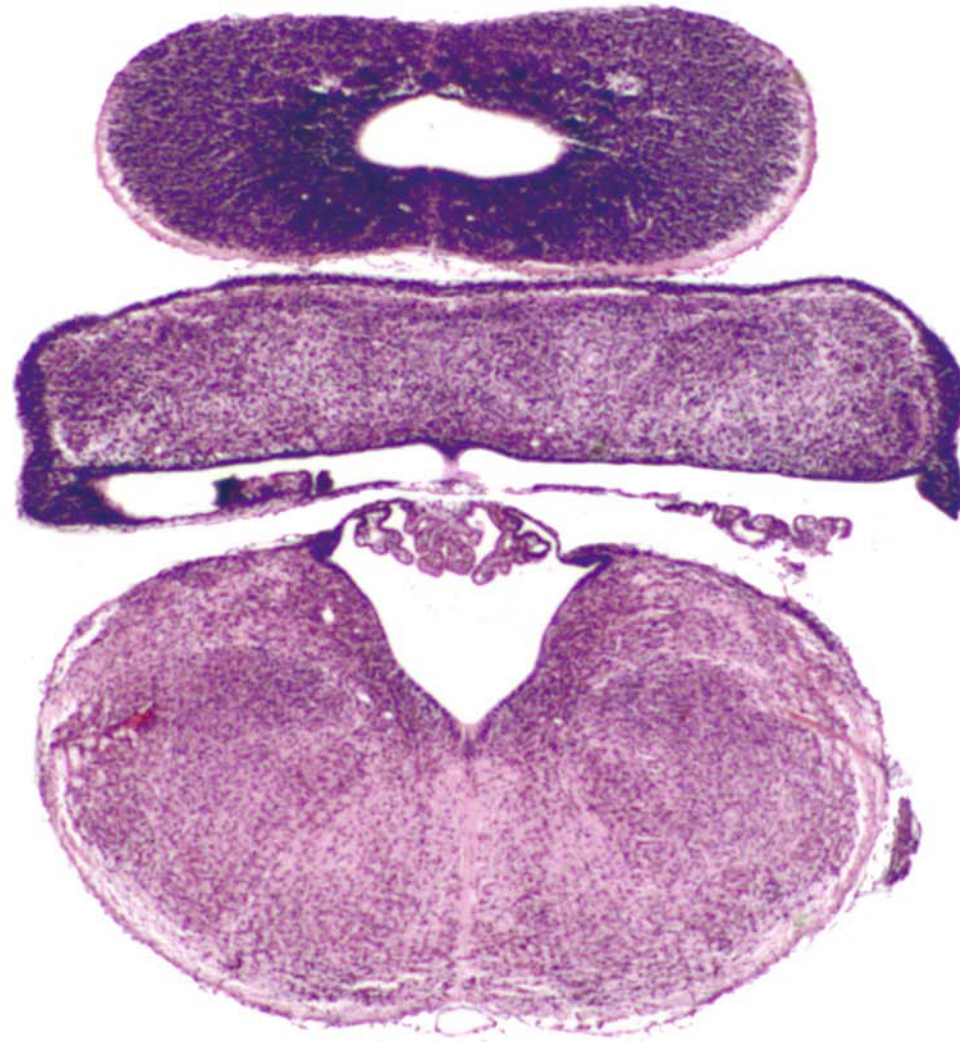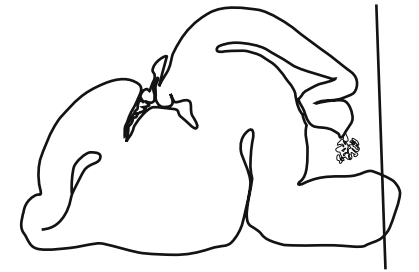




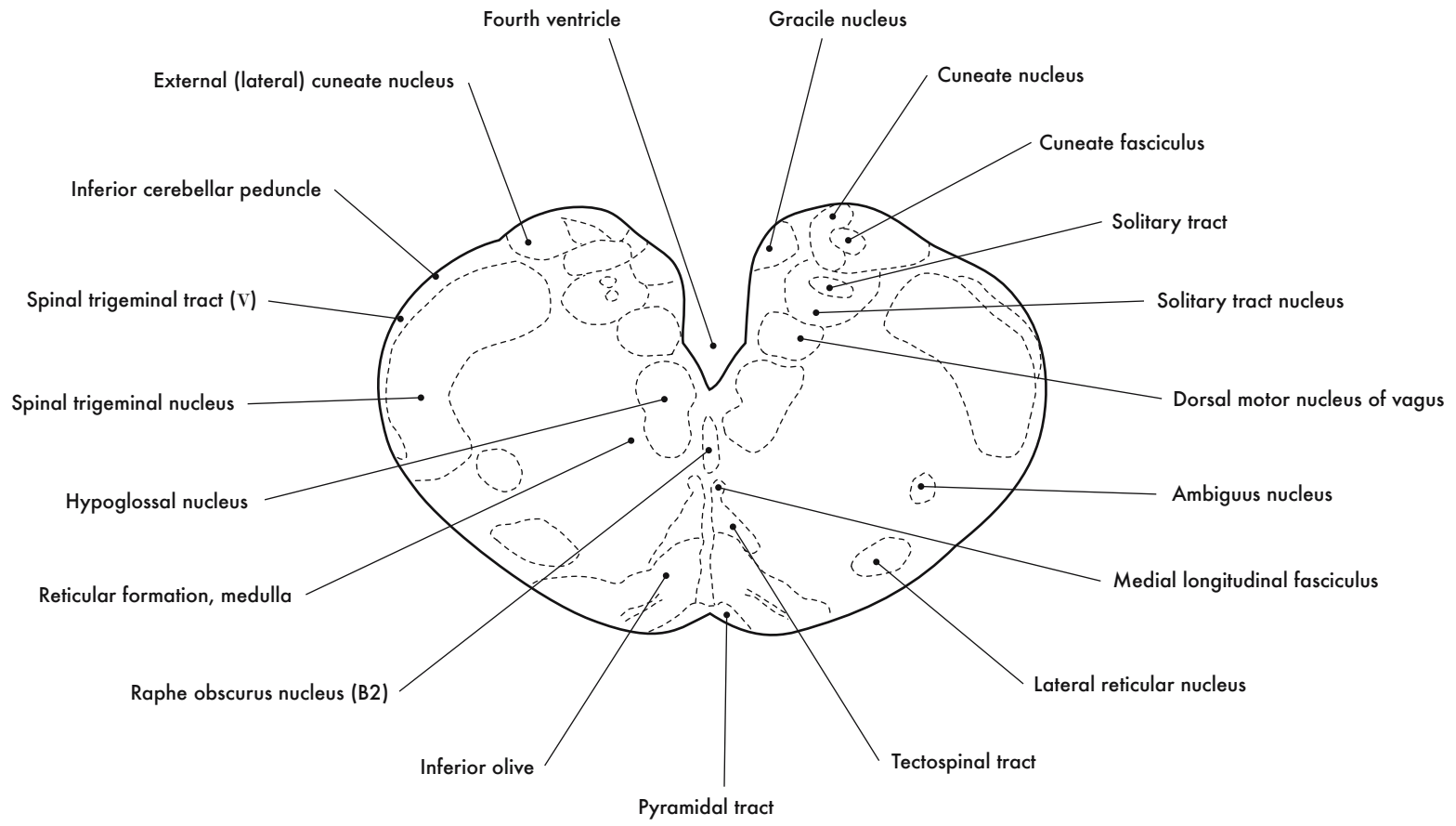


GD 16 CORONAL 28

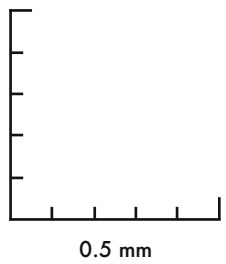
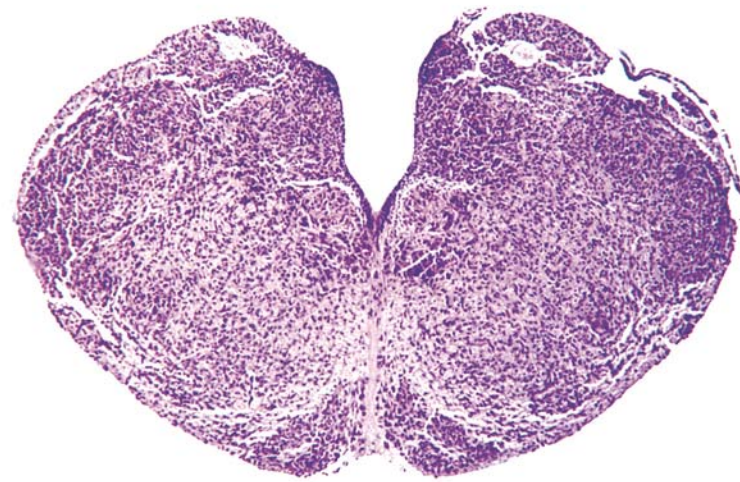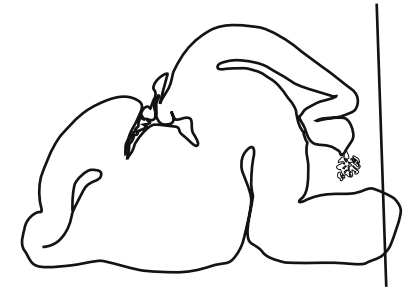




GD 16 CORONAL 29



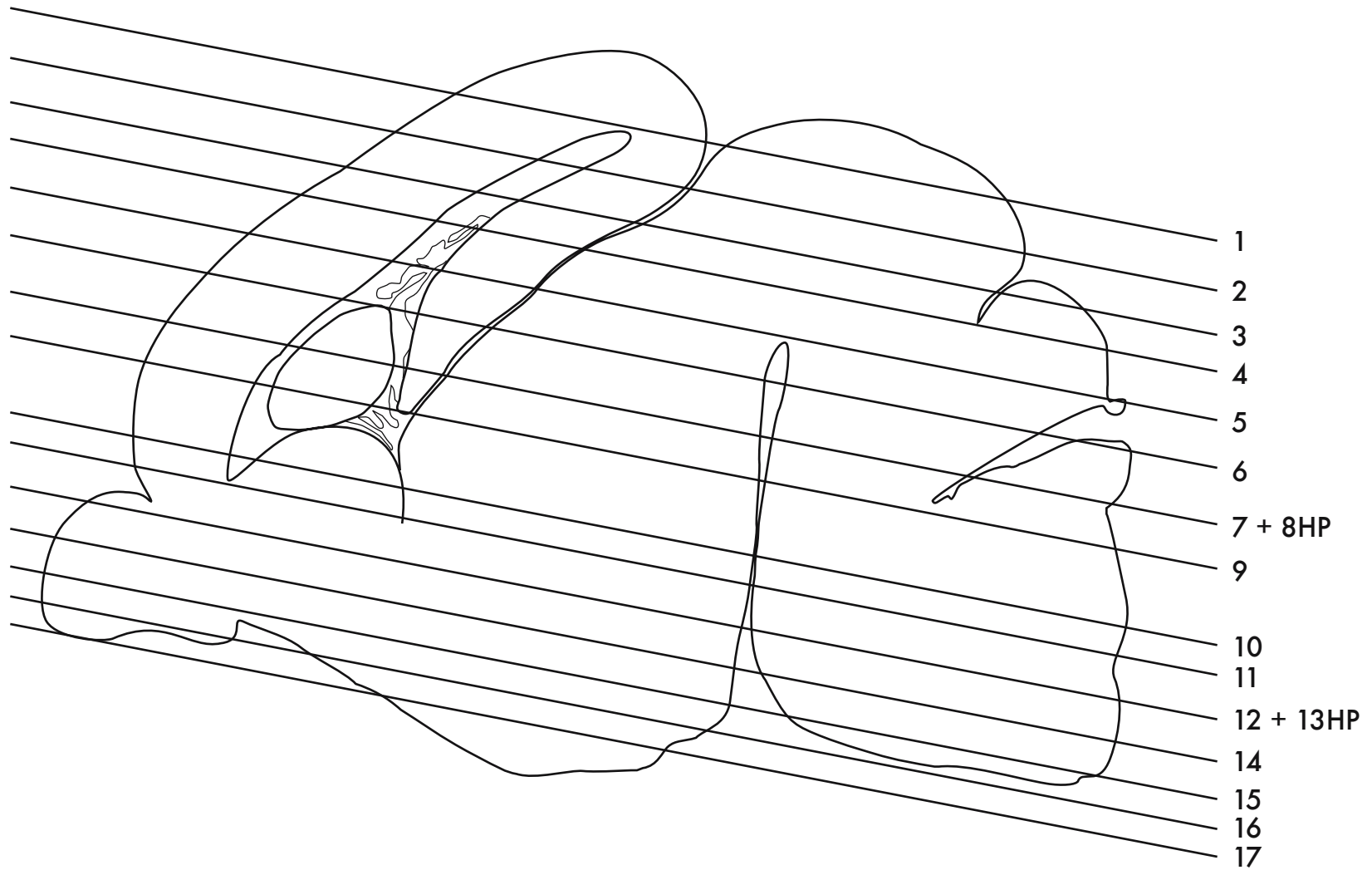




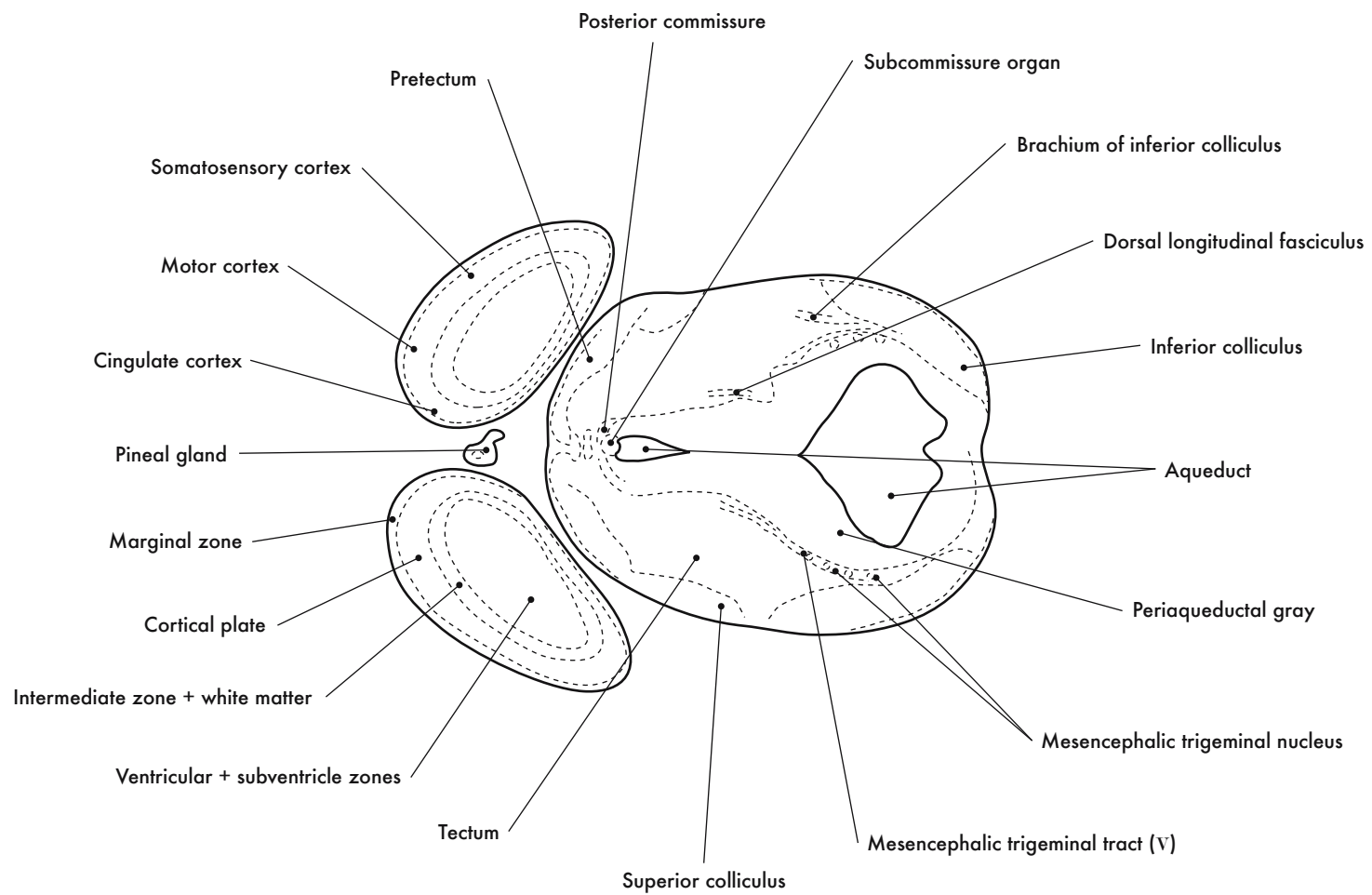
GD 16 CORONAL 30

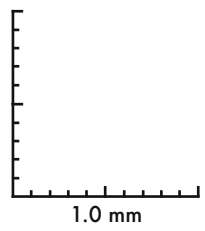
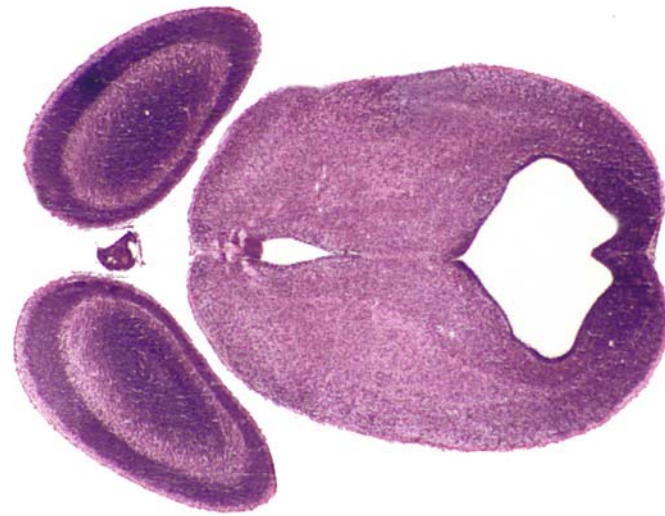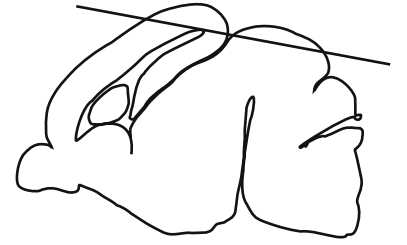
373

HP denotes image enlargement



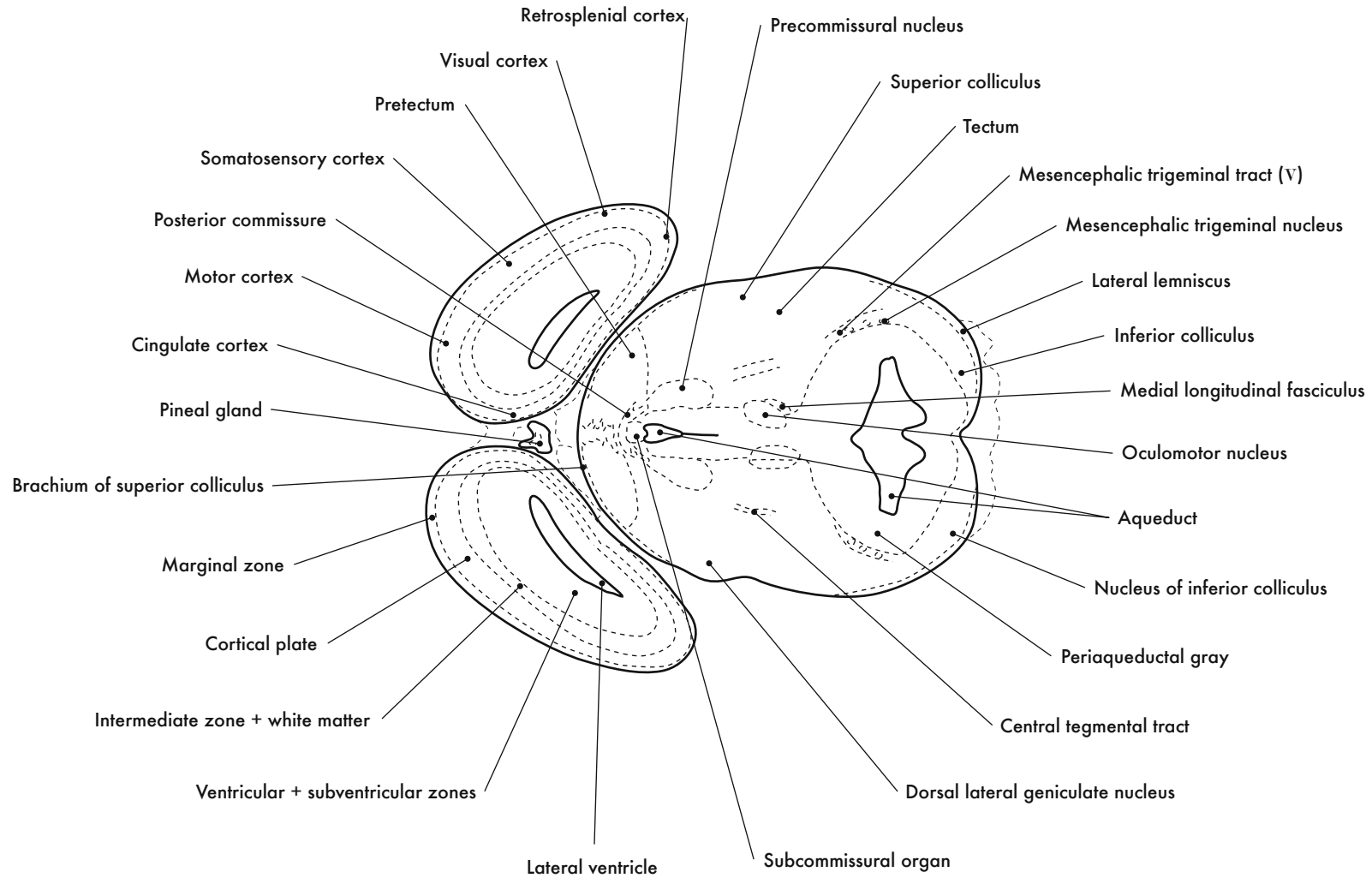
**GESTATIONAL DAY 16 (GD 16)  
HORIZONTAL SECTIONS**

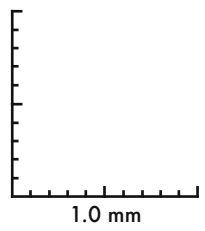
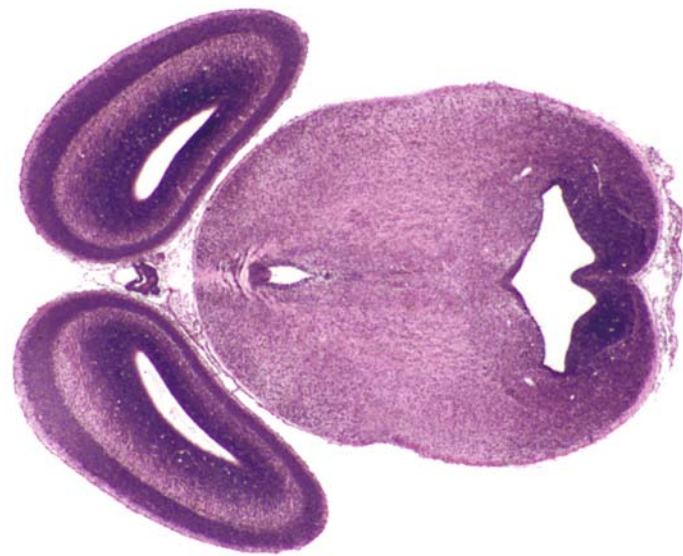




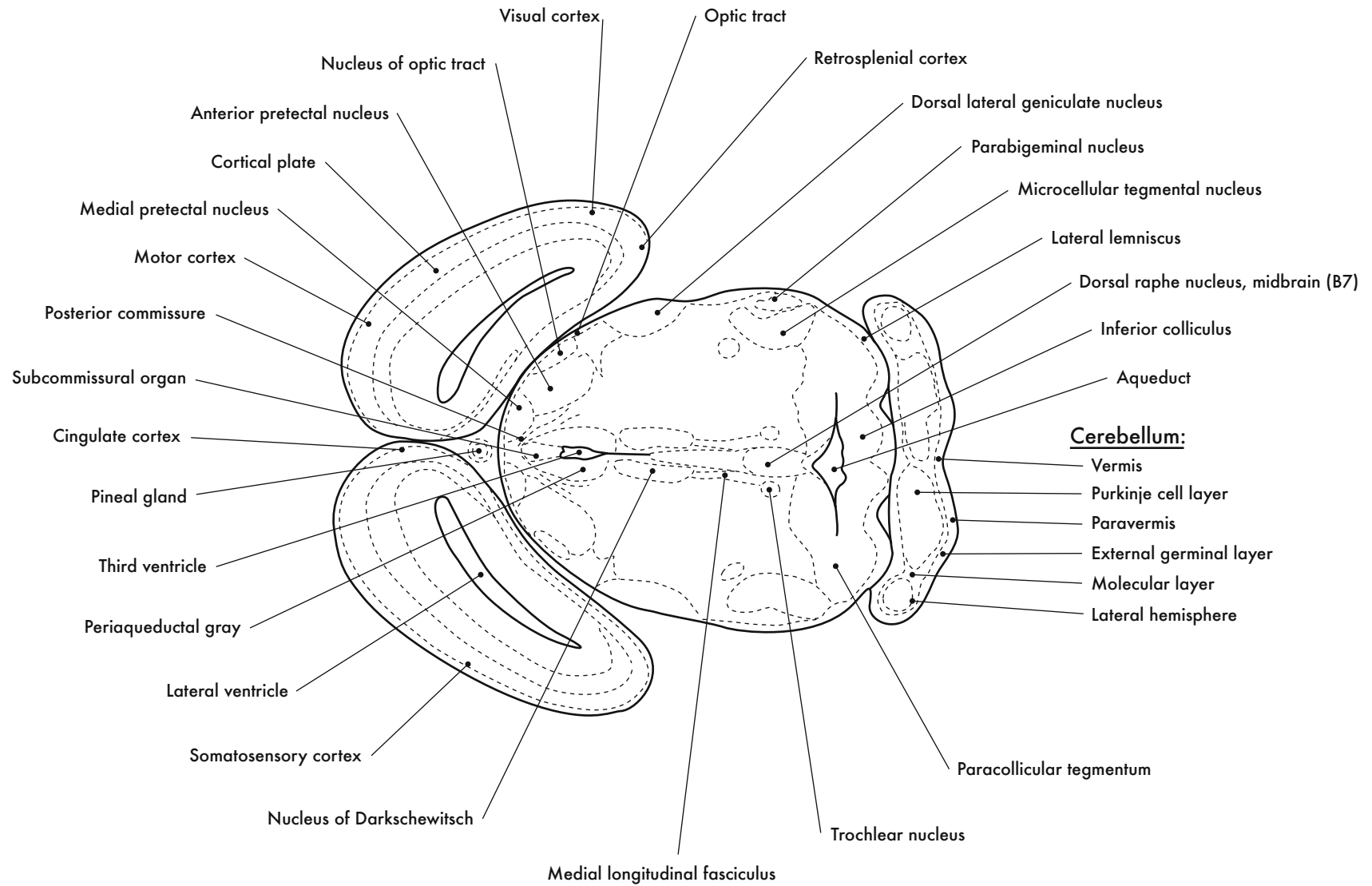
GD 16 HORIZONTAL 1

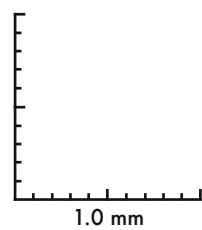
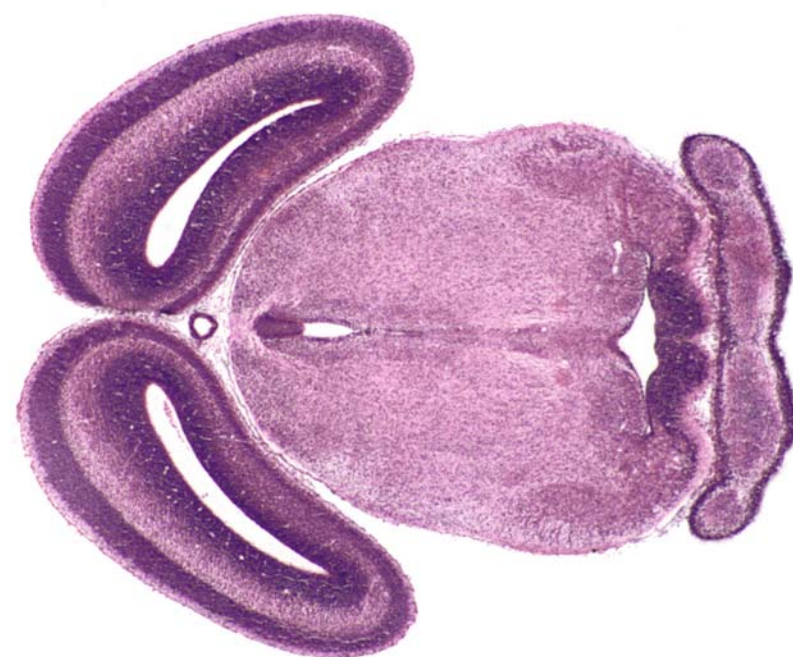







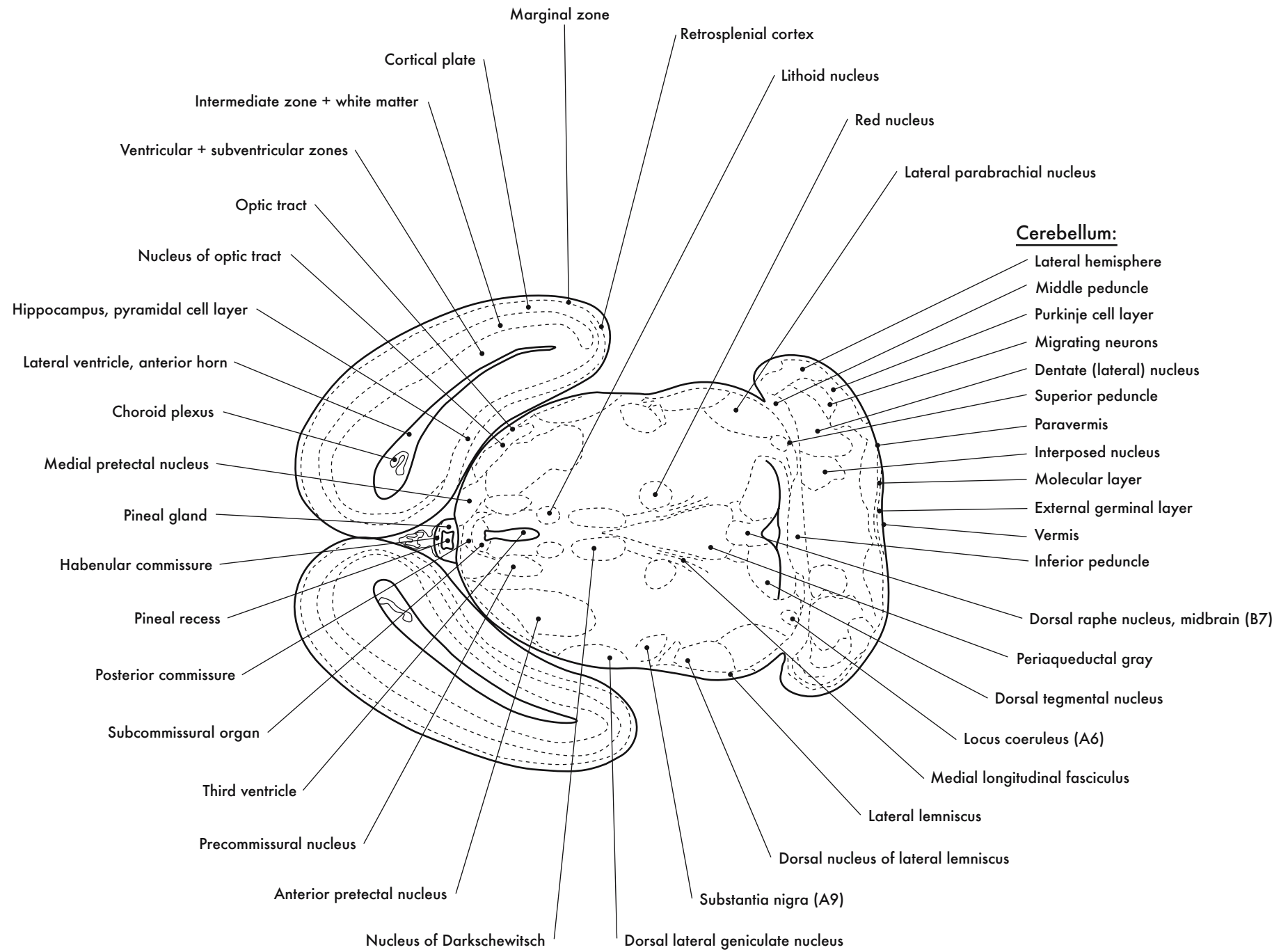
GD 16 HORIZONTAL 2

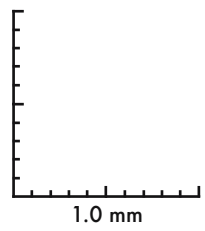
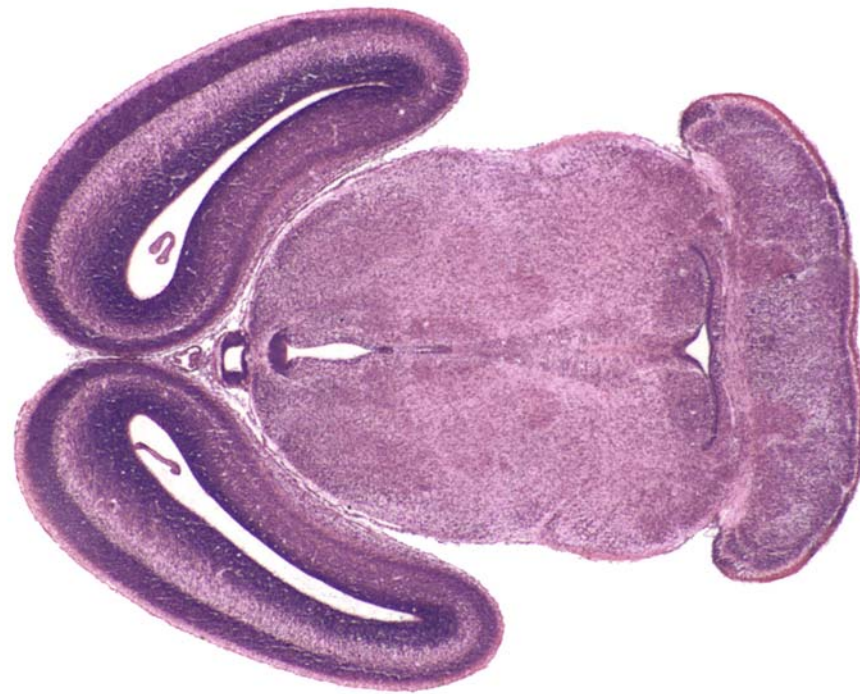




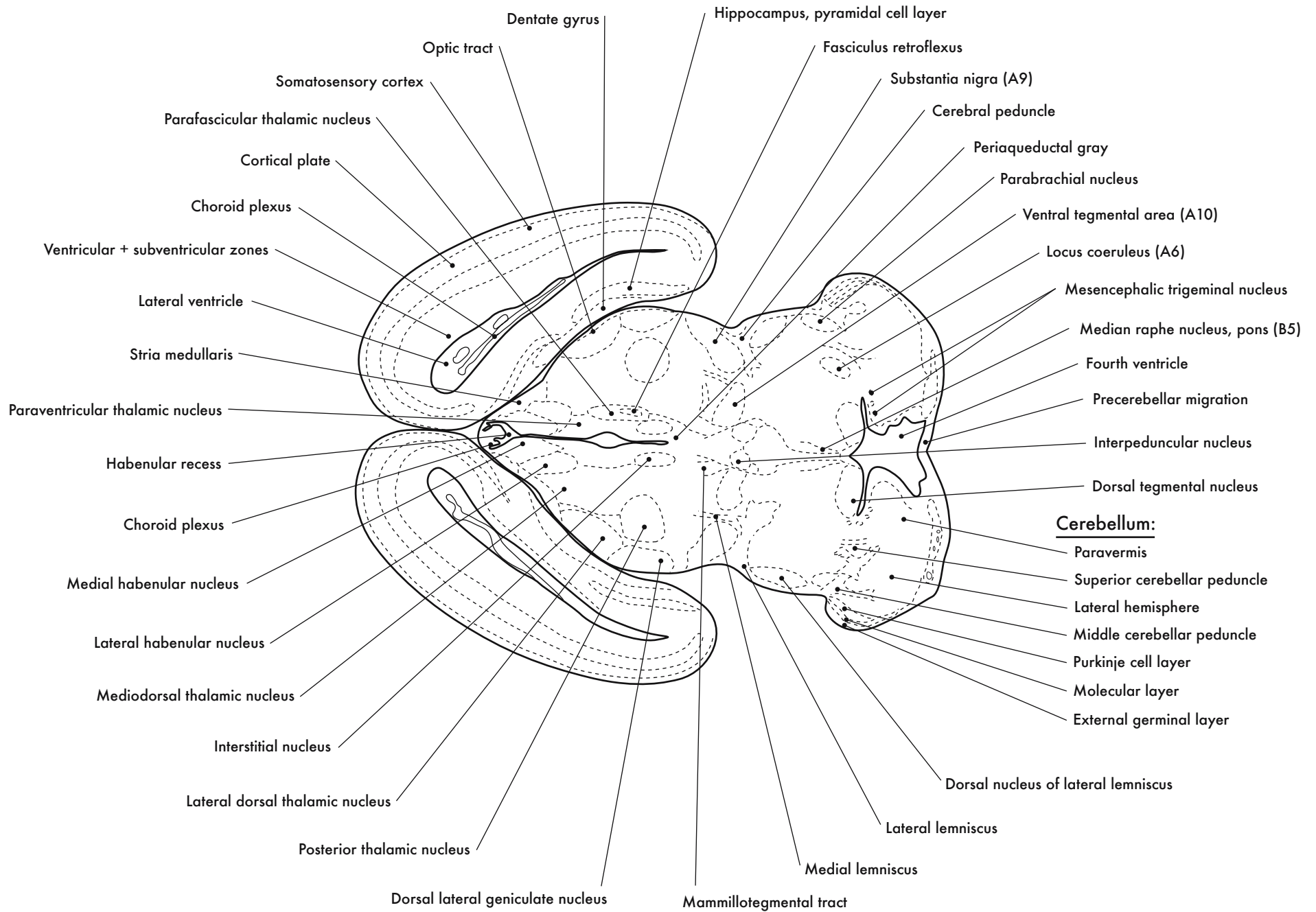
GD 16 HORIZONTAL 3

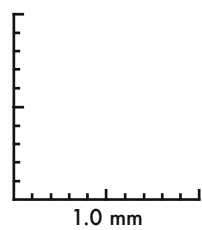
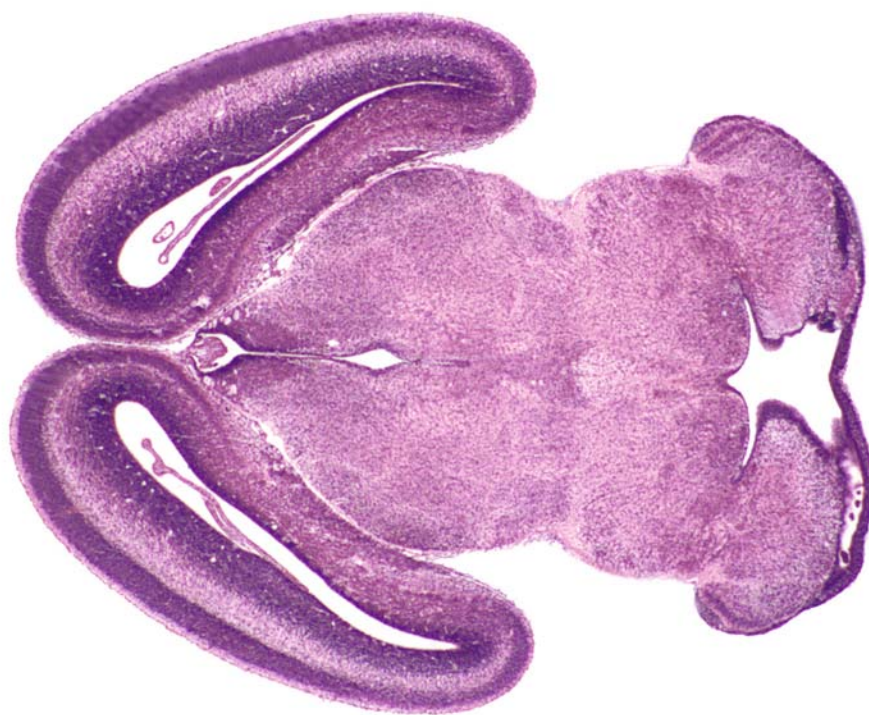






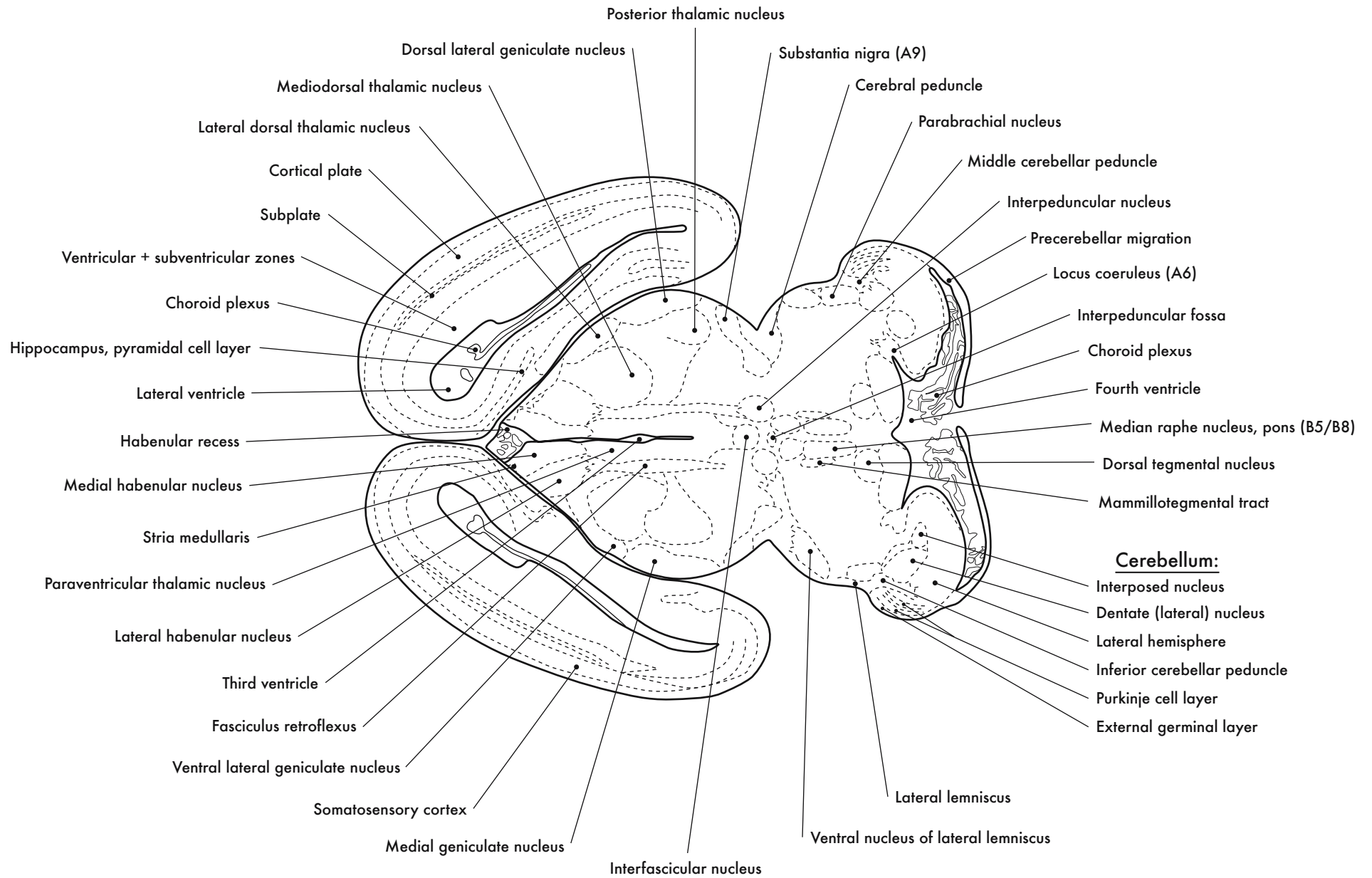
GD 16 HORIZONTAL 4

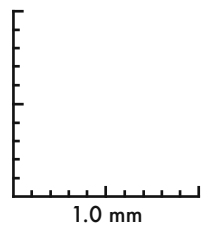
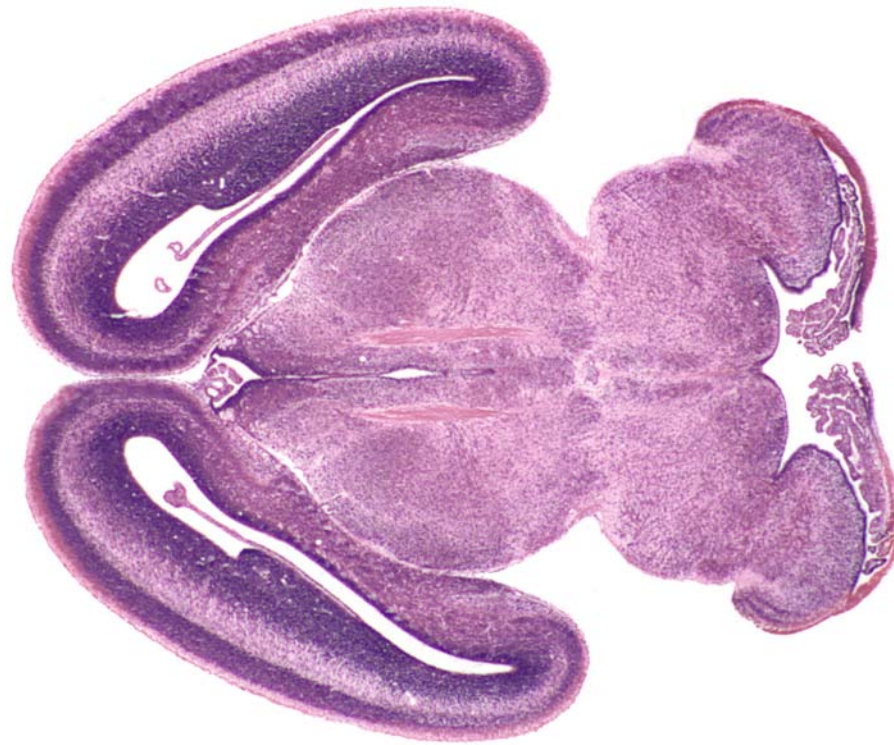




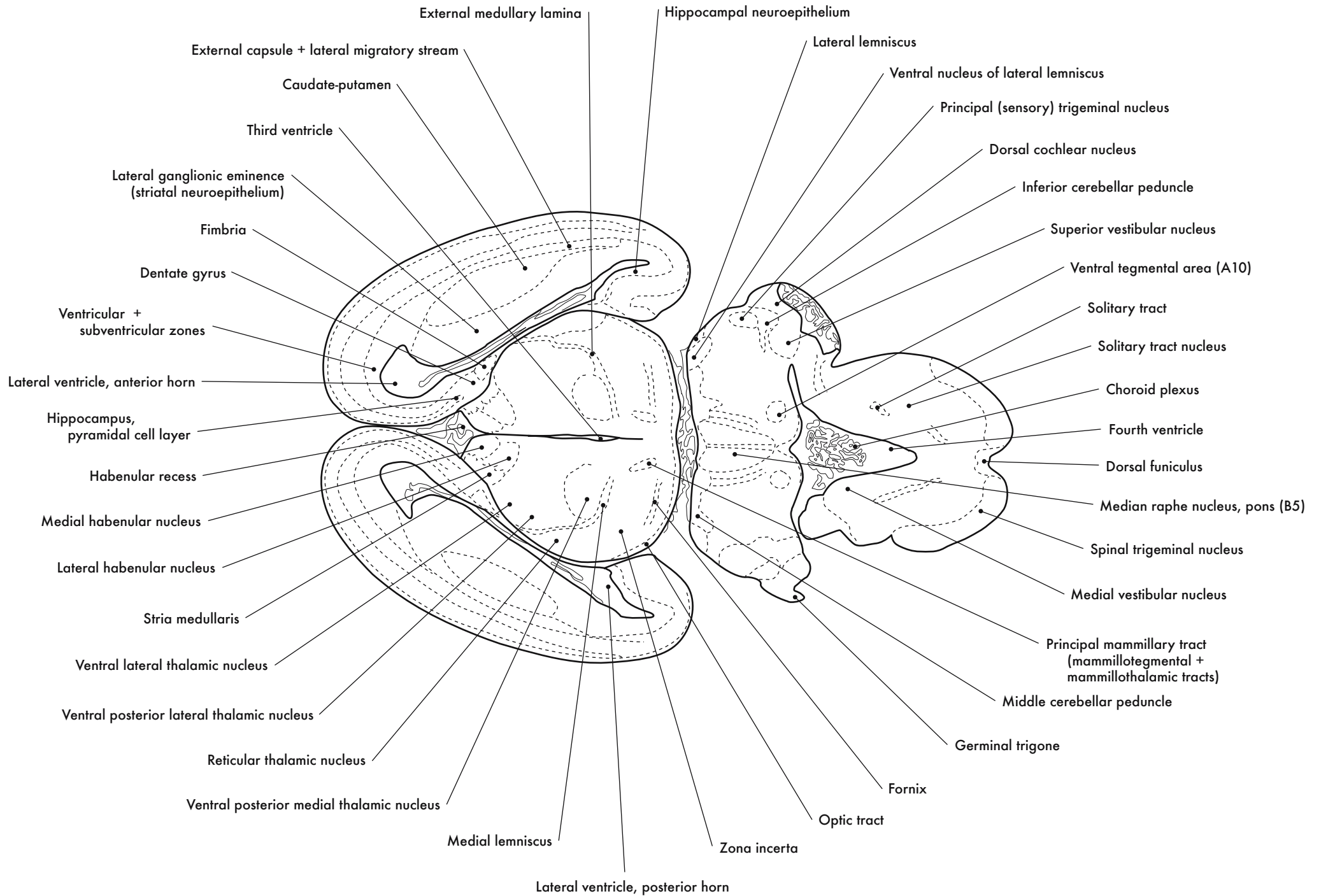
GD 16 HORIZONTAL 5

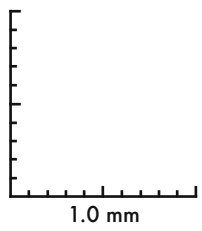
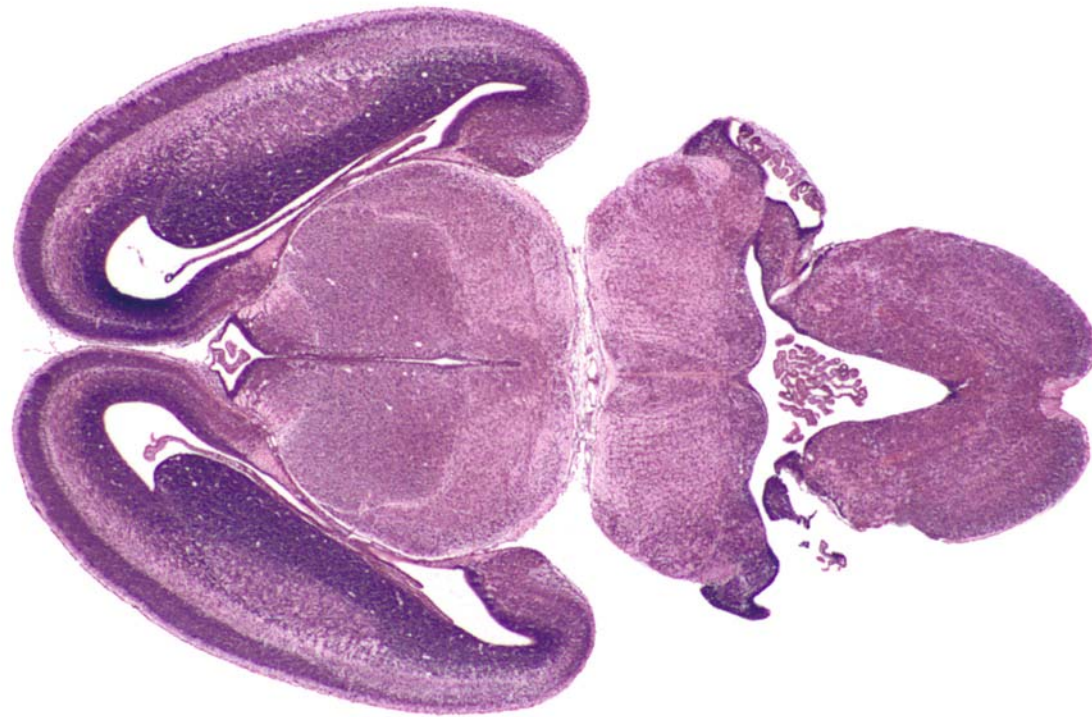







GD 16 HORIZONTAL 6

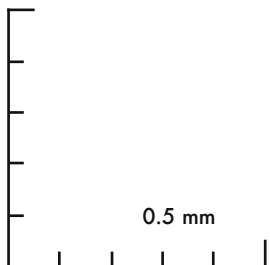
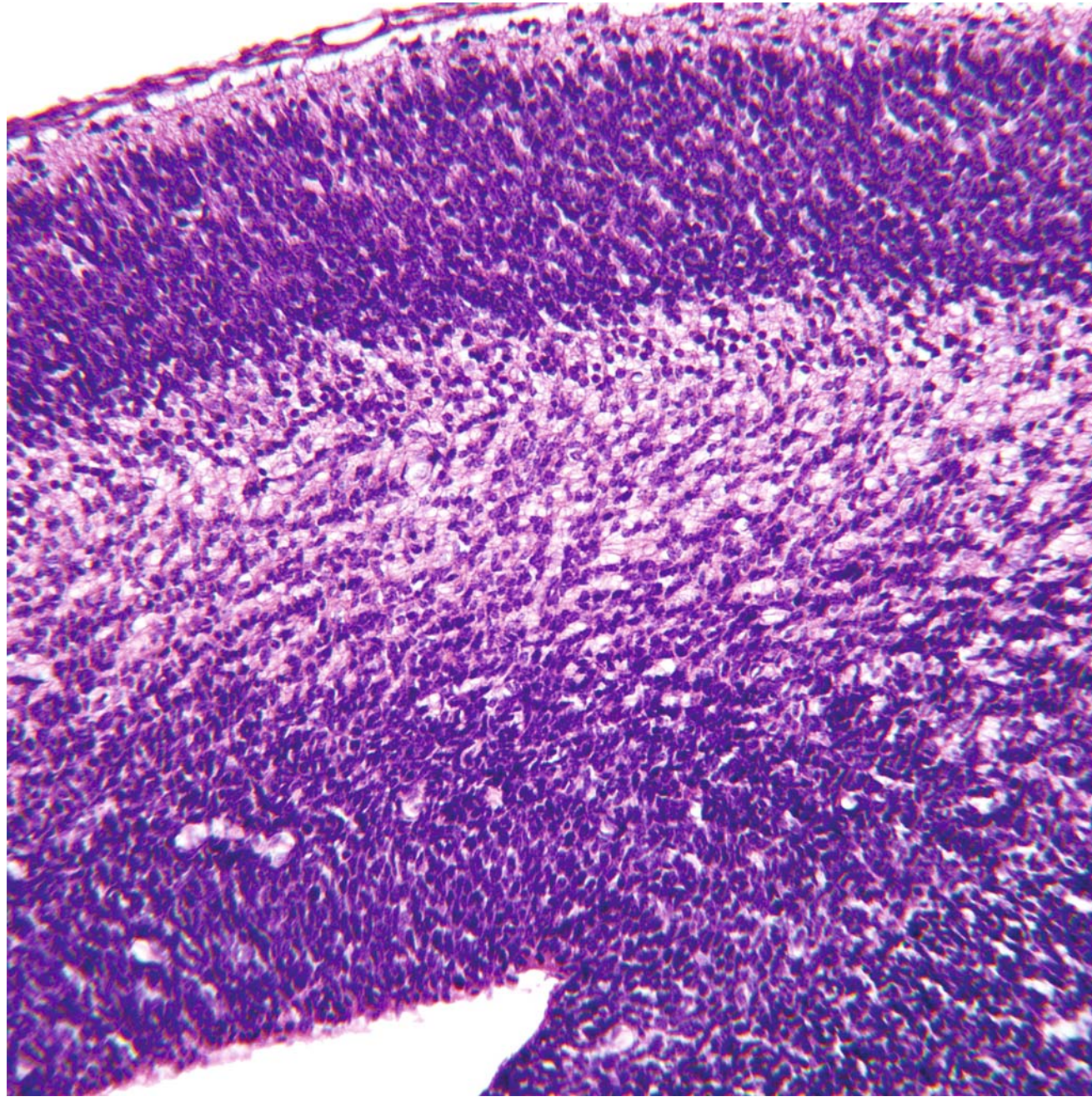
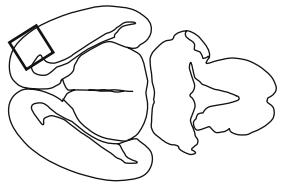




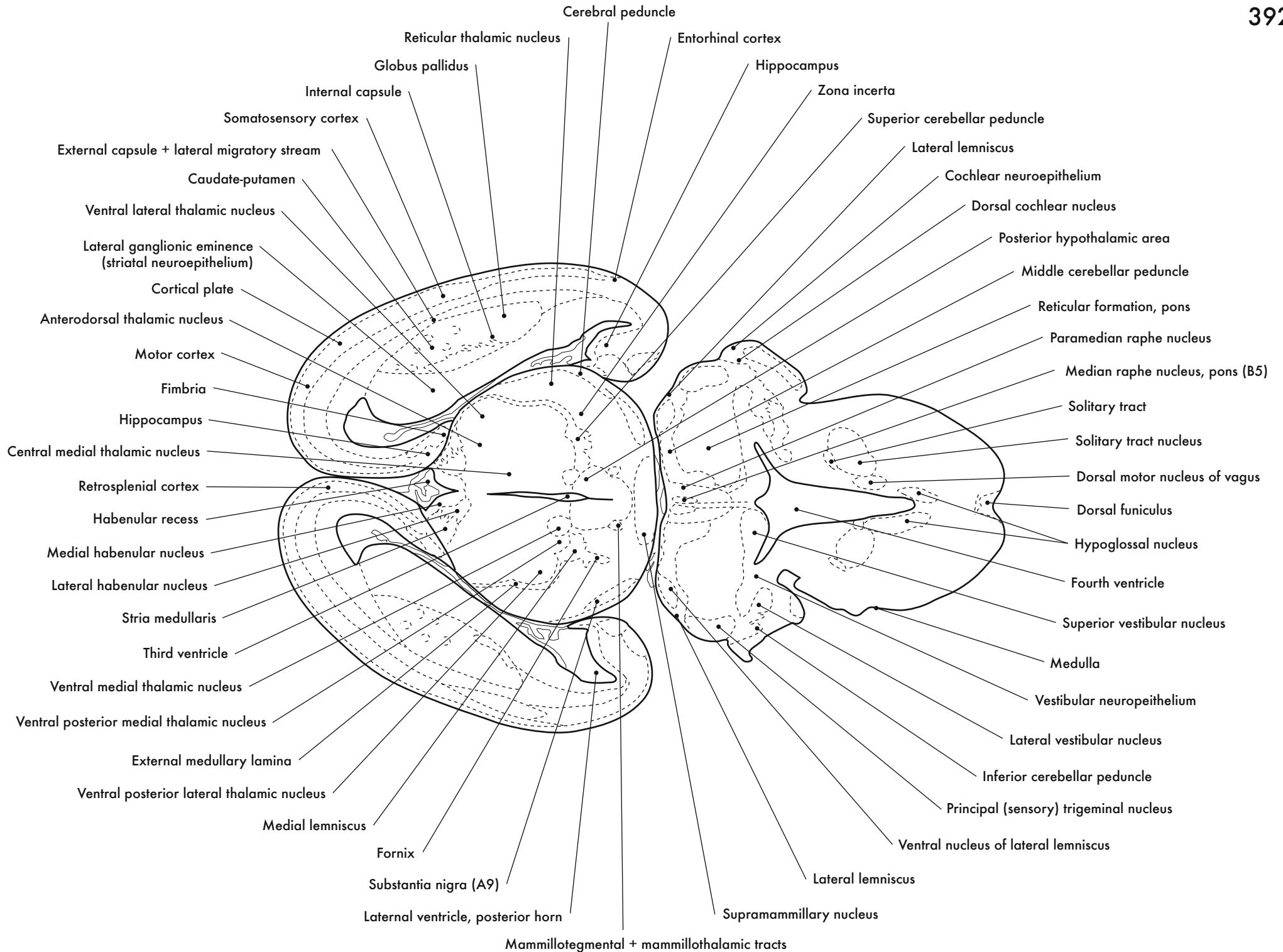
GD 16 HORIZONTAL 7



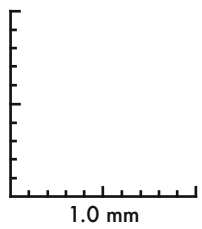
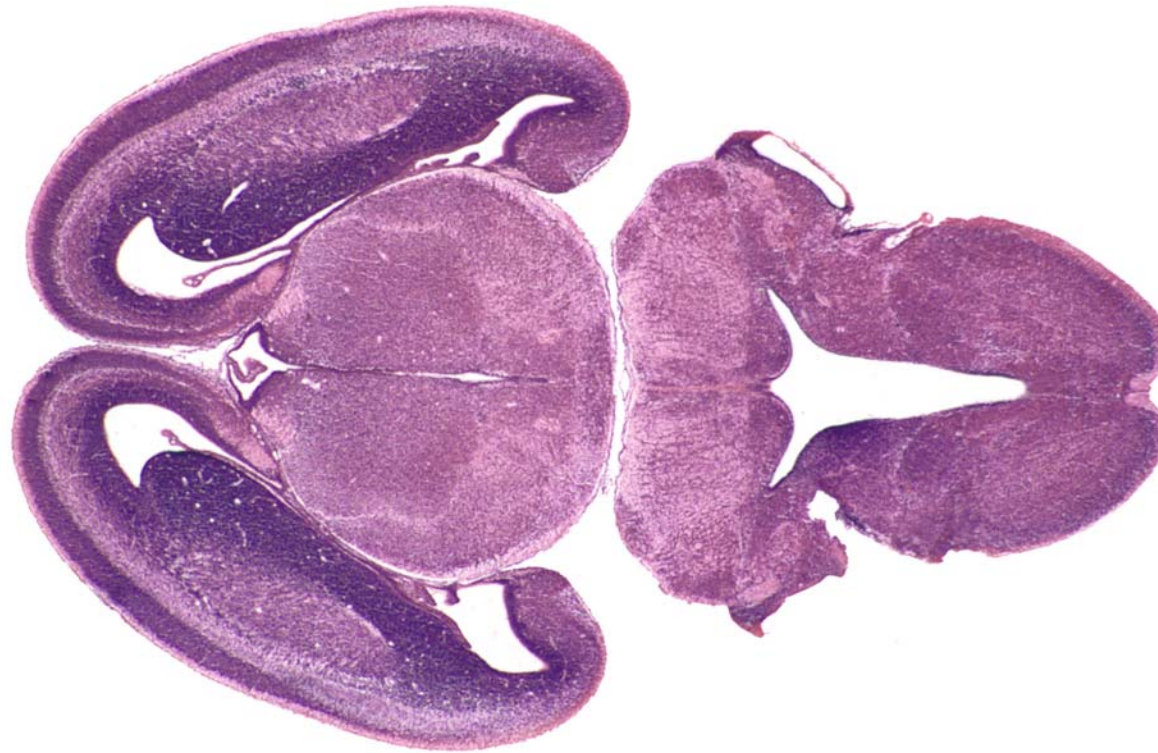




GD 16 HORIZONTAL 8

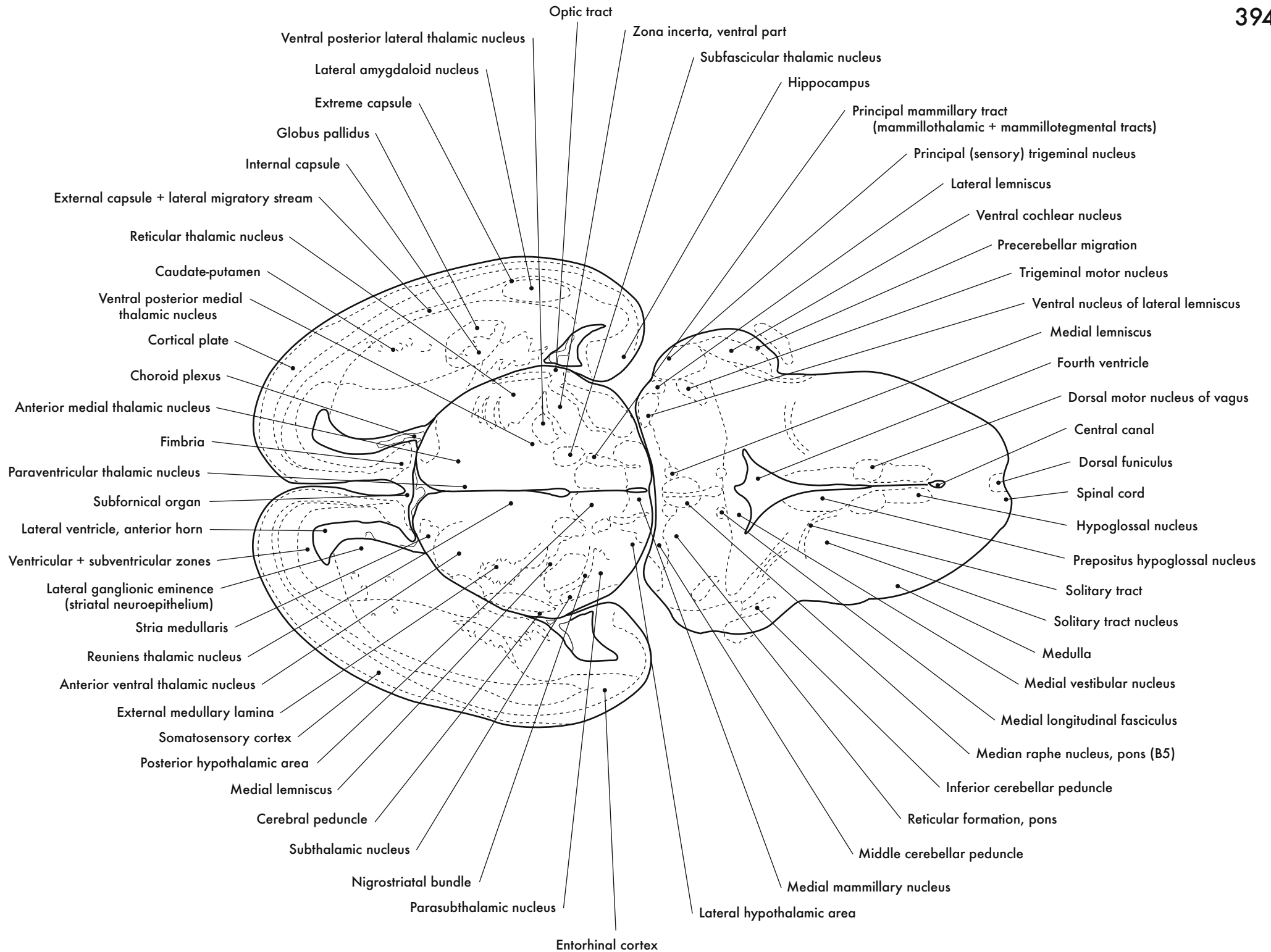


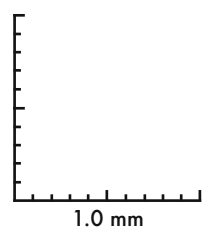
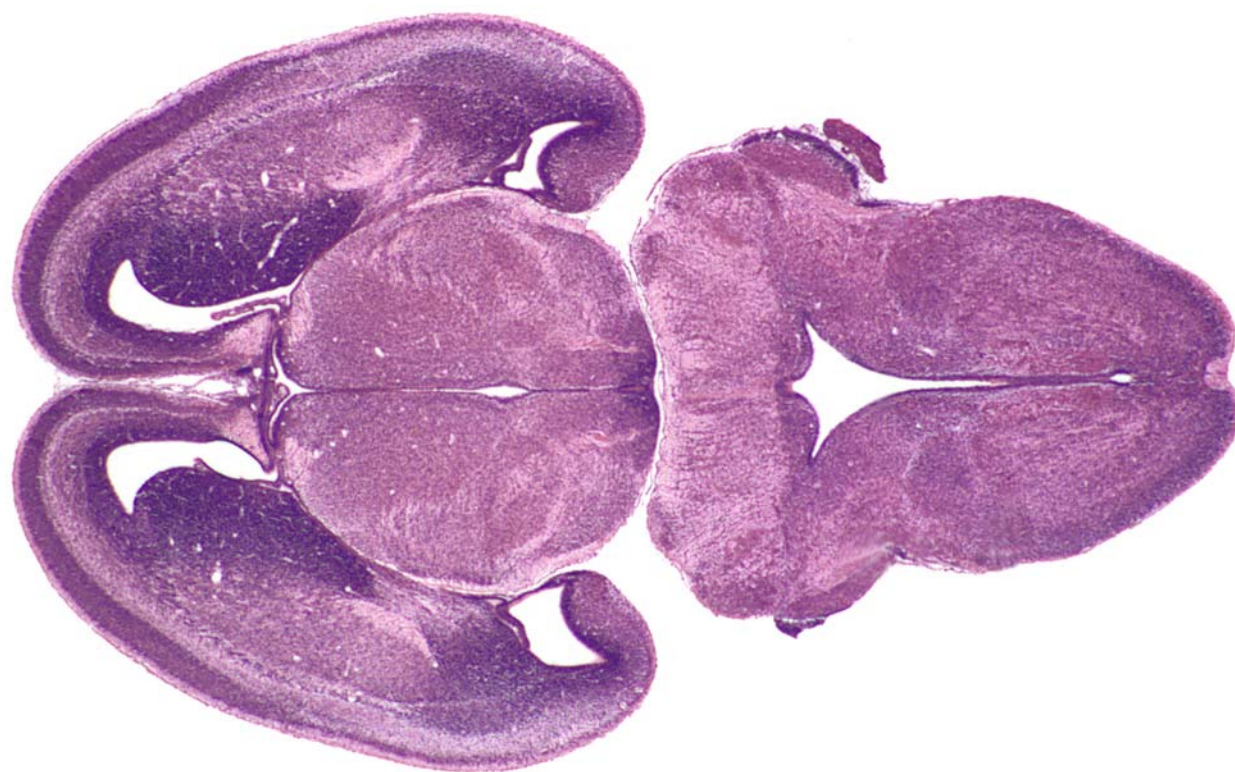




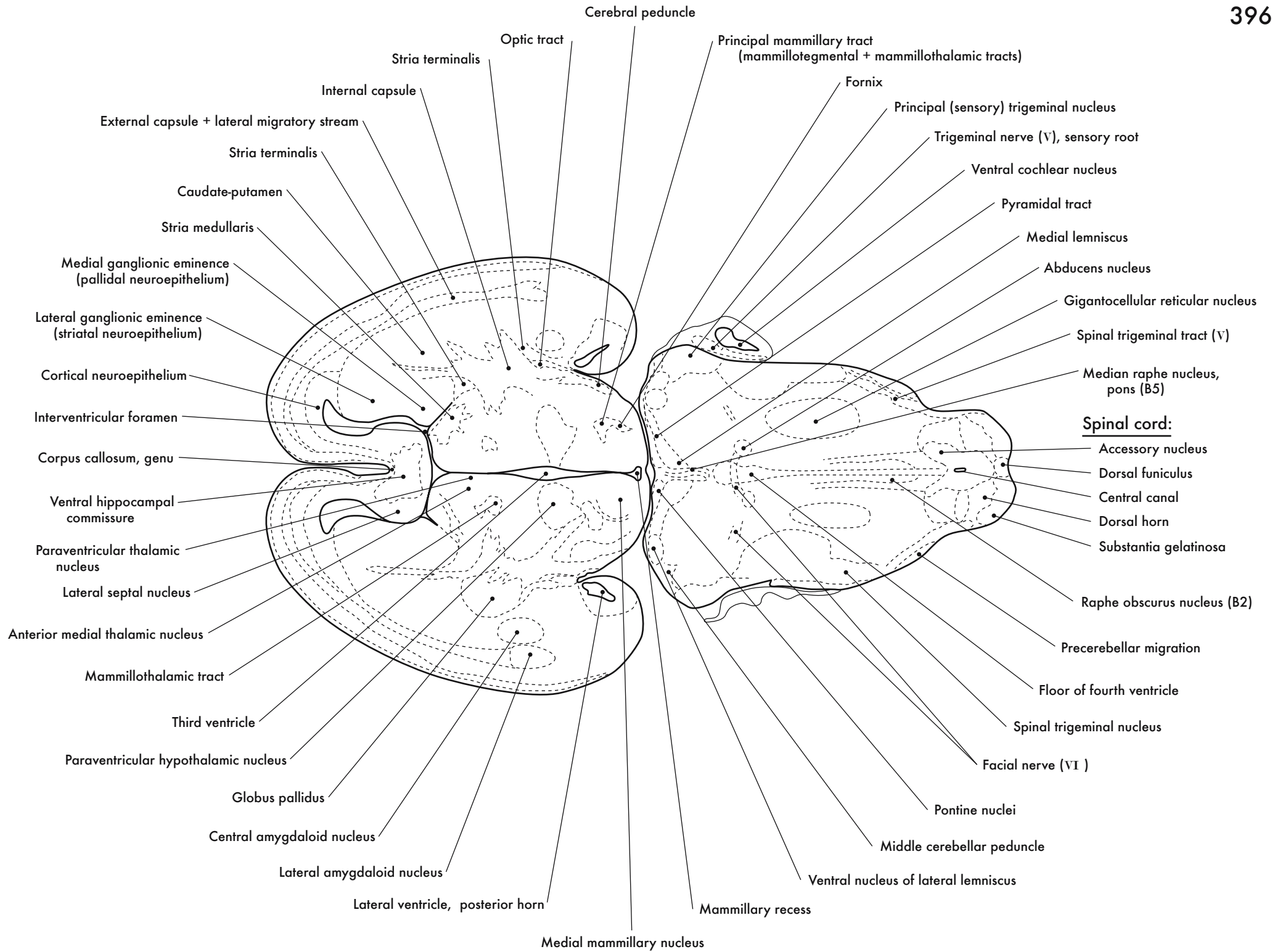
GD 16 HORIZONTAL 9

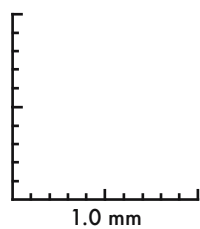
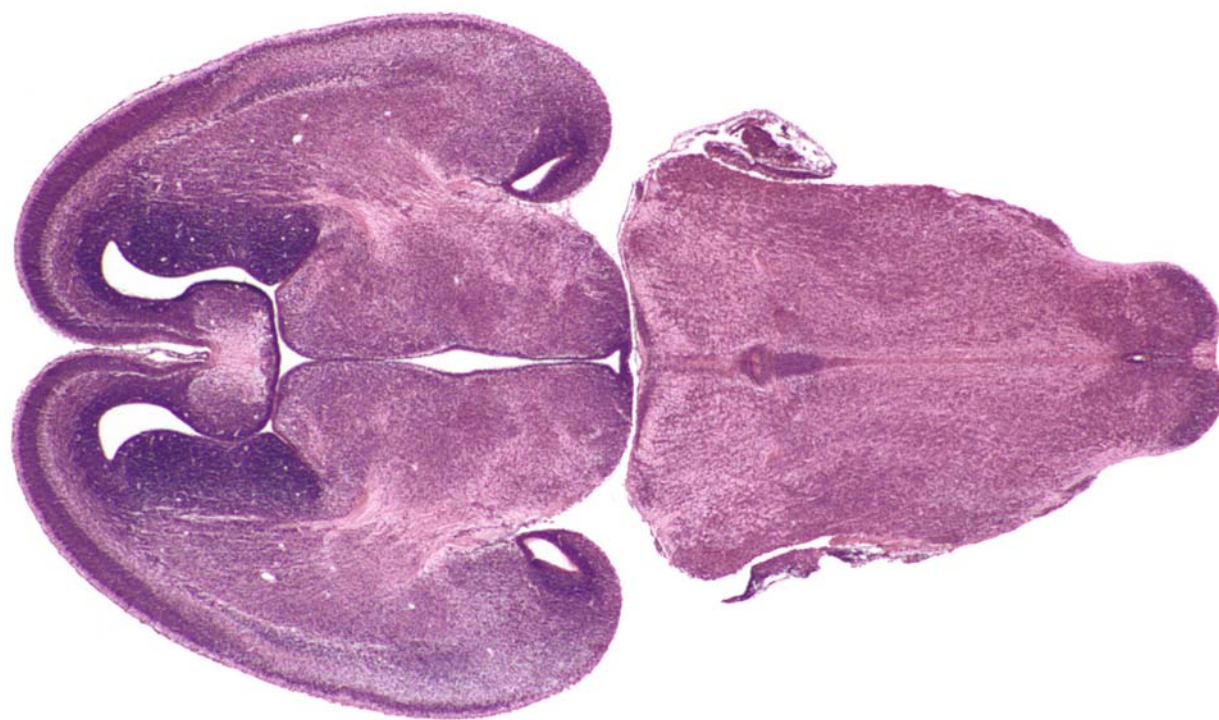







GD 16 HORIZONTAL 10

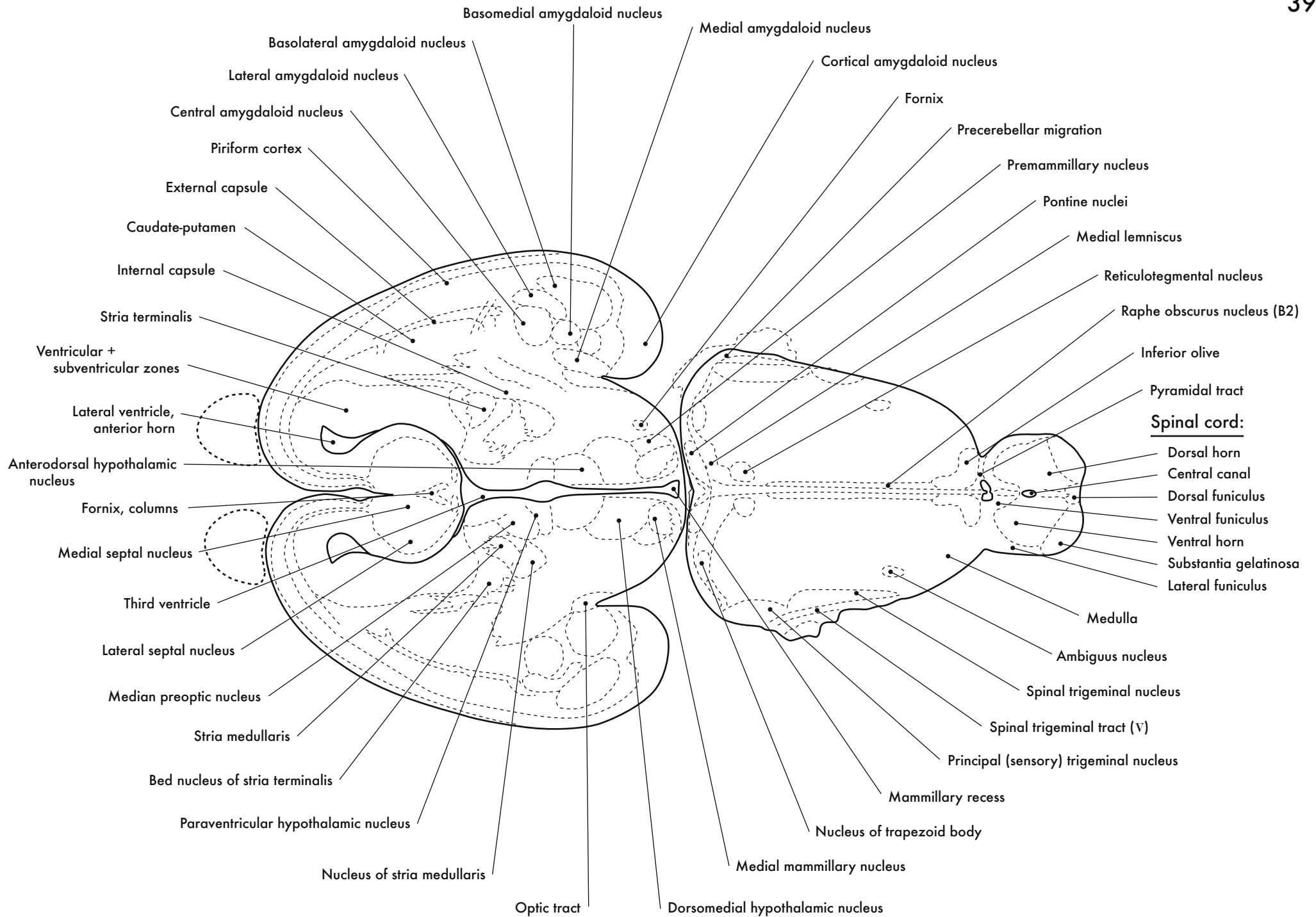


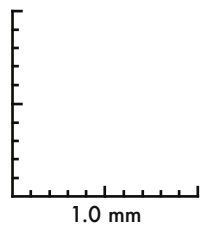
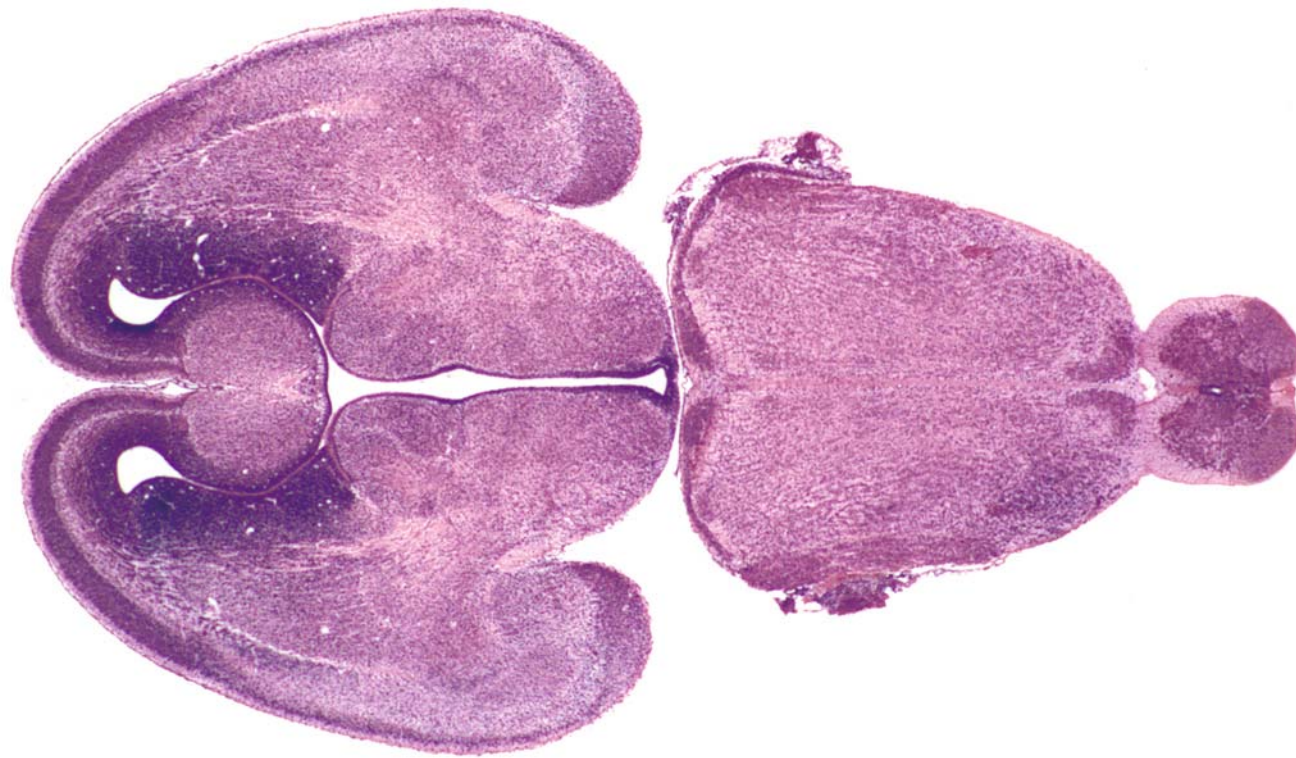



GD 16 HORIZONTAL 11

397



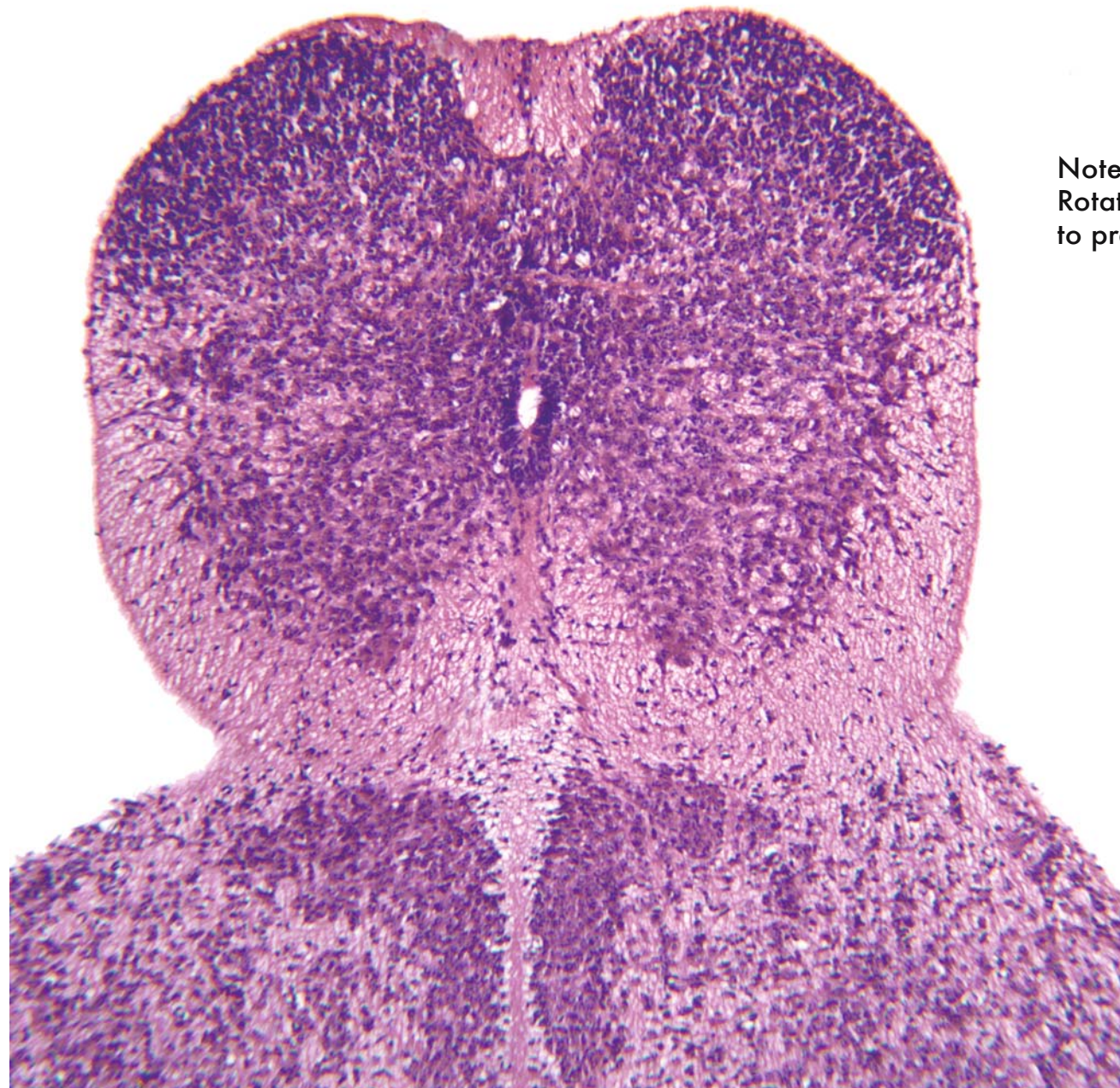
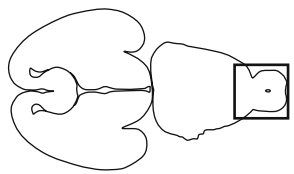




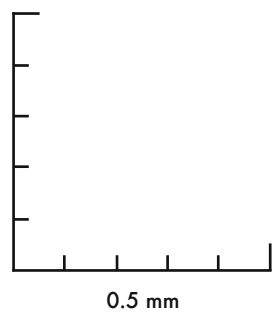
GD 16 HORIZONTAL 12







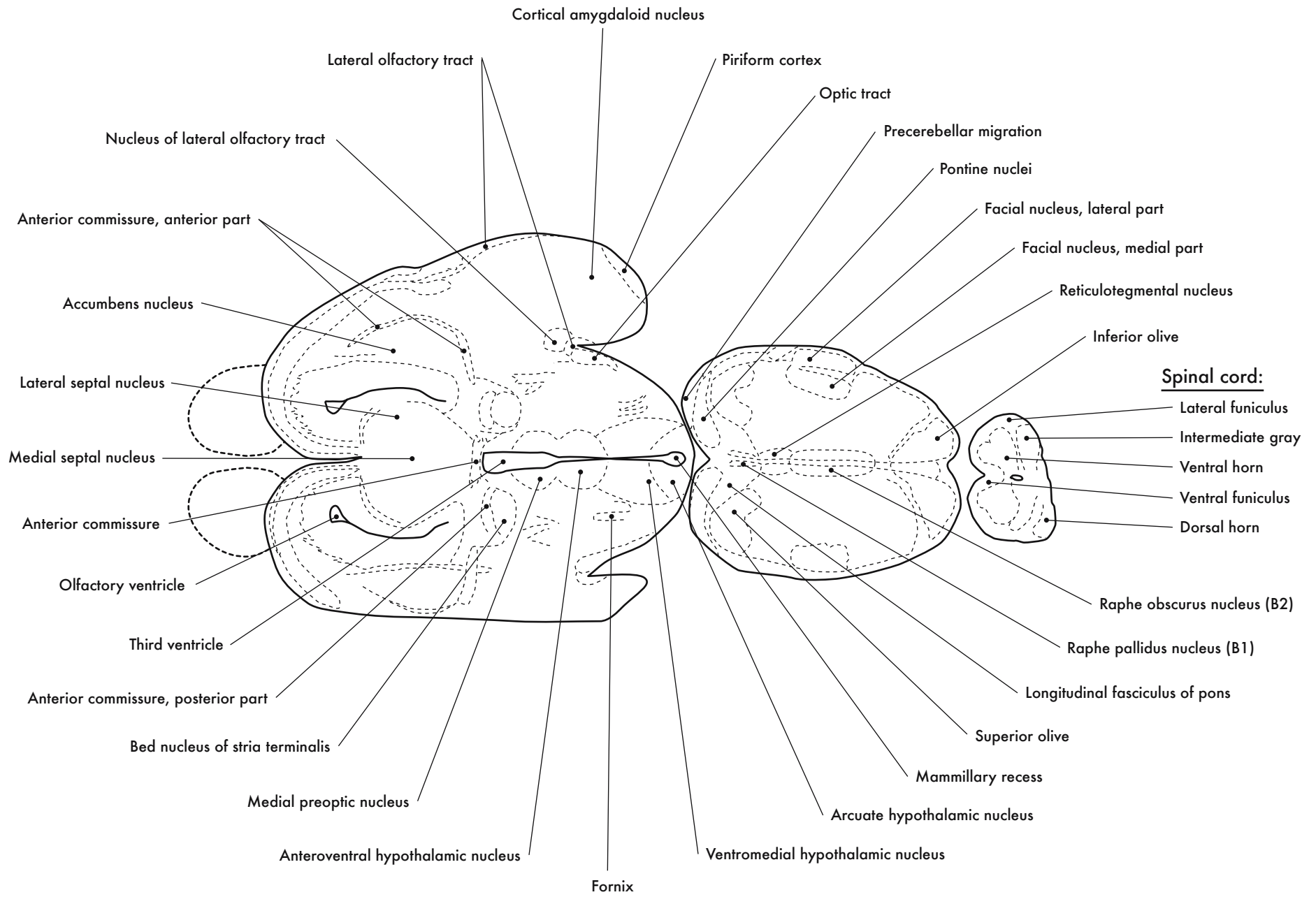
Note:  
Rotated 90° counterclockwise  
to present as coronal section

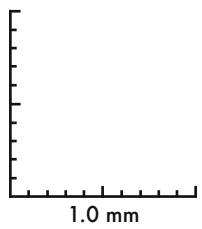
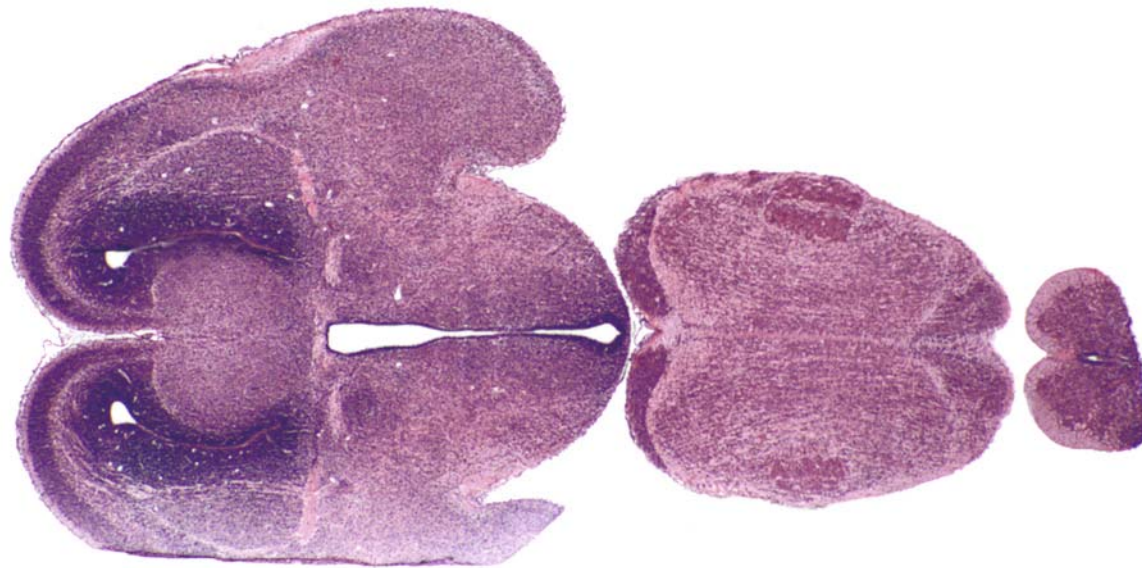


GD 16 HORIZONTAL 13

401

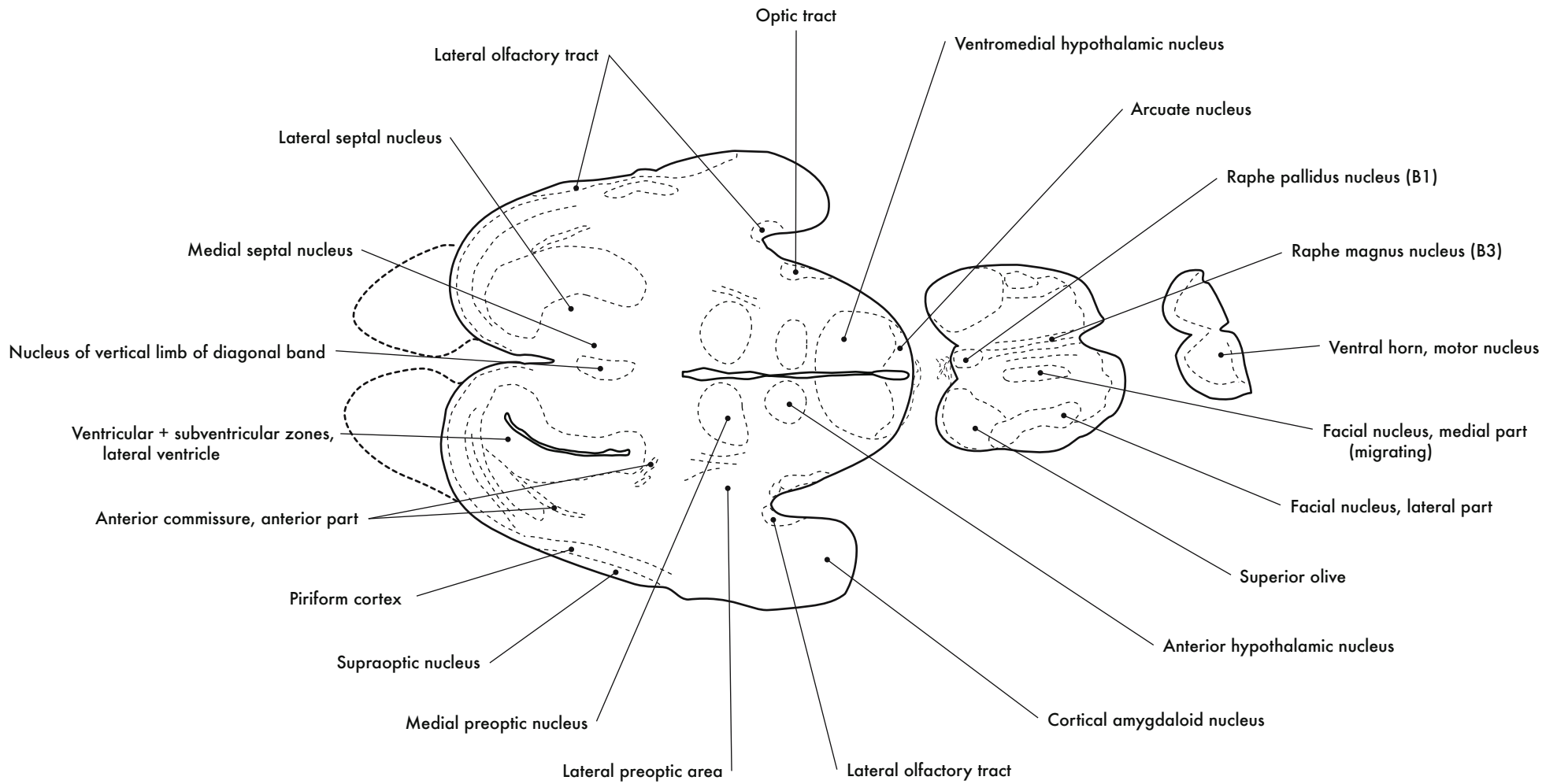


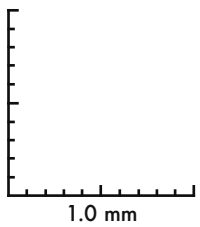
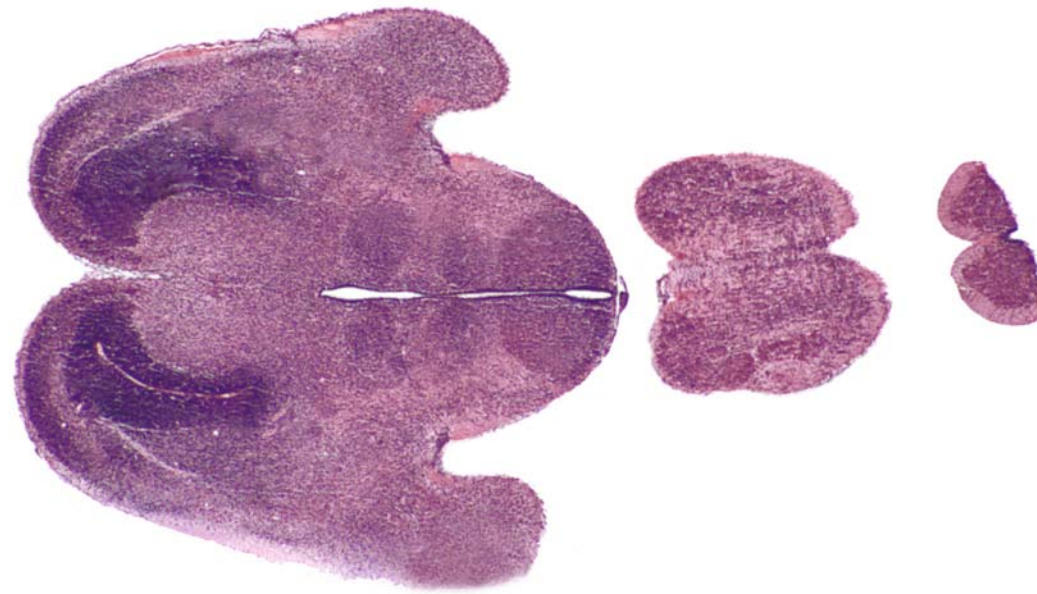





GD 16 HORIZONTAL 14

403

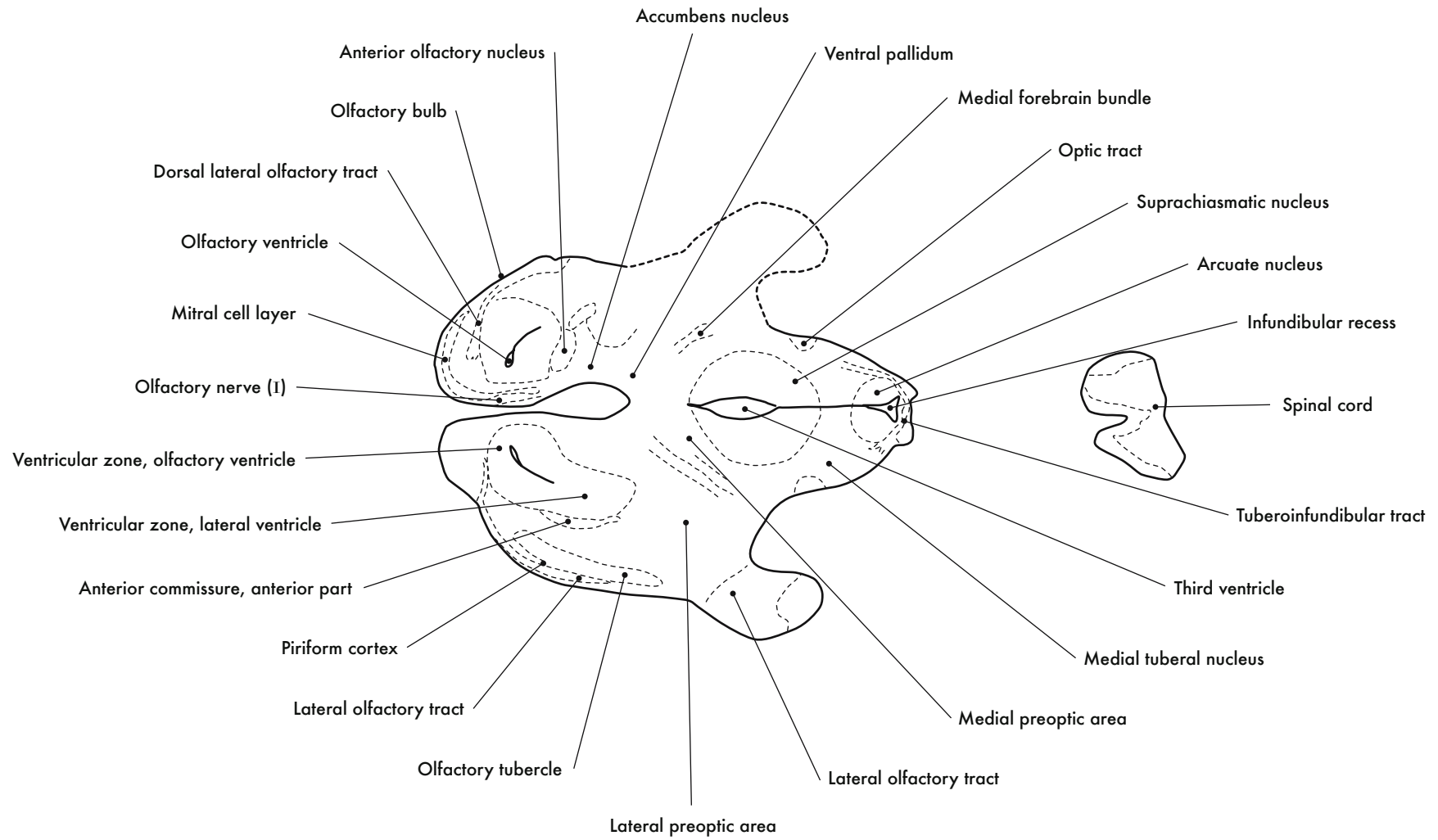


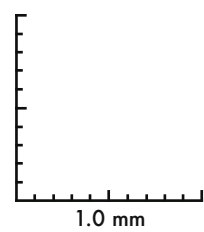
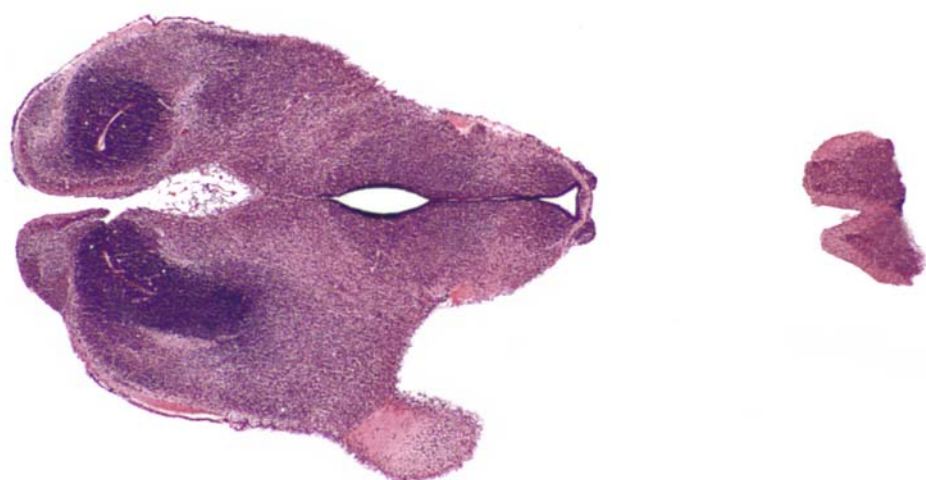


GD 16 HORIZONTAL 15

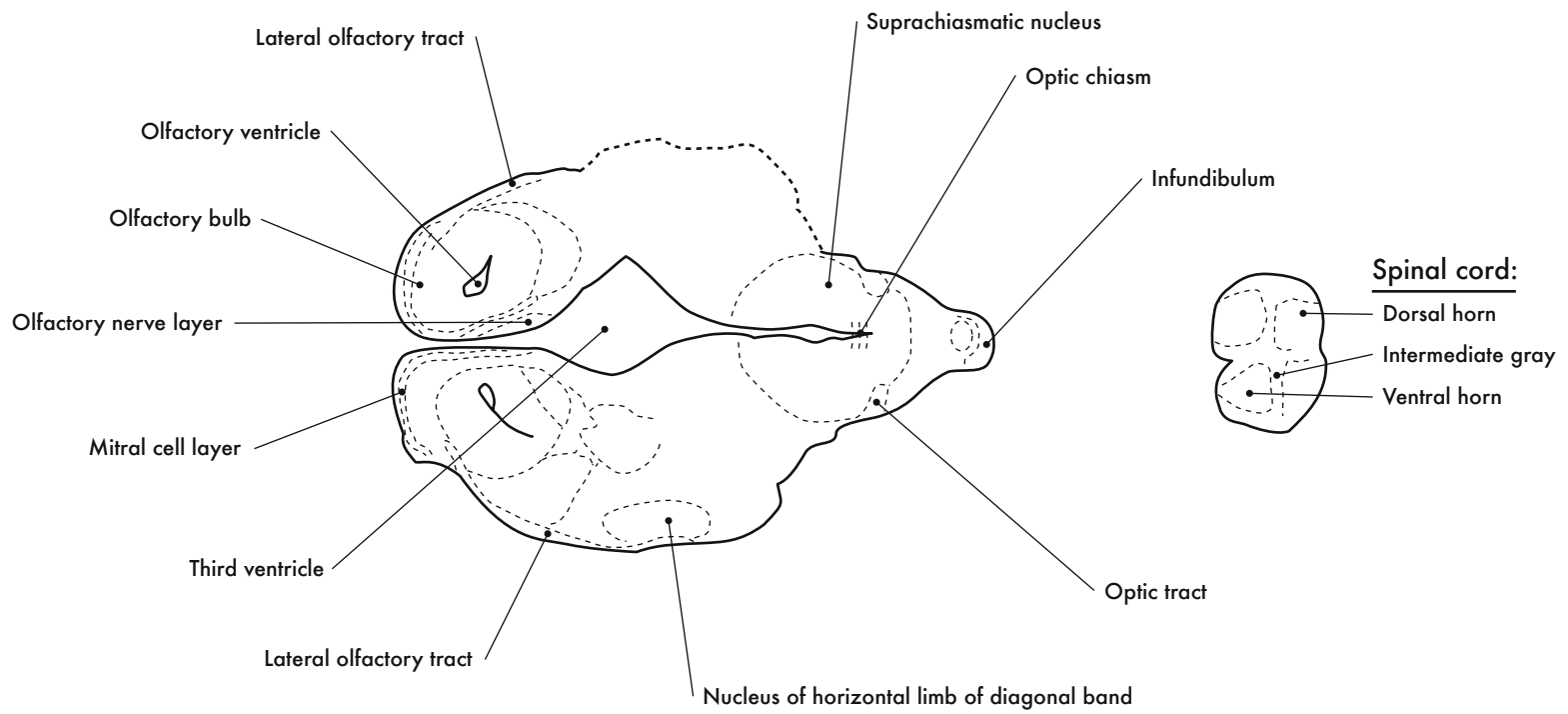
405

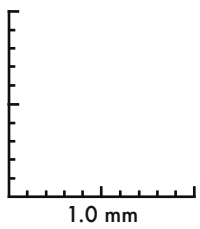
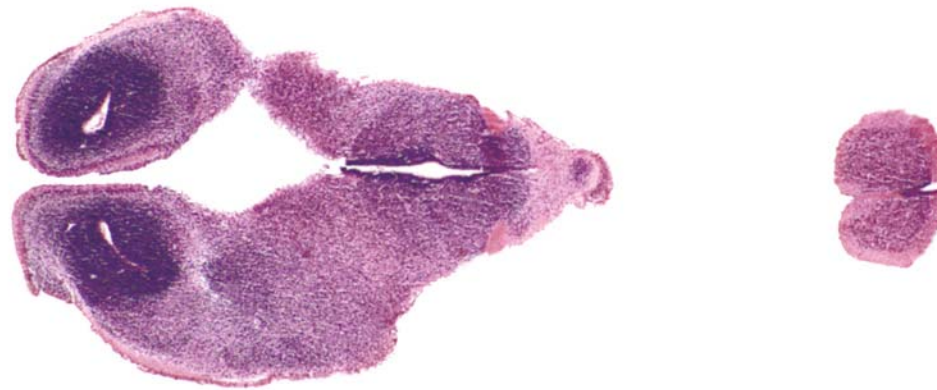






GD 16 HORIZONTAL 16






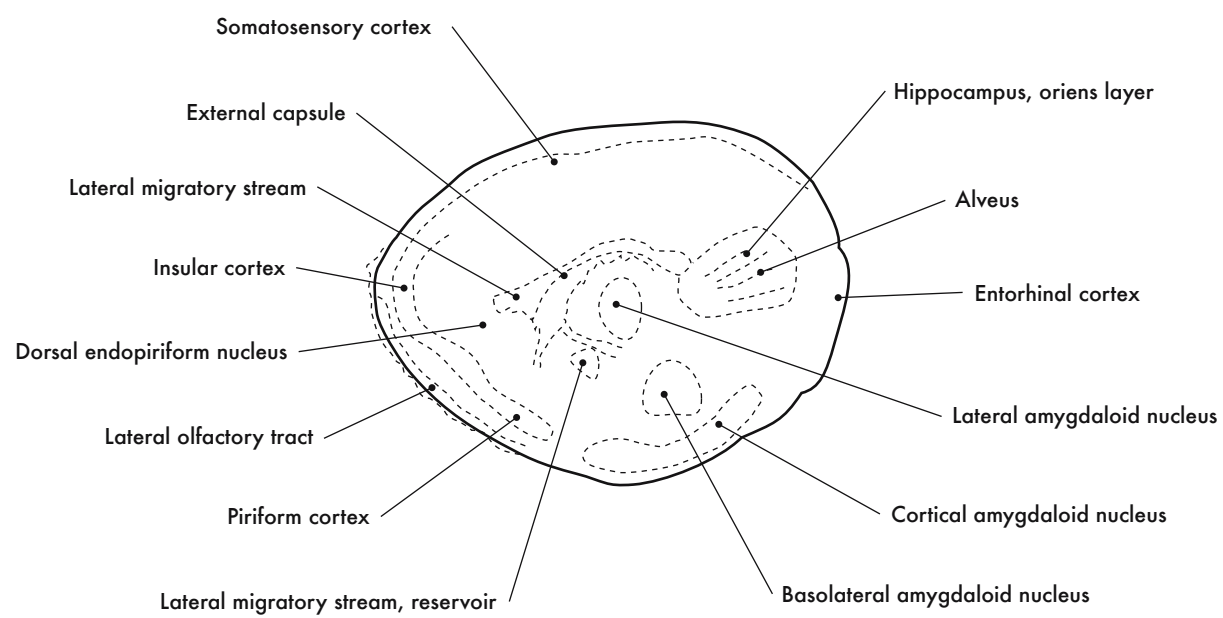
GD 16 HORIZONTAL 17

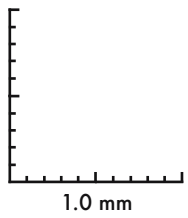
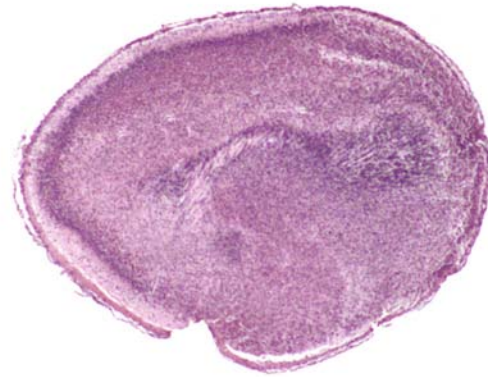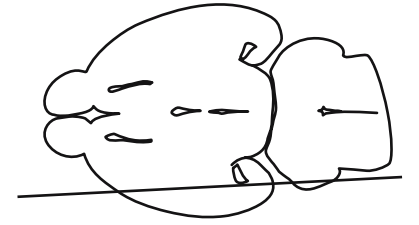


HP denotes image enlargement

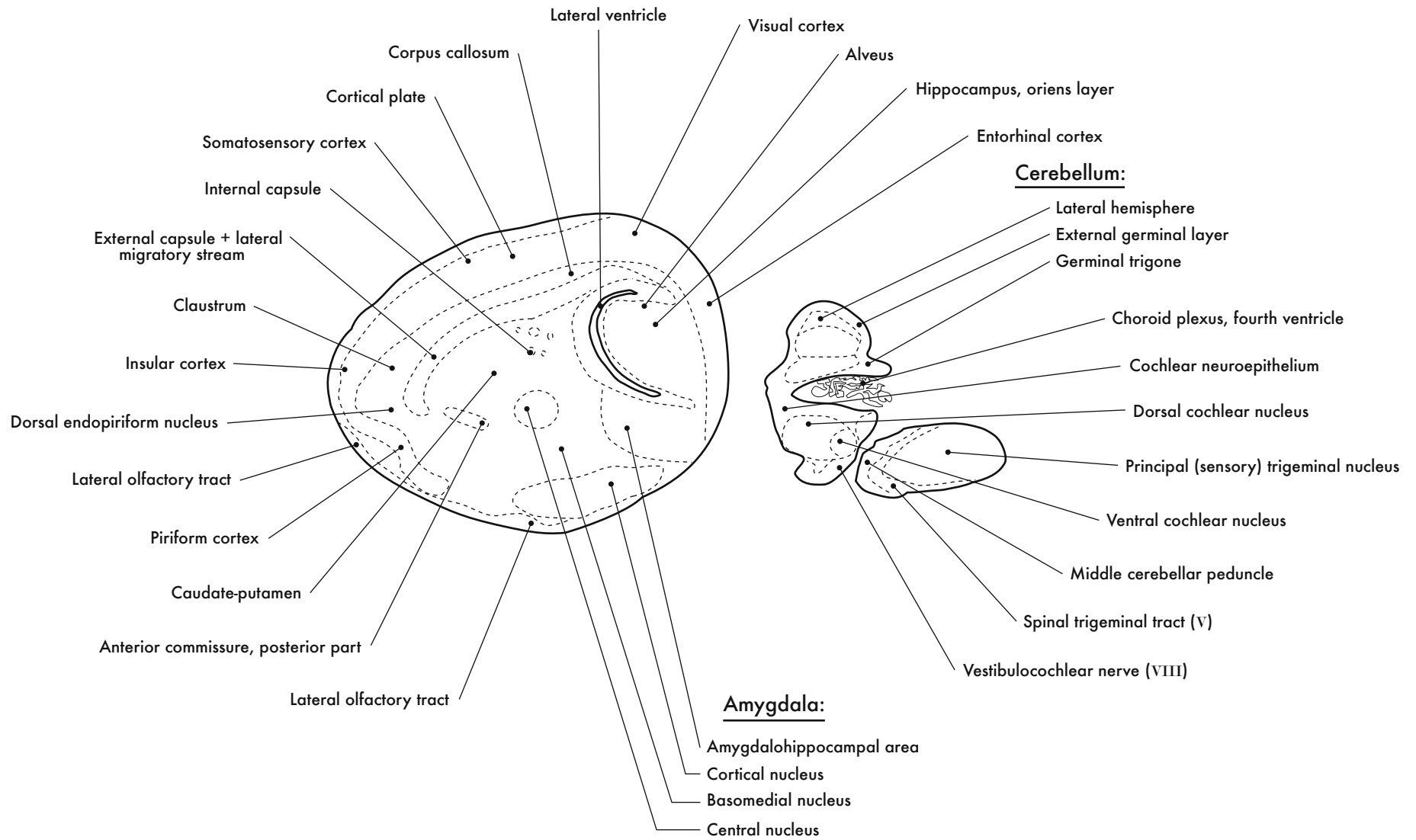


GESTATIONAL DAY 18 (GD 18)  
SAGITTAL SECTIONS

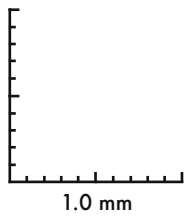
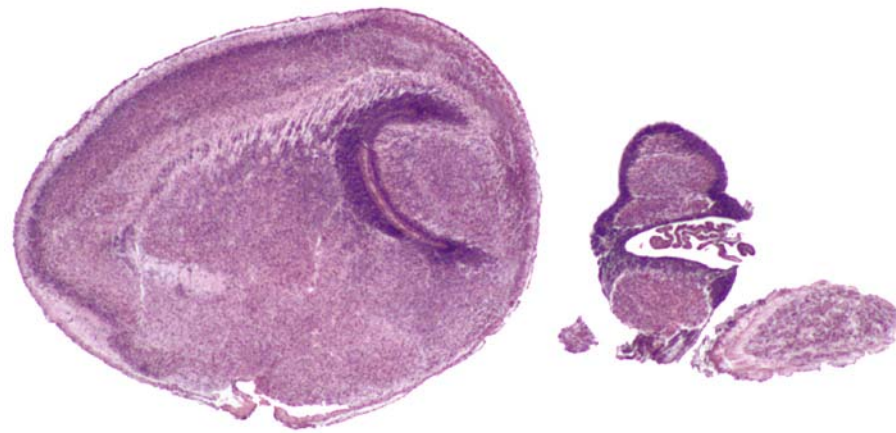





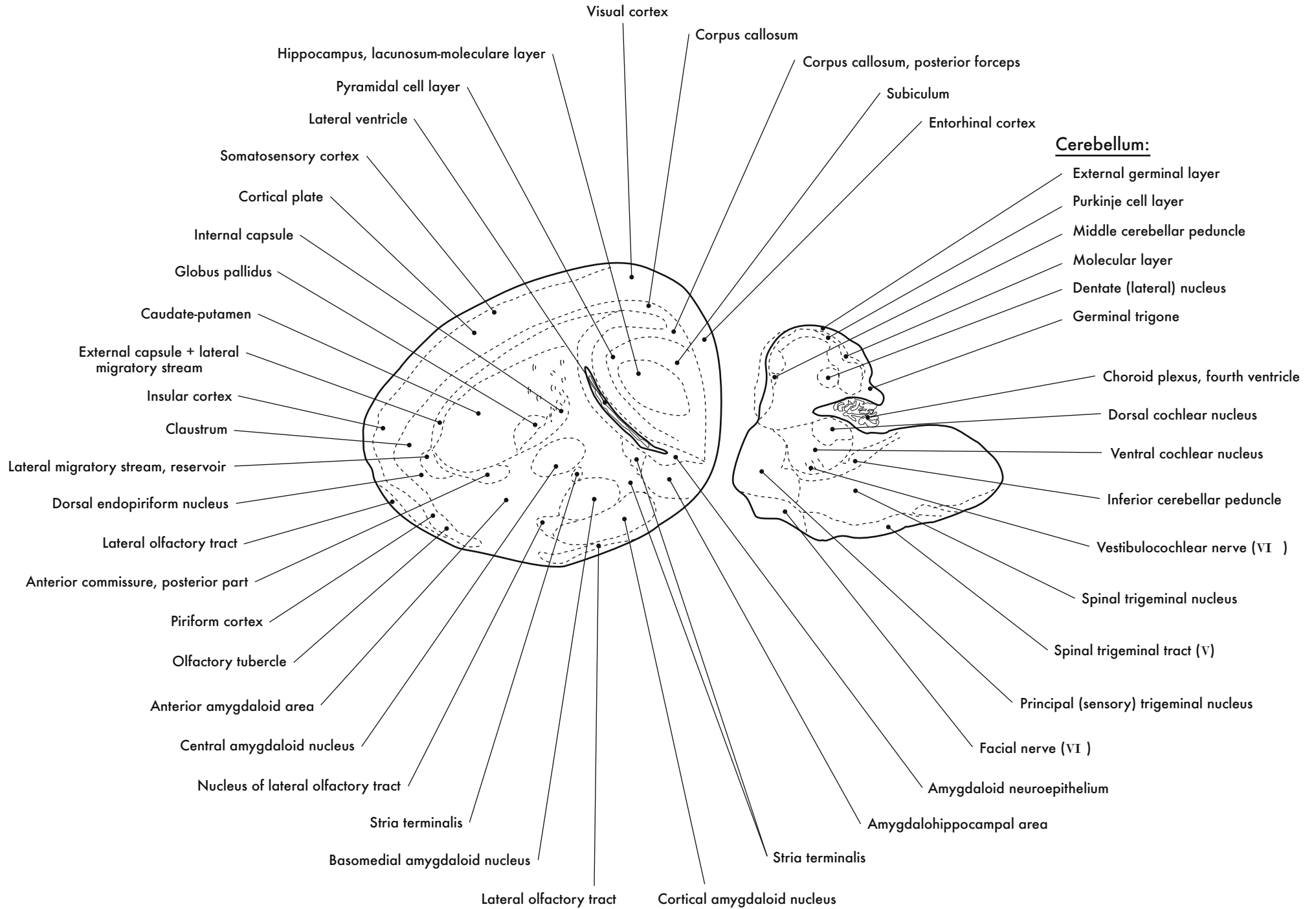
GD 18 SAGITTAL 1

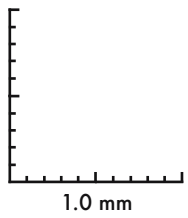
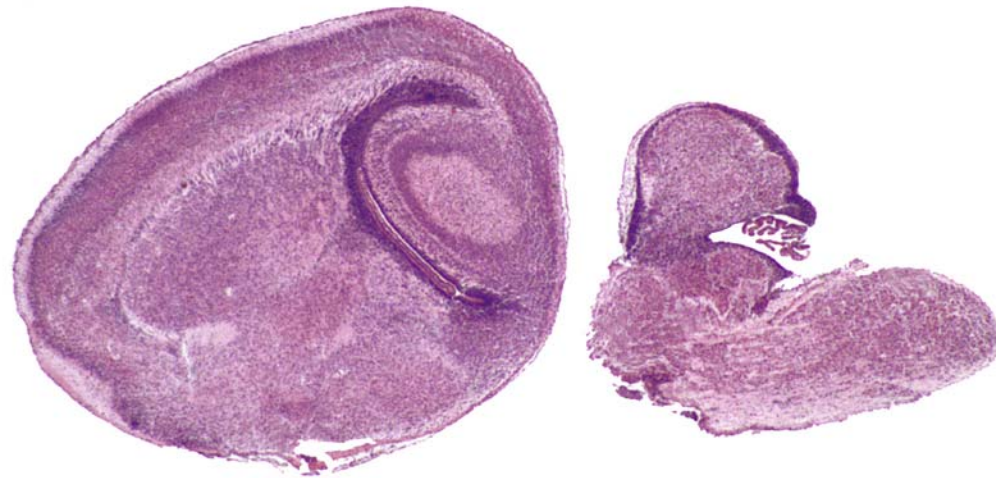
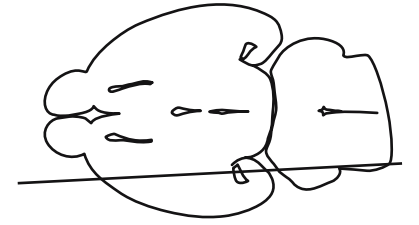






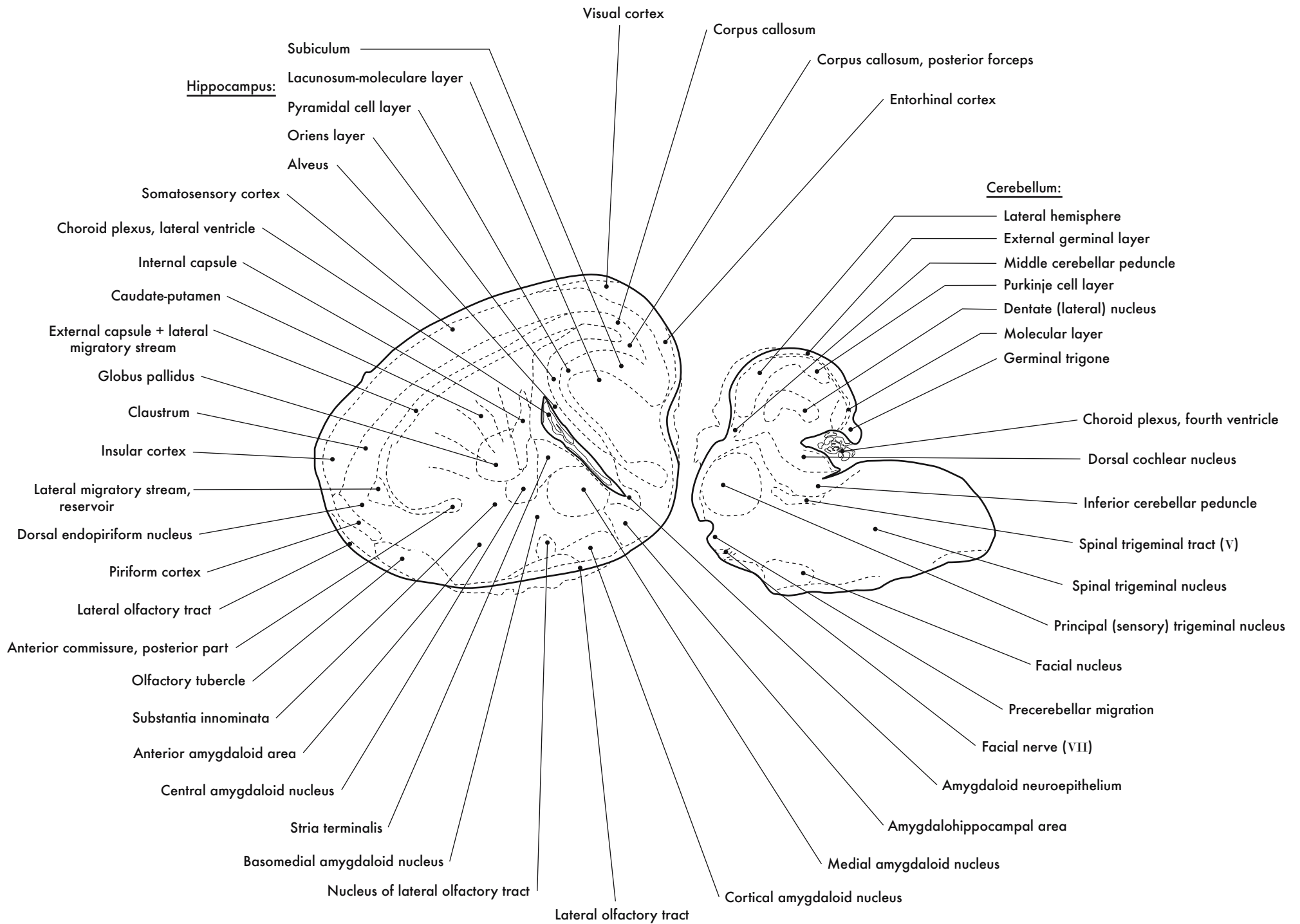
GD 18 SAGITTAL 2



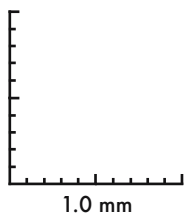
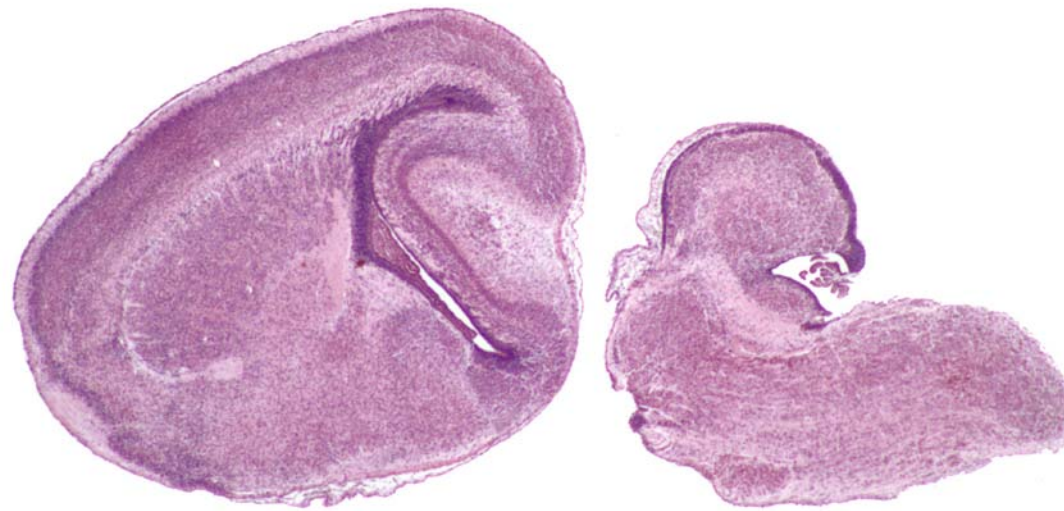

GD 18 SAGITTAL 3

417

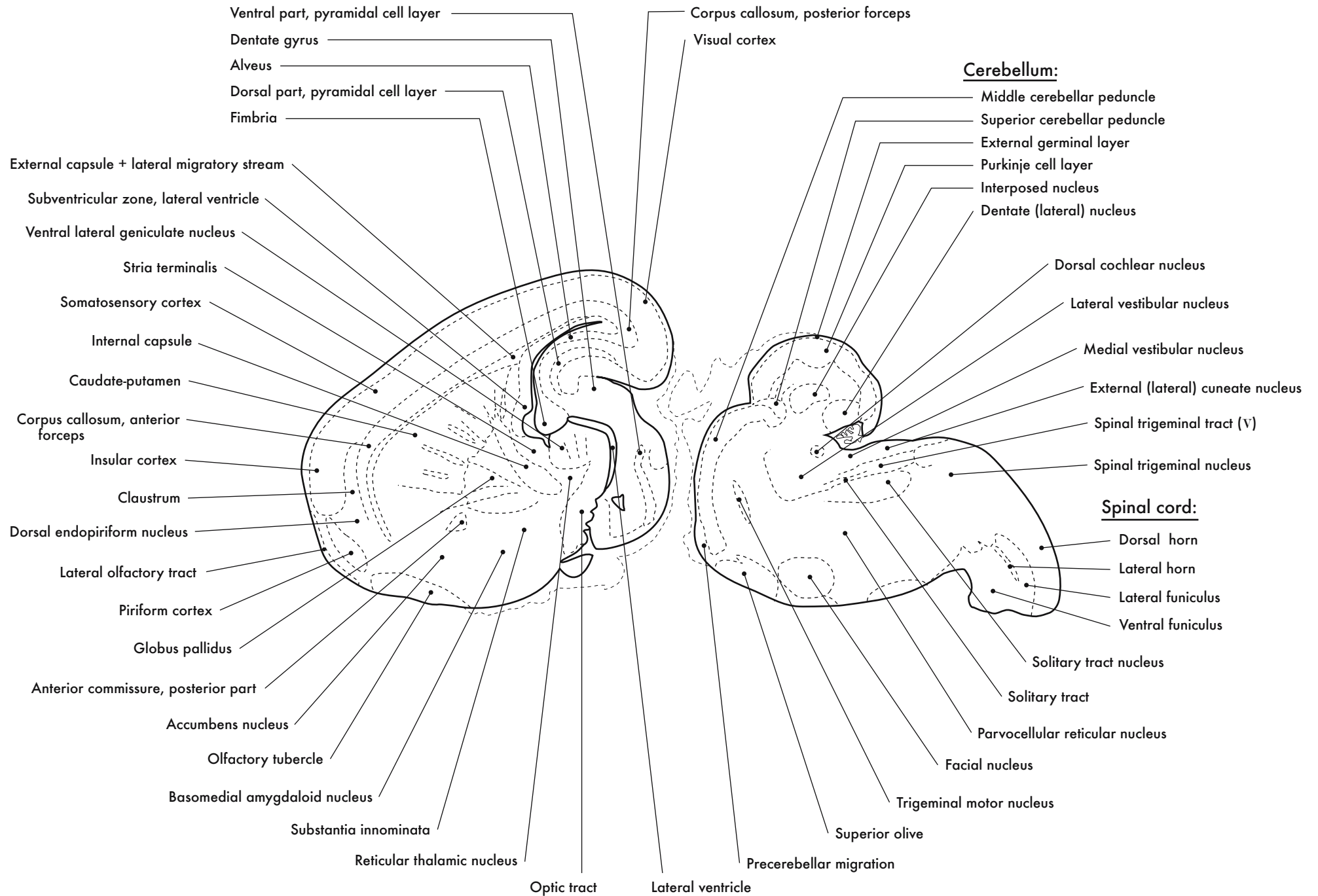


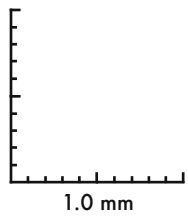
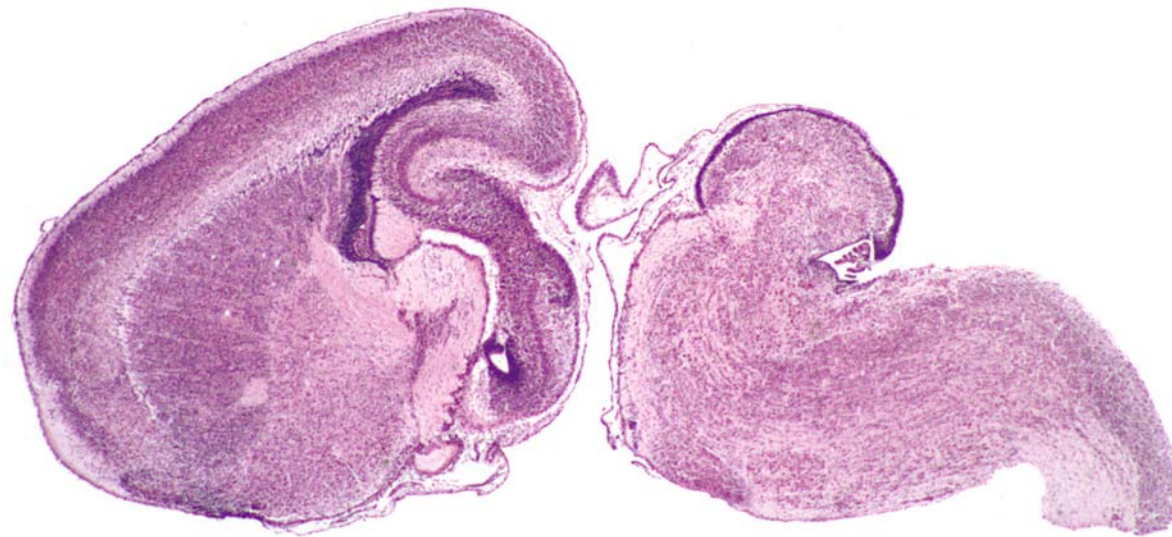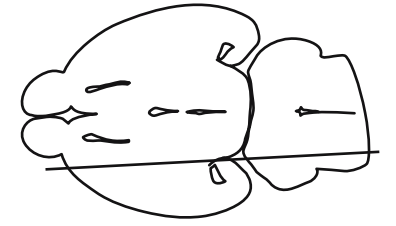




GD 18 SAGITTAL 4

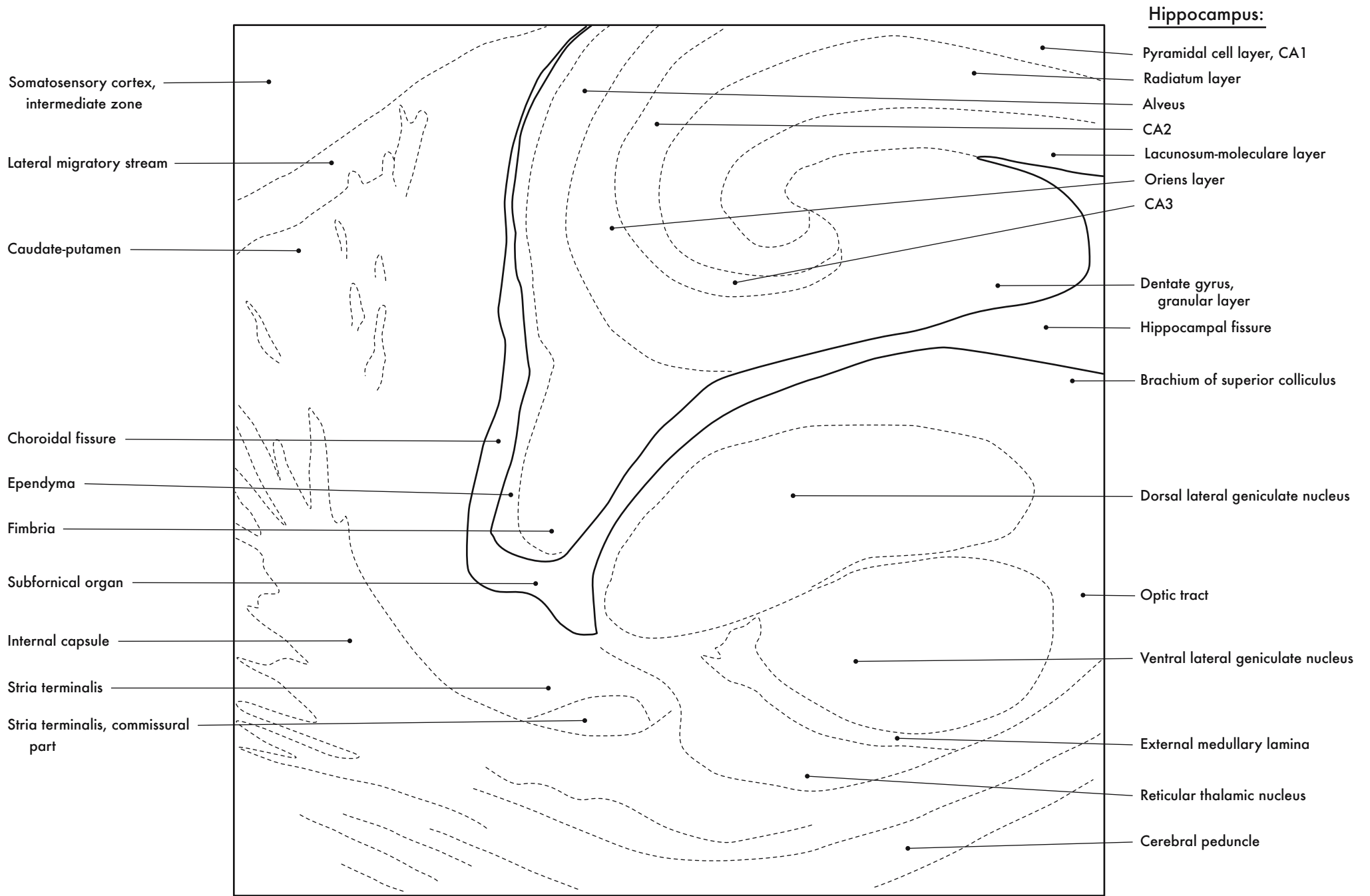
Hippocampal formation:





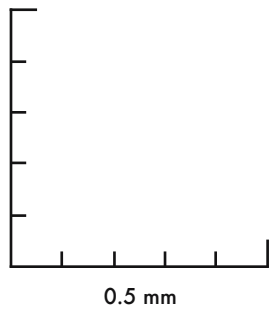
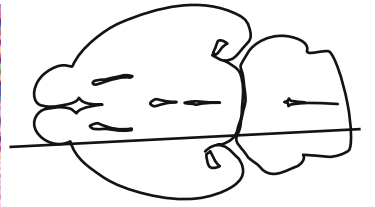
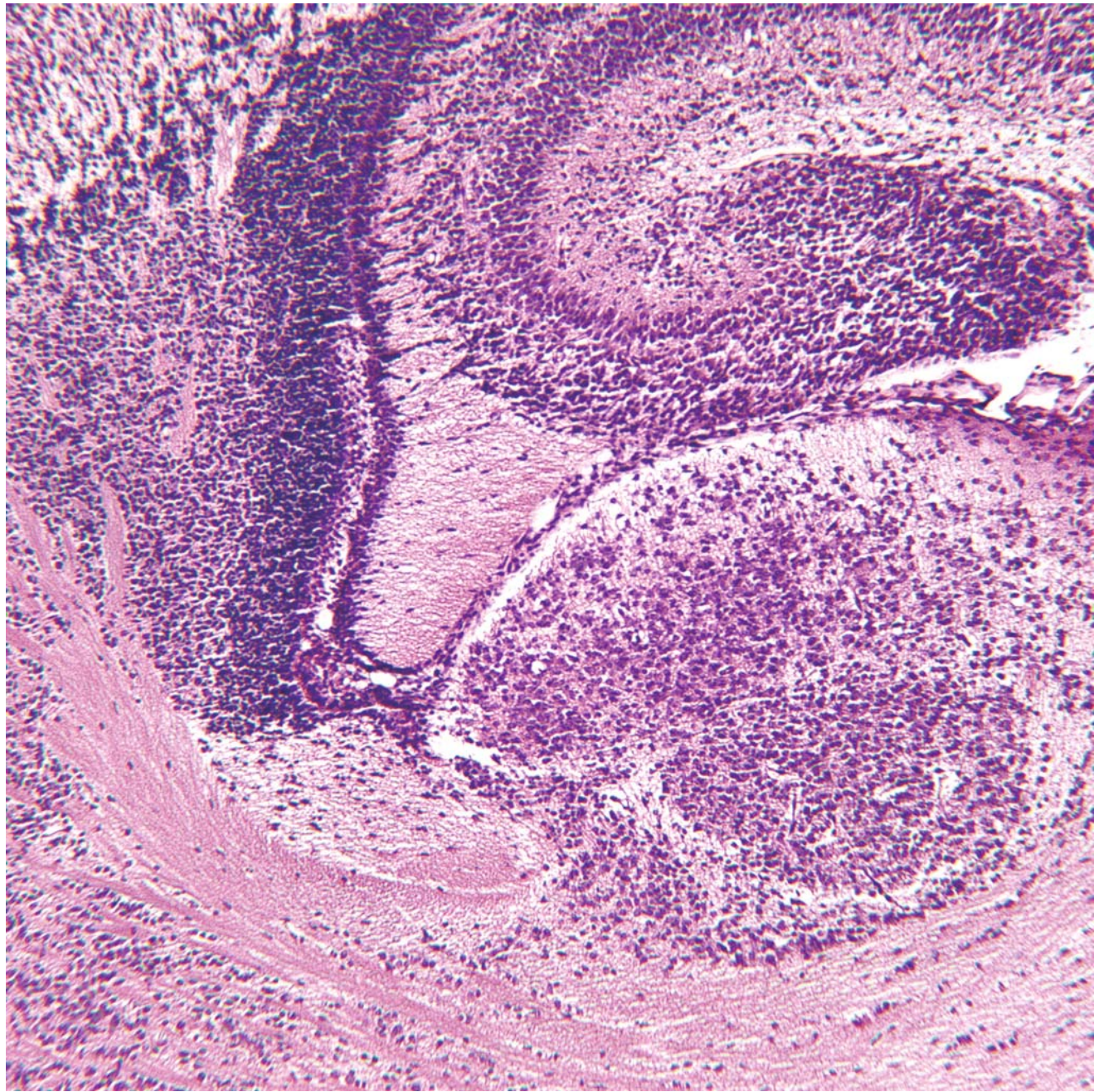
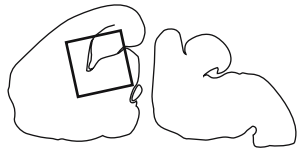
GD 18 SAGITTAL 5

421



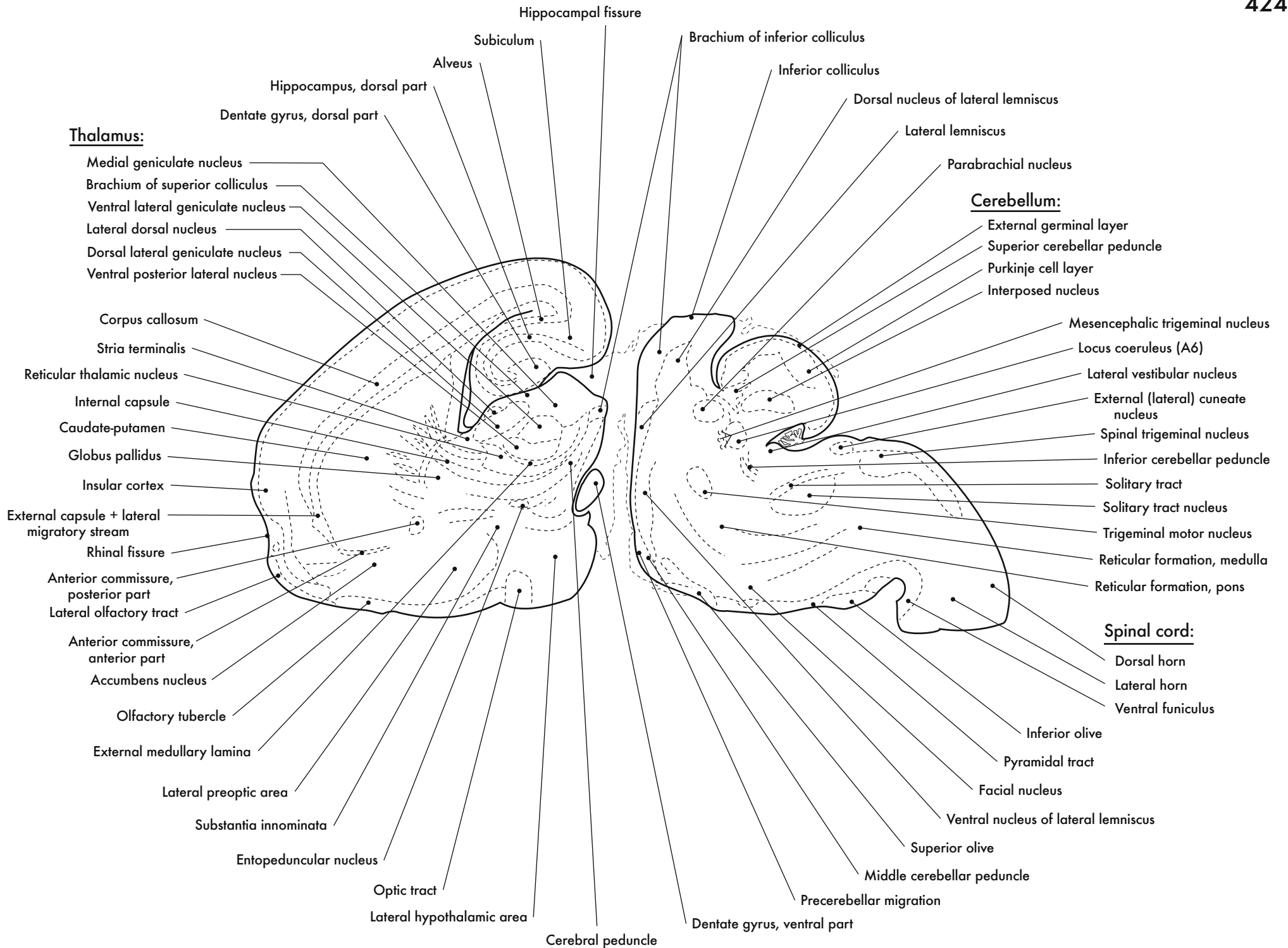
Hippocampus, Thalamus and Internal Capsule





GD 18 SAGITTAL 6





**Thalamus:**

- Medial geniculate nucleus
- Brachium of superior colliculus
- Ventral lateral geniculate nucleus
- Lateral dorsal nucleus
- Dorsal lateral geniculate nucleus
- Ventral posterior lateral nucleus
- Corpus callosum
- Stria terminalis
- Reticular thalamic nucleus
- Internal capsule
- Caudate-putamen
- Globus pallidus
- Insular cortex
- External capsule + lateral migratory stream
- Rhinal fissure
- Anterior commissure, posterior part
- Lateral olfactory tract
- Anterior commissure, anterior part
- Accumbens nucleus
- Olfactory tubercle
- External medullary lamina
- Lateral preoptic area
- Substantia innominata
- Entopeduncular nucleus
- Optic tract
- Lateral hypothalamic area

**Cerebellum:**

- External germinal layer
- Superior cerebellar peduncle
- Purkinje cell layer
- Interposed nucleus
- Mesencephalic trigeminal nucleus
- Locus coeruleus (A6)
- Lateral vestibular nucleus
- External (lateral) cuneate nucleus
- Spinal trigeminal nucleus
- Inferior cerebellar peduncle
- Solitary tract
- Solitary tract nucleus
- Trigeminal motor nucleus
- Reticular formation, medulla
- Reticular formation, pons

**Spinal cord:**

- Dorsal horn
- Lateral horn
- Ventral funiculus
- Inferior olive
- Pyramidal tract
- Facial nucleus
- Ventral nucleus of lateral lemniscus
- Superior olive

Hippocampal fissure

Subiculum

Brachium of inferior colliculus

Alveus

Inferior colliculus

Hippocampus, dorsal part

Dorsal nucleus of lateral lemniscus

Dentate gyrus, dorsal part

Lateral lemniscus

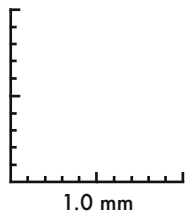
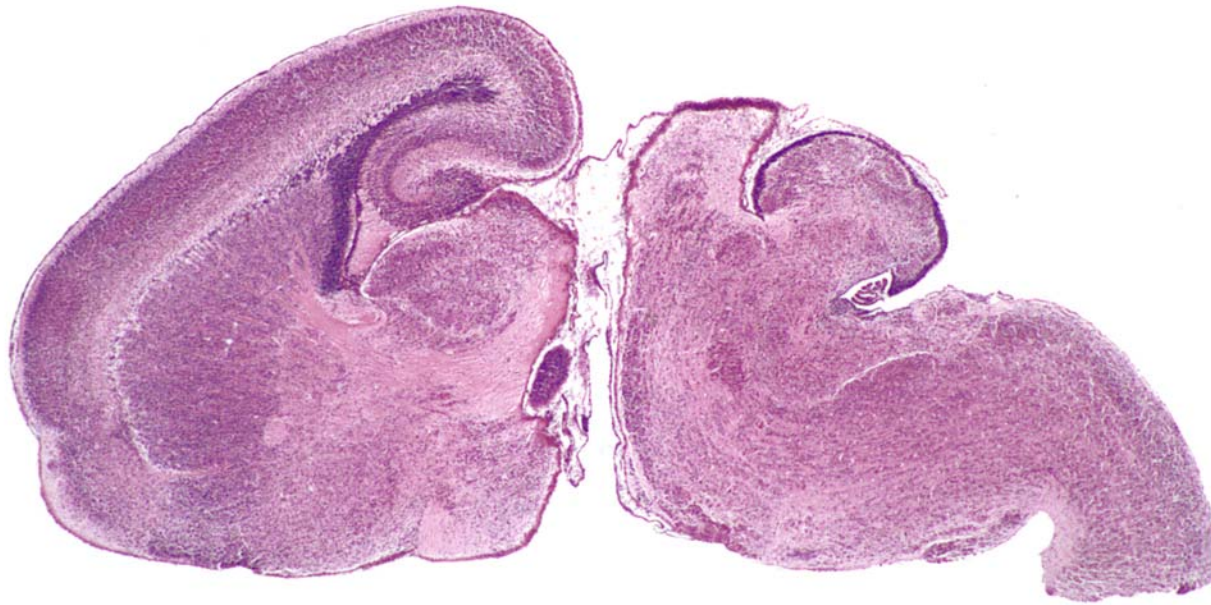
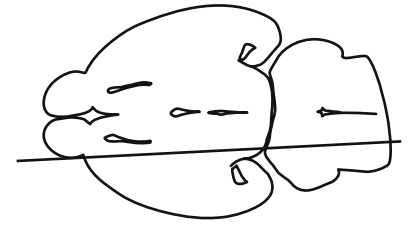
Parabrachial nucleus

Cerebral peduncle

Dentate gyrus, ventral part

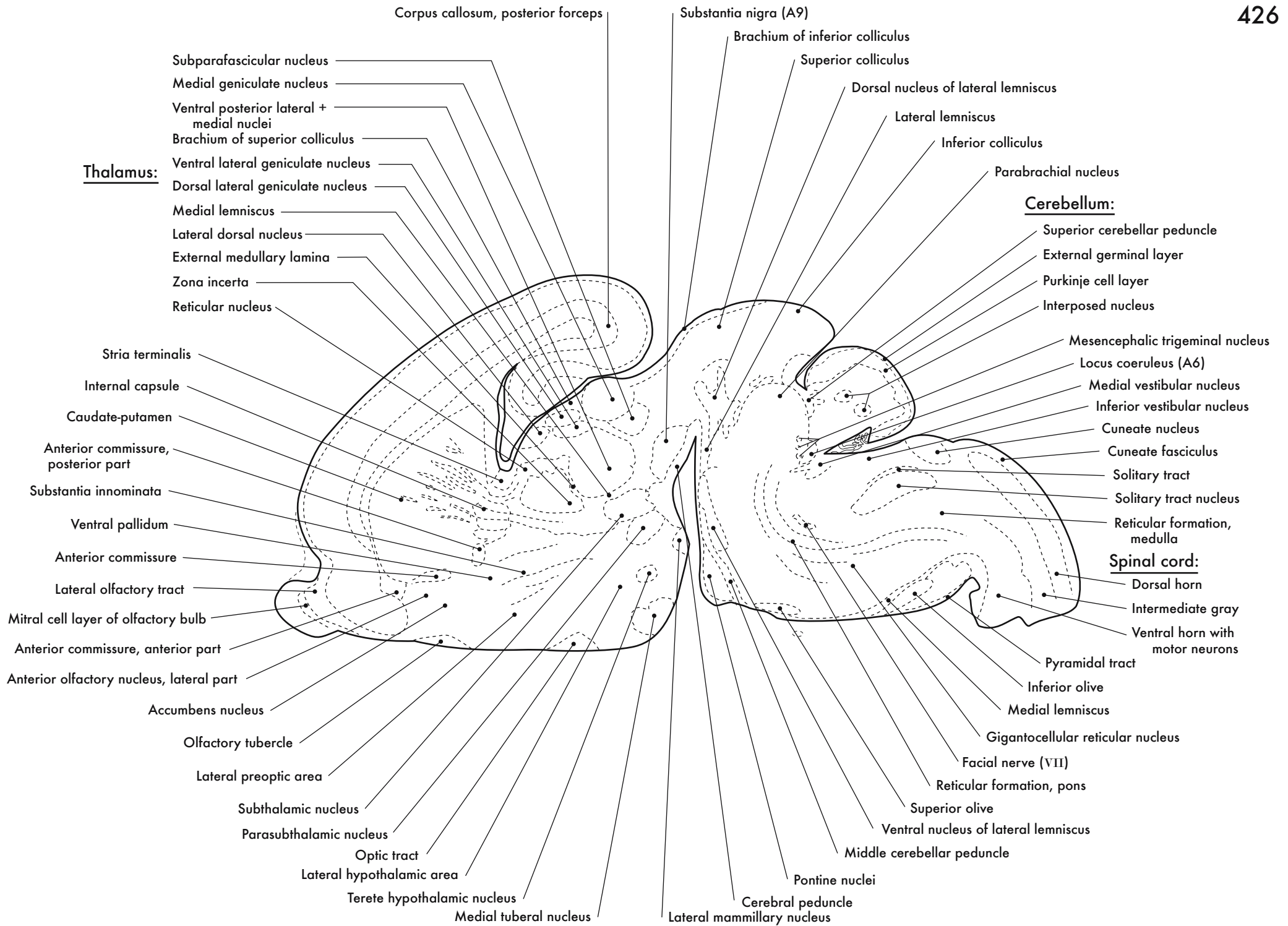
Middle cerebellar peduncle

Precerebellar migration

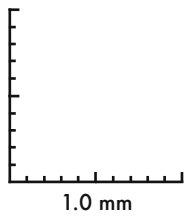
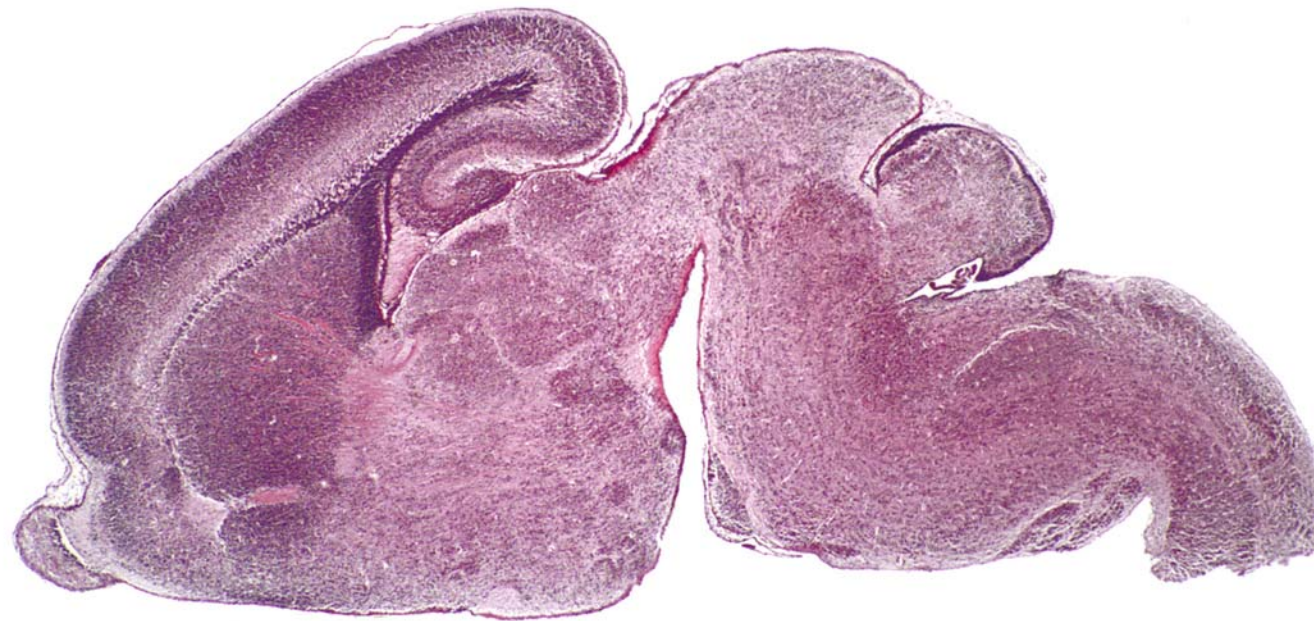
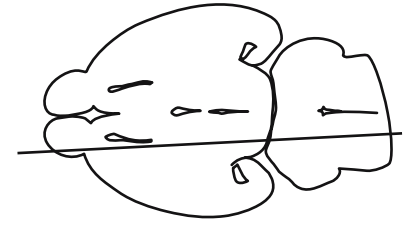


GD 18 SAGITTAL 7

425







GD 18 SAGITTAL 8

427

Thalamus:

Midbrain:

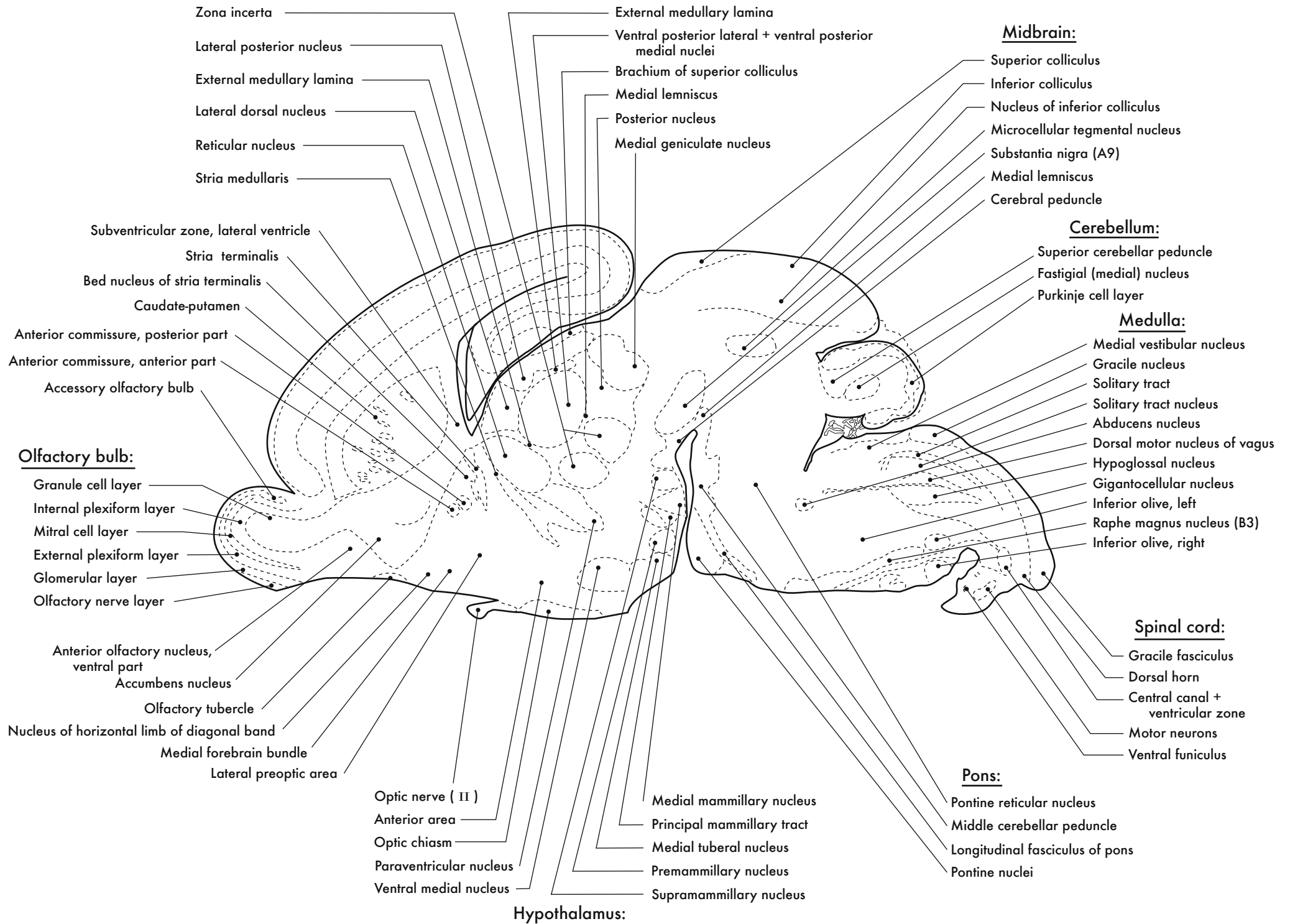
Cerebellum:

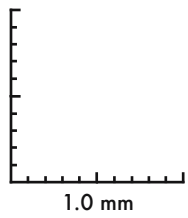
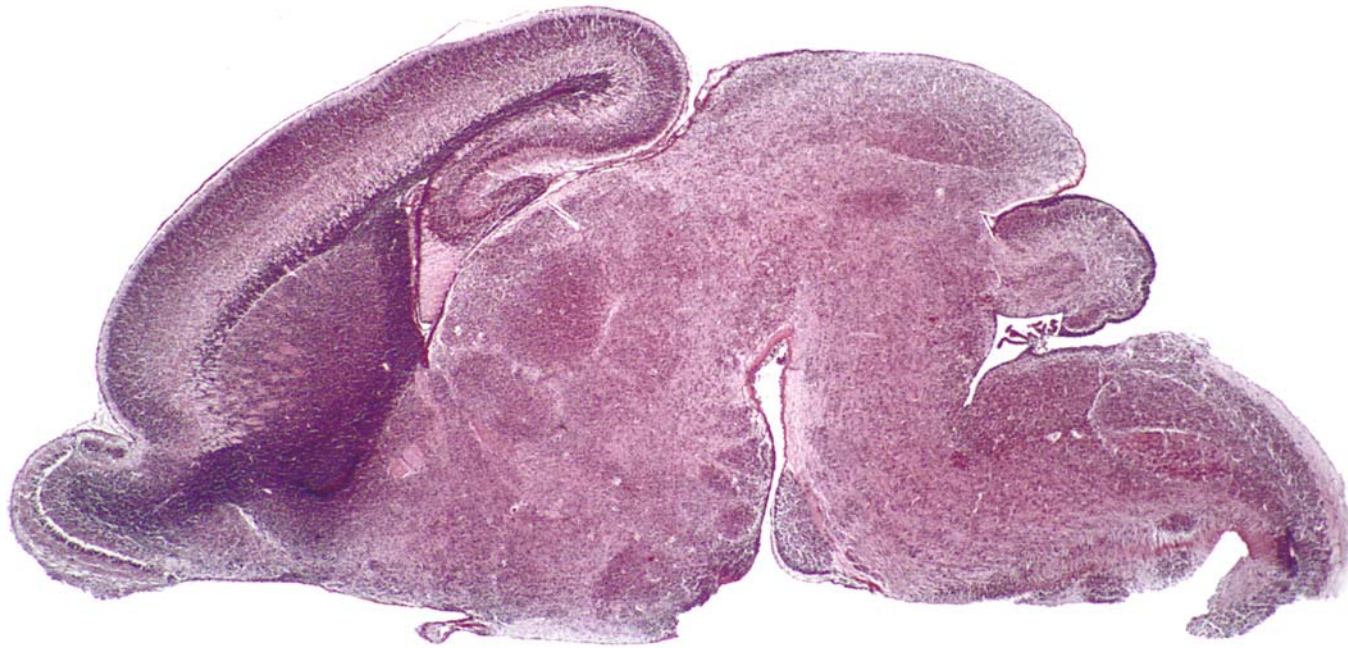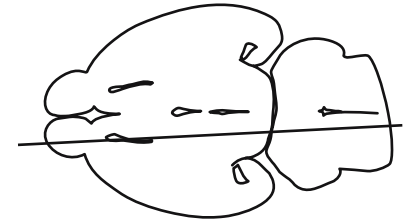
Medulla:

Spinal cord:

Pons:

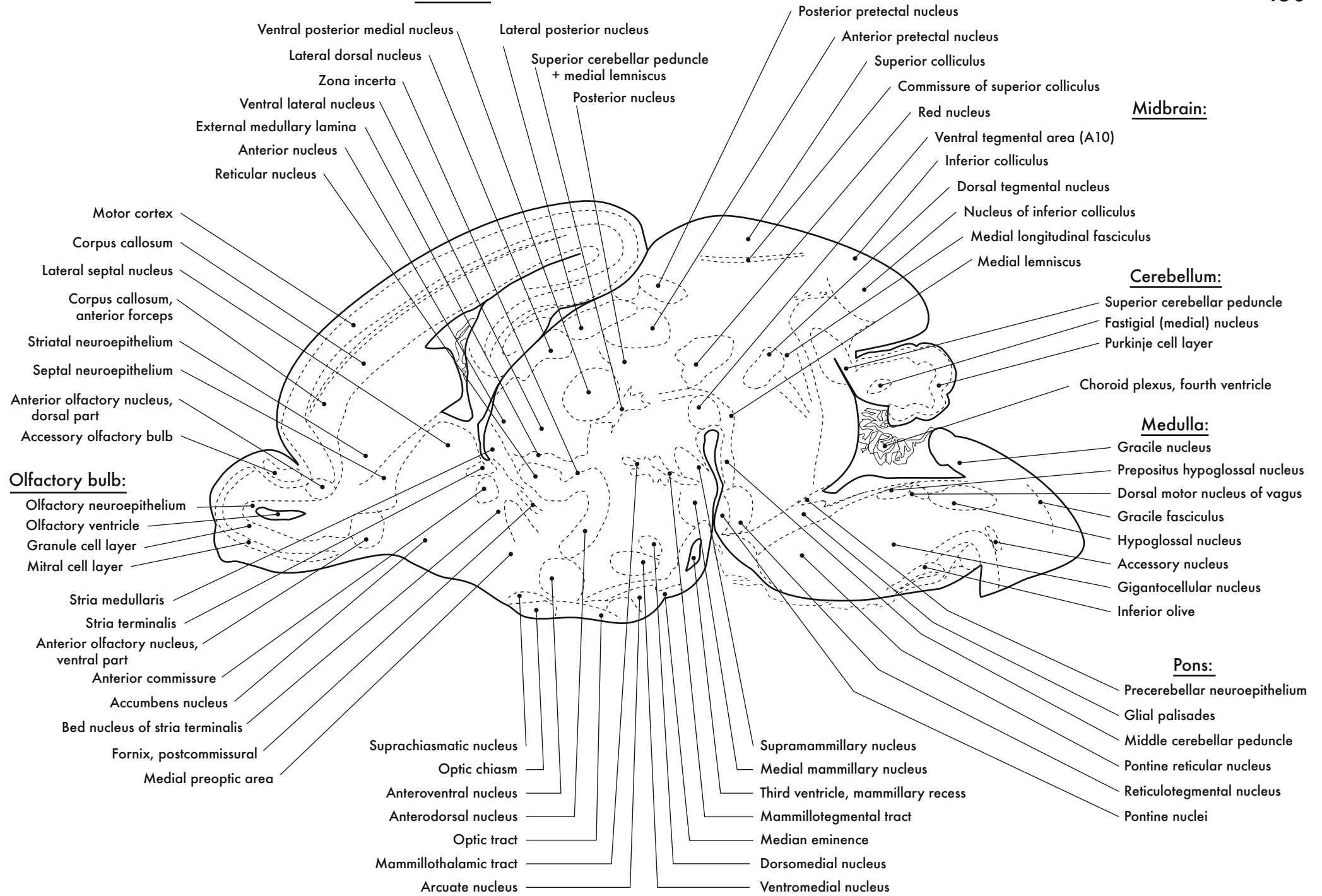
Hypothalamus:



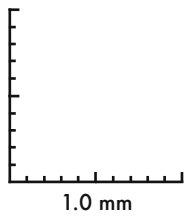
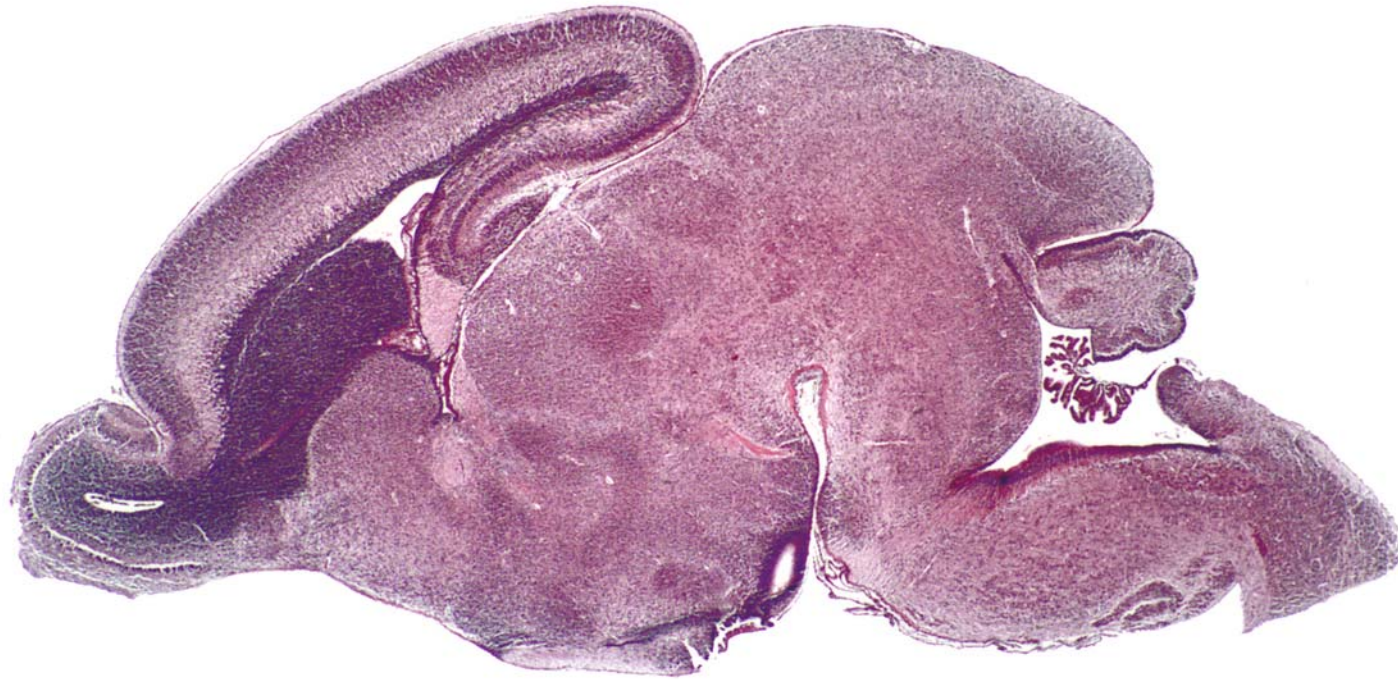


GD 18 SAGITTAL 9

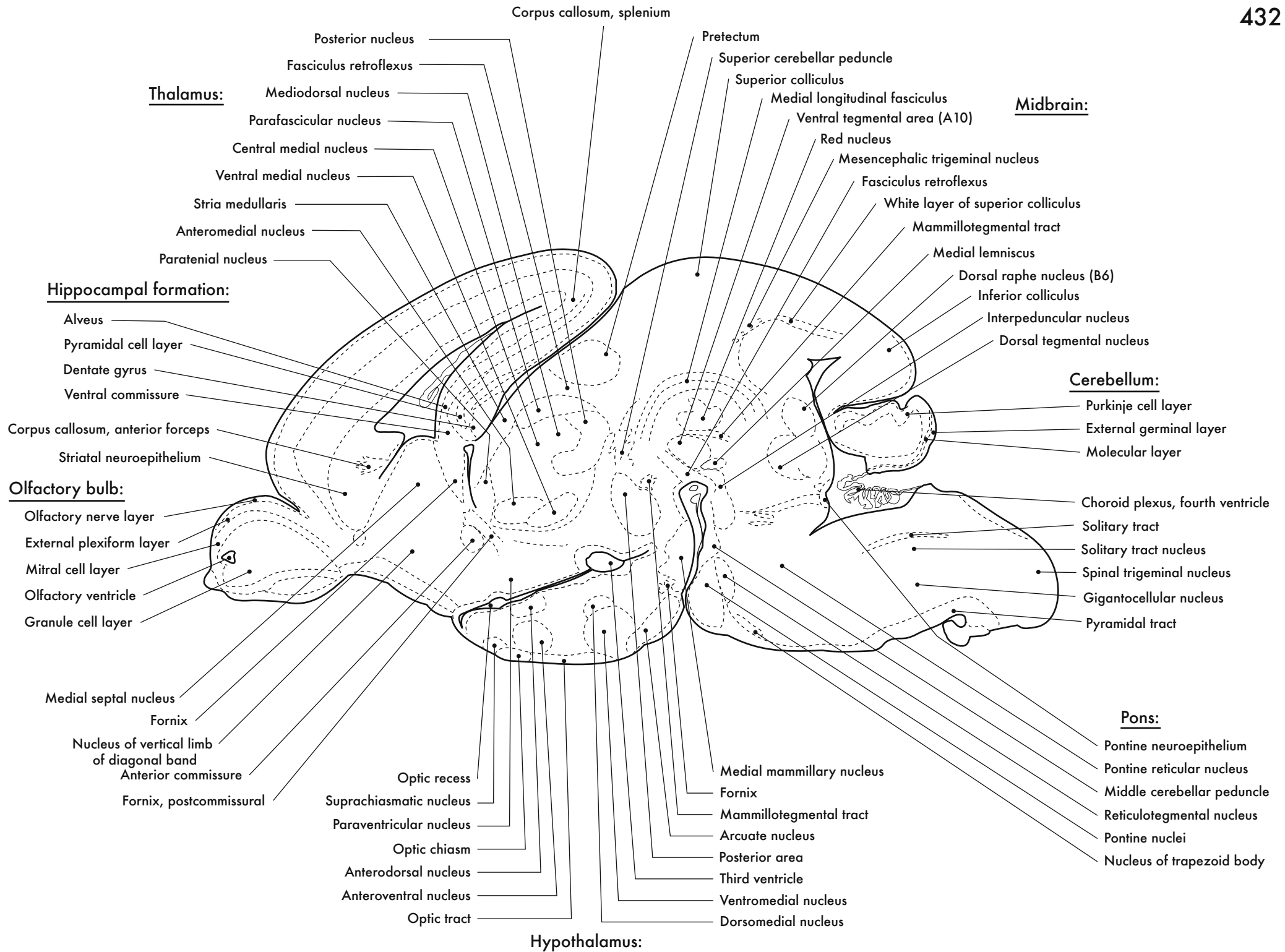
Thalamus:

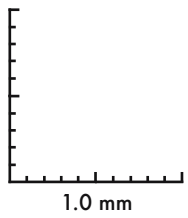
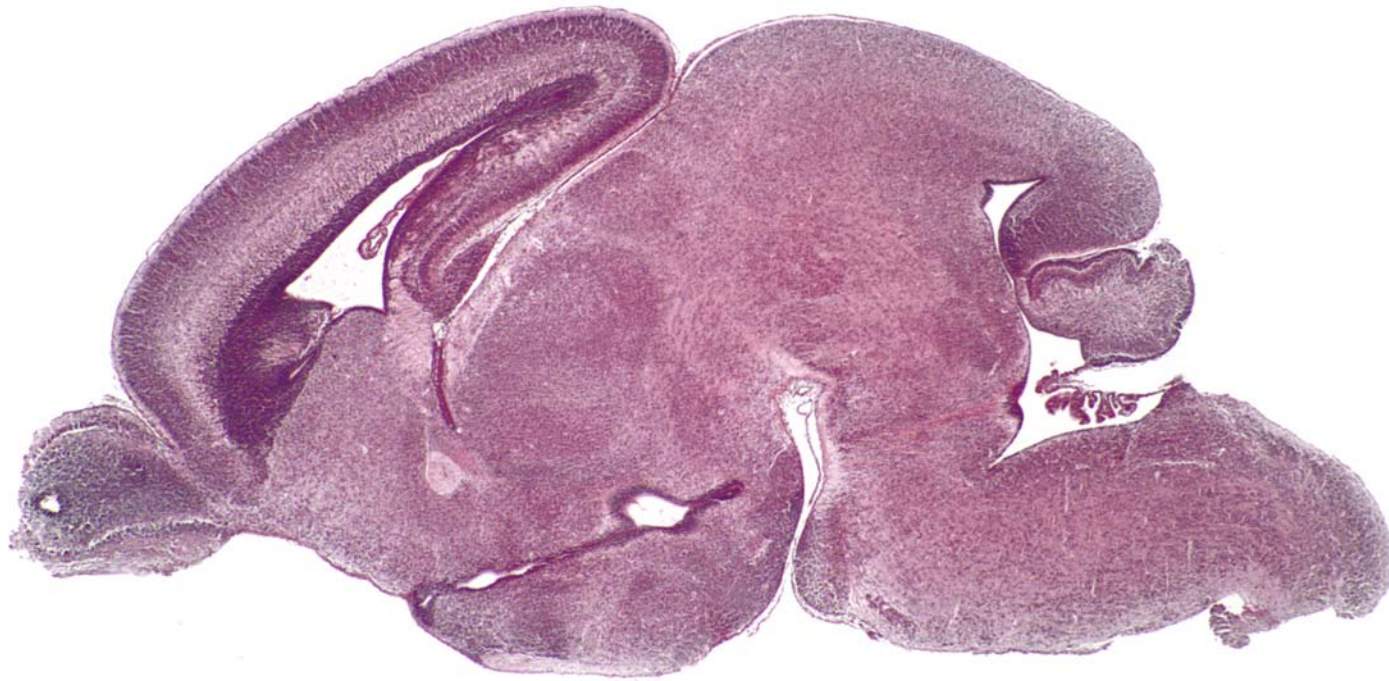
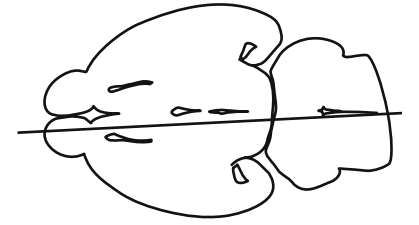




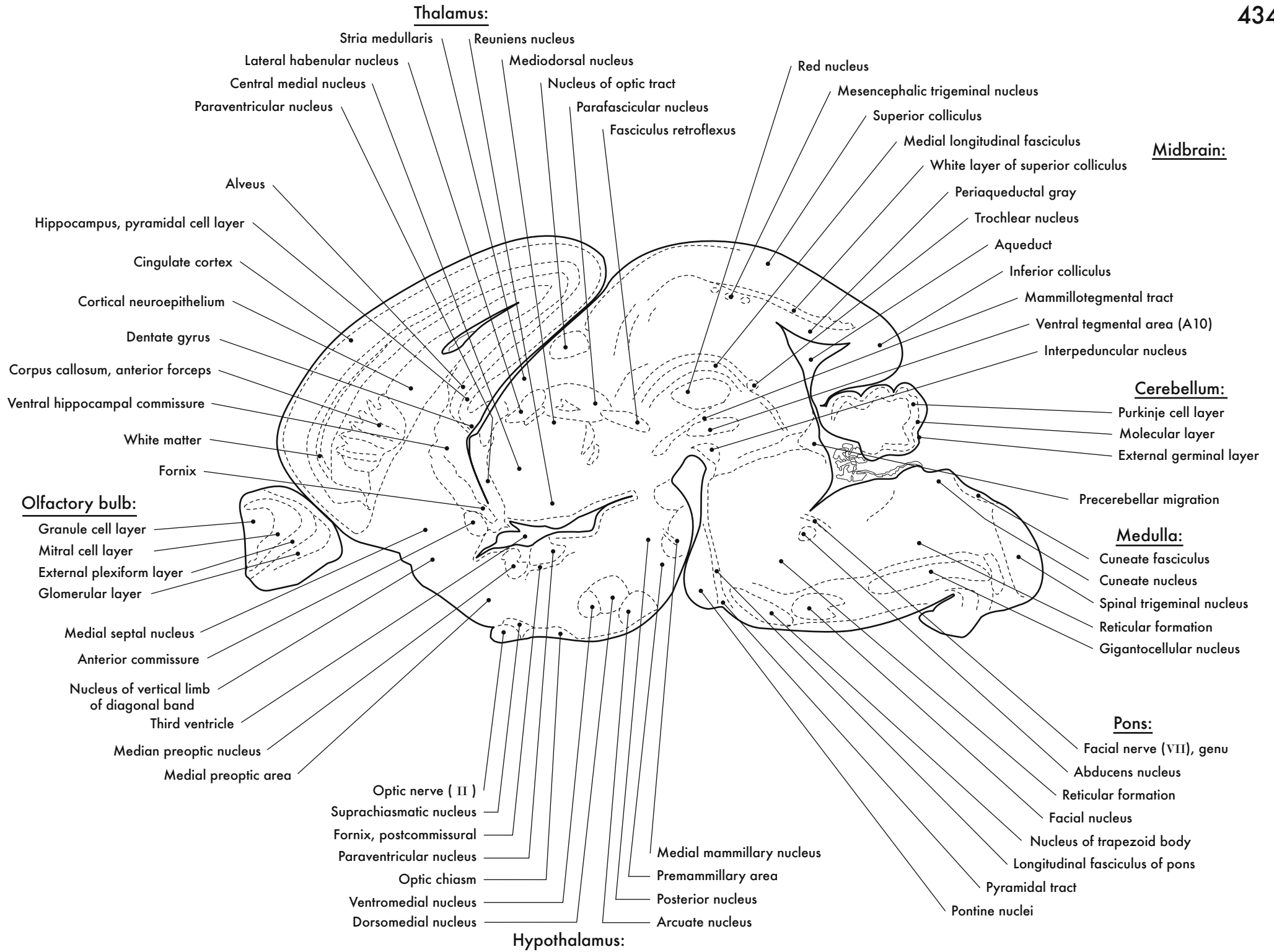


GD 18 SAGITTAL 10

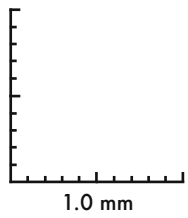
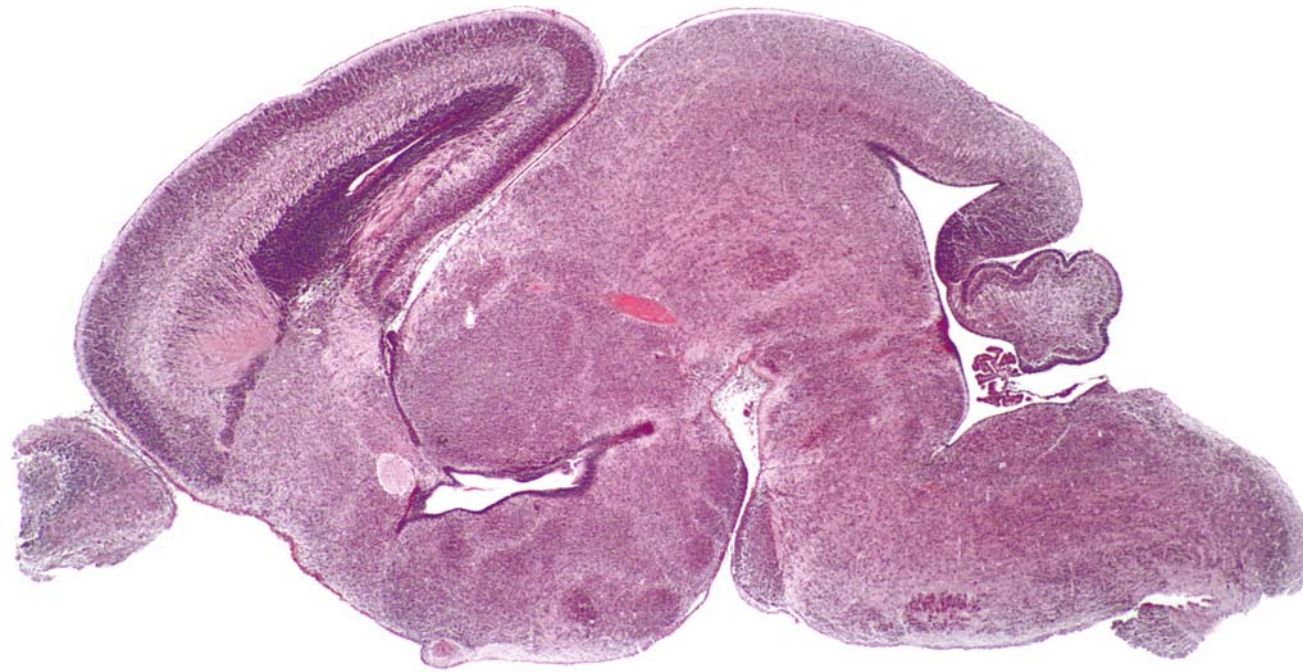
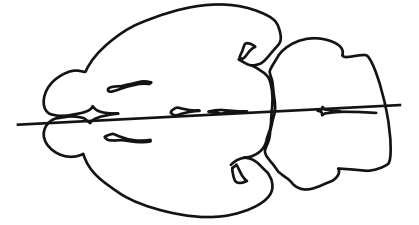




GD 18 SAGITTAL 11

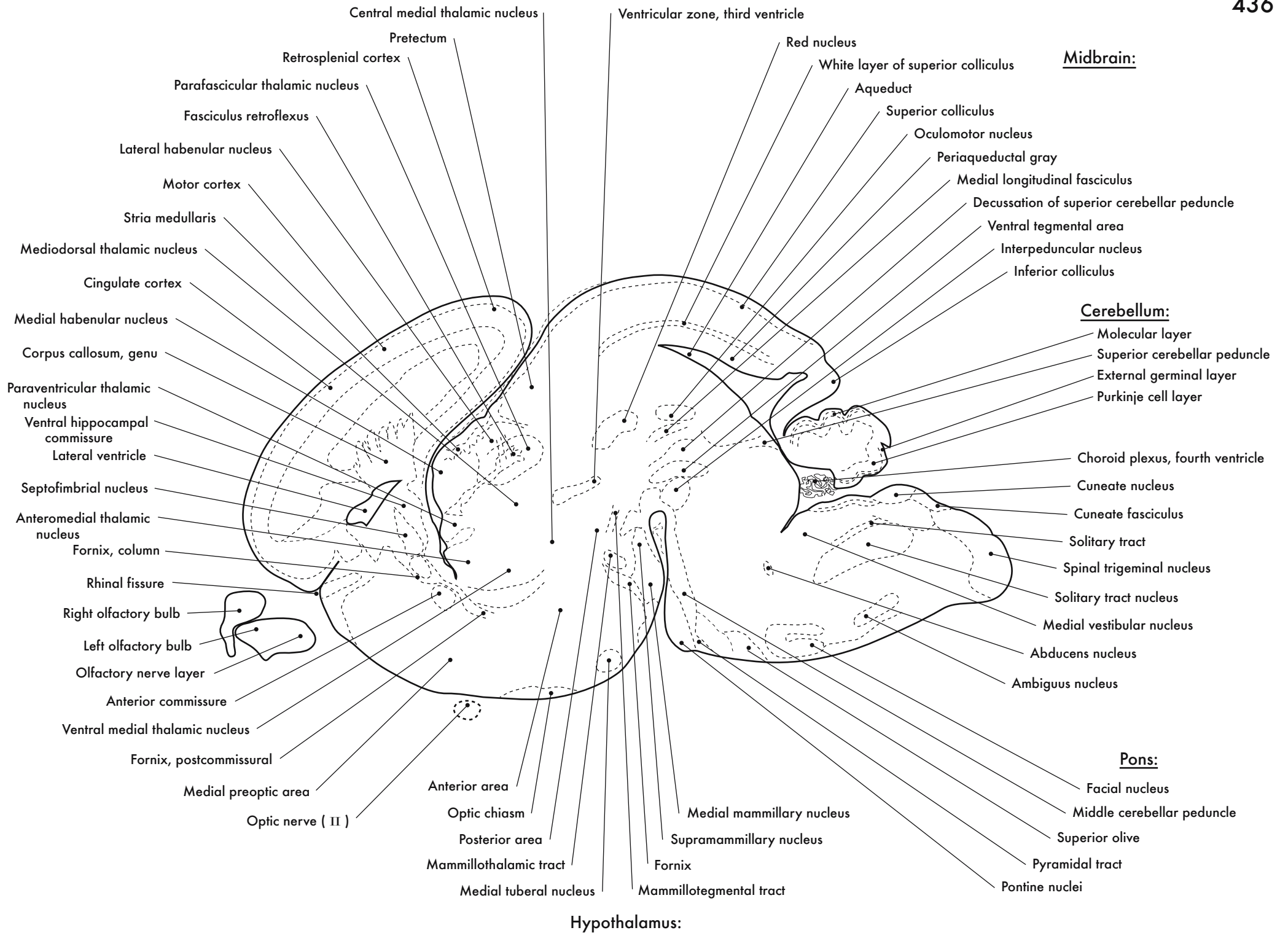


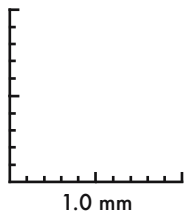
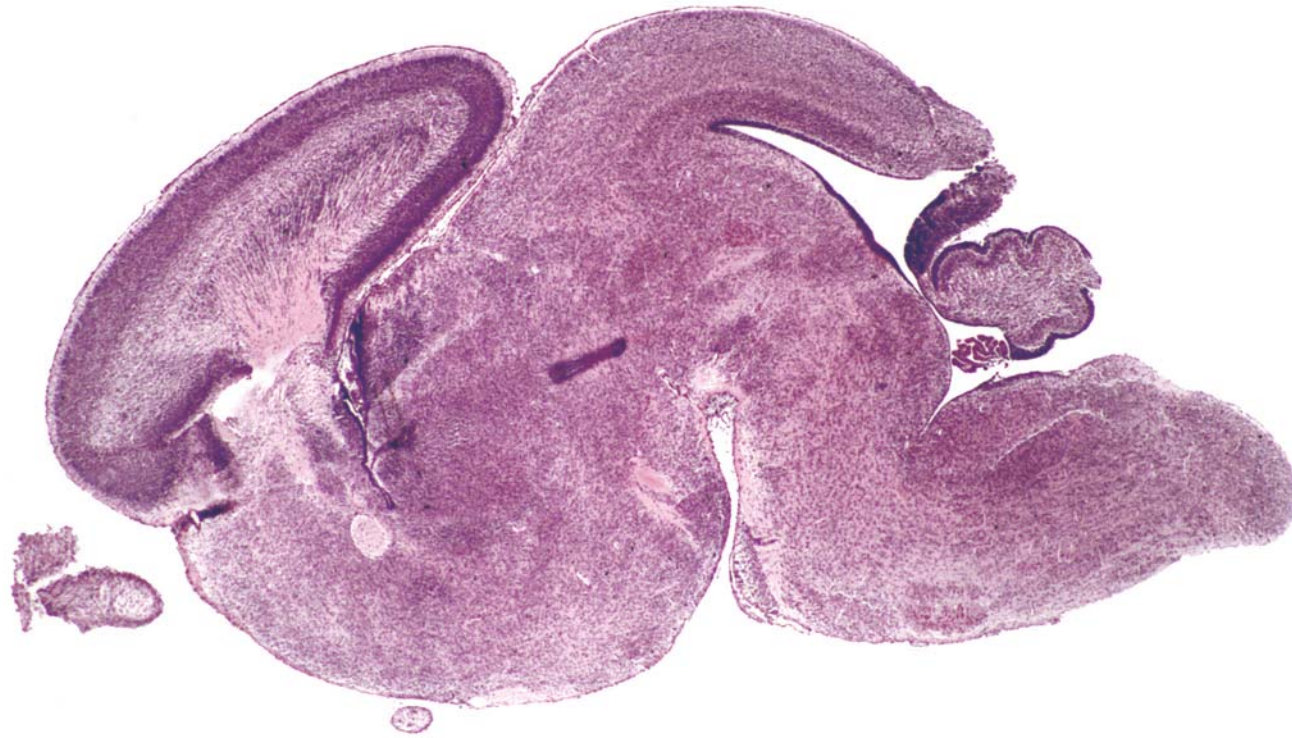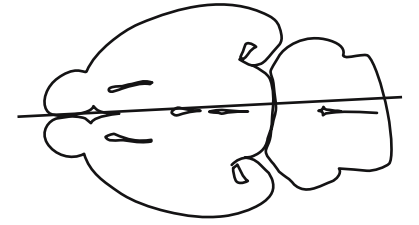




GD 18 SAGITTAL 12

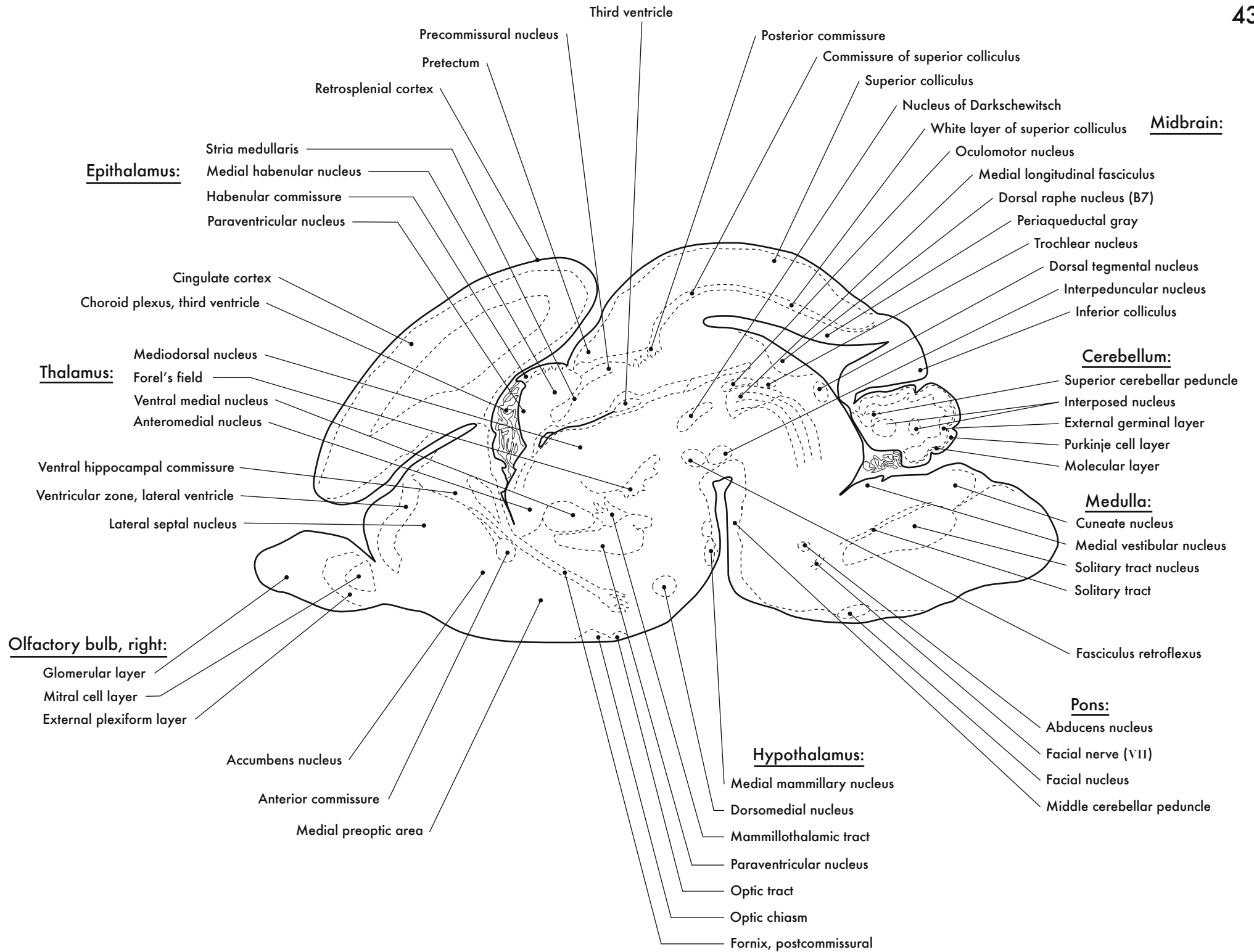
435



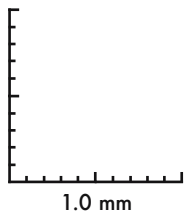
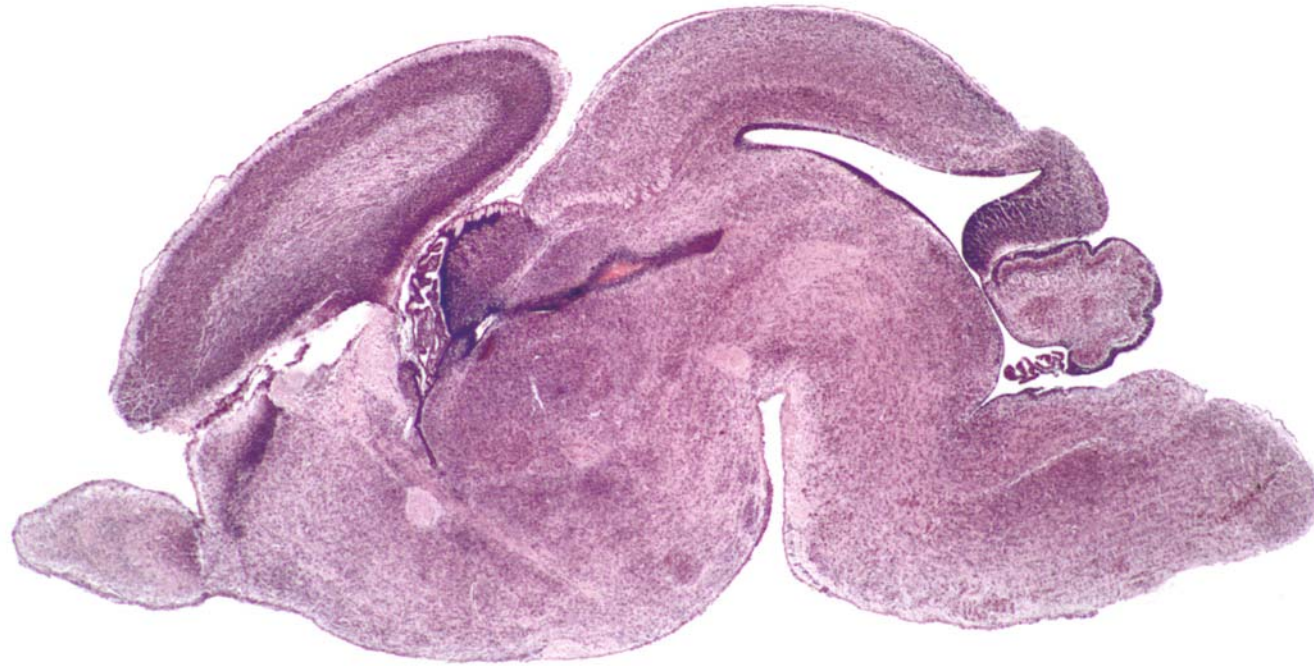
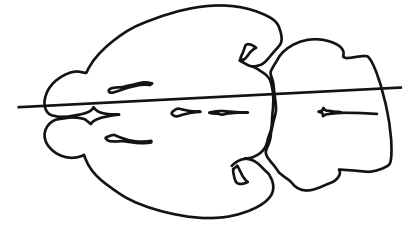


GD 18 SAGITTAL 13

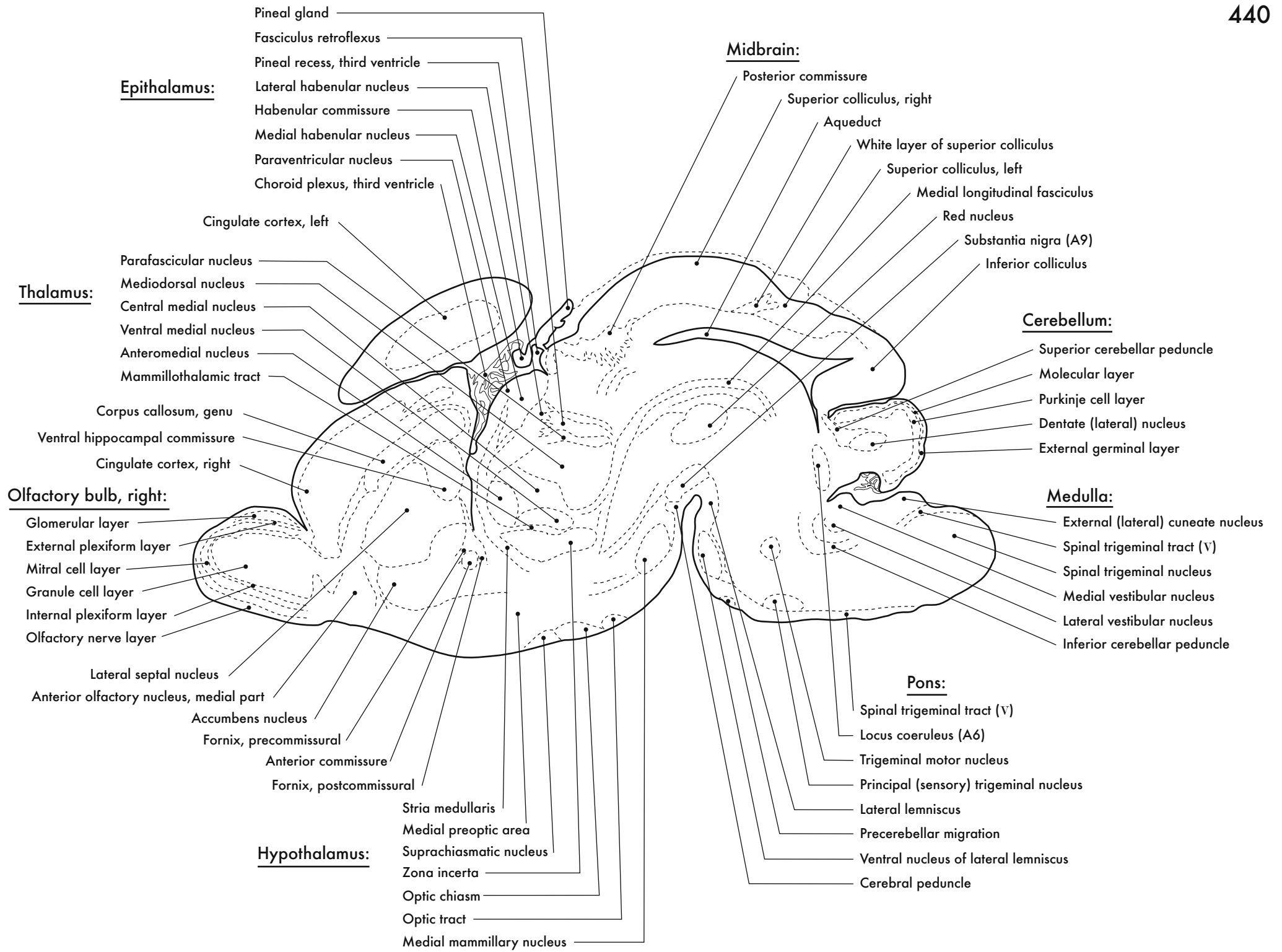
437

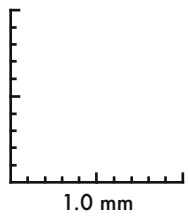
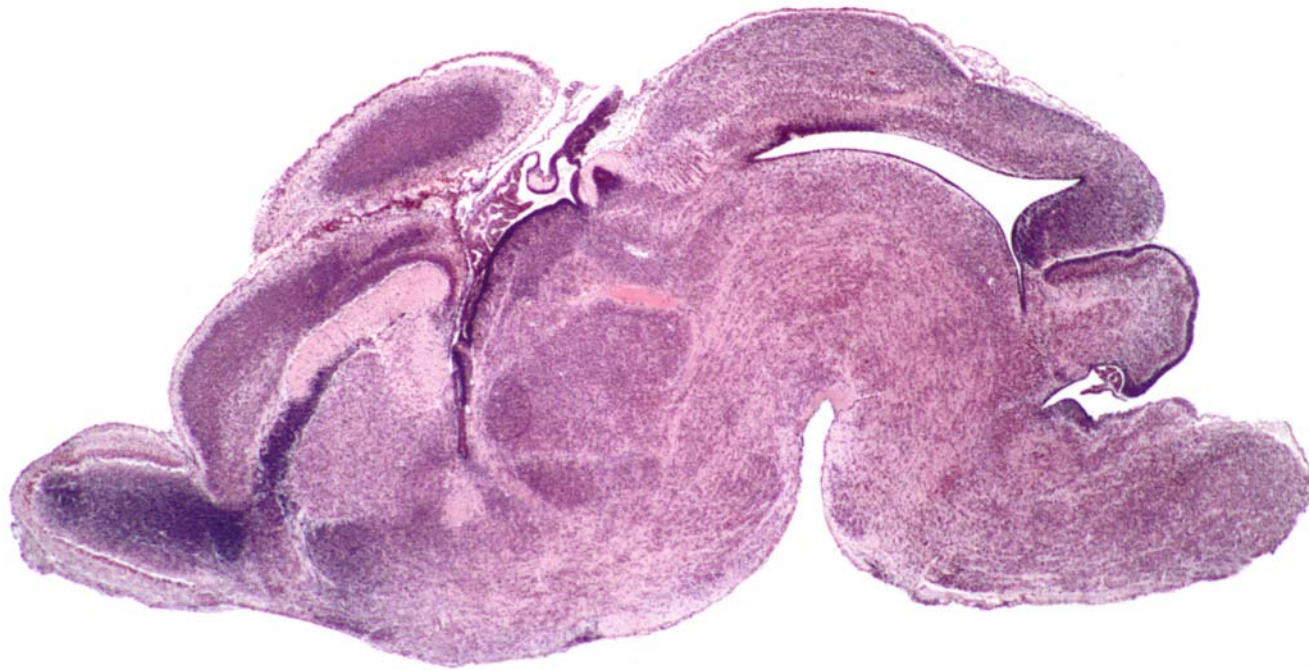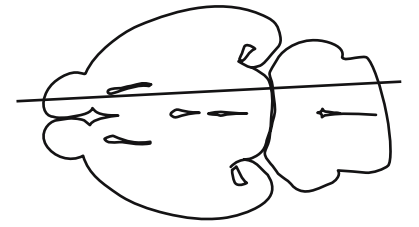




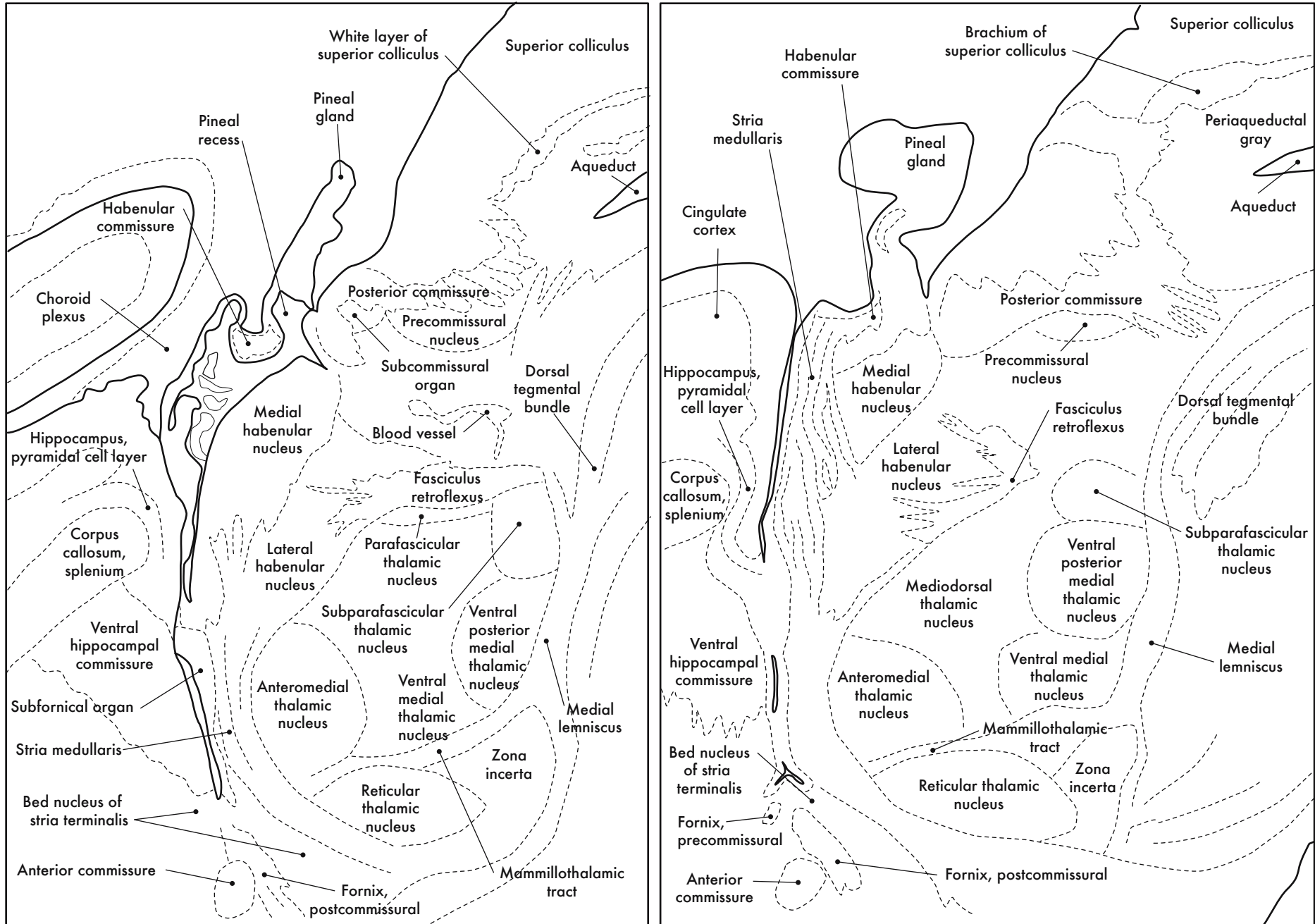


GD 18 SAGITTAL 14



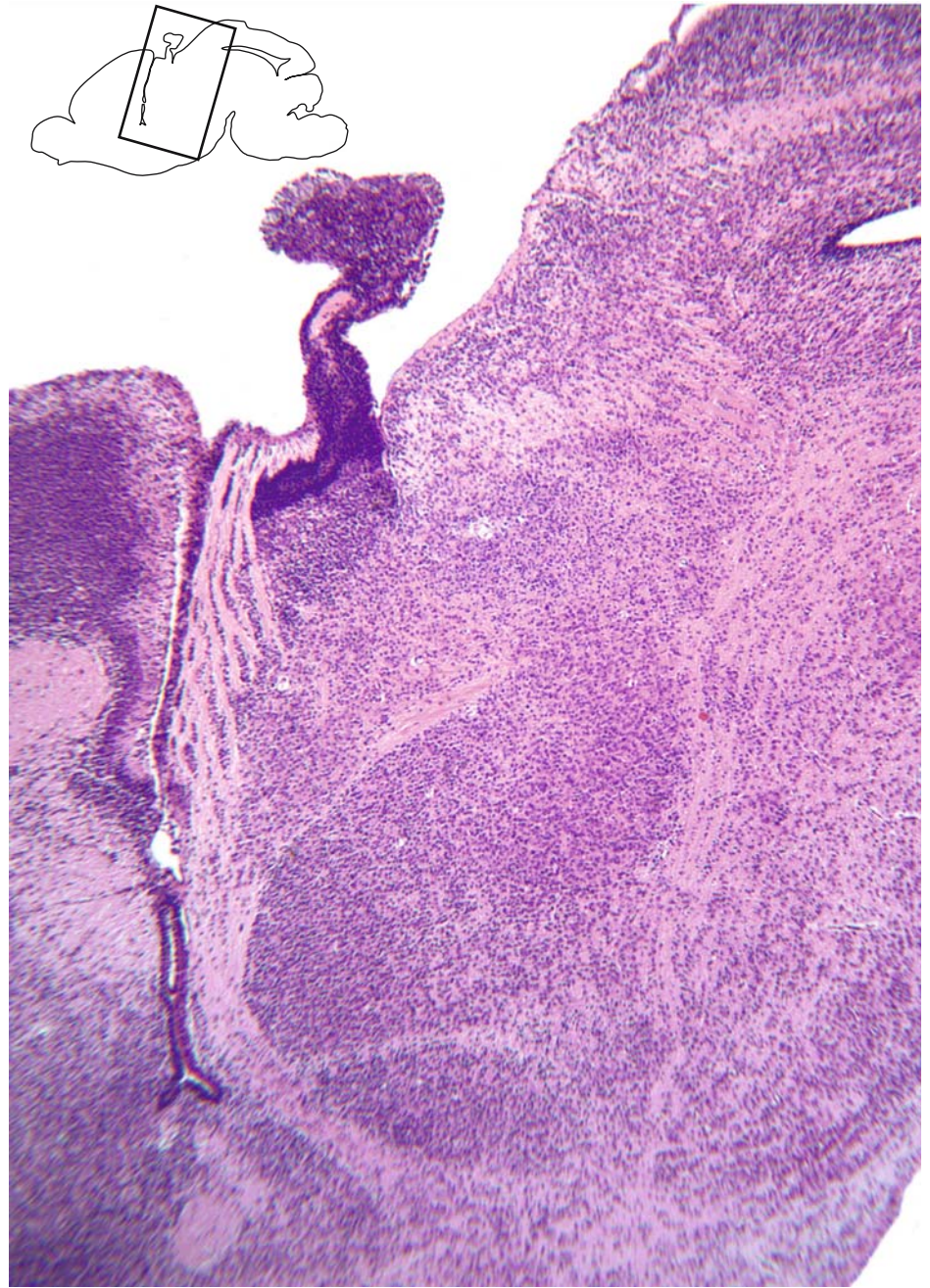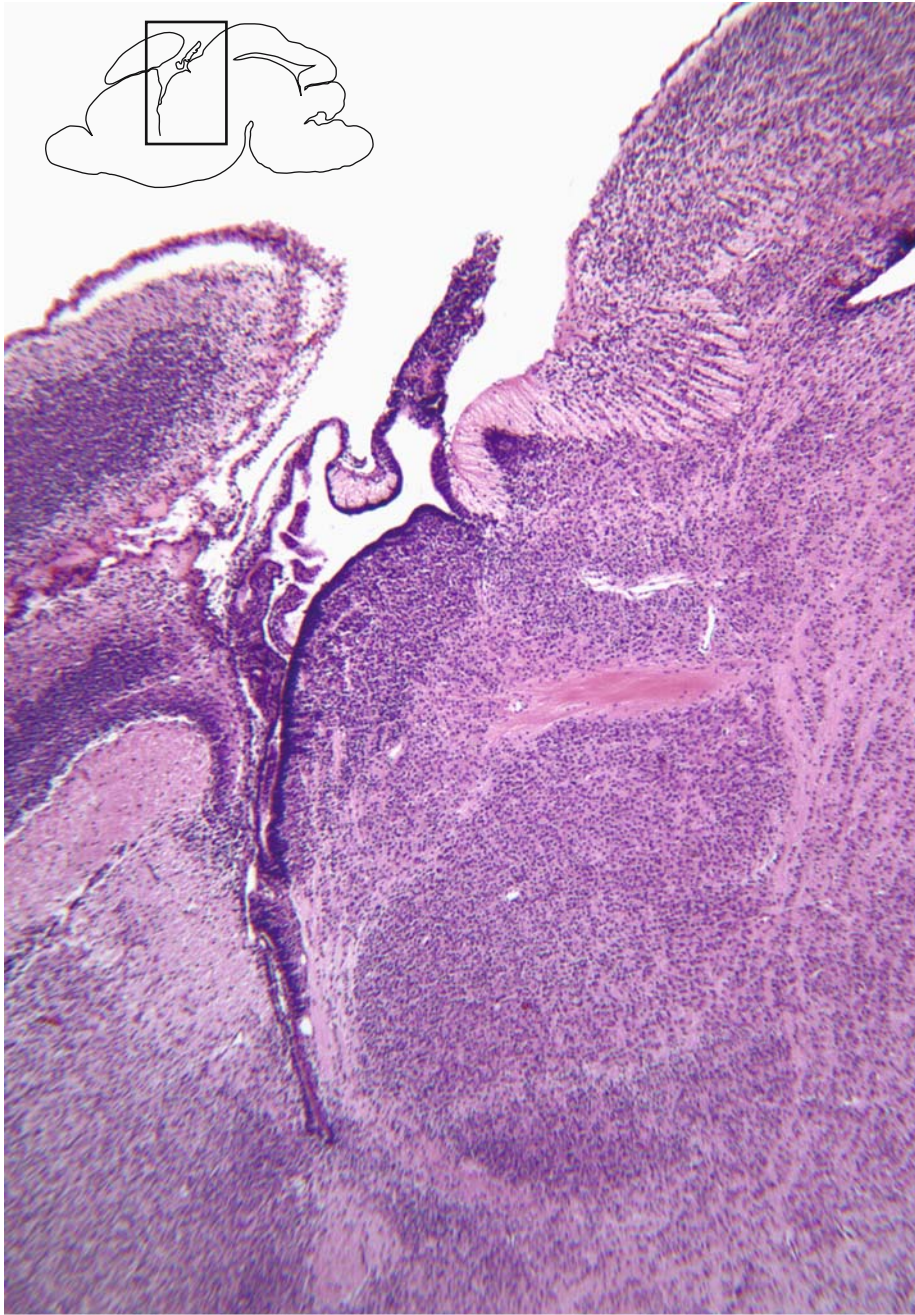


GD 18 SAGITTAL 15



Midline forebrain structures



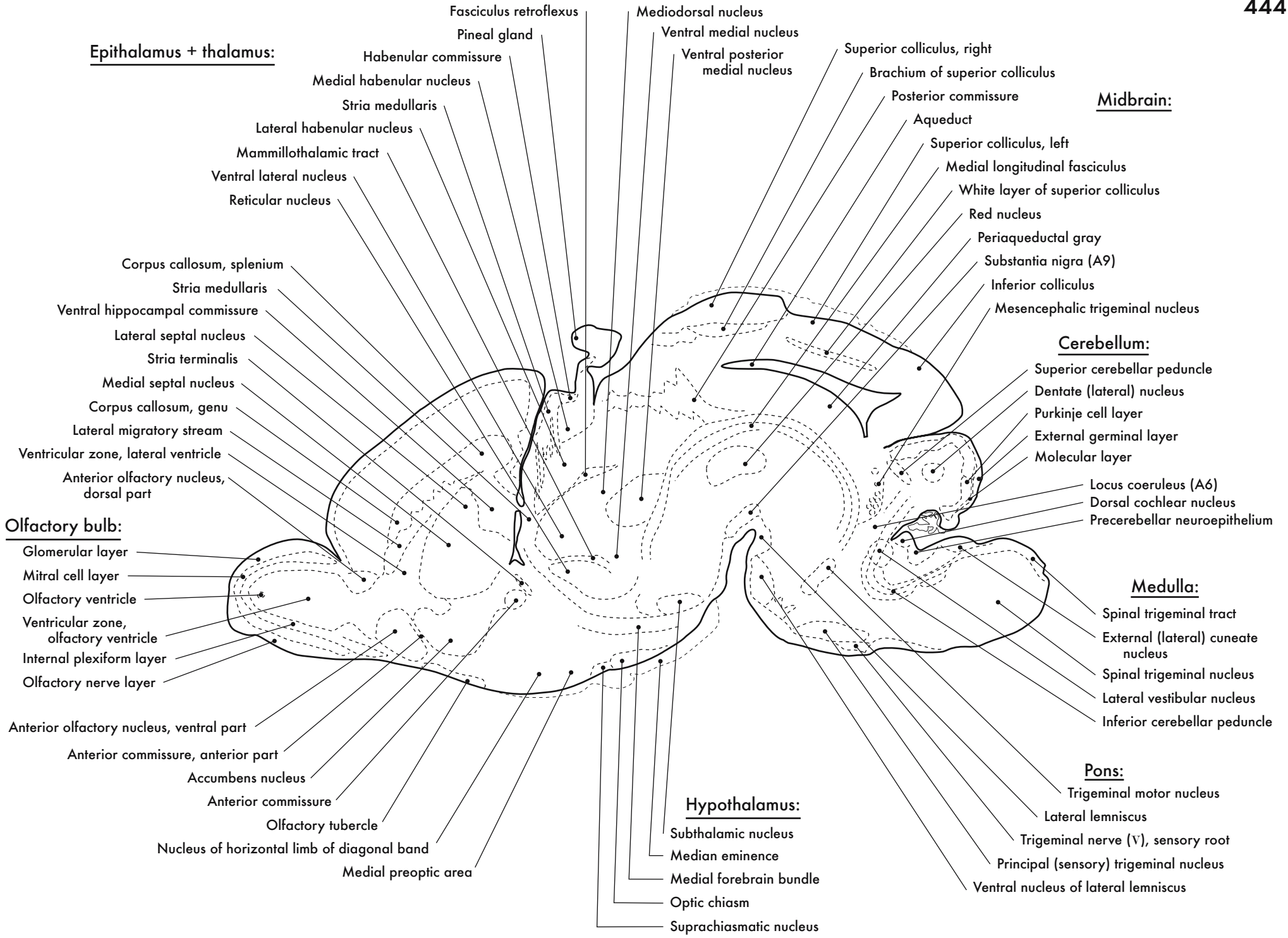


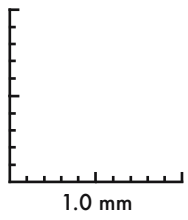
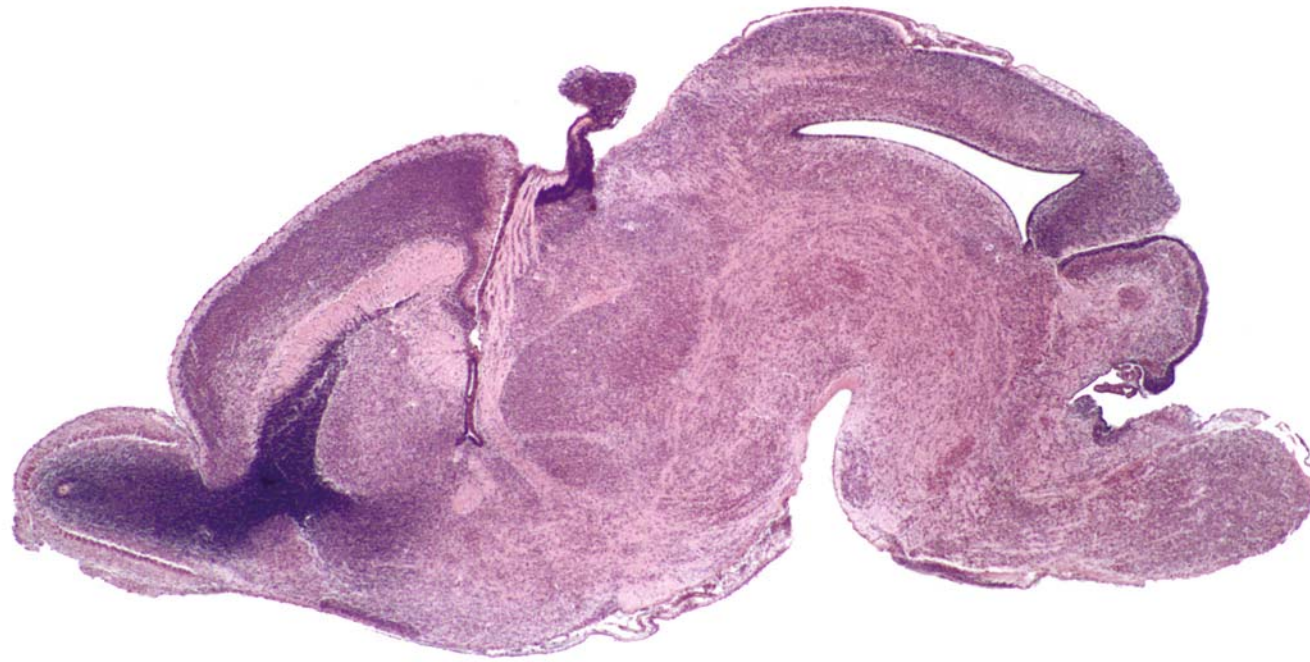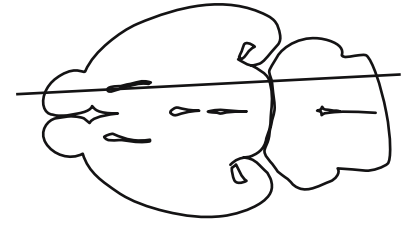
0.5 mm

GD 18 SAGITTAL 16

443








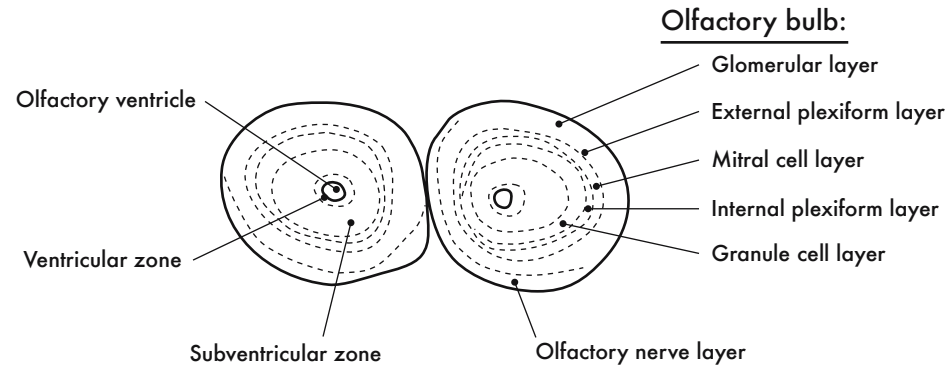
GD 18 SAGITTAL 17

HP denotes image enlargement

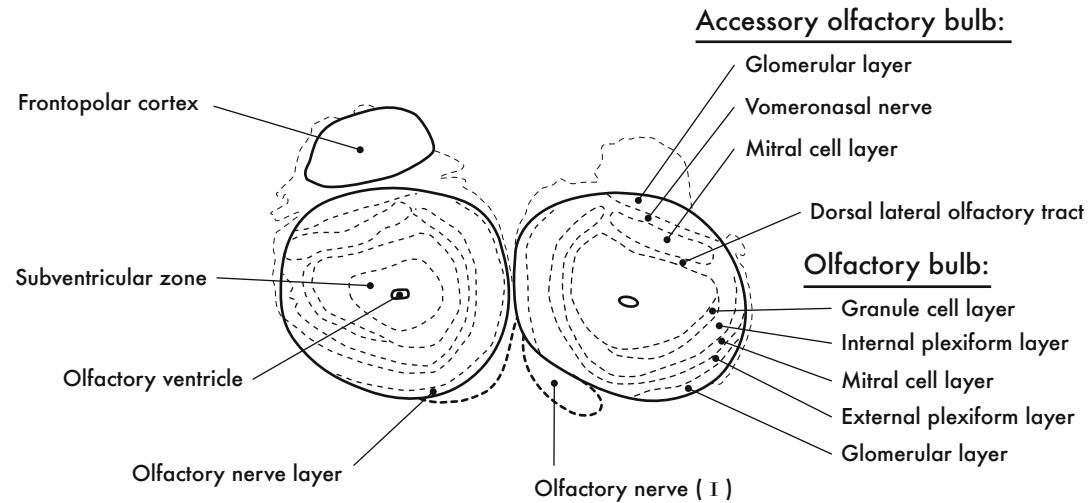


**GESTATIONAL DAY 18 (GD 18)  
CORONAL SECTIONS**

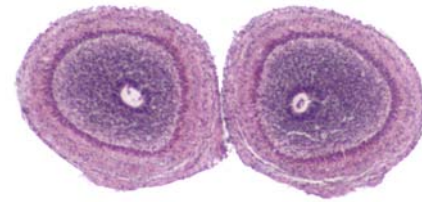




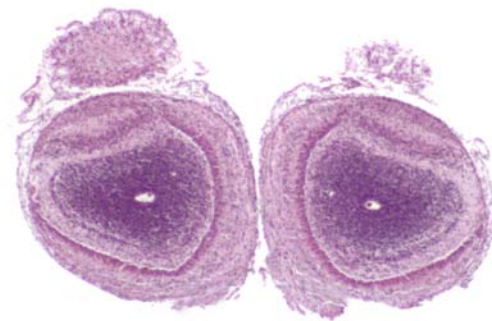

GD 18 CORONAL 1A



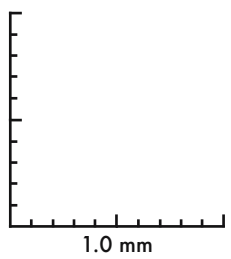
GD 18 CORONAL 1B

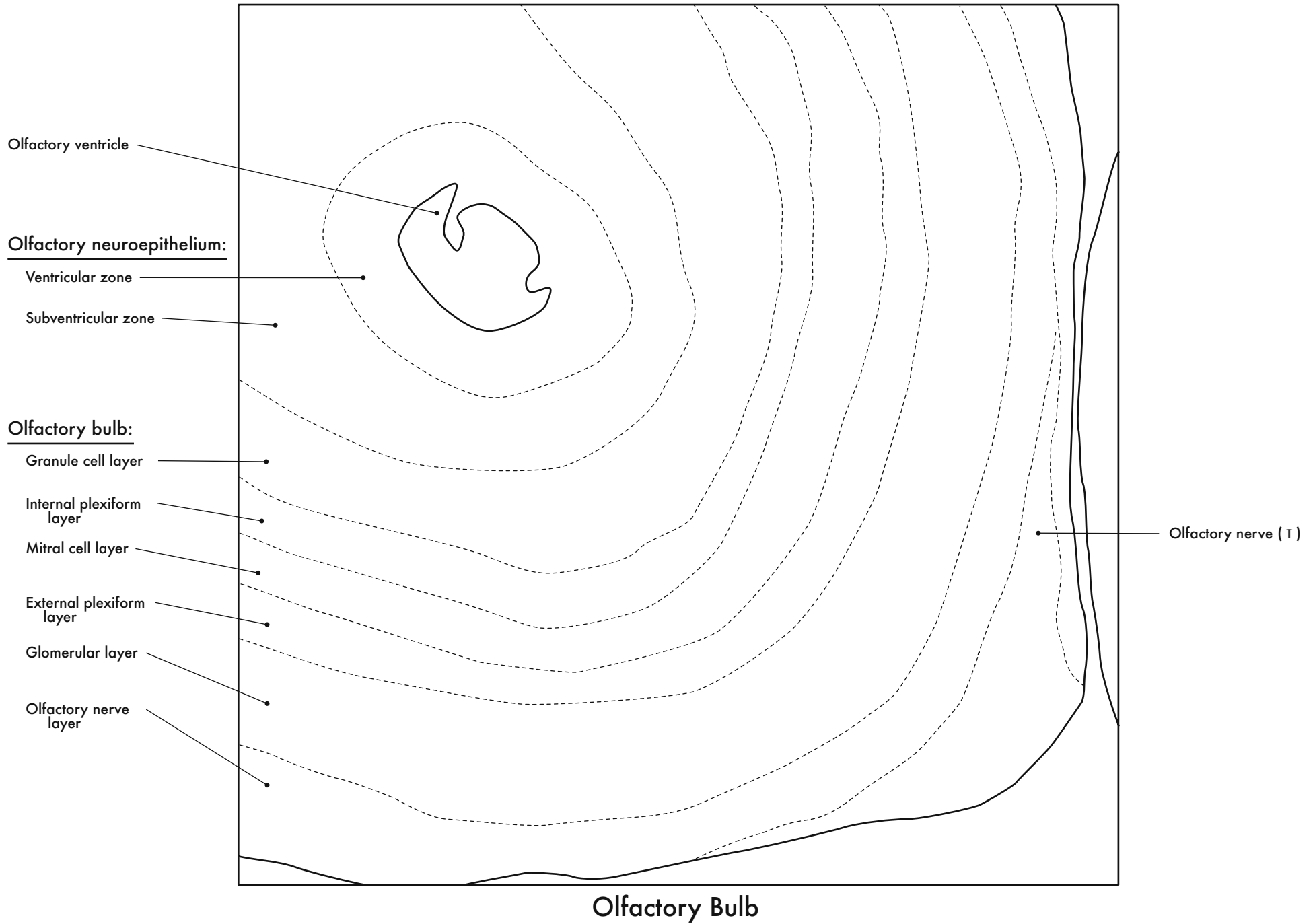


GD 18 CORONAL 1A

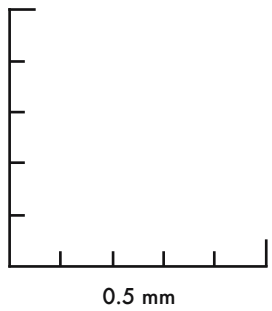
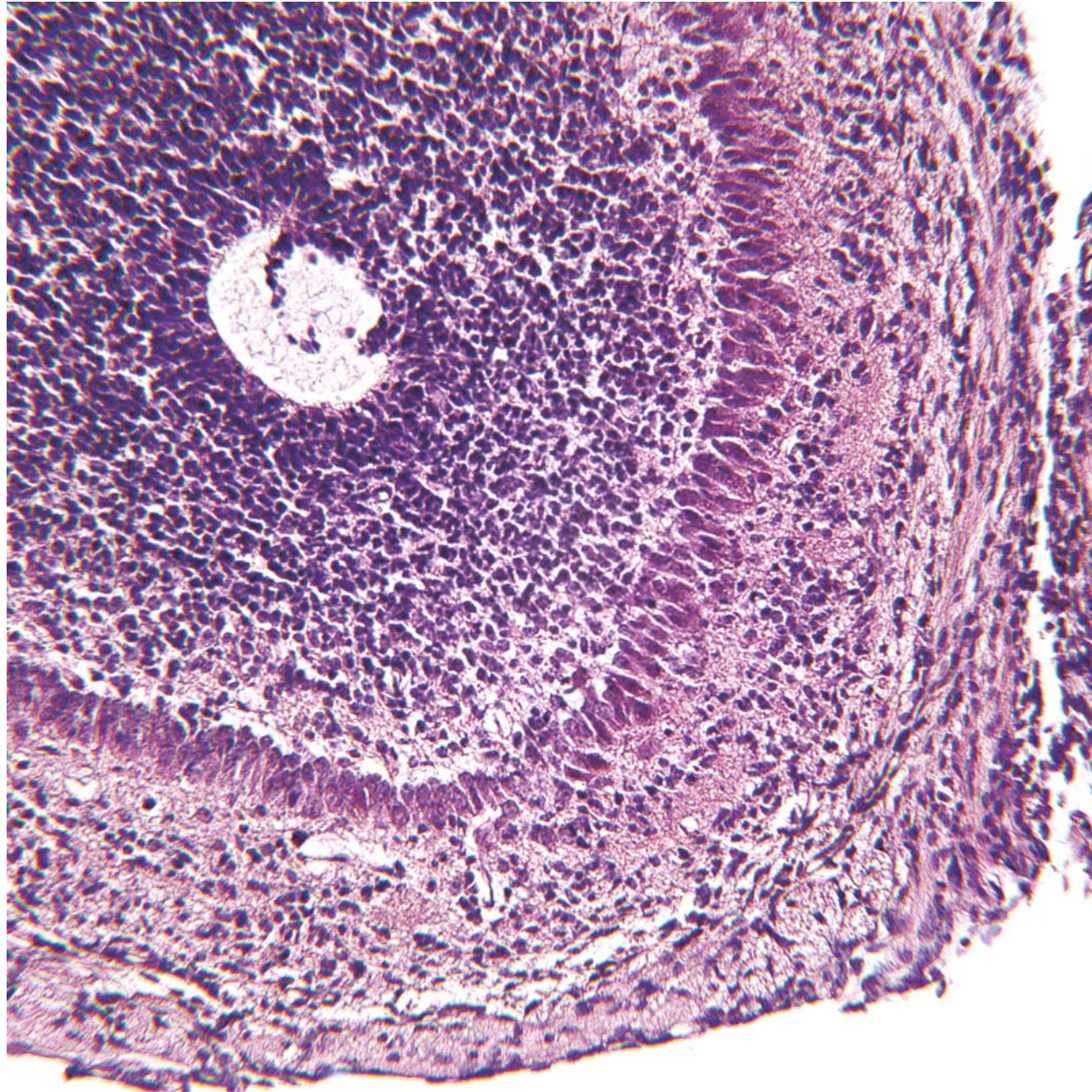
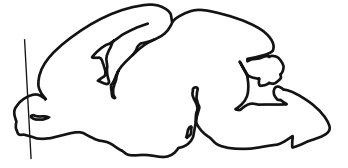
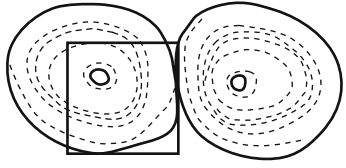


GD 18 CORONAL 1B



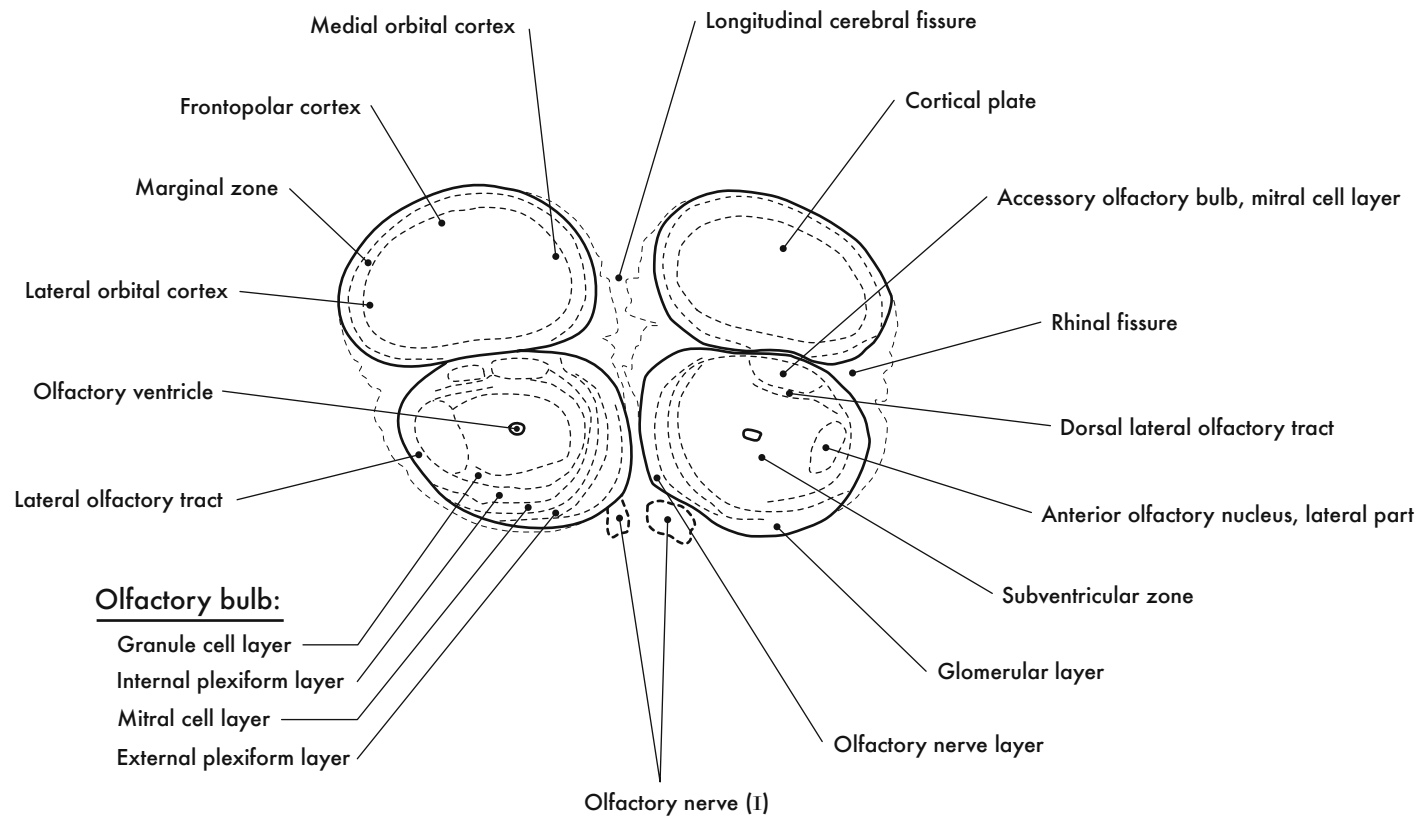


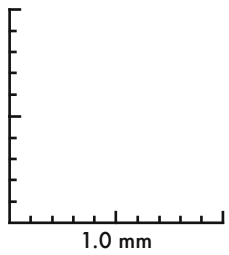
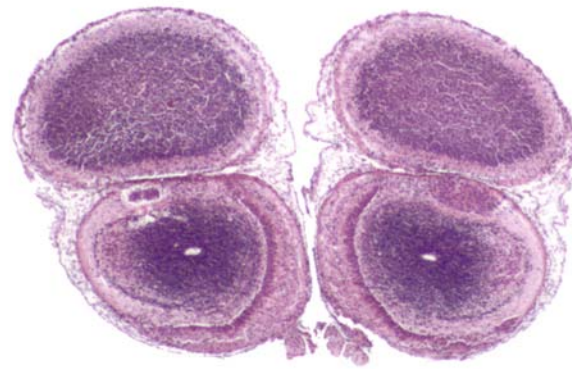





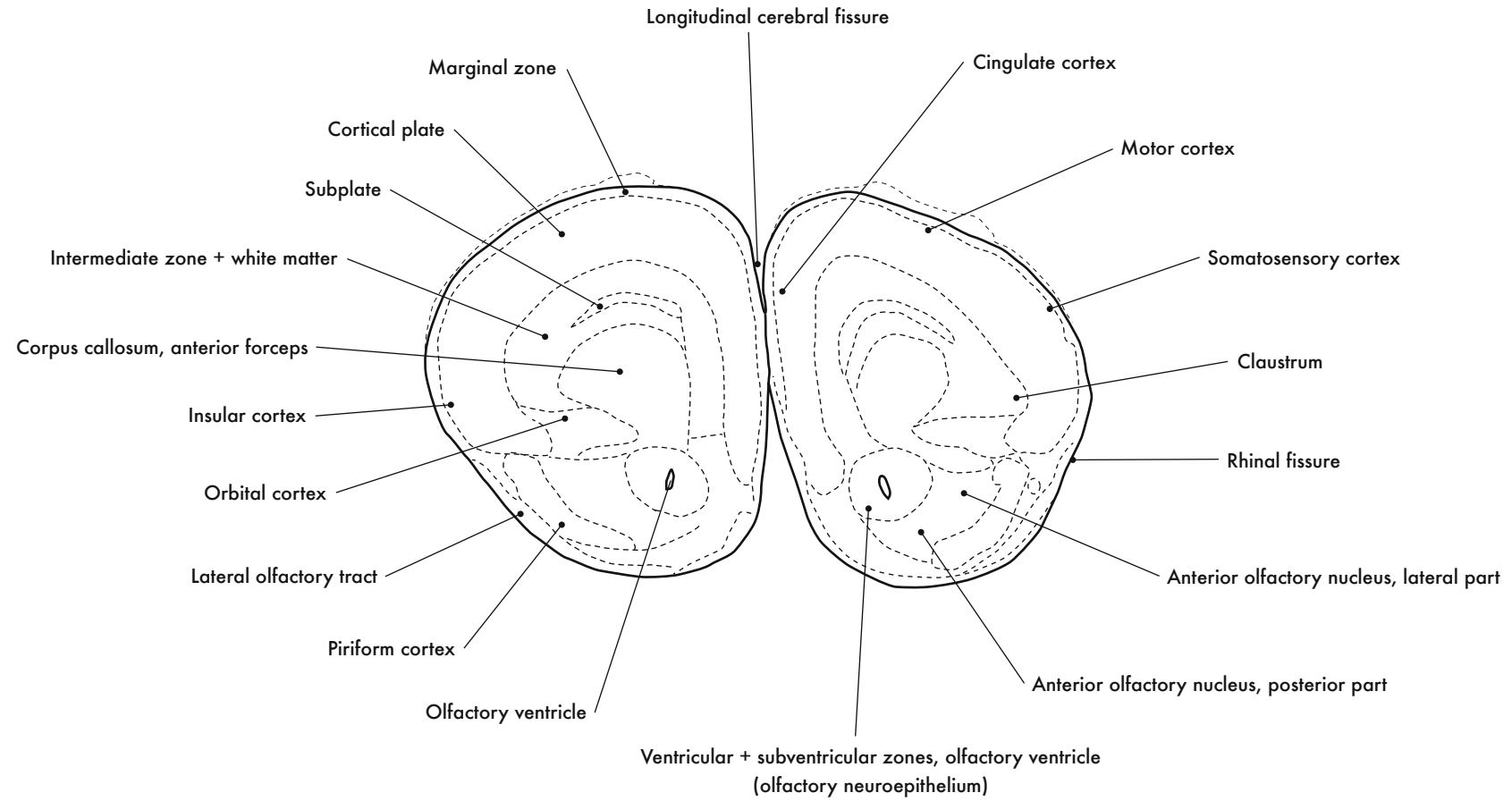
GD 18 CORONAL 2

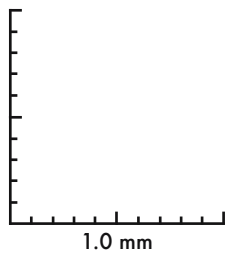
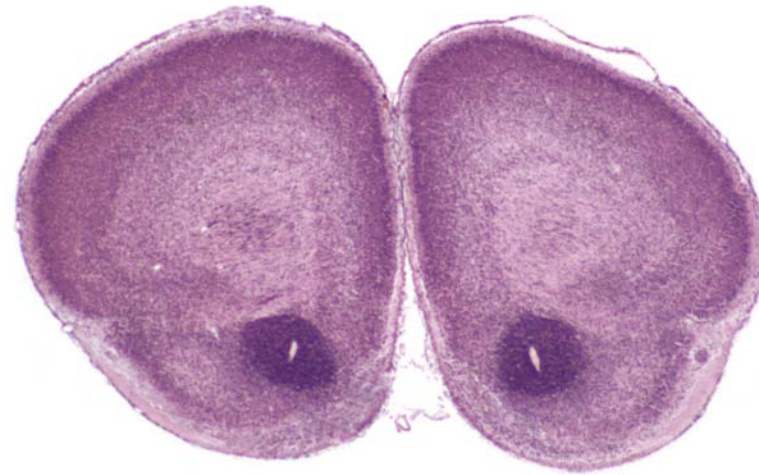






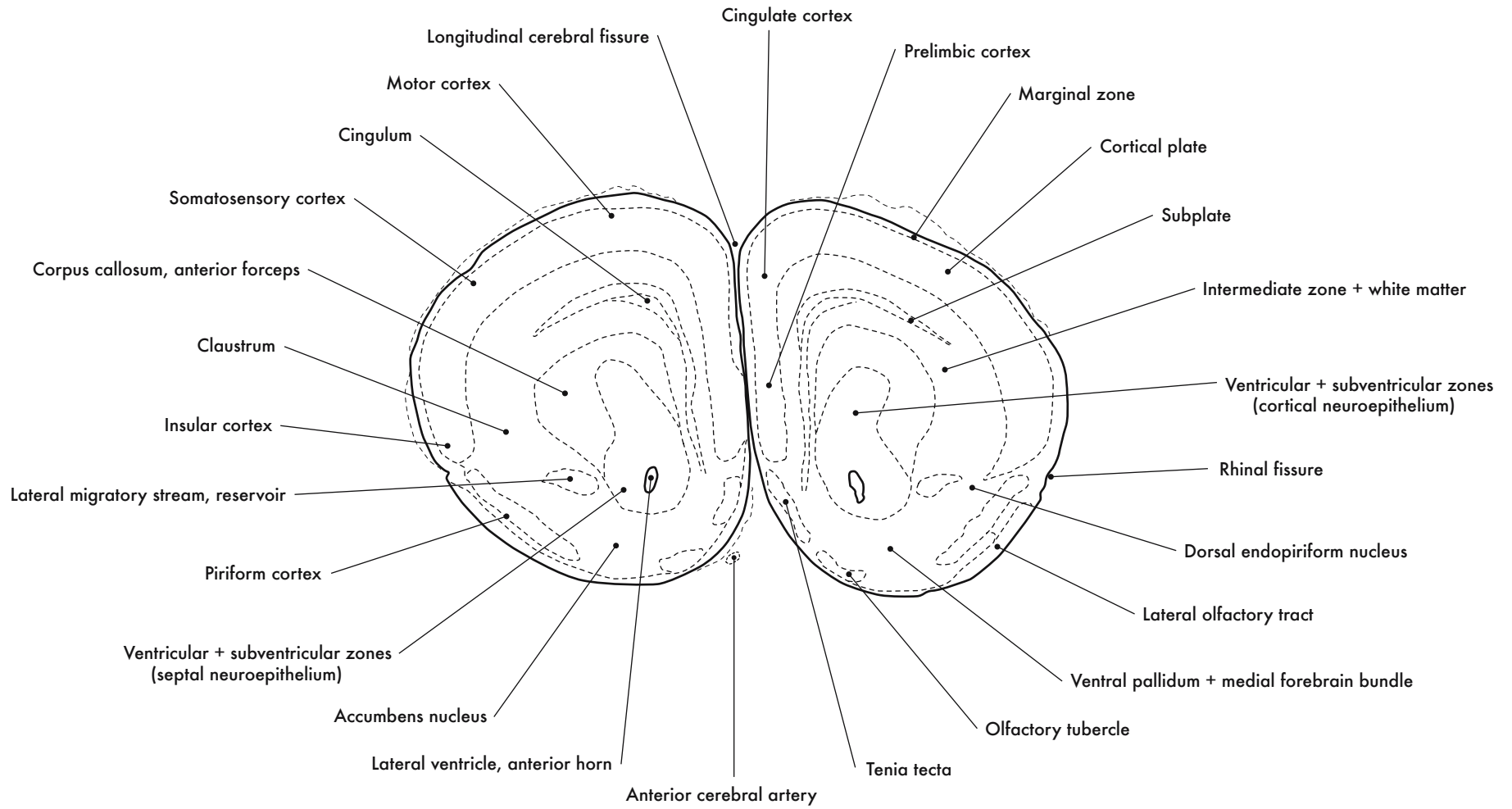
GD 18 CORONAL 3

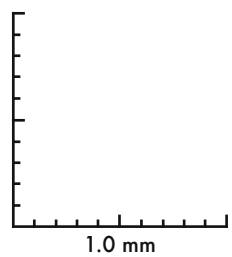
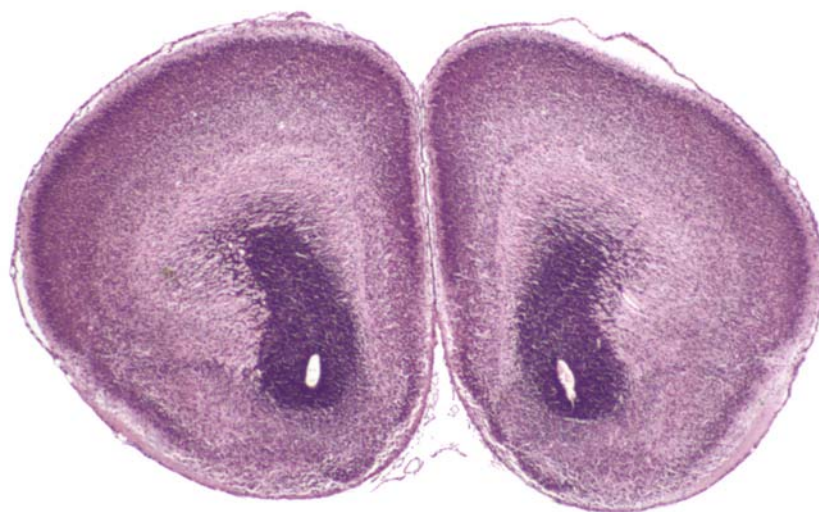
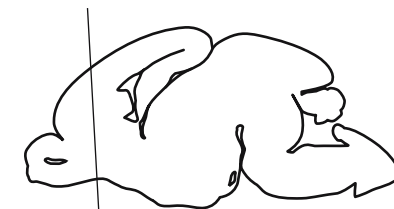


GD 18 CORONAL 4

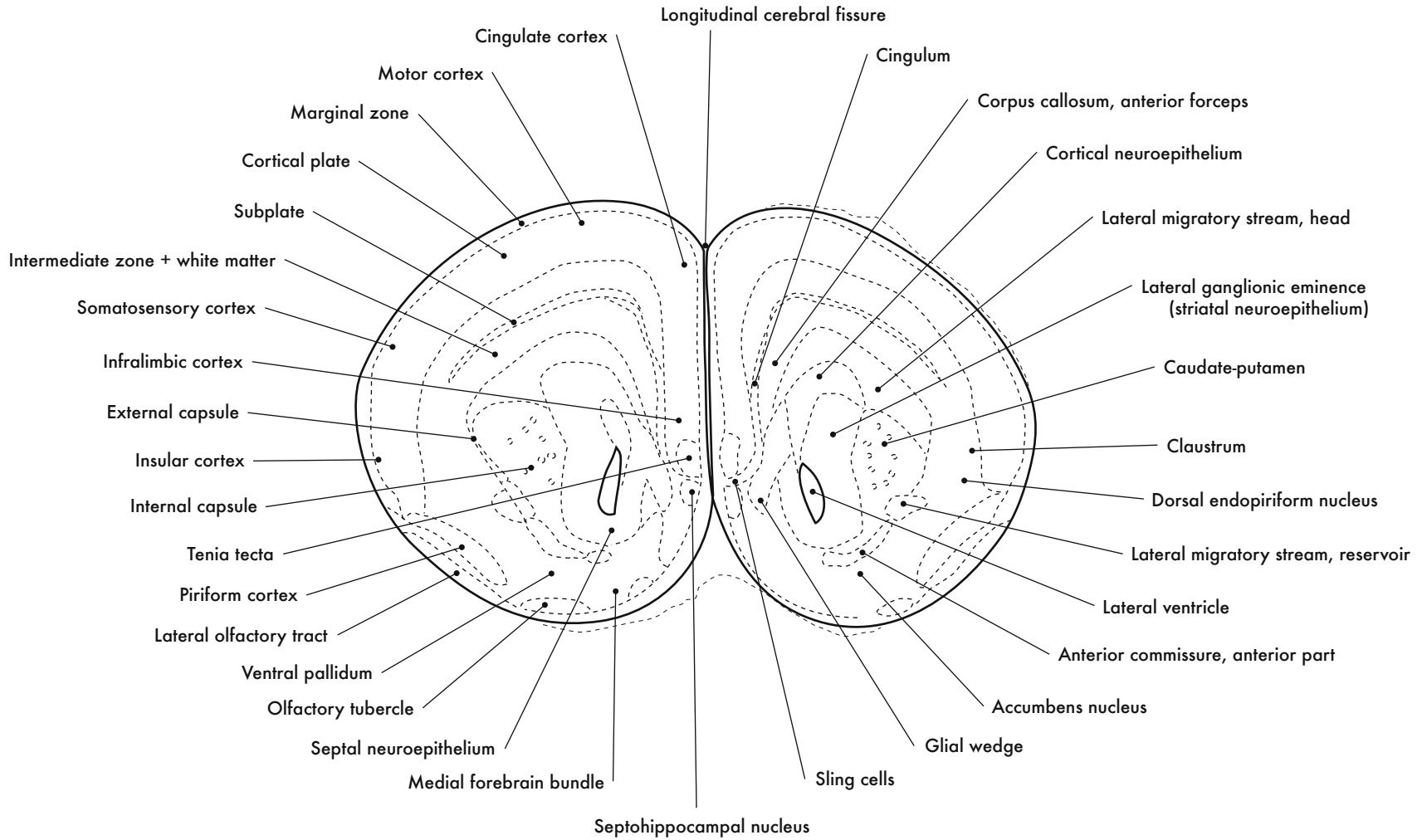


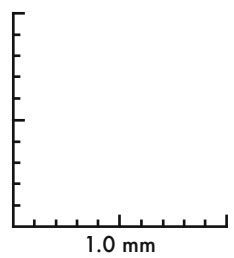
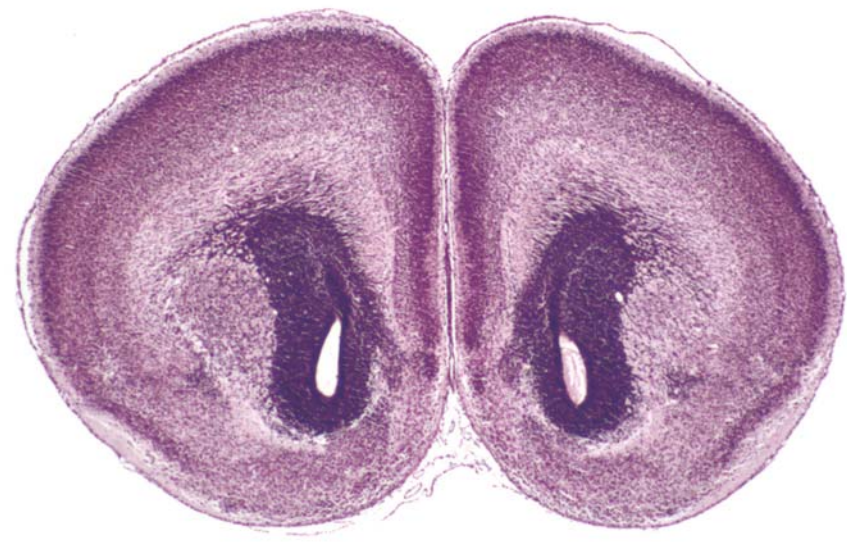
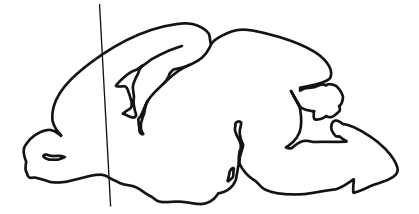




GD 18 CORONAL 5

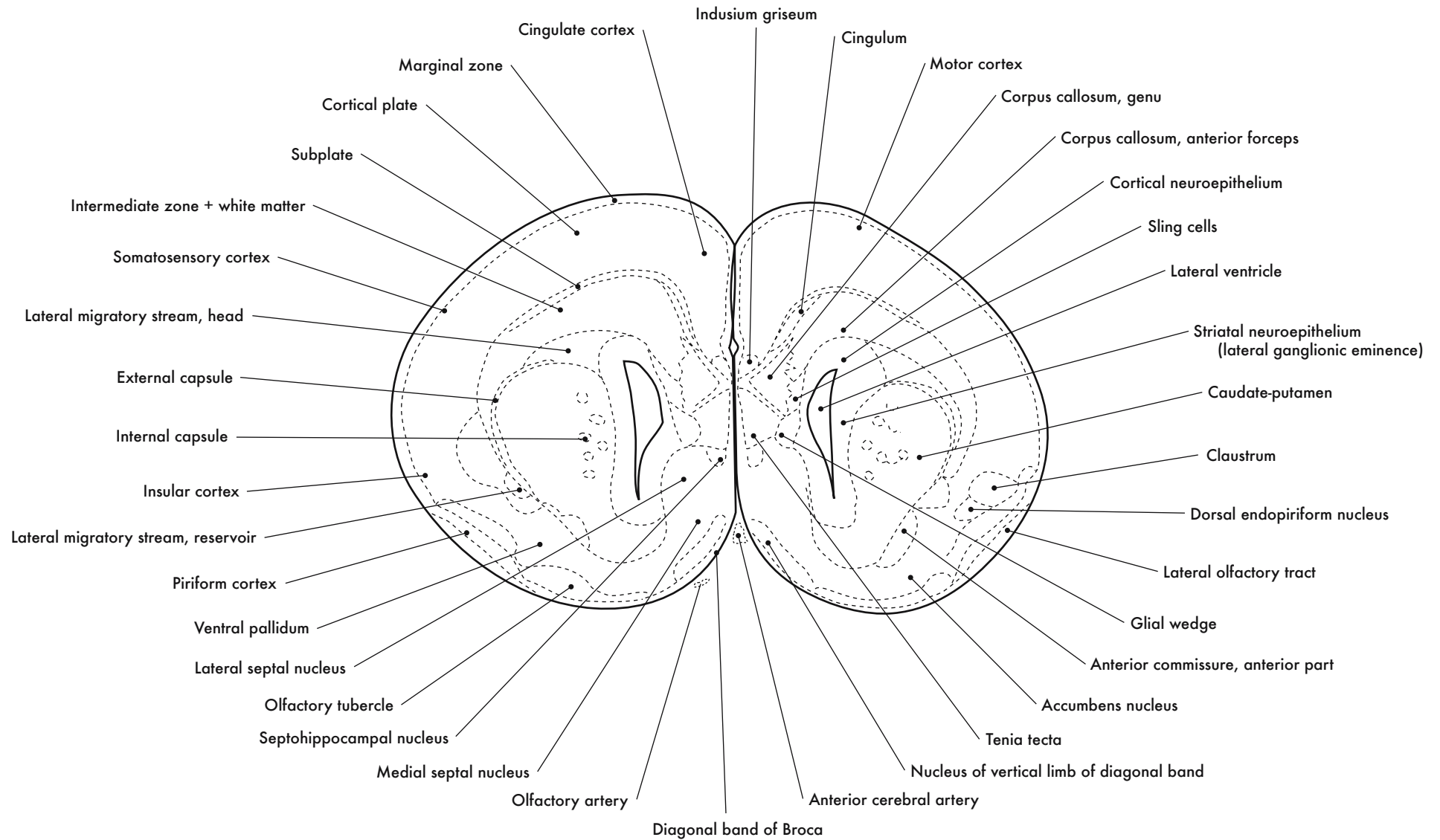
457

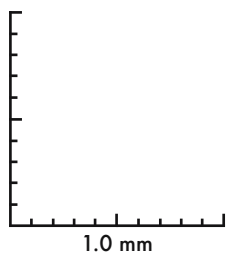
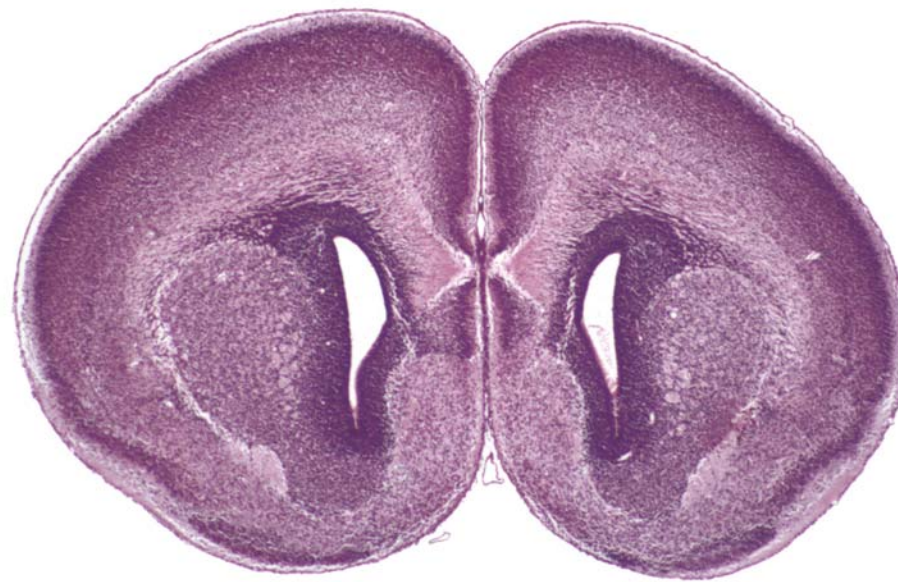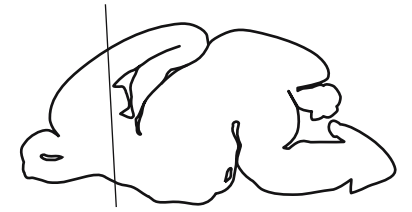


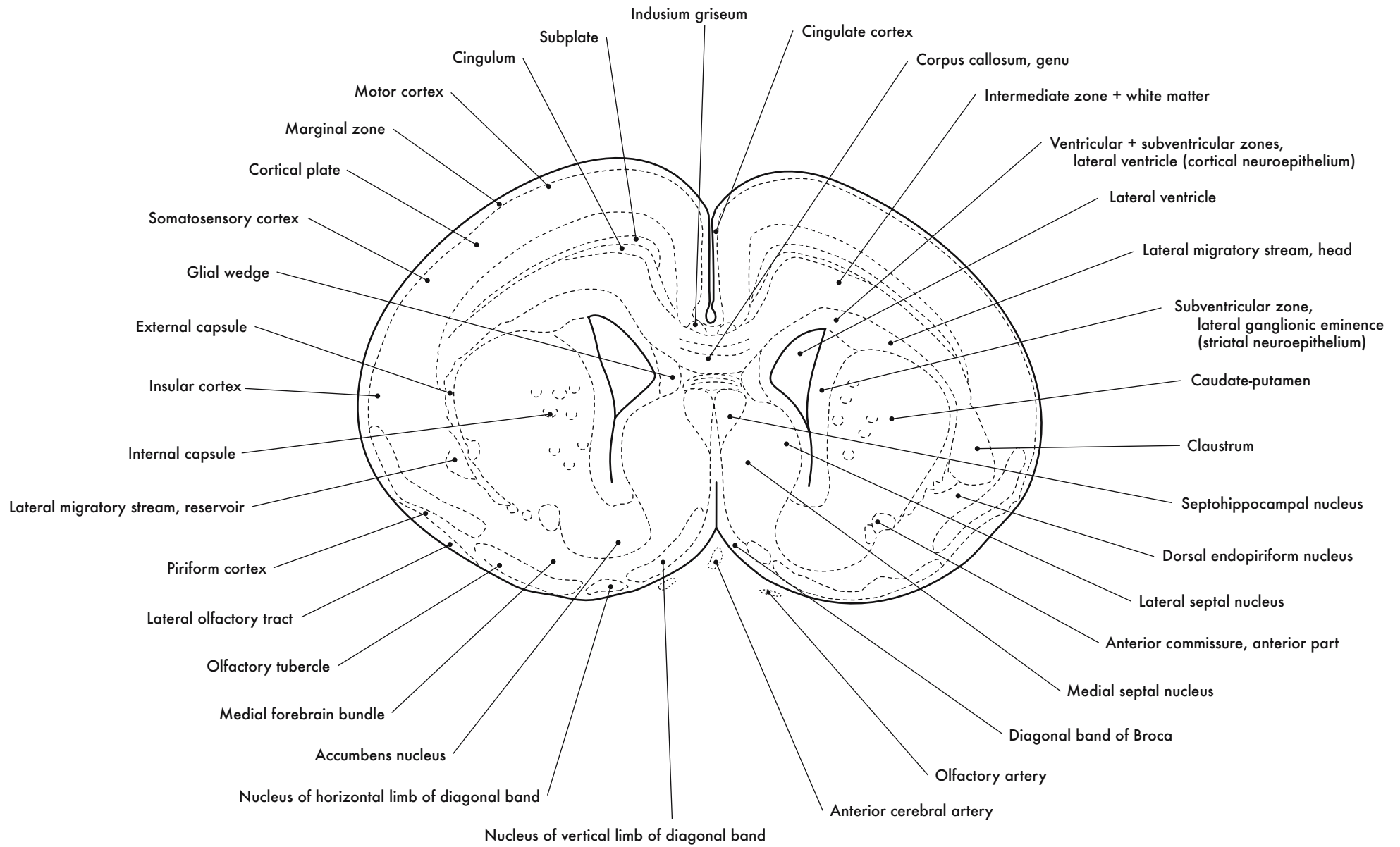


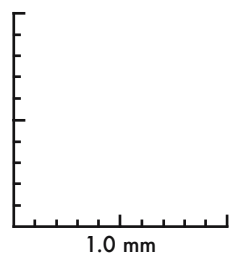
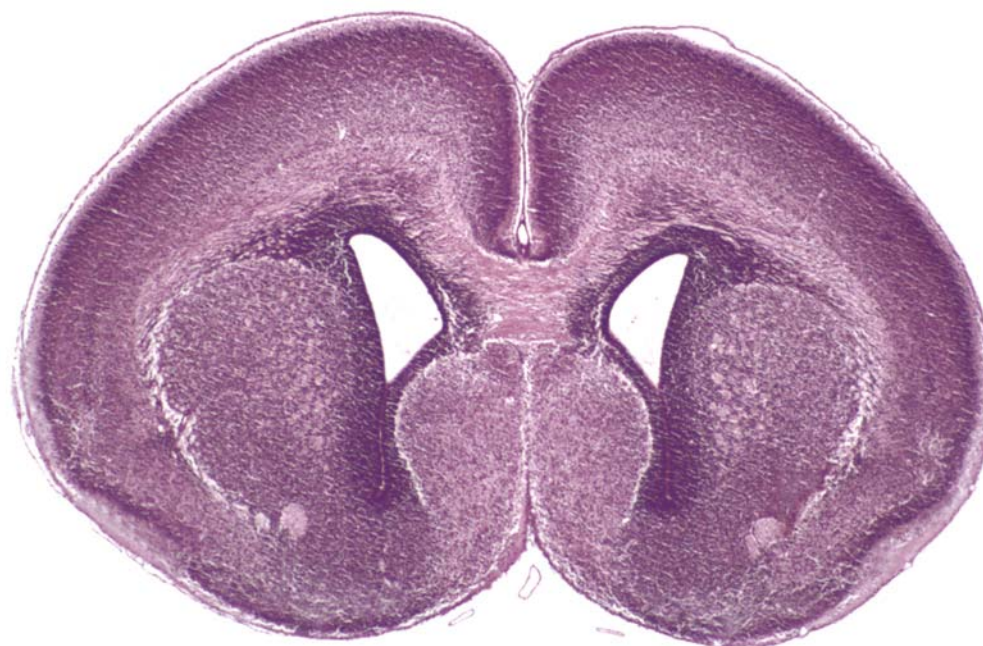

GD 18 CORONAL 6





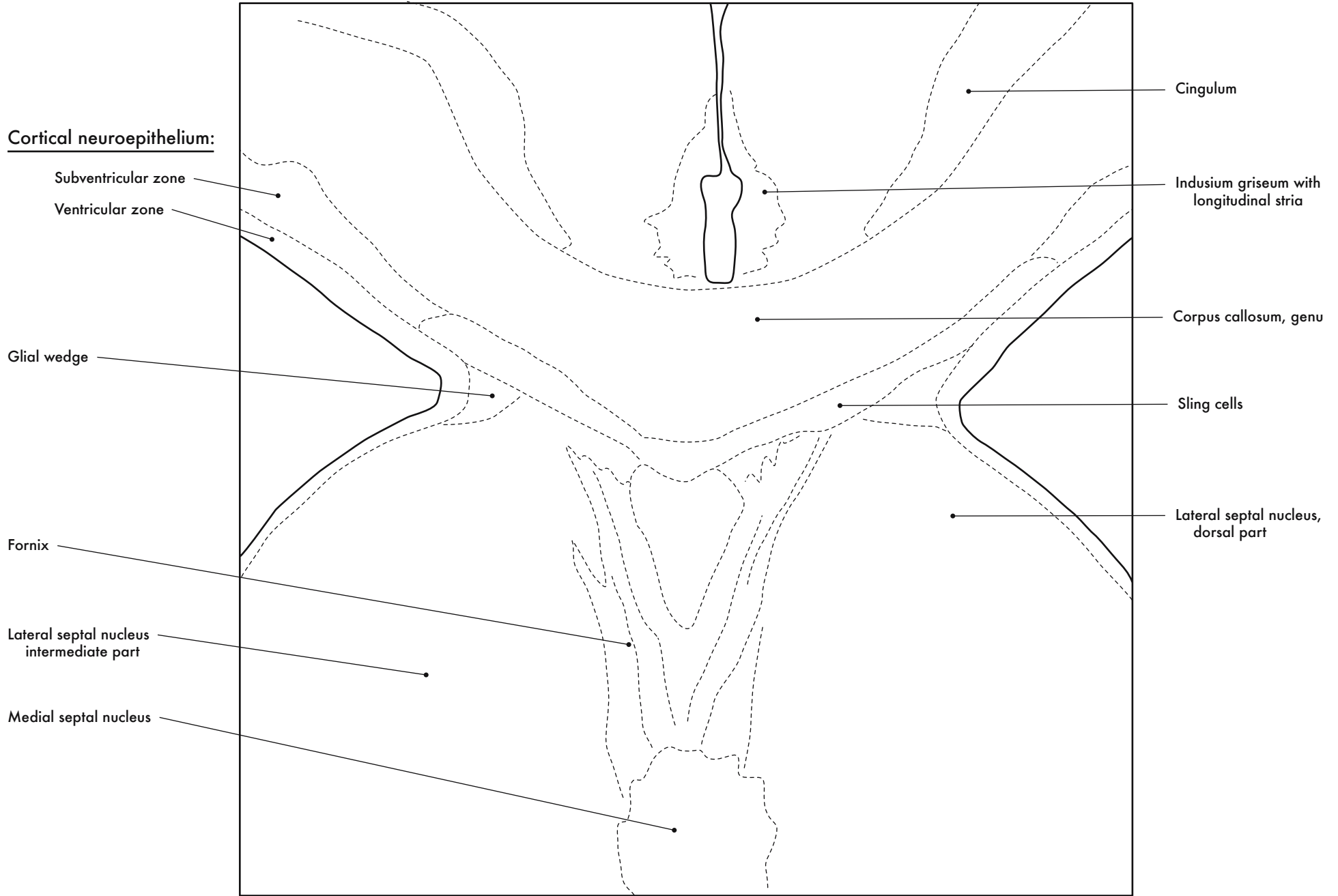




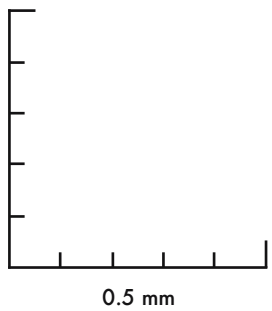
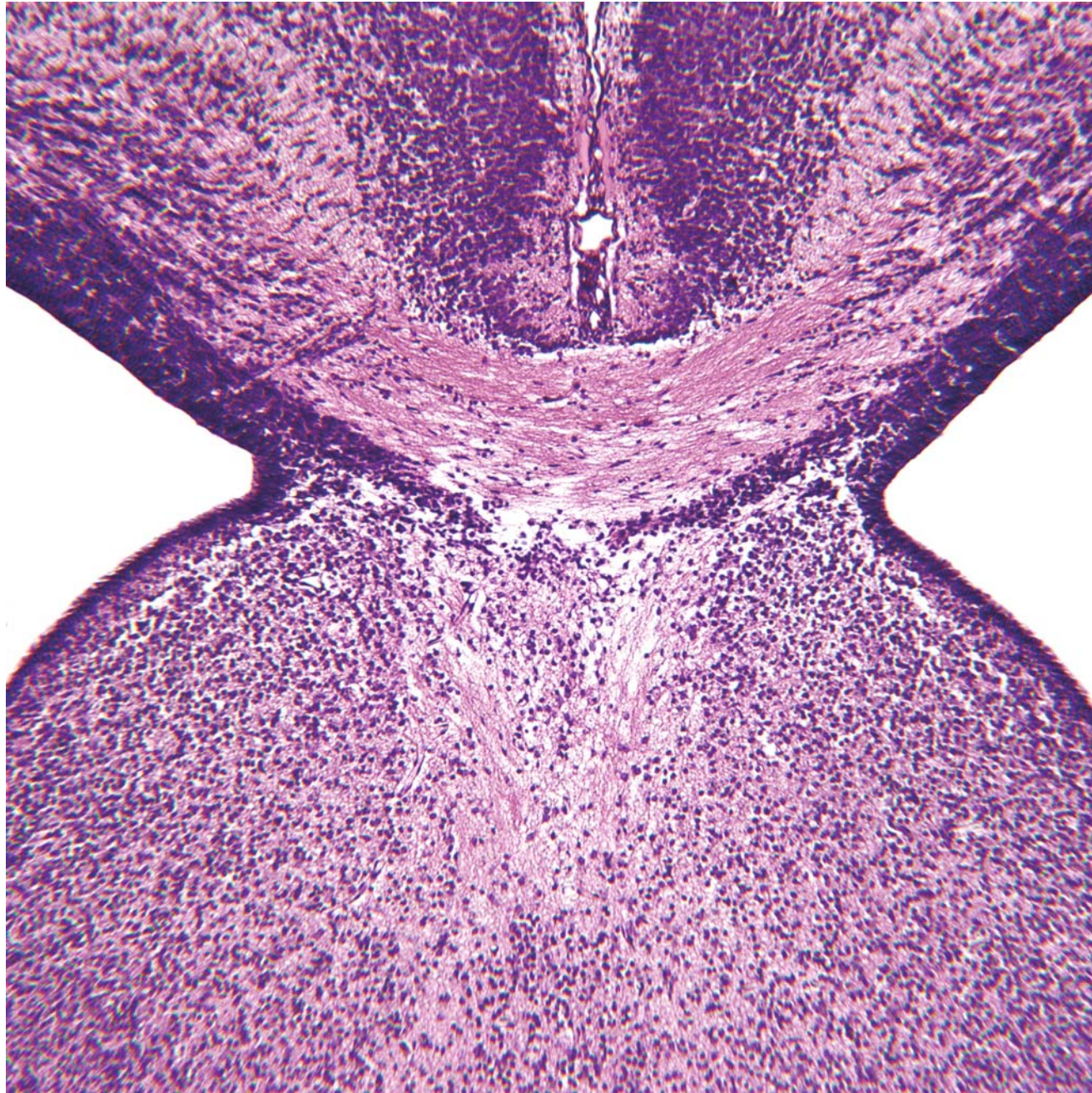

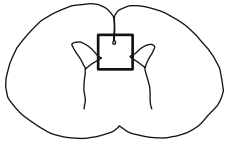


GD 18 CORONAL 8

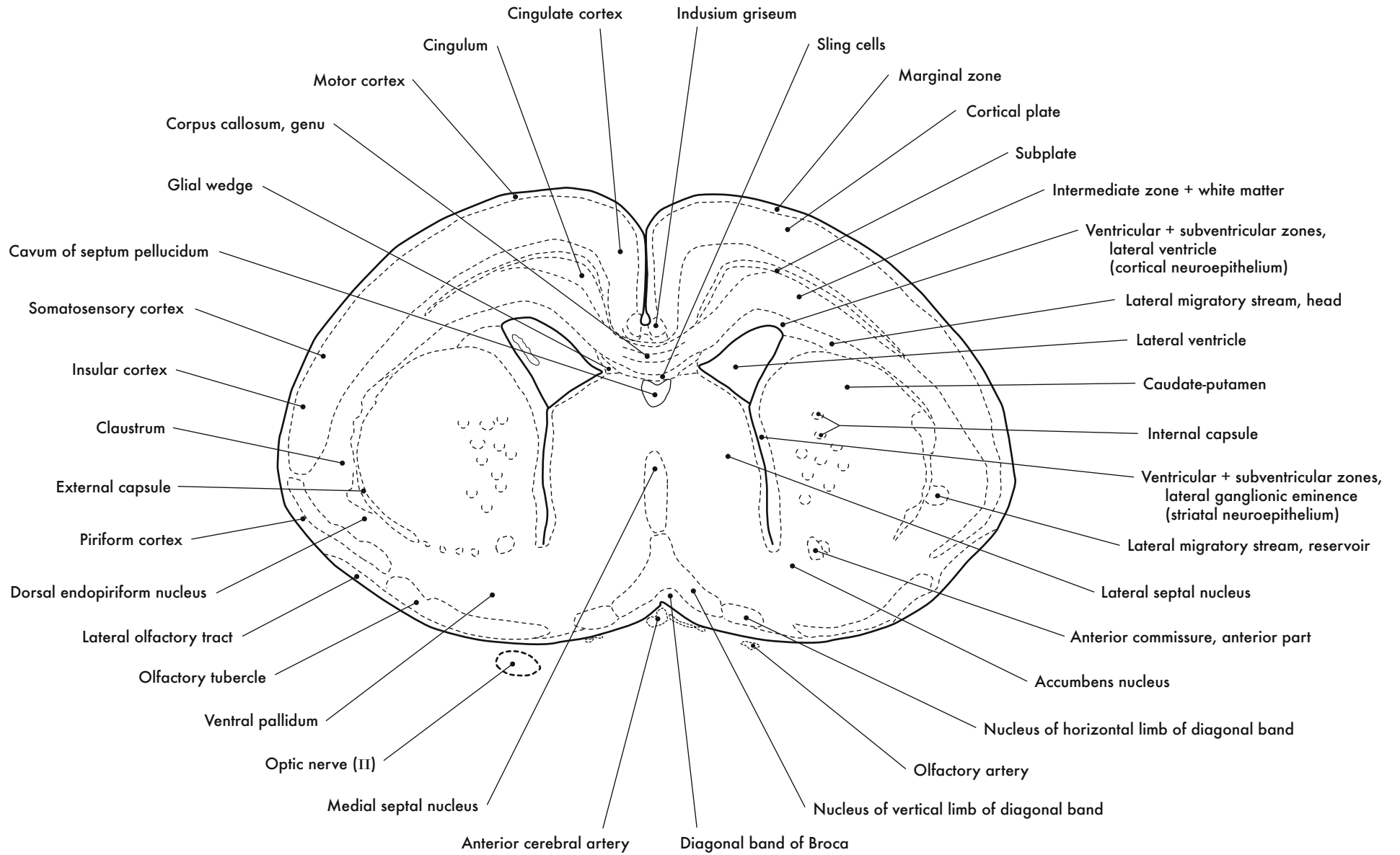




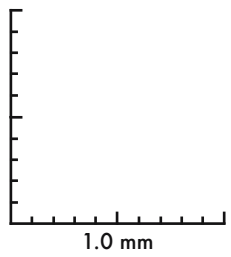
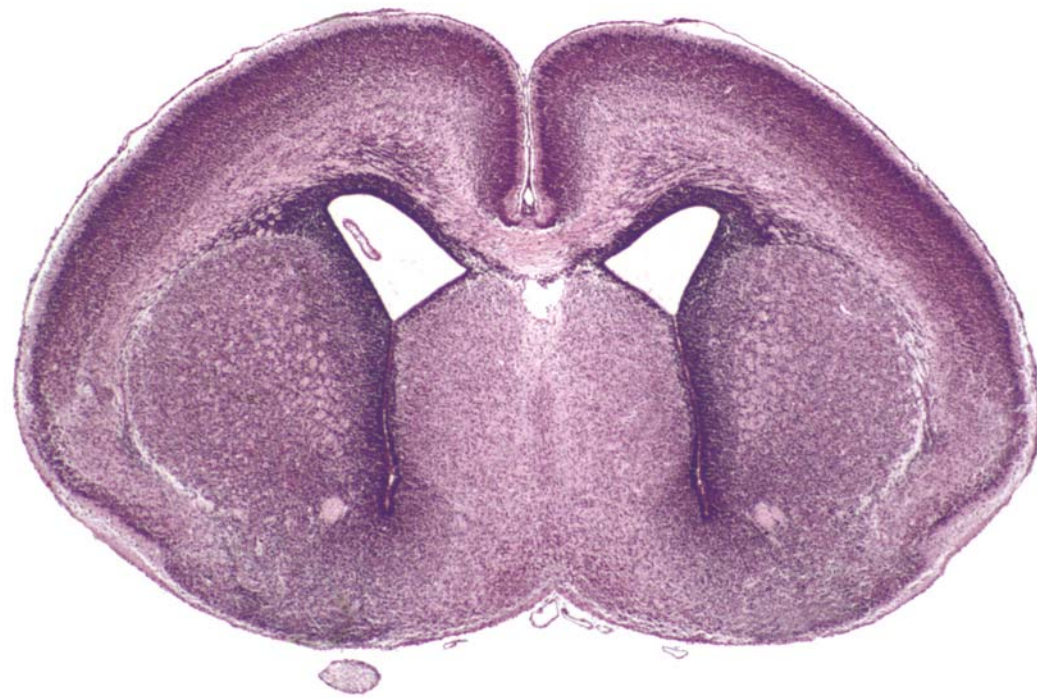

Corpus Callosum and Septal Area



GD 18 CORONAL 9

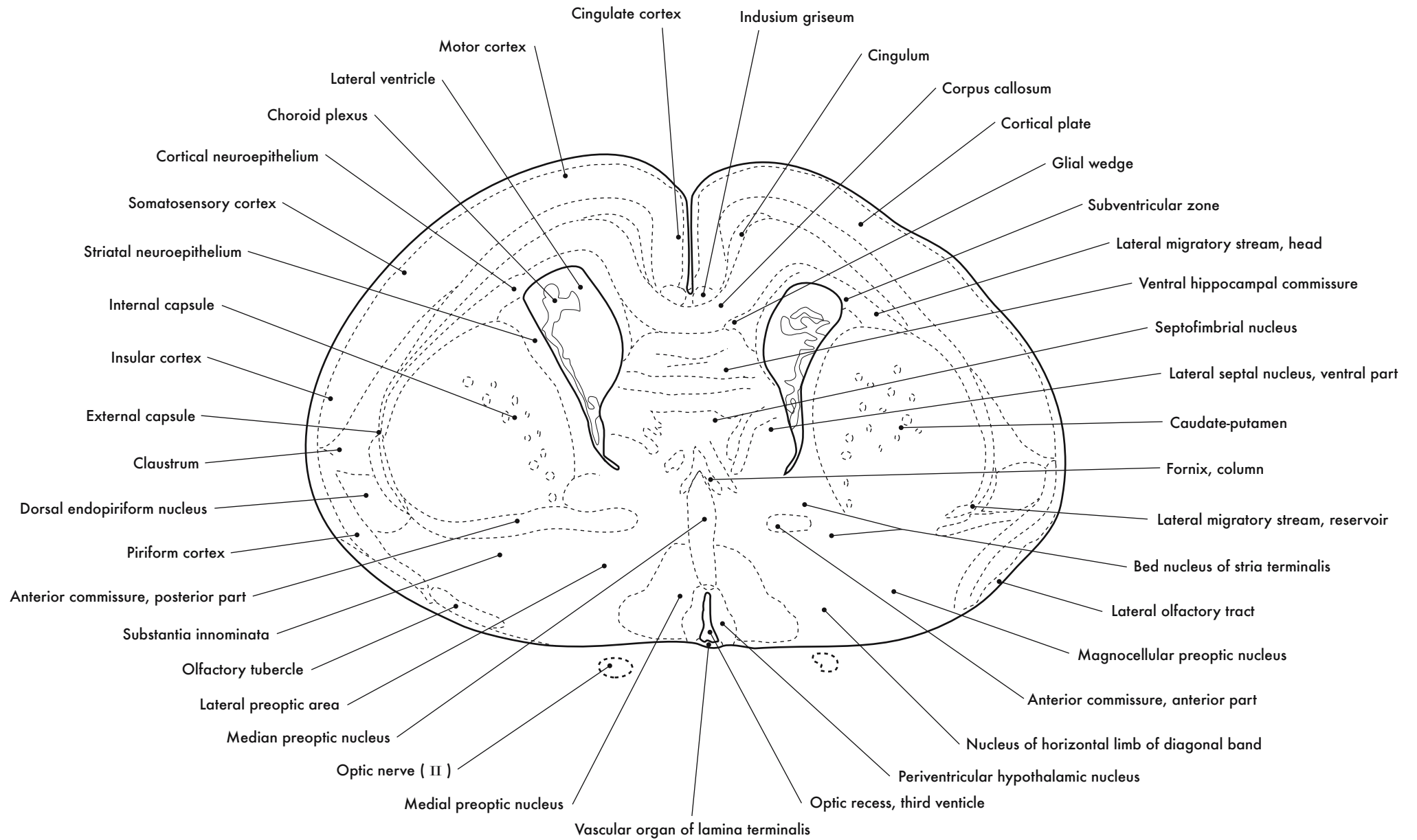


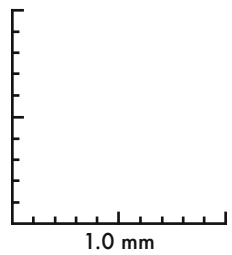
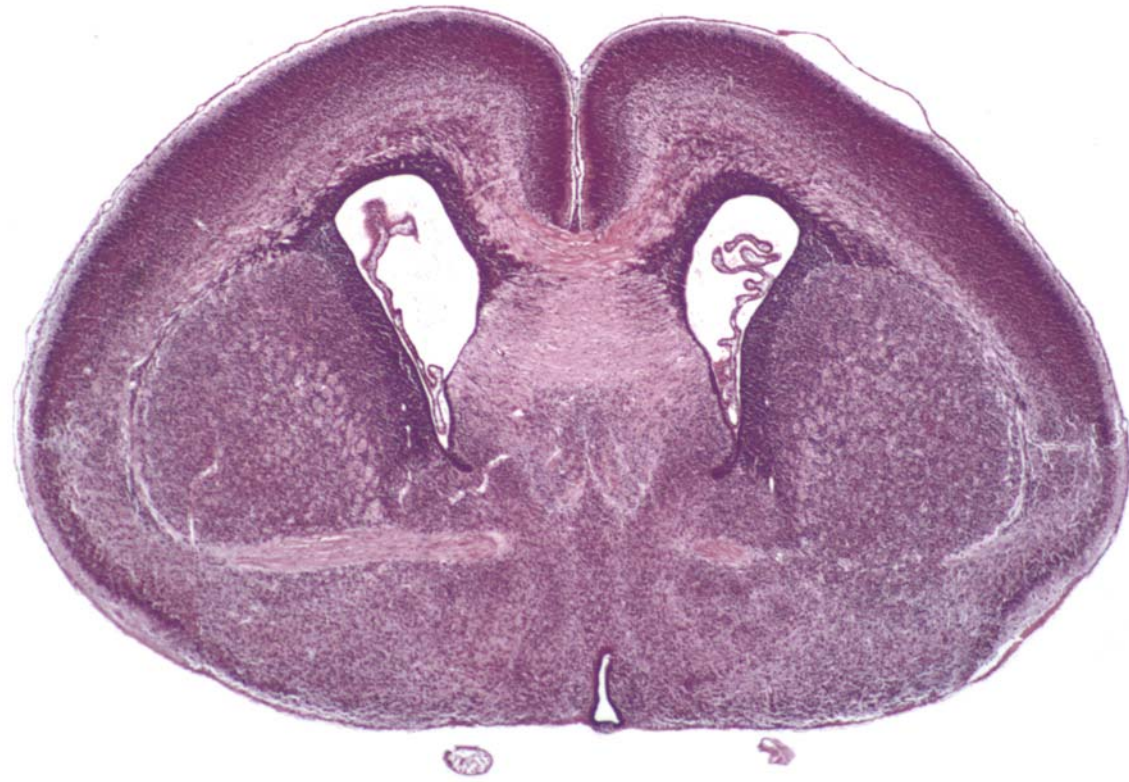




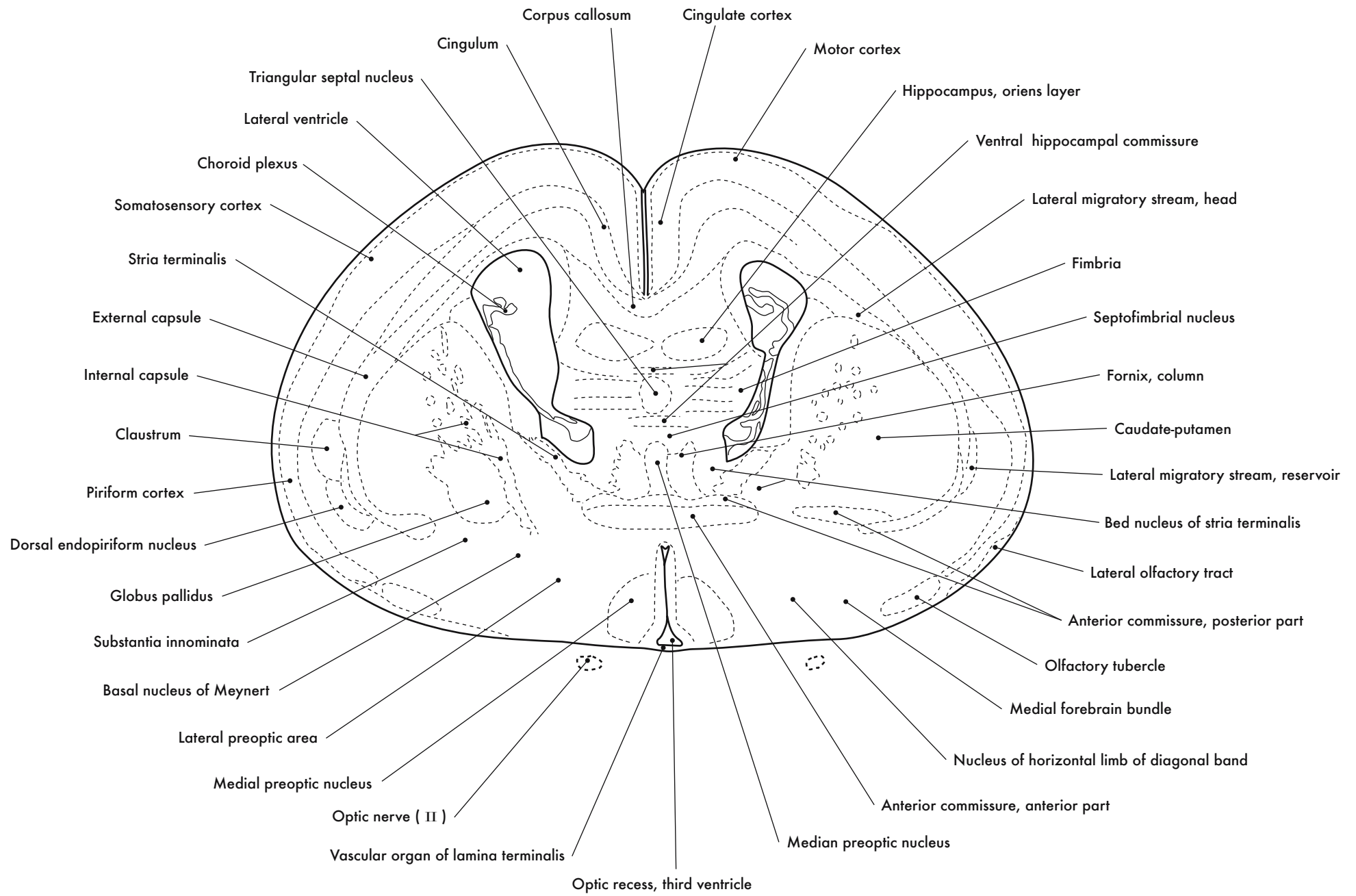
GD 18 CORONAL 10

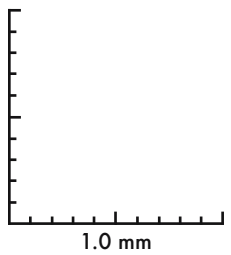
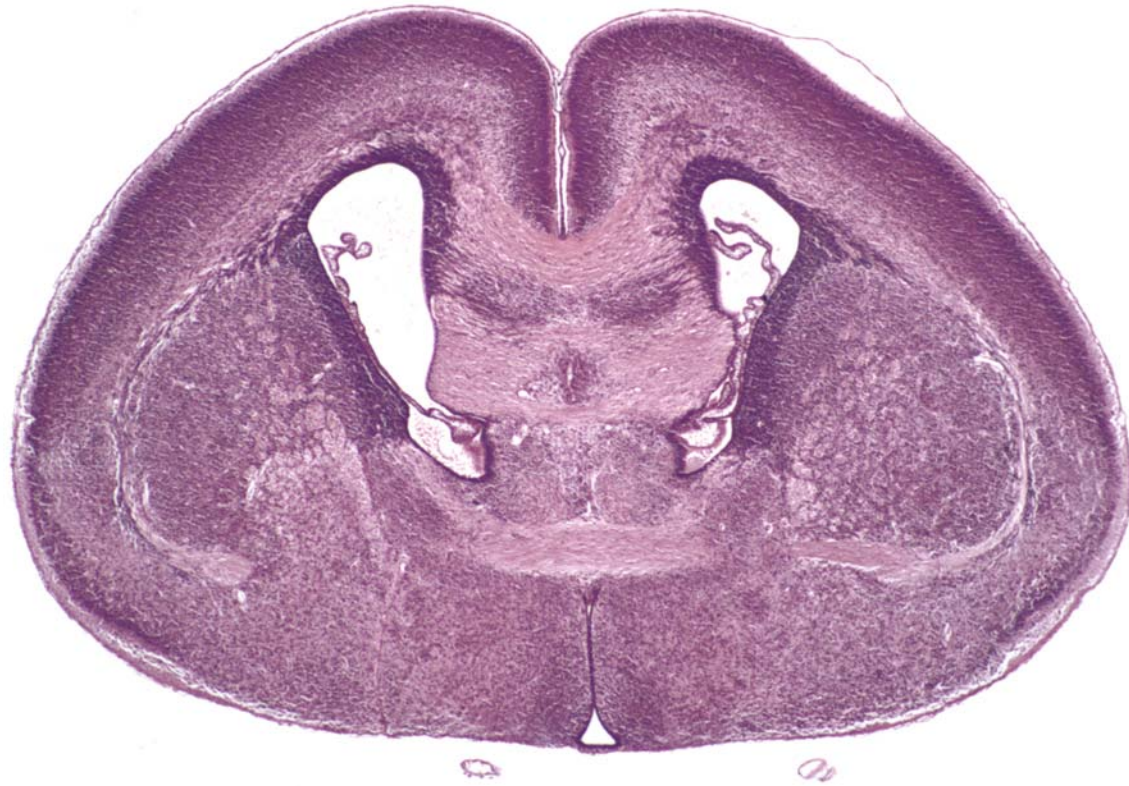






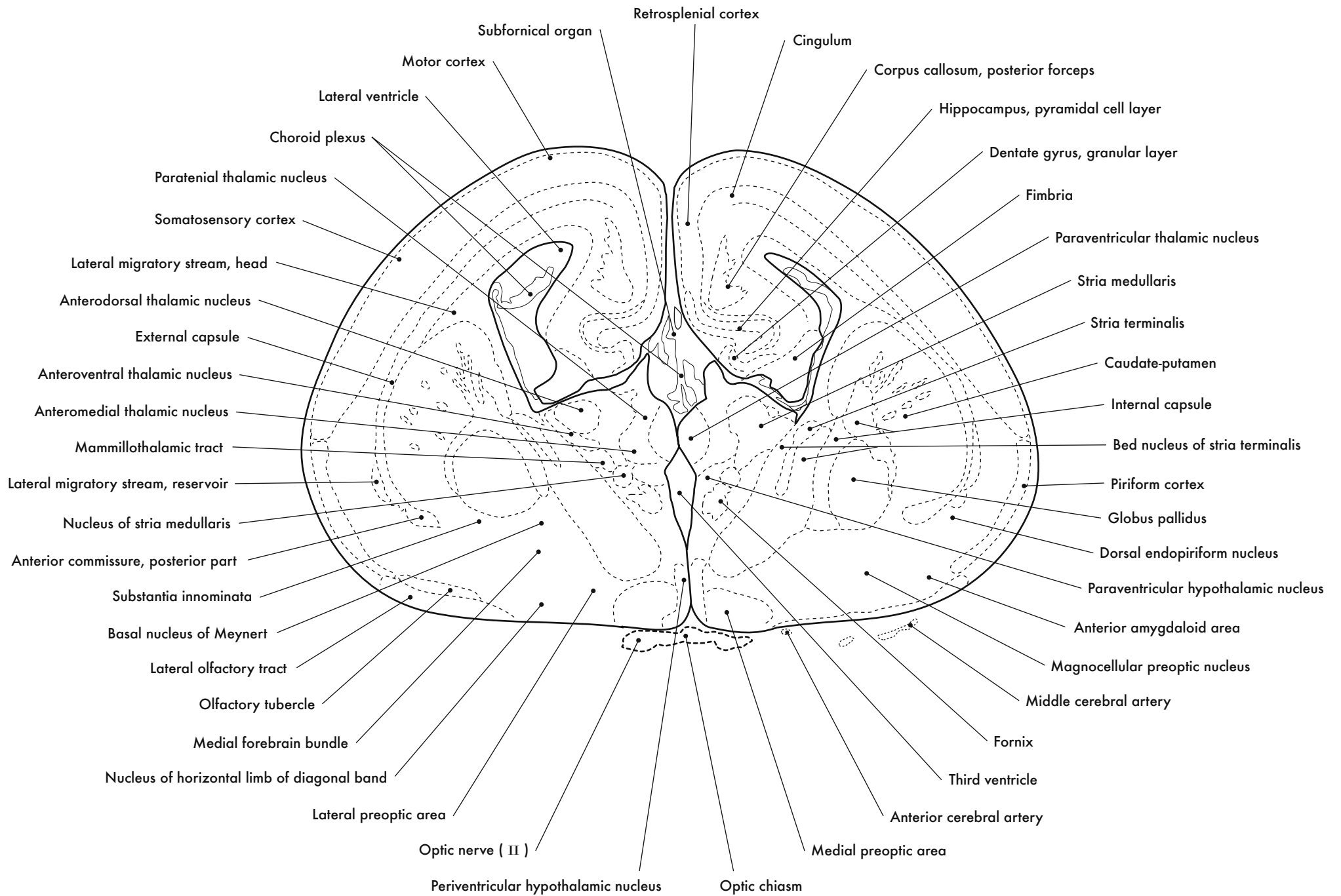
GD 18 CORONAL 11

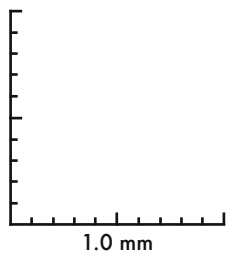
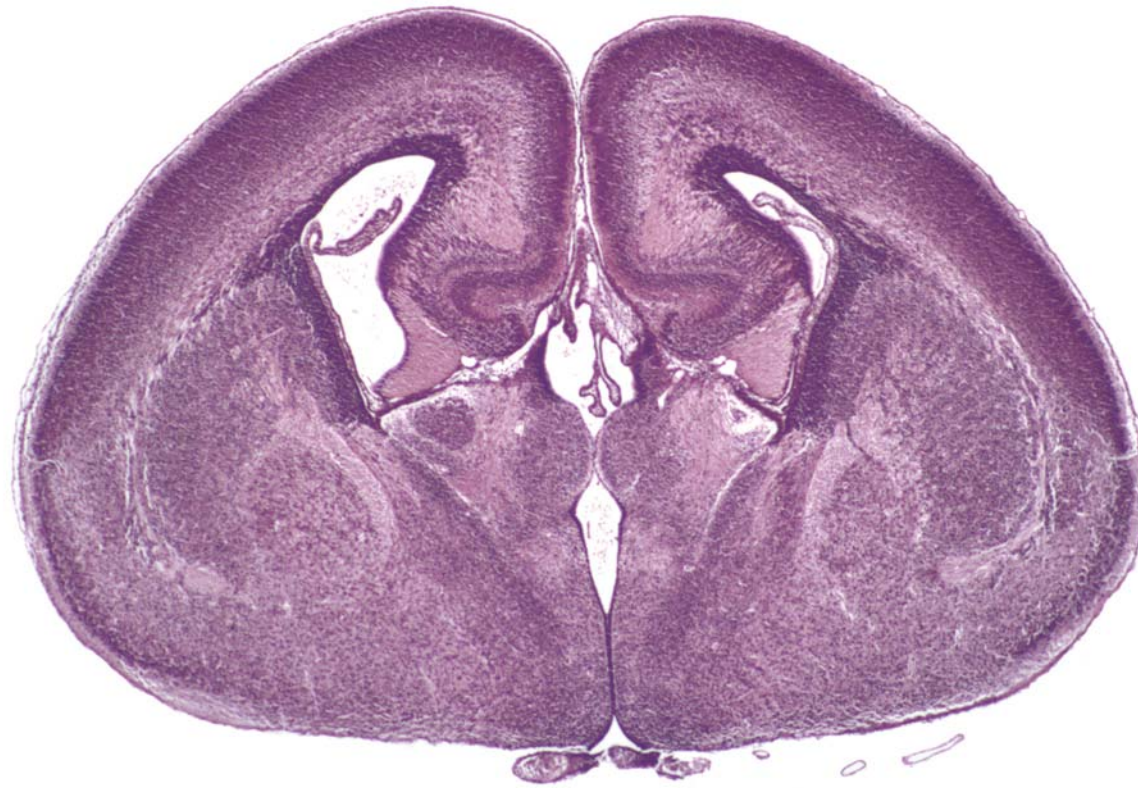




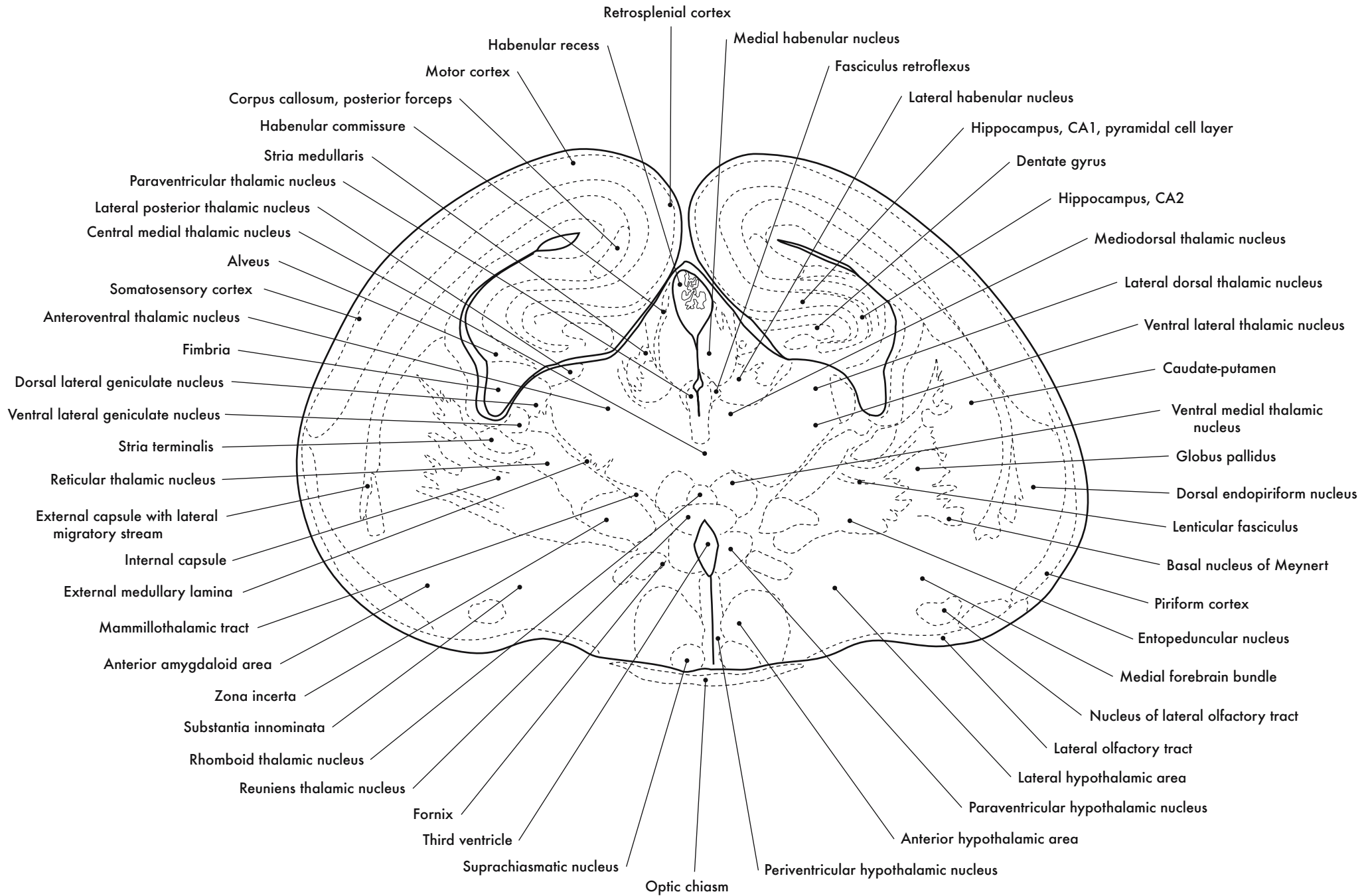
GD 18 CORONAL 12

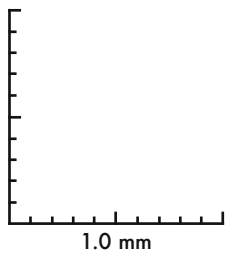
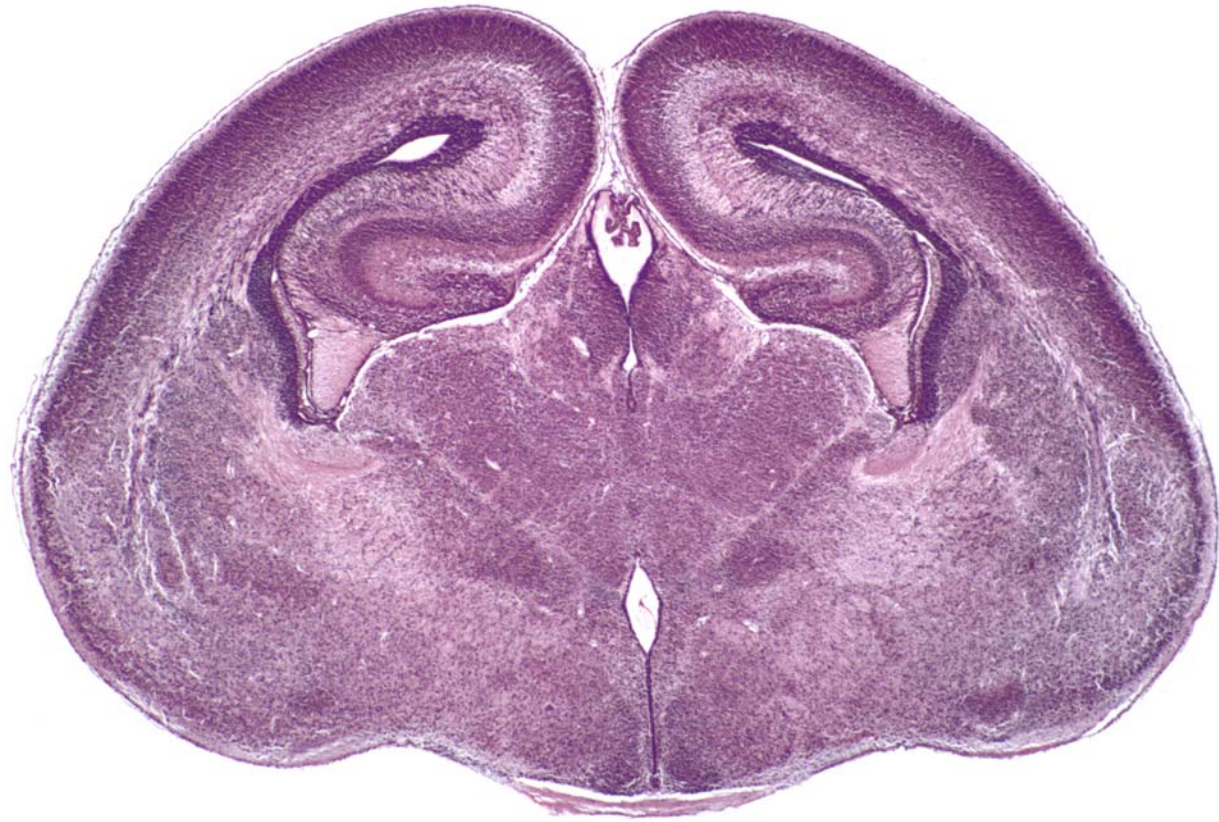







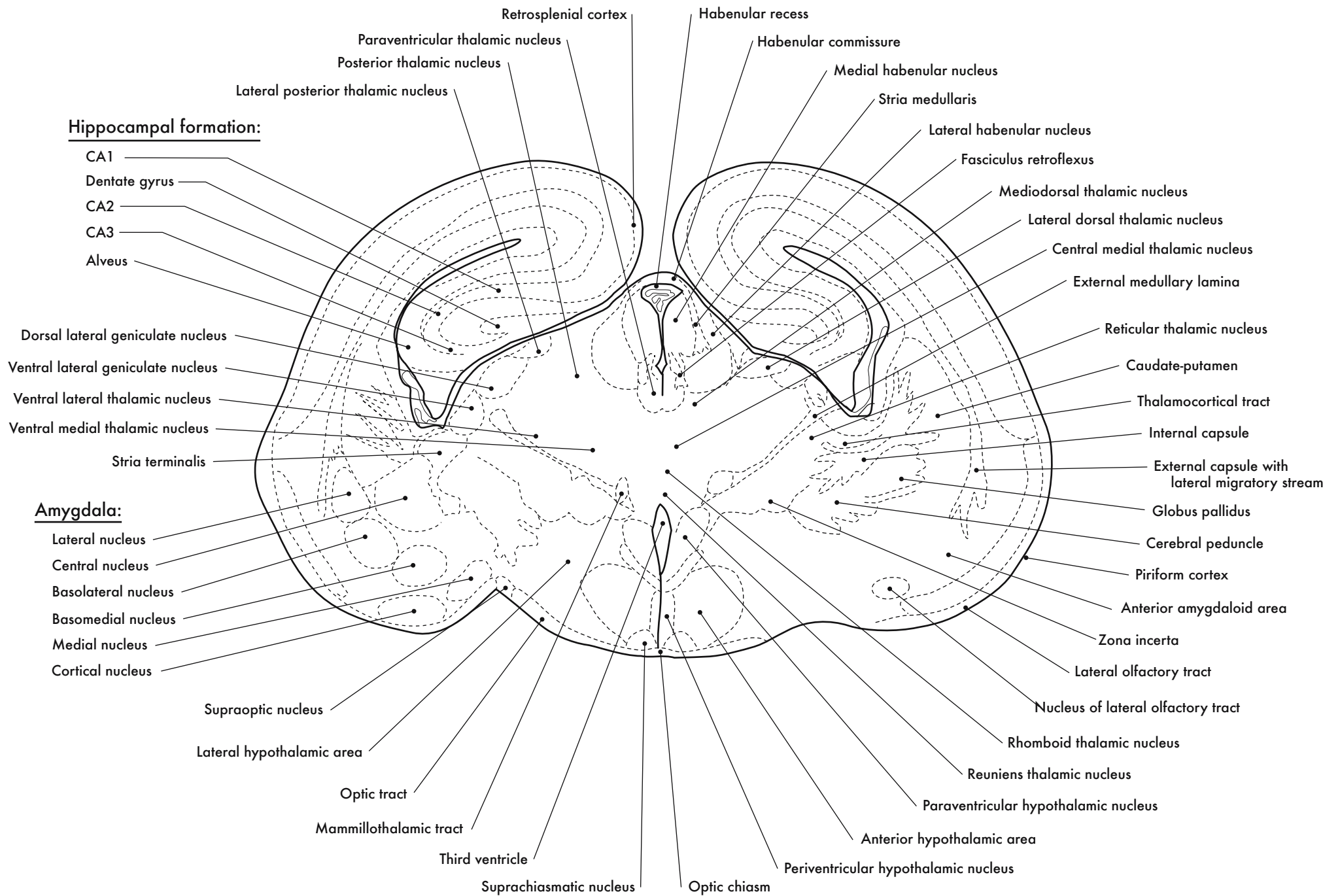
GD 18 CORONAL 13

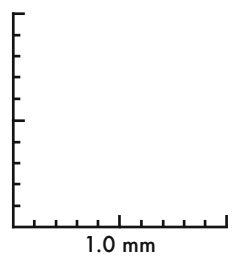
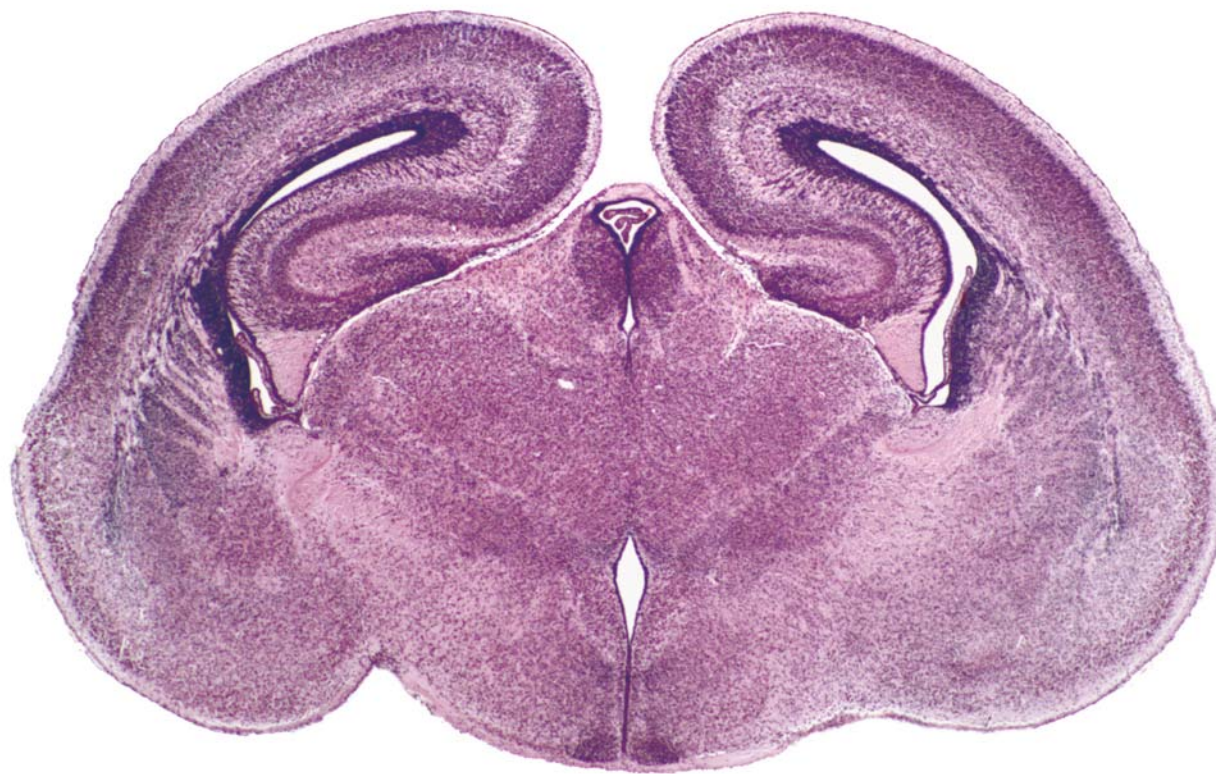





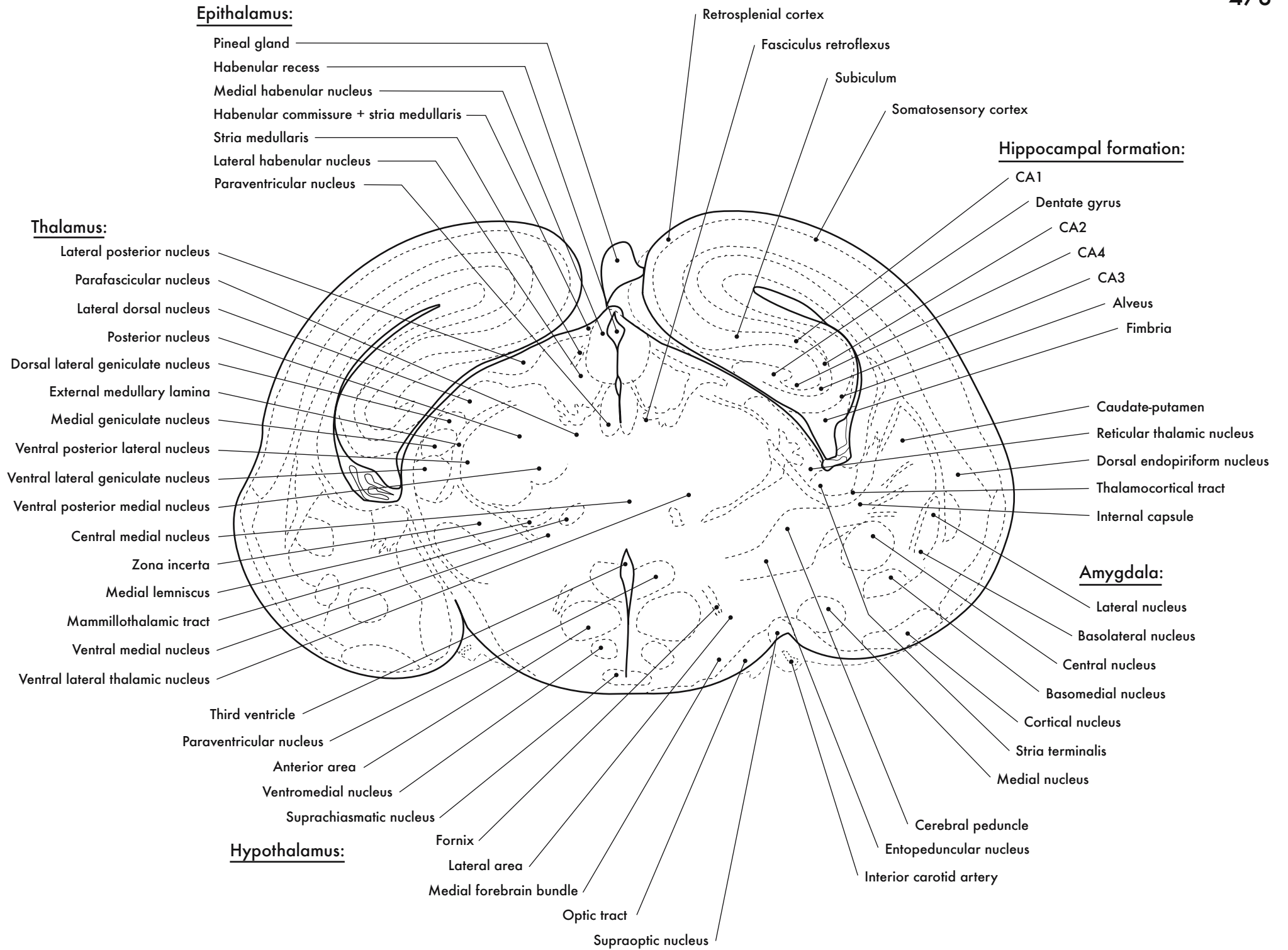
GD 18 CORONAL 14



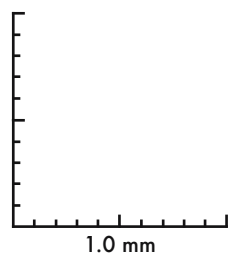
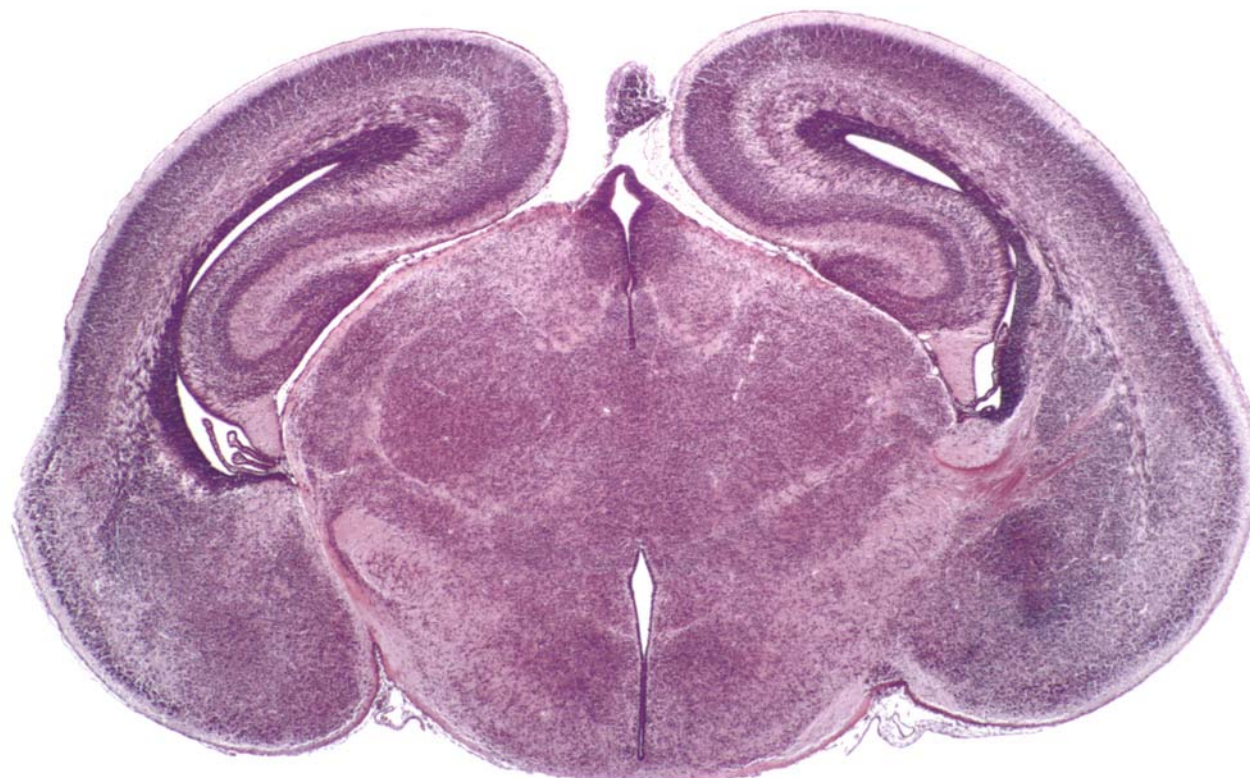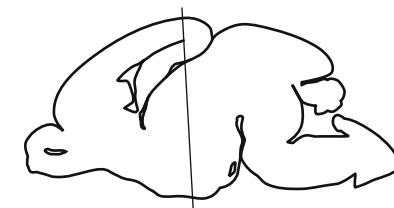




GD 18 CORONAL 15

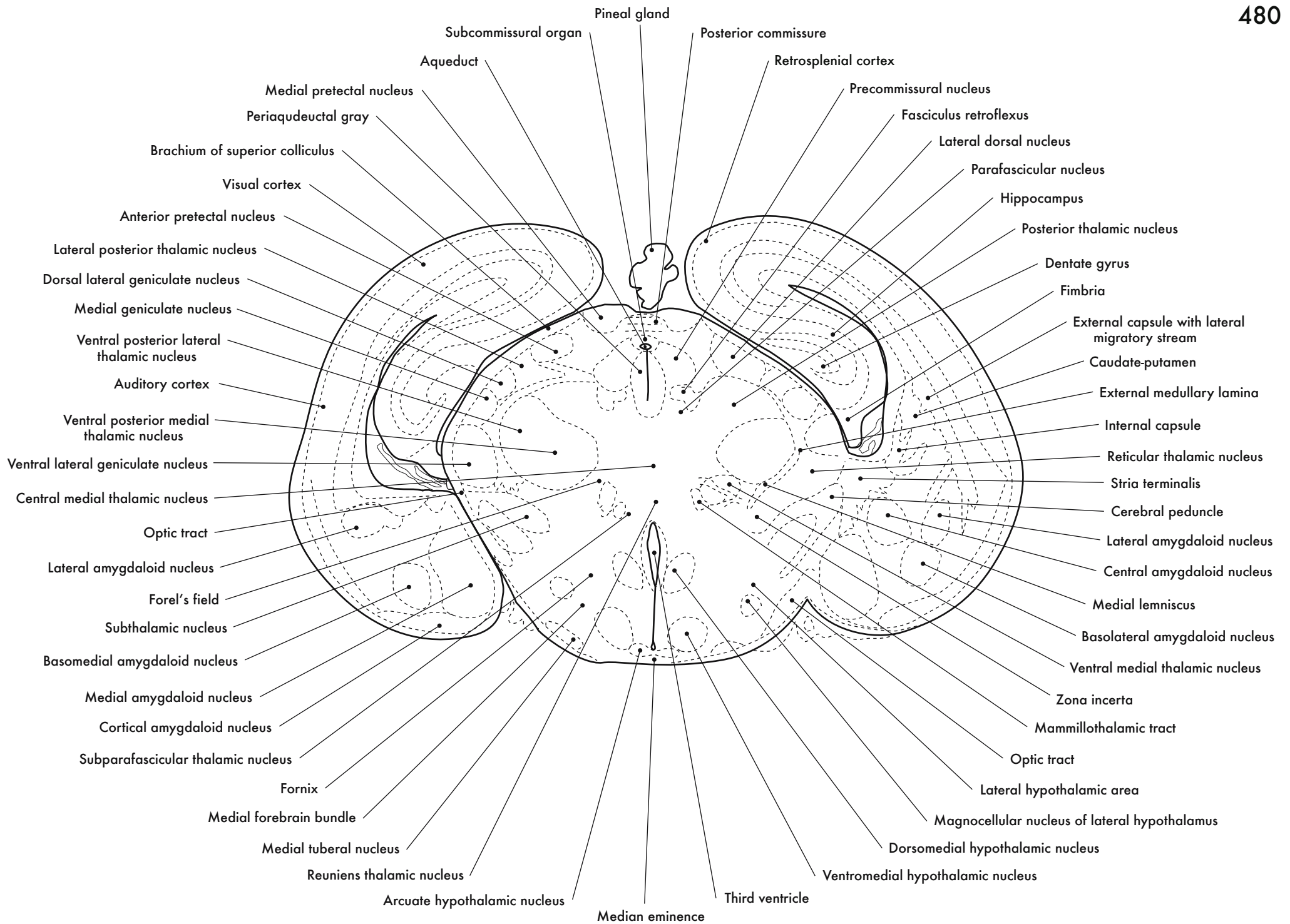


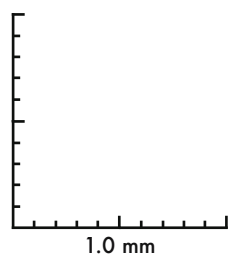
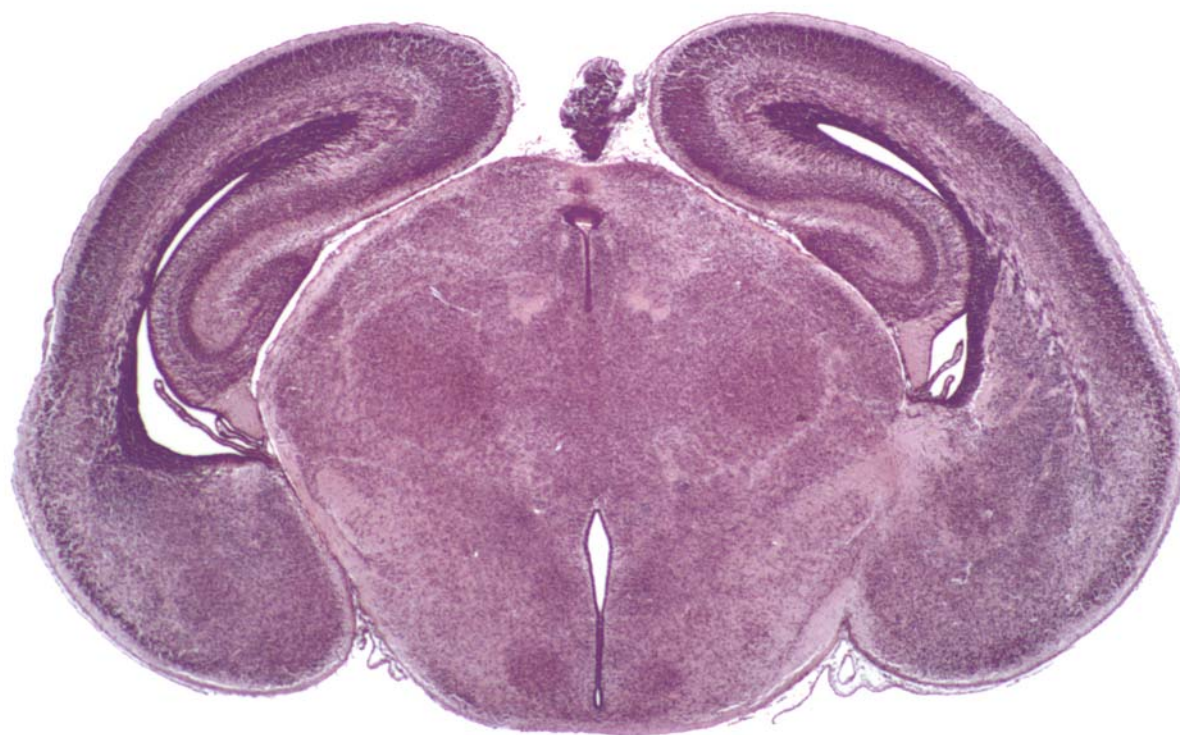
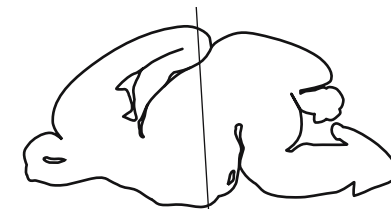




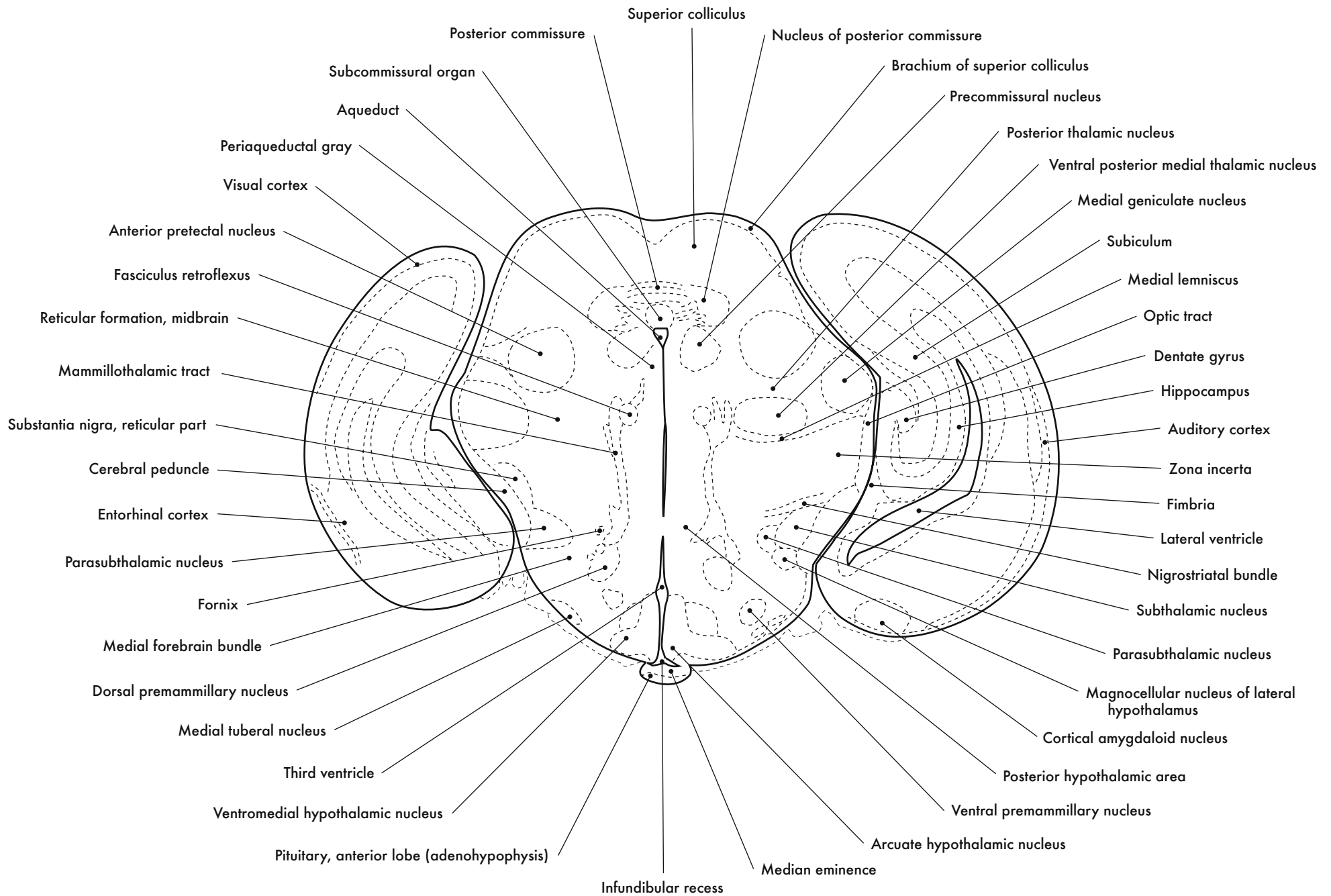
GD 18 CORONAL 16

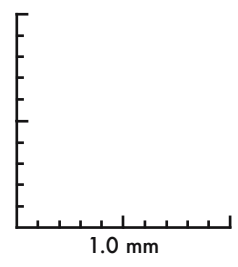
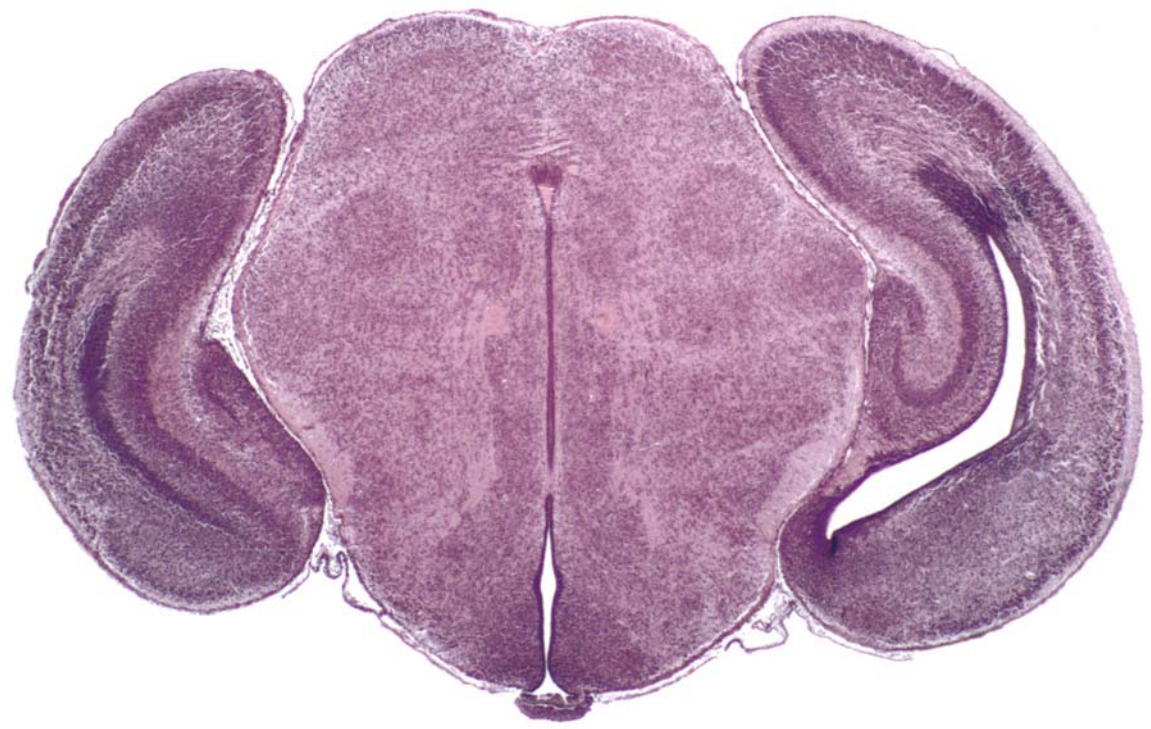
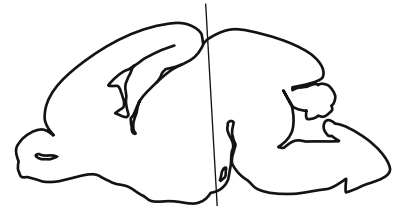






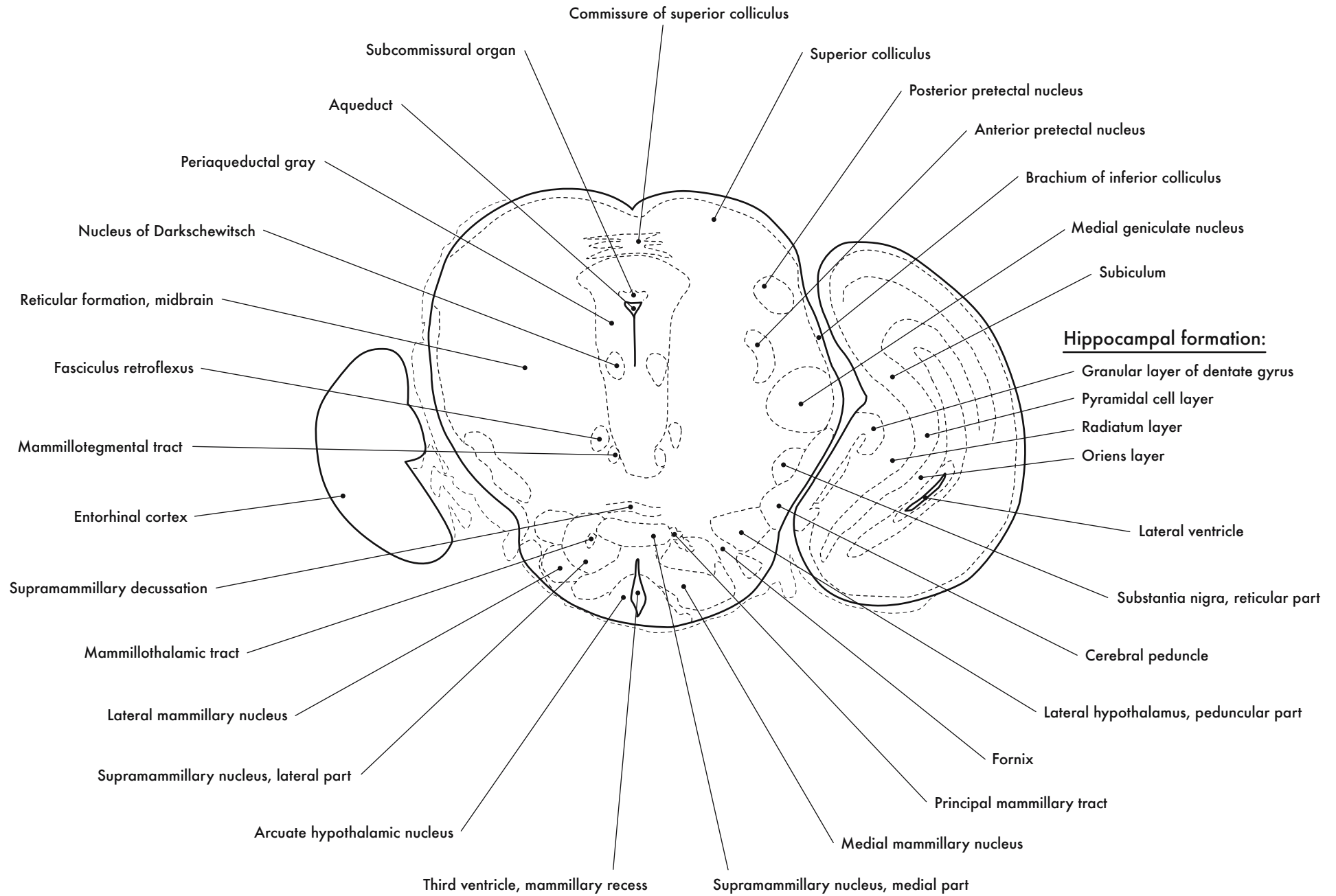
GD 18 CORONAL 17

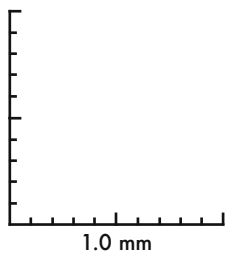
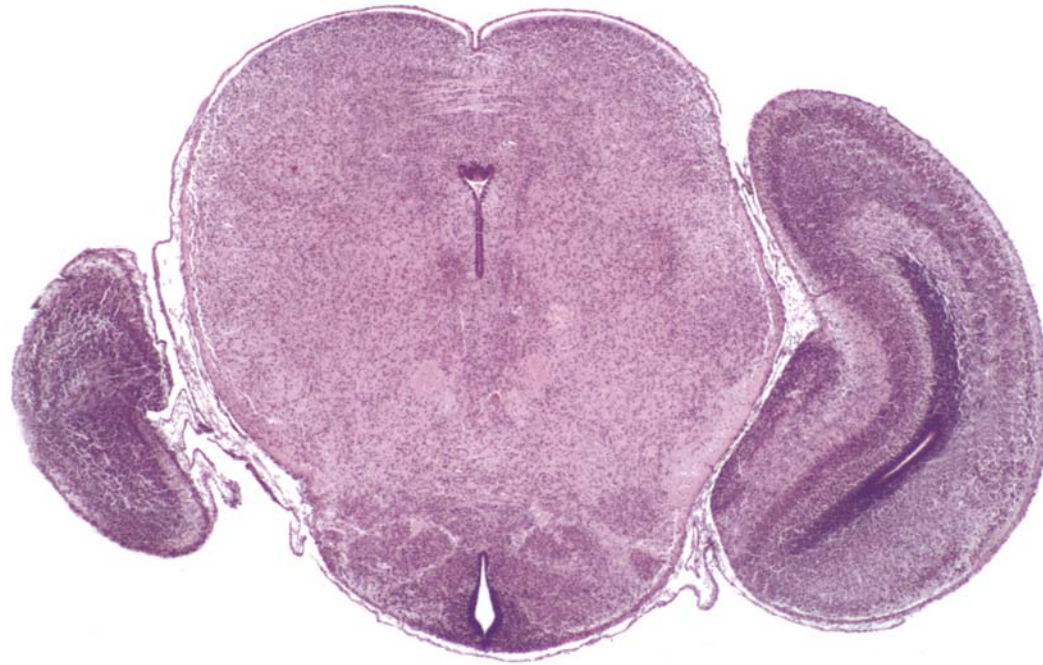
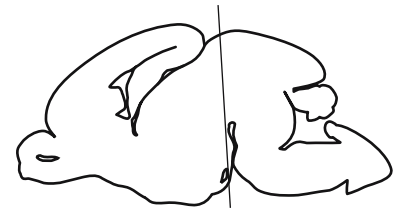




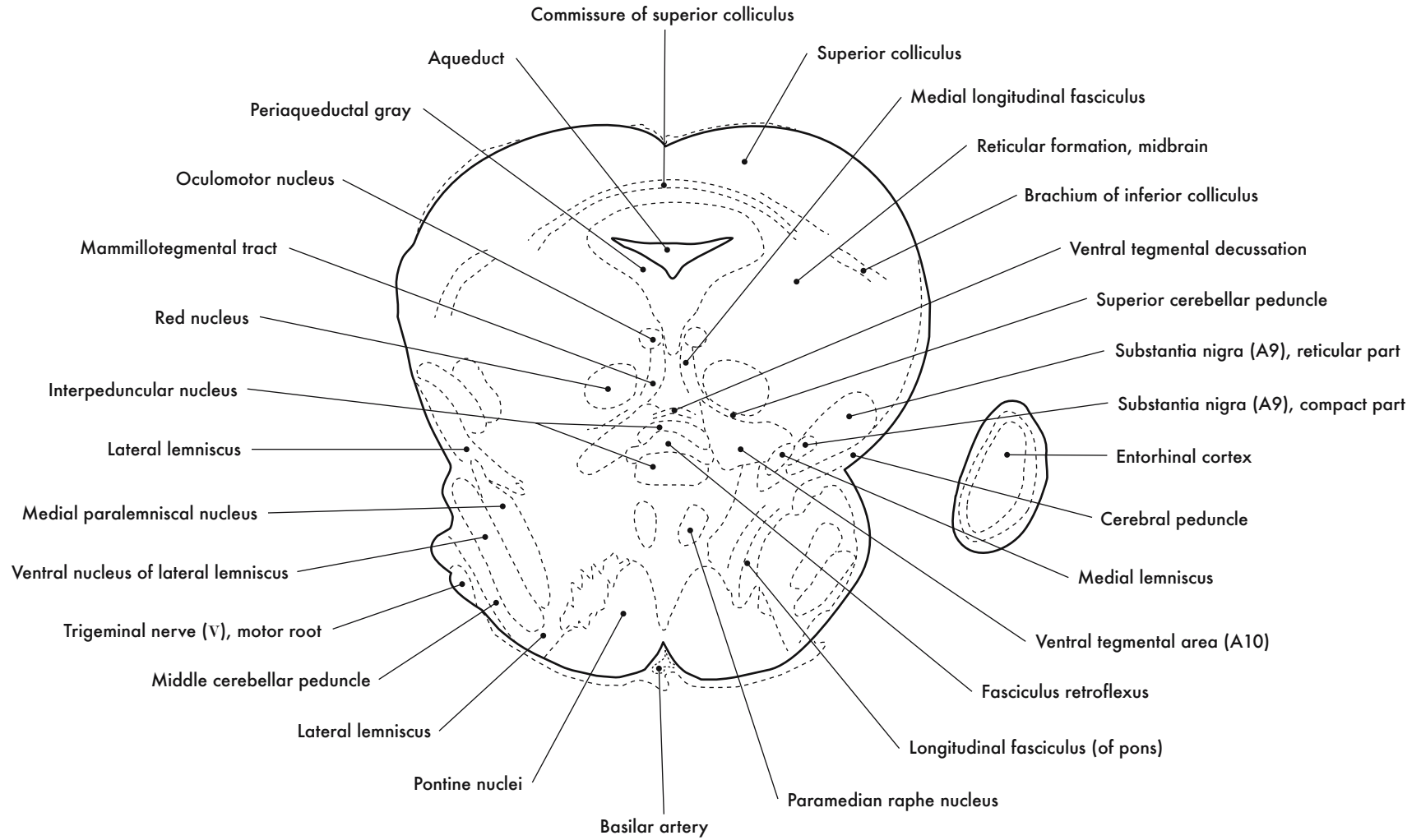
GD 18 CORONAL 18

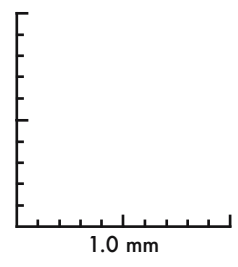
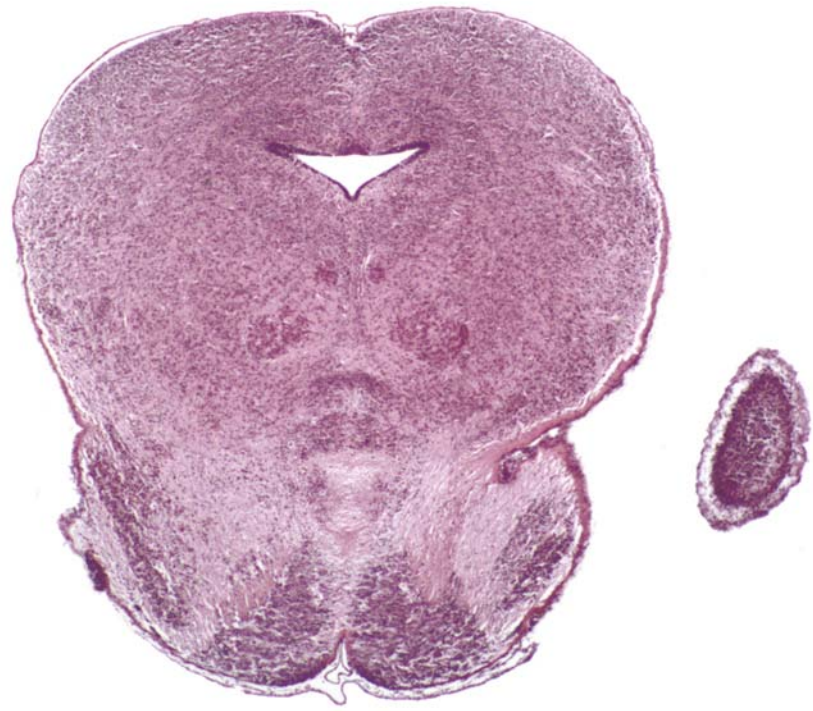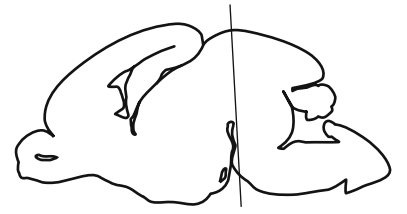






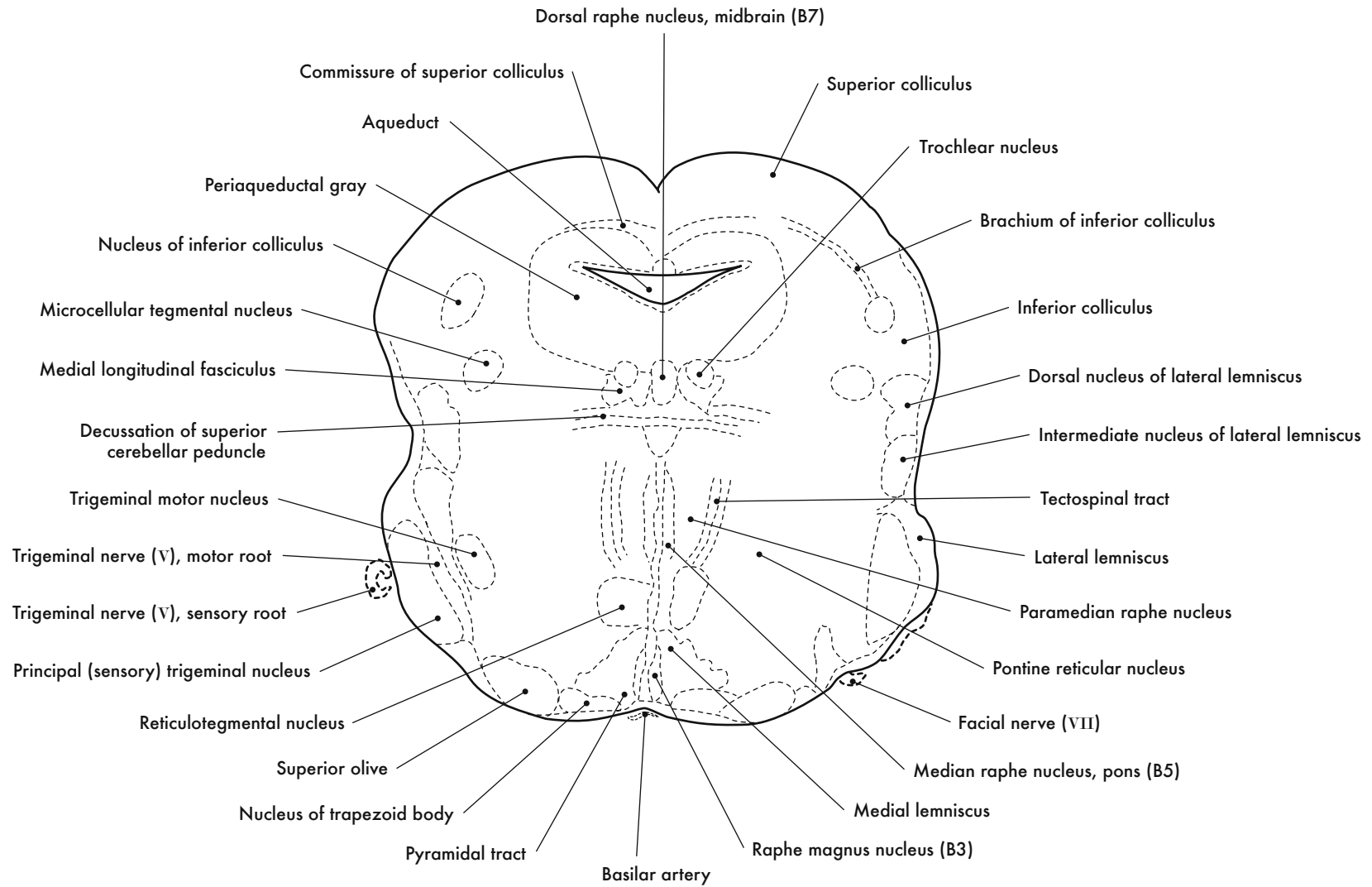
GD 18 CORONAL 19

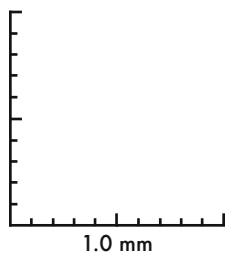
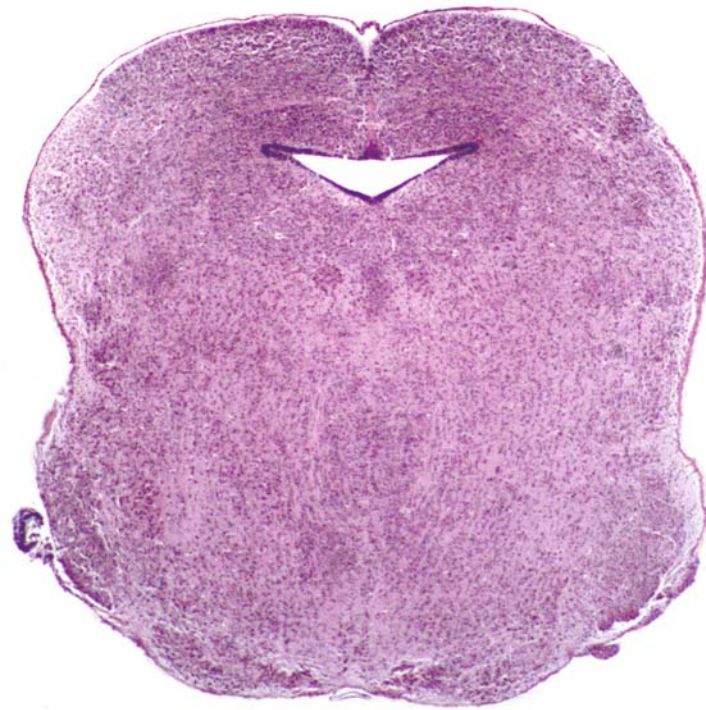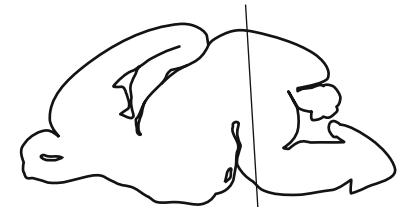




GD 18 CORONAL 20

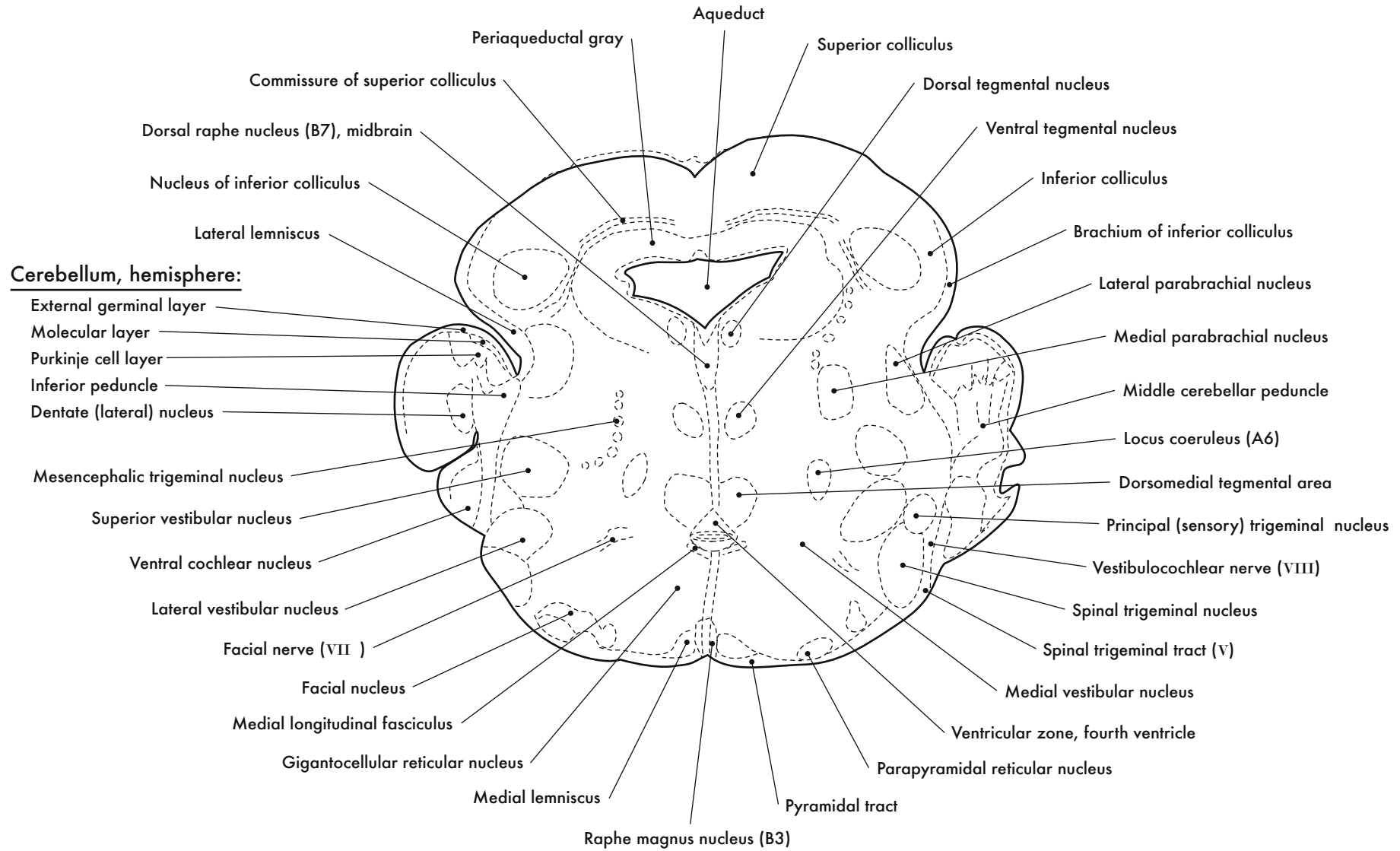


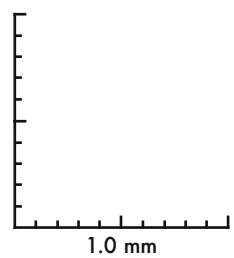
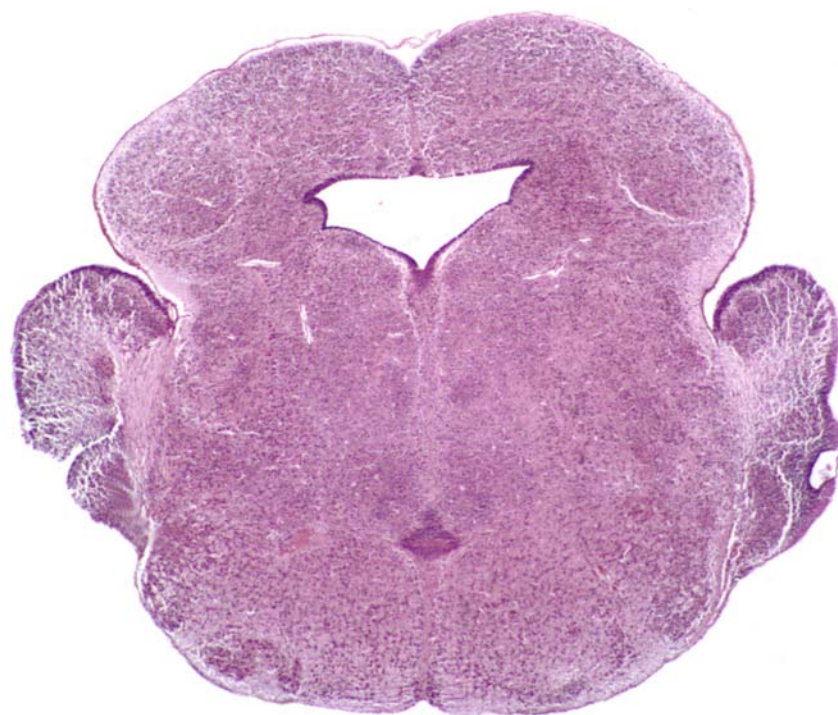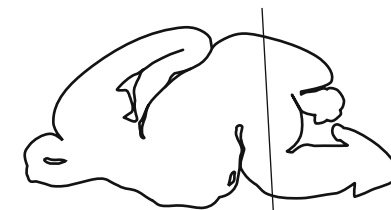




GD 18 CORONAL 21

489

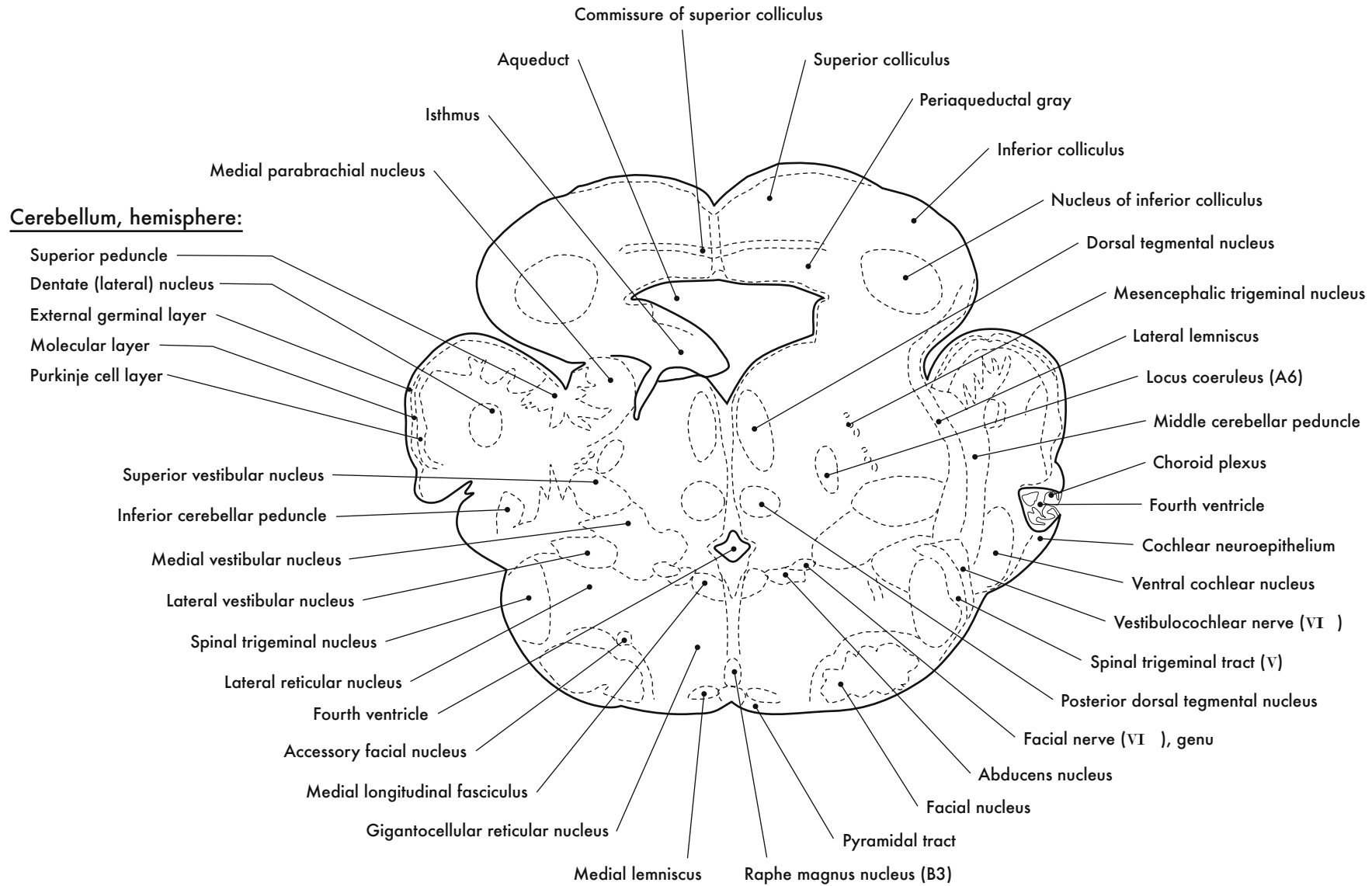


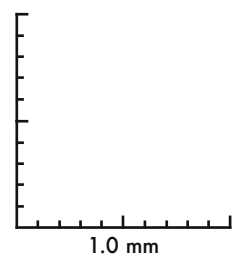
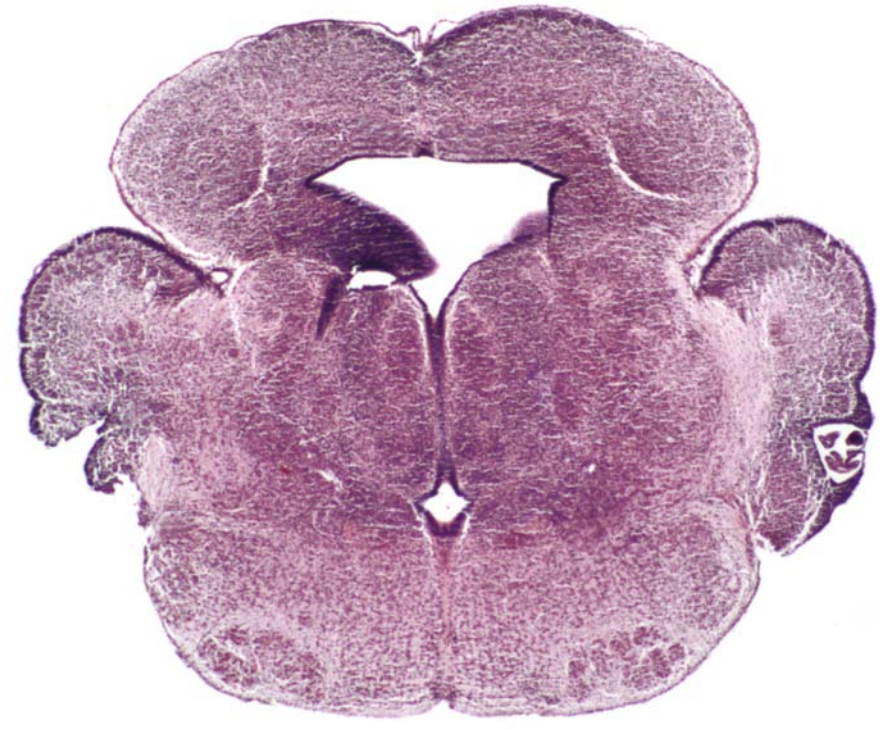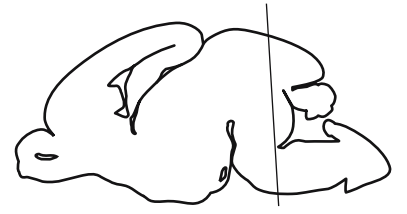


GD 18 CORONAL 22

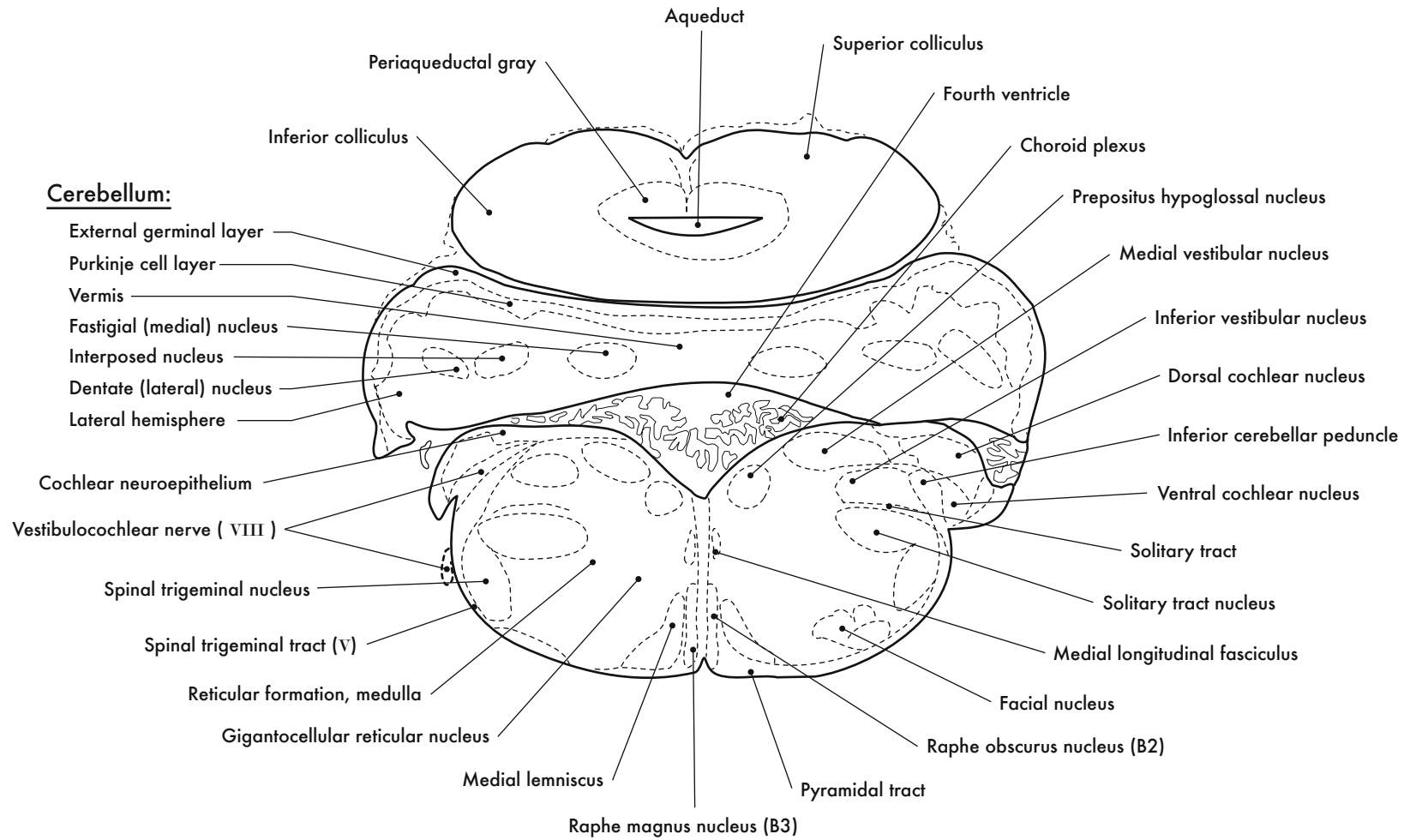
491

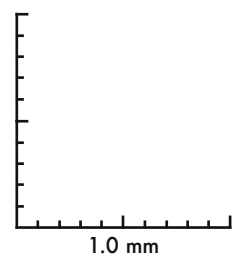
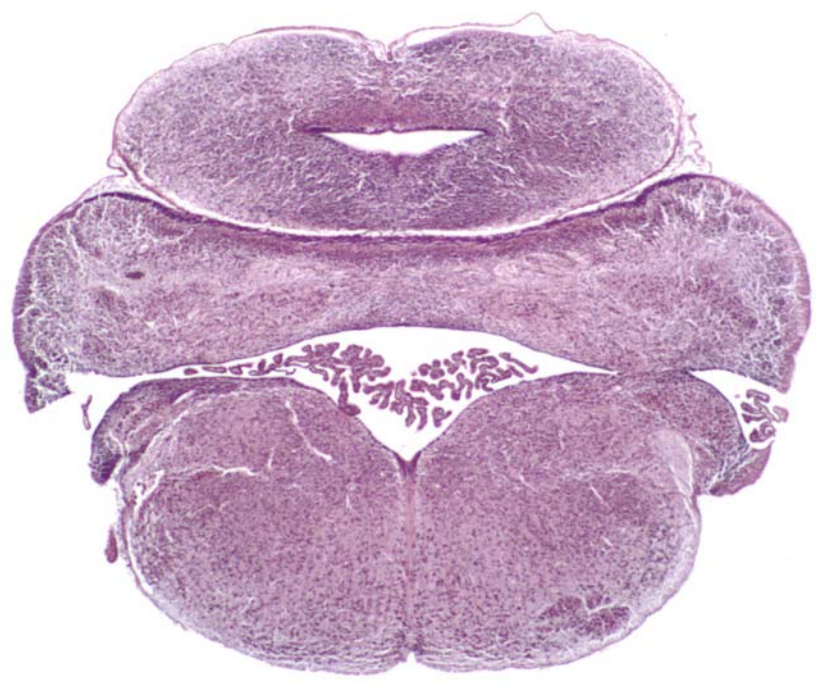






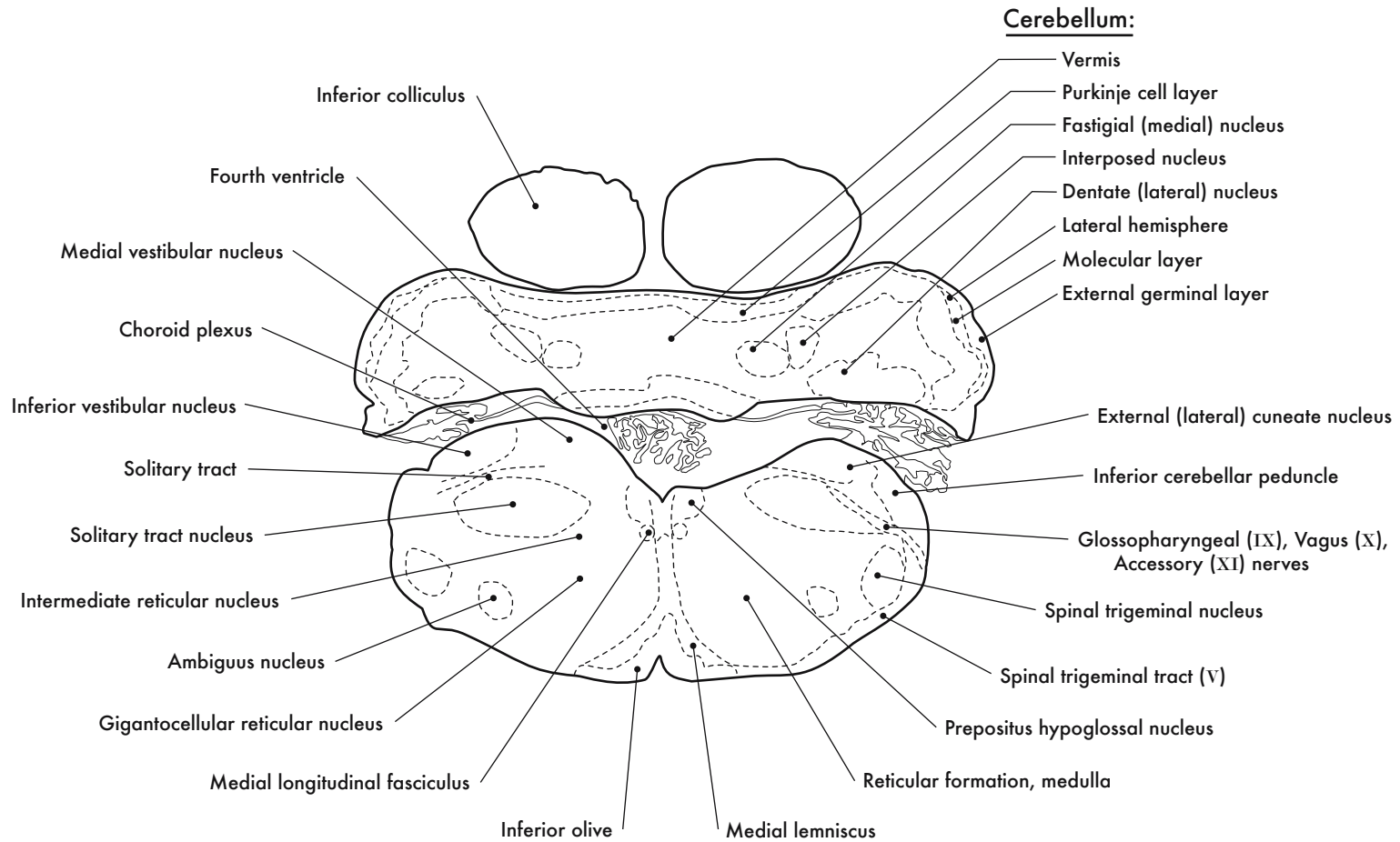
GD 18 CORONAL 23

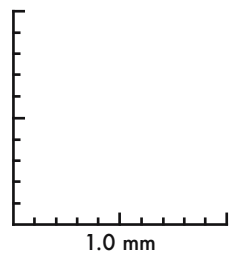
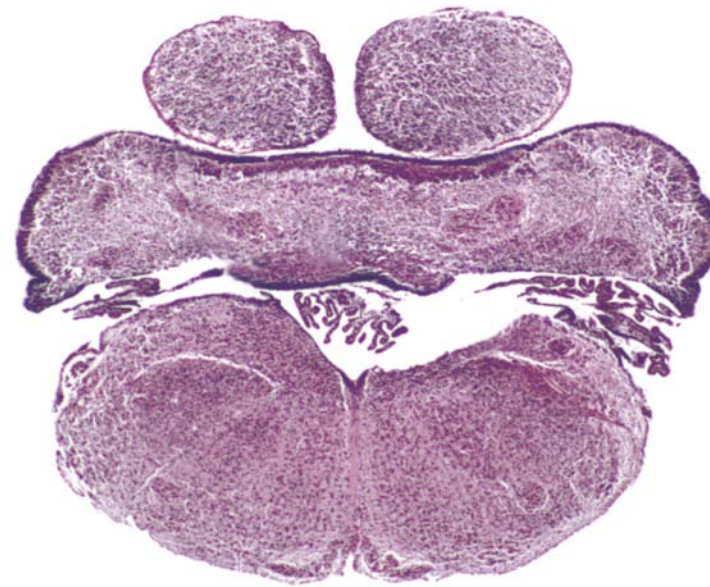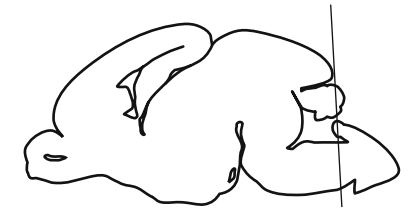




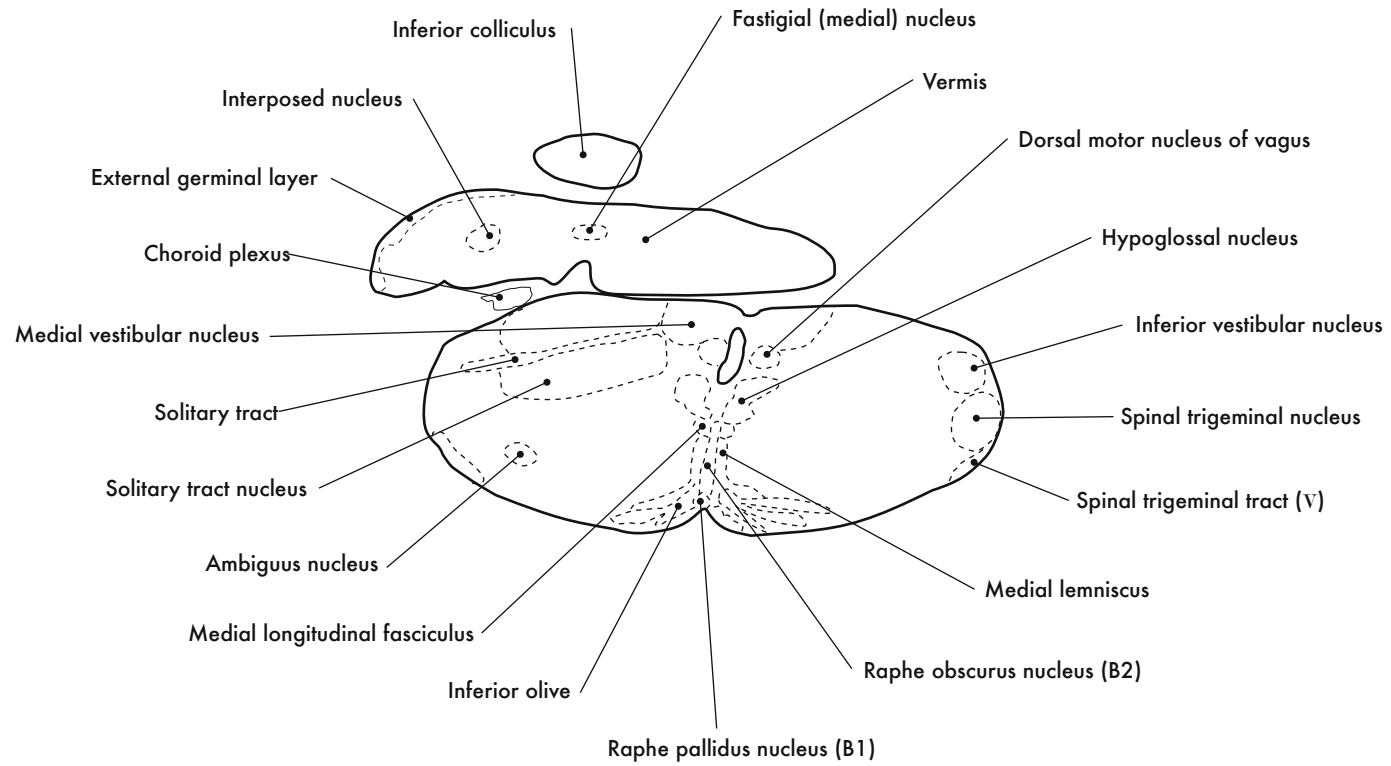
GD 18 CORONAL 24

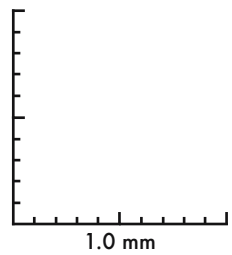
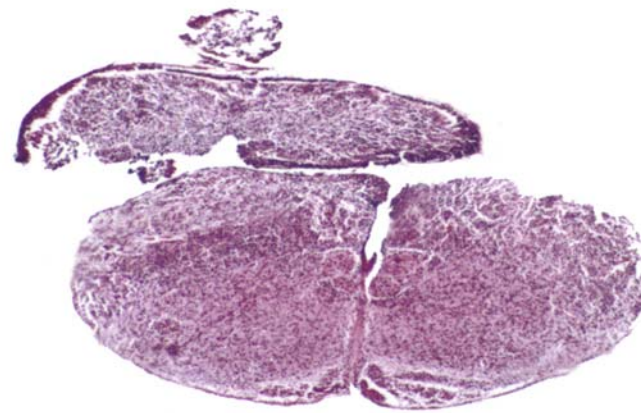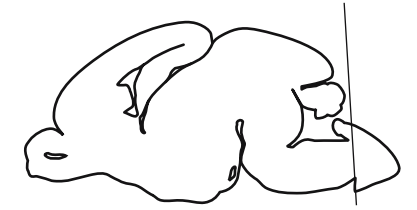






GD 18 CORONAL 25






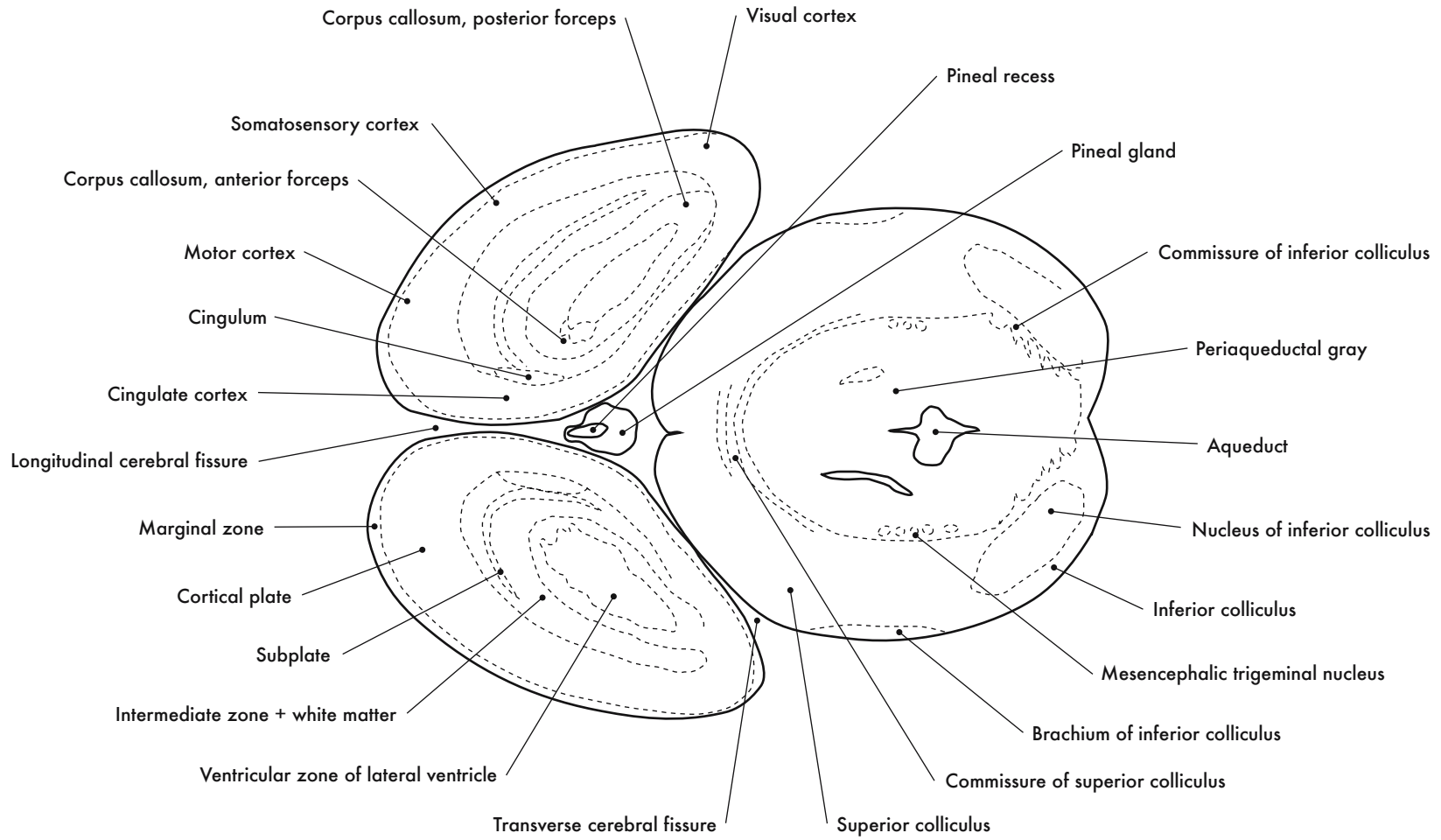
GD 18 CORONAL 26

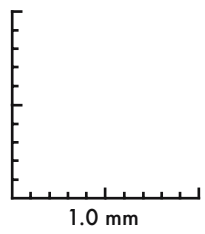
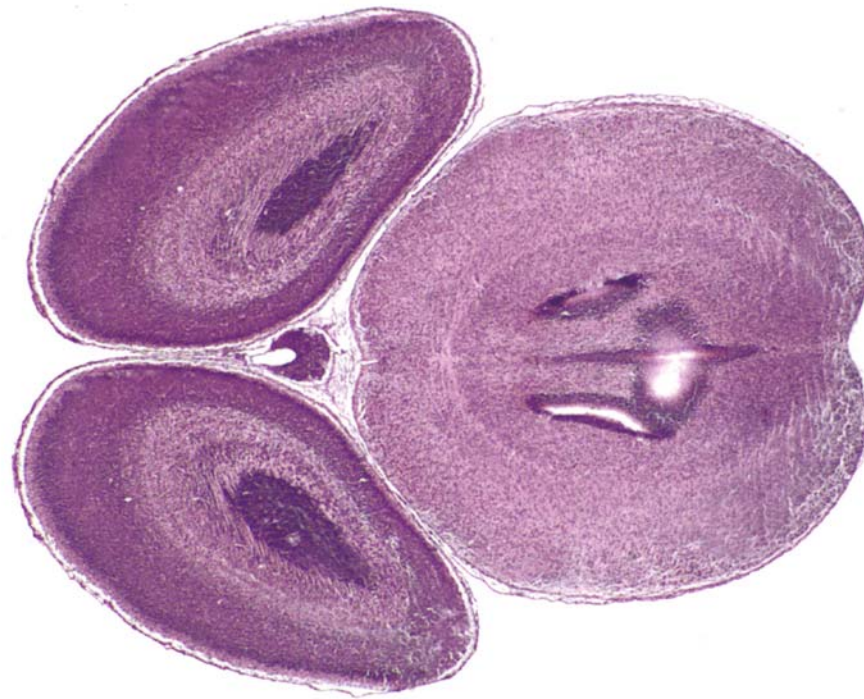


HP denotes image enlargement

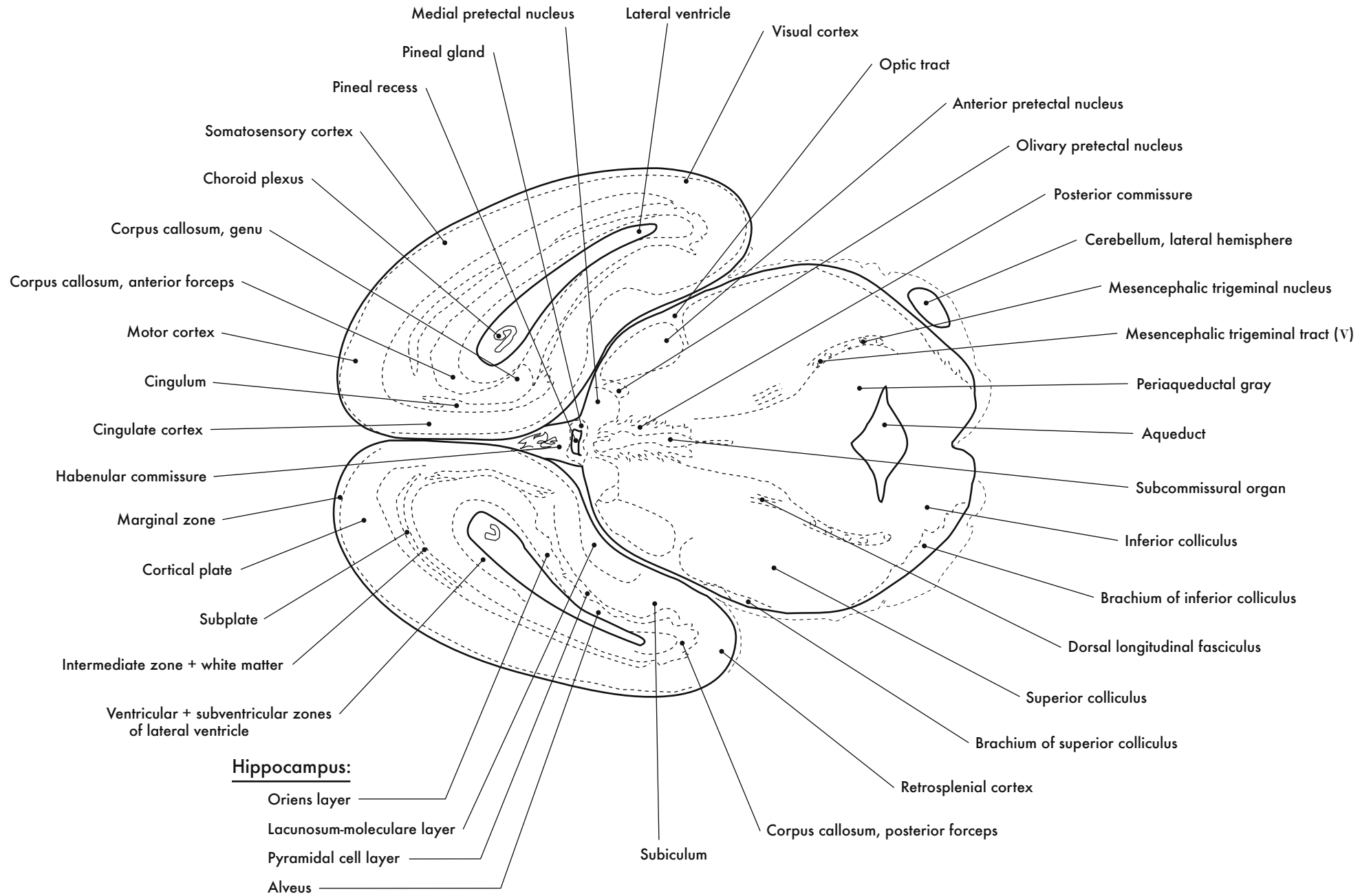


**GESTATIONAL DAY 18 (GD 18)  
HORIZONTAL SECTIONS**

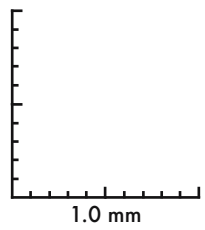
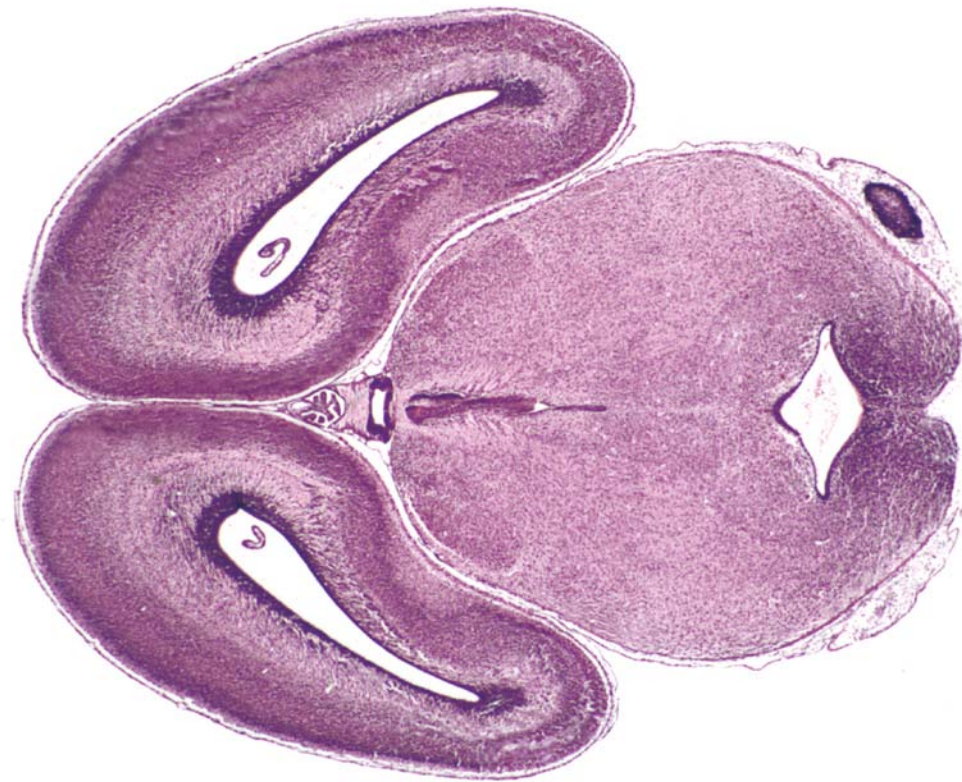





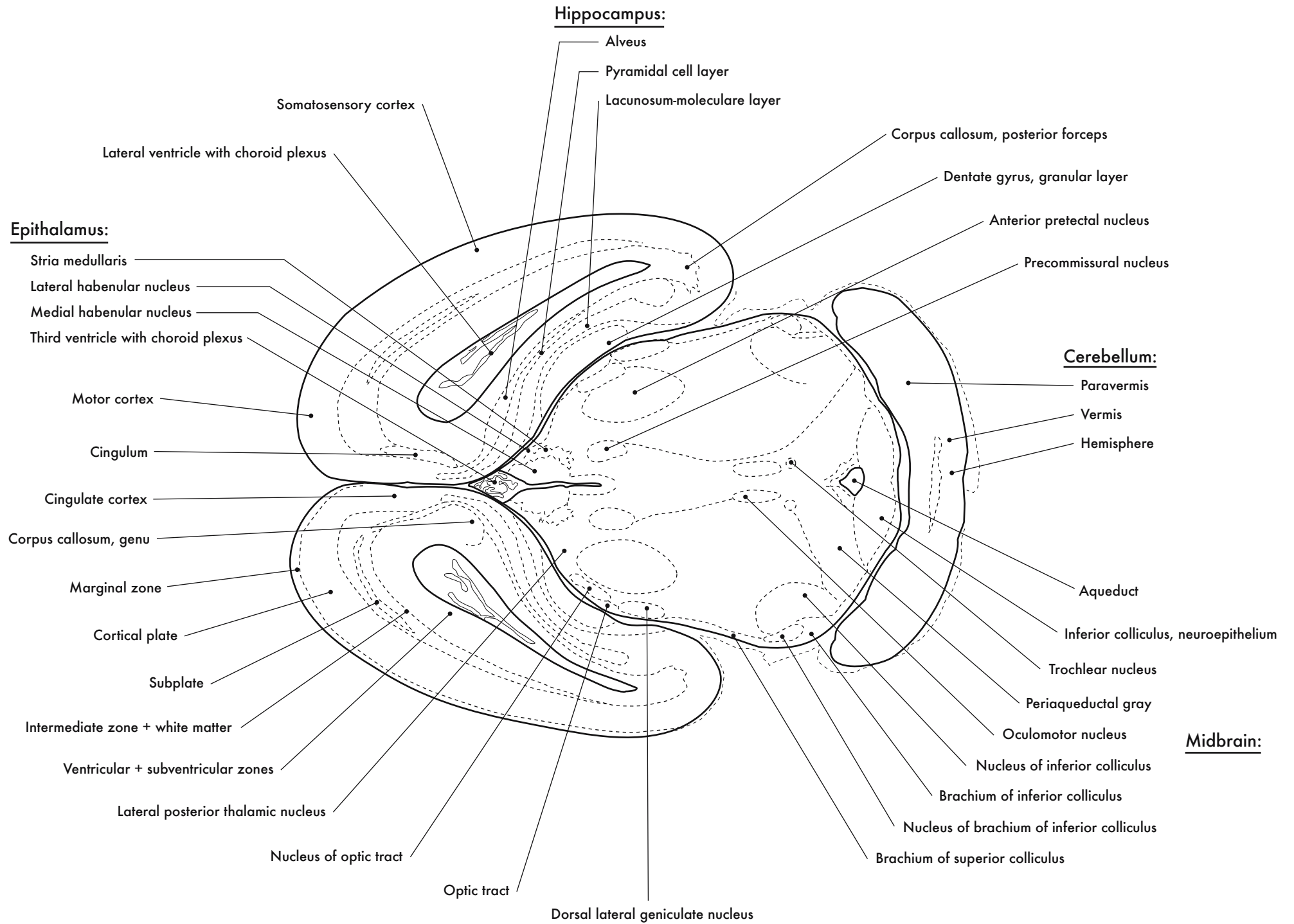
GD 18 HORIZONTAL 1

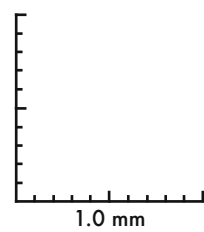
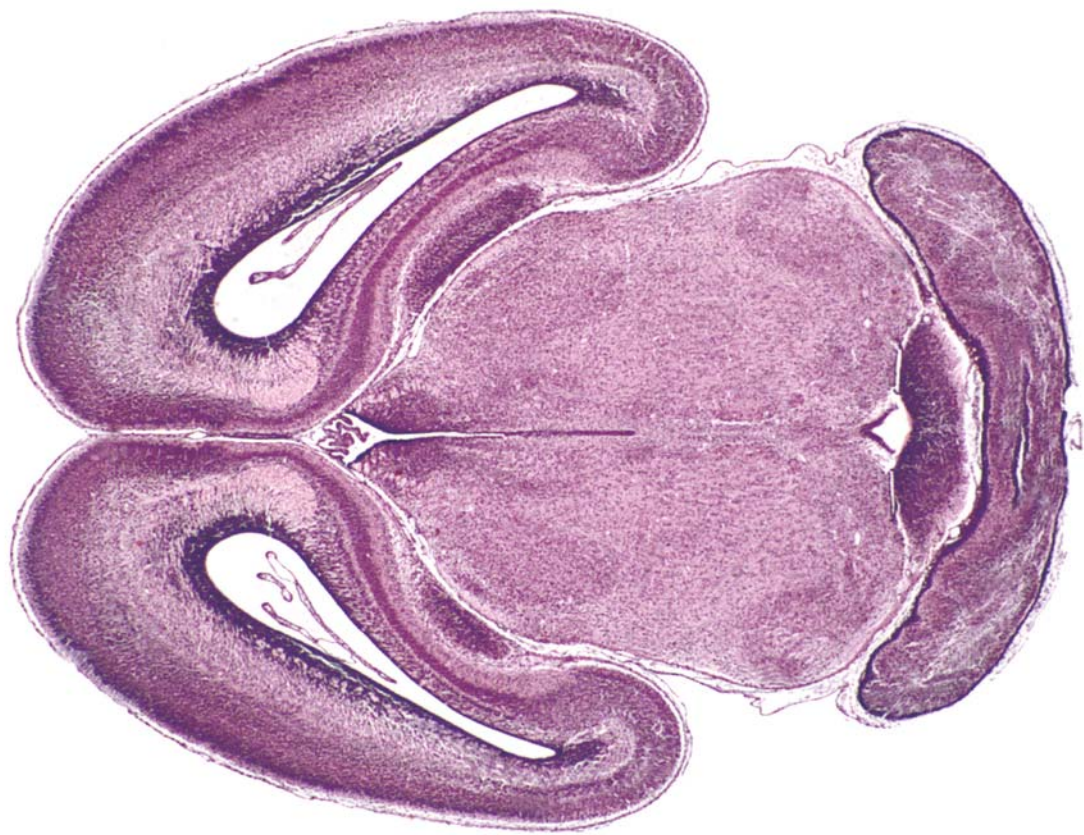



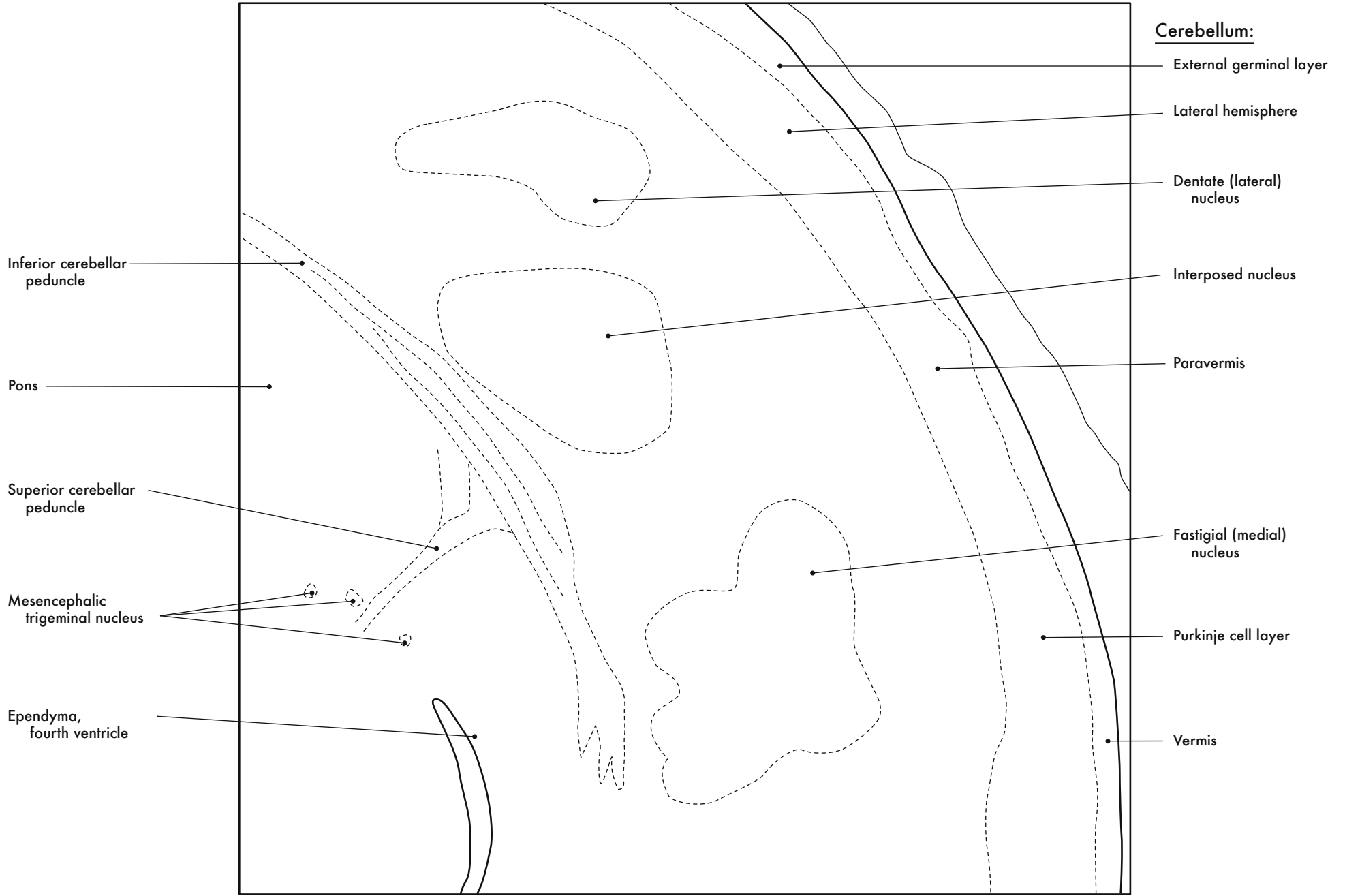


GD 18 HORIZONTAL 2



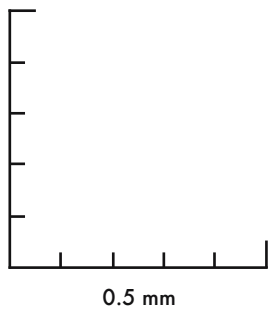
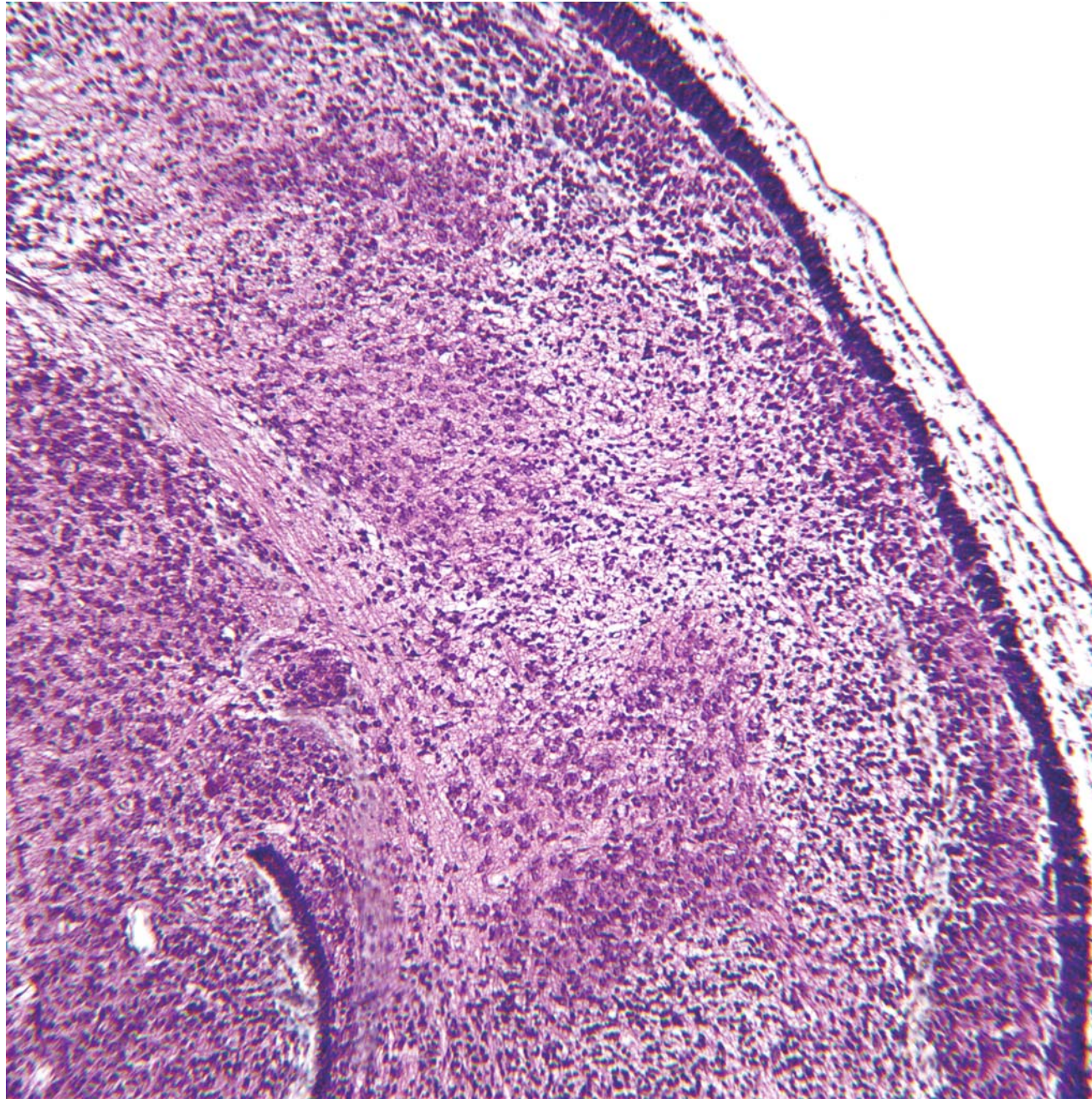
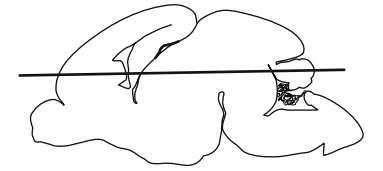
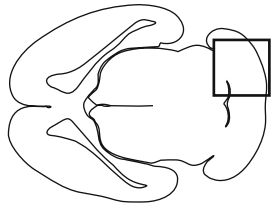


GD 18 HORIZONTAL 3

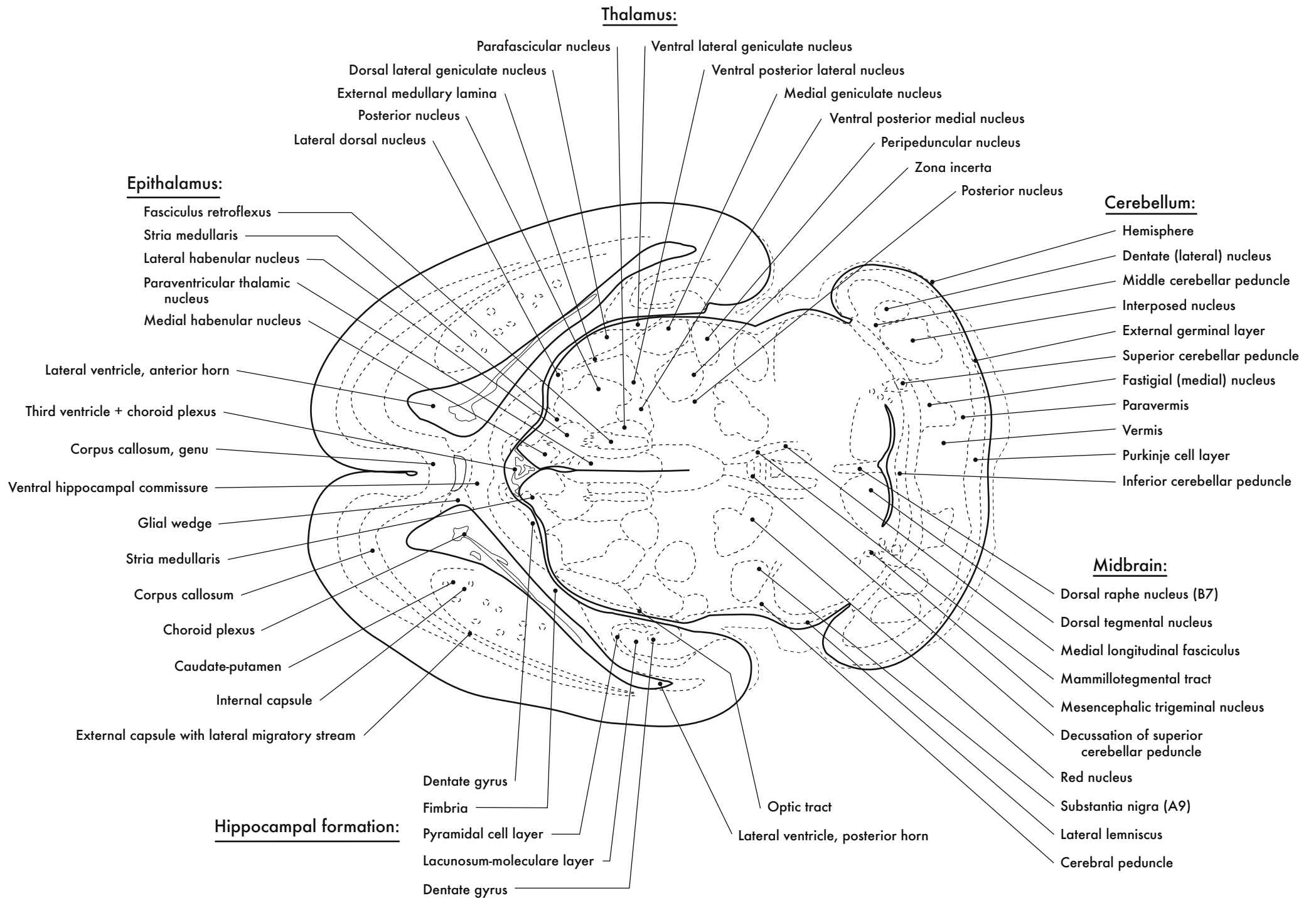


Cerebellum

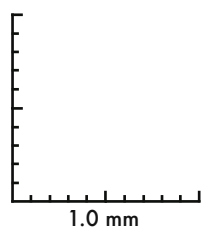
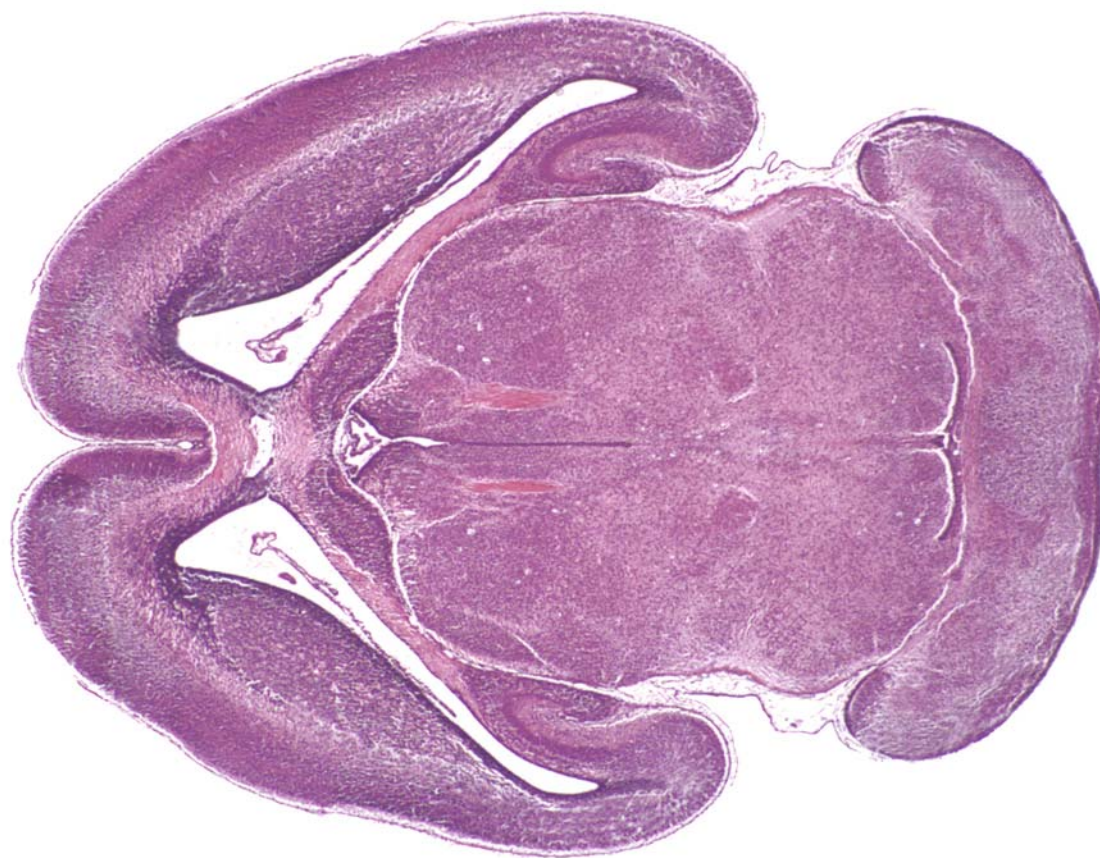




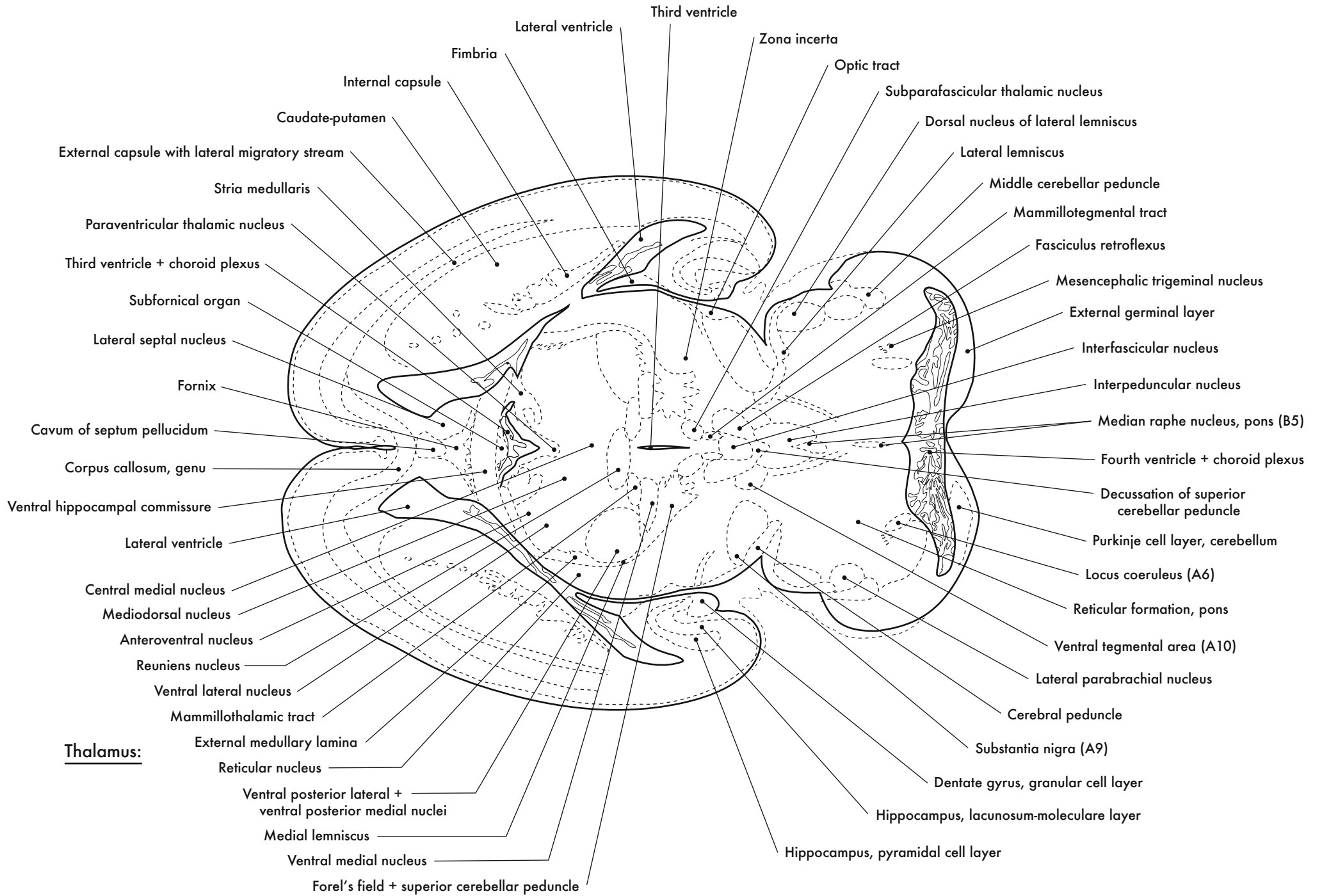
GD 18 HORIZONTAL 4



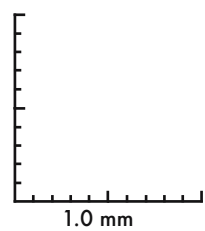
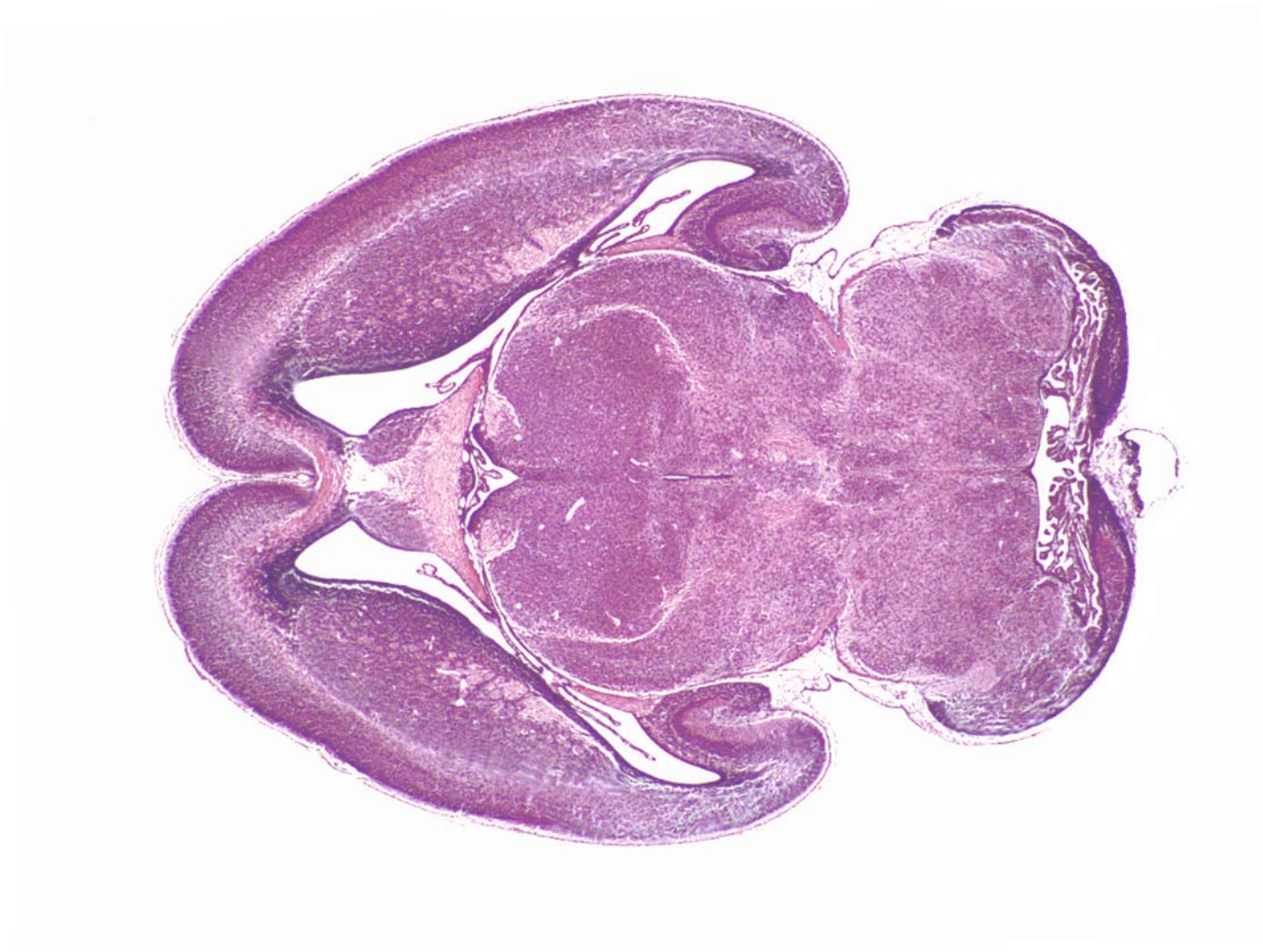




GD 18 HORIZONTAL 5

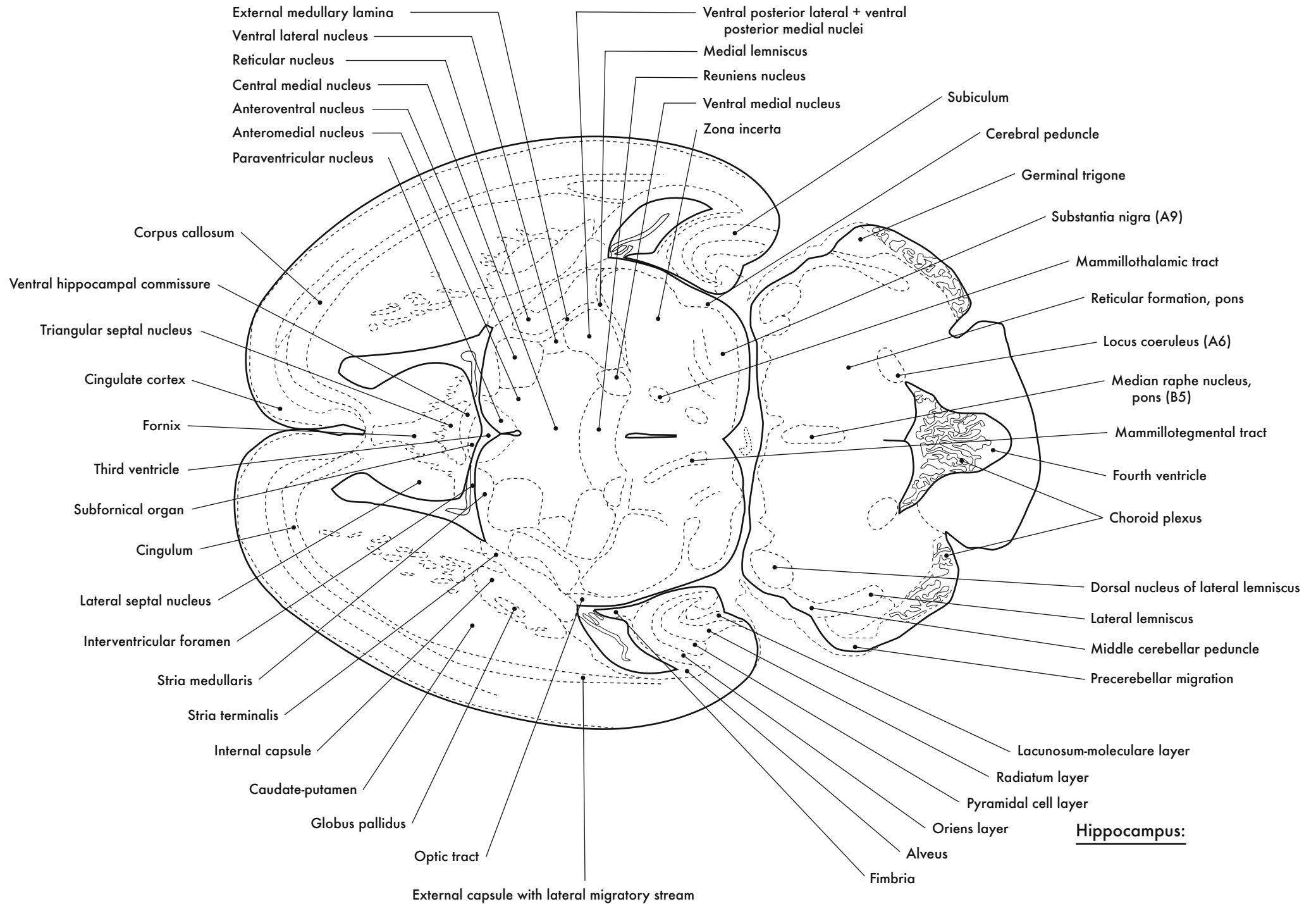


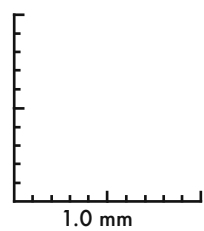
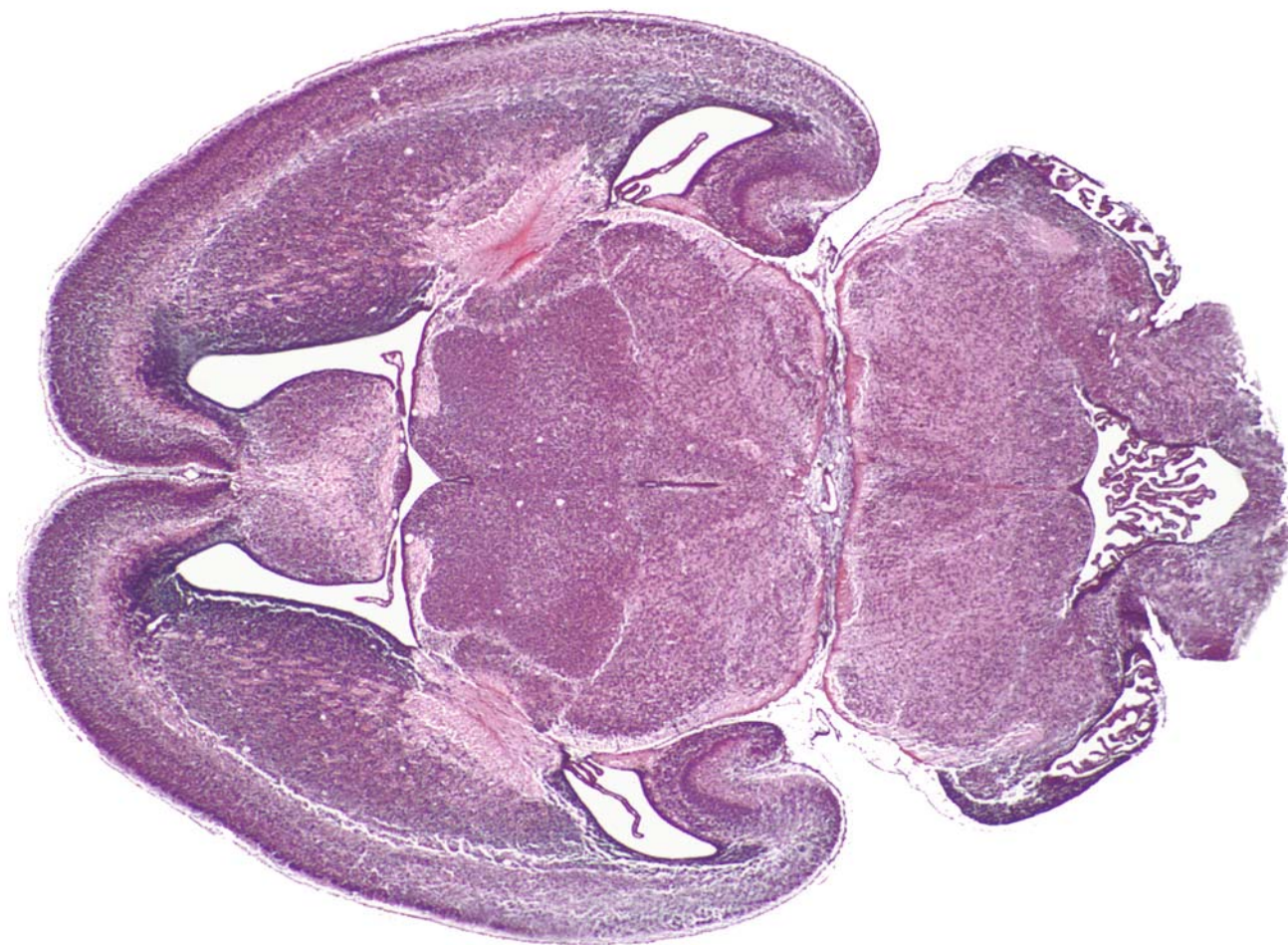




GD 18 HORIZONTAL 6

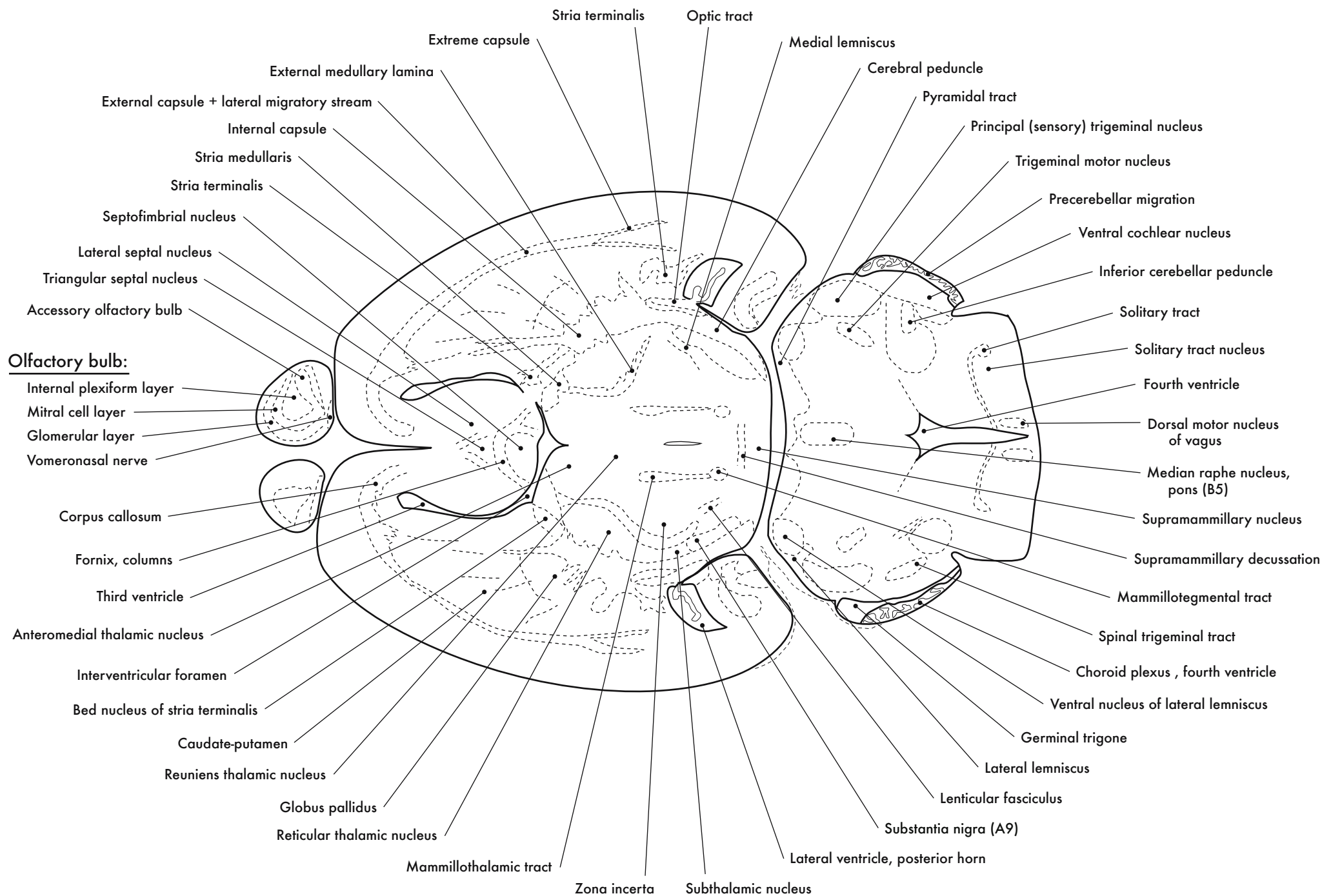
Thalamus:



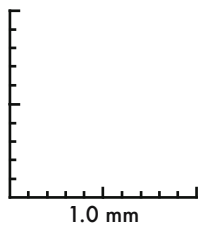
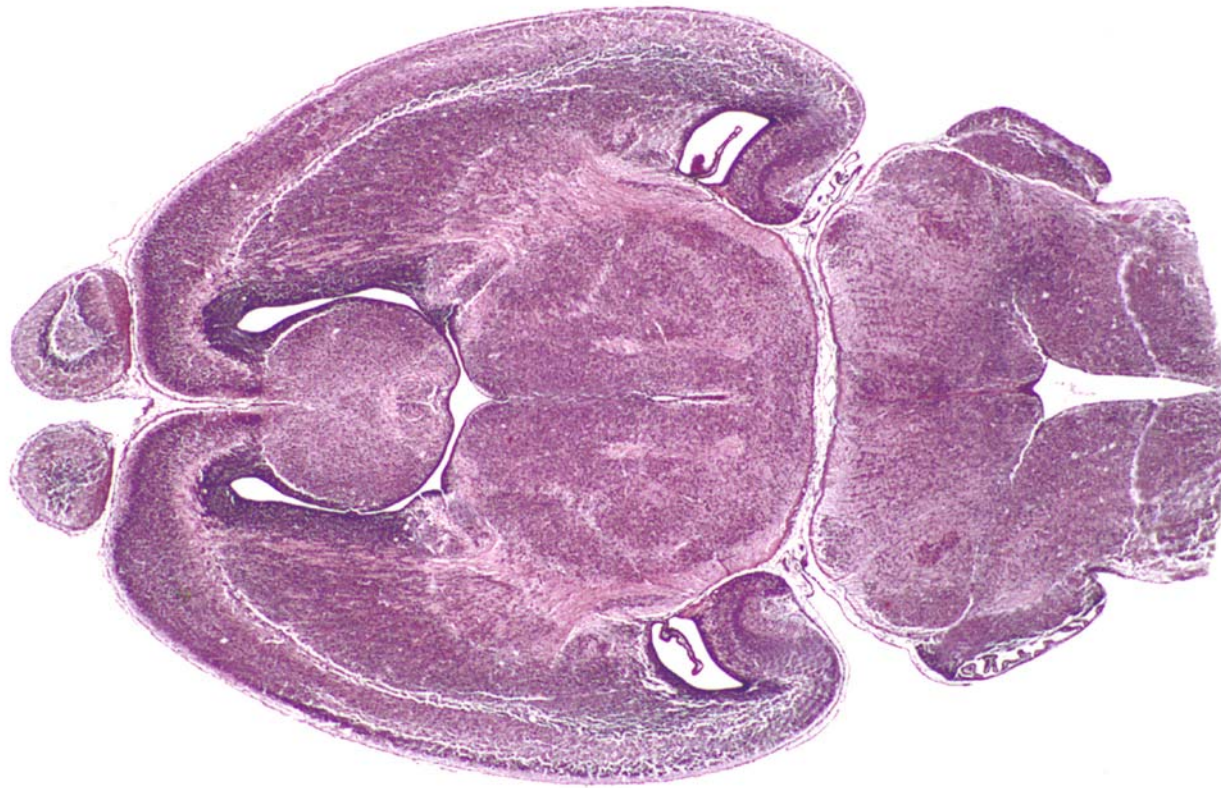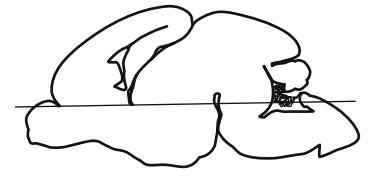


GD 18 HORIZONTAL 7





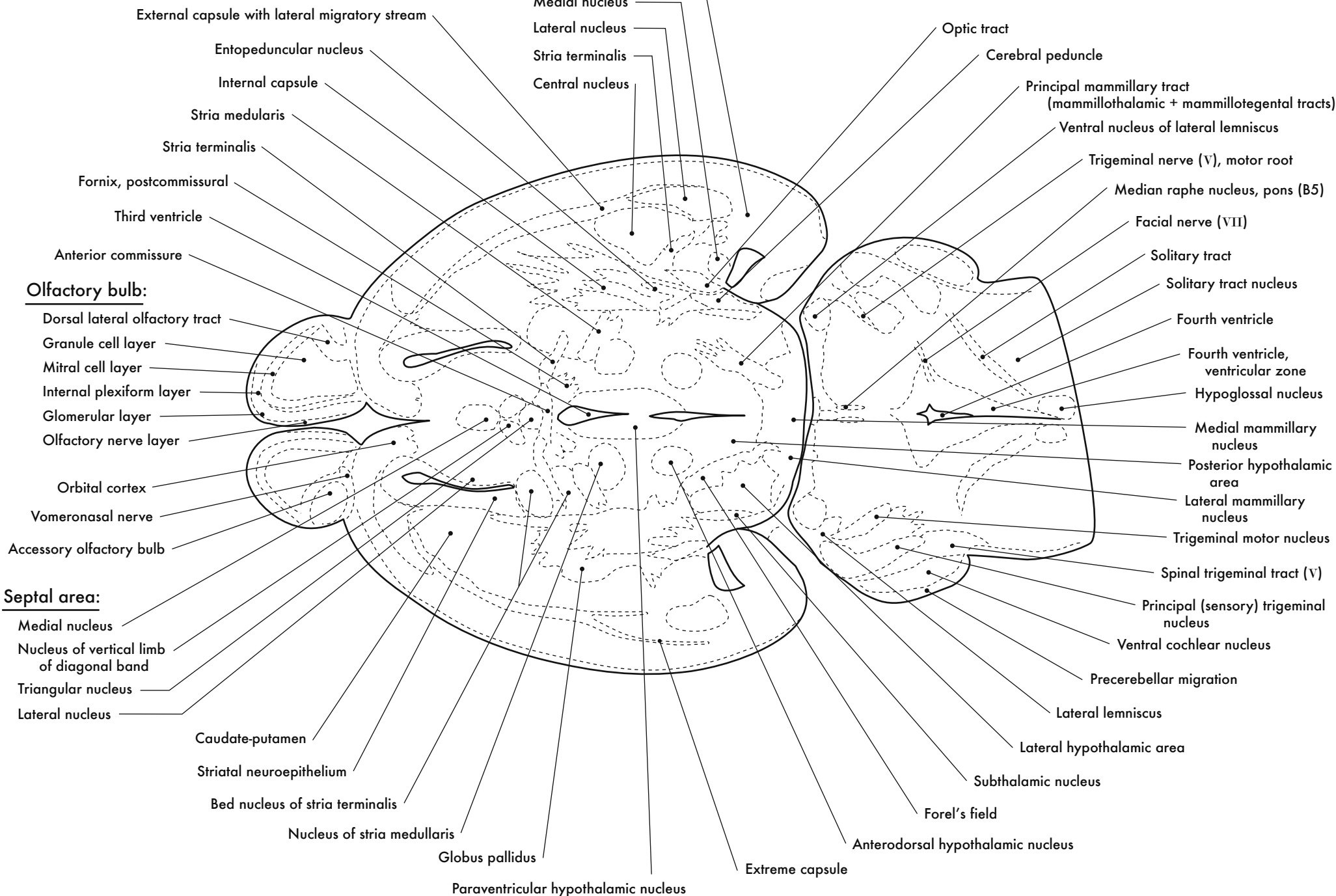




GD 18 HORIZONTAL 8

Amygdala:

- Basolateral nucleus
- Medial nucleus
- Lateral nucleus
- Stria terminalis
- Central nucleus



- External capsule with lateral migratory stream
- Entopeduncular nucleus
- Internal capsule
- Stria medularis
- Stria terminalis
- Fornix, postcommissural
- Third ventricle
- Anterior commissure

Olfactory bulb:

- Dorsal lateral olfactory tract
- Granule cell layer
- Mitral cell layer
- Internal plexiform layer
- Glomerular layer
- Olfactory nerve layer

- Orbital cortex
- Vomeranosal nerve
- Accessory olfactory bulb

Septal area:

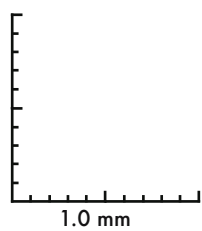
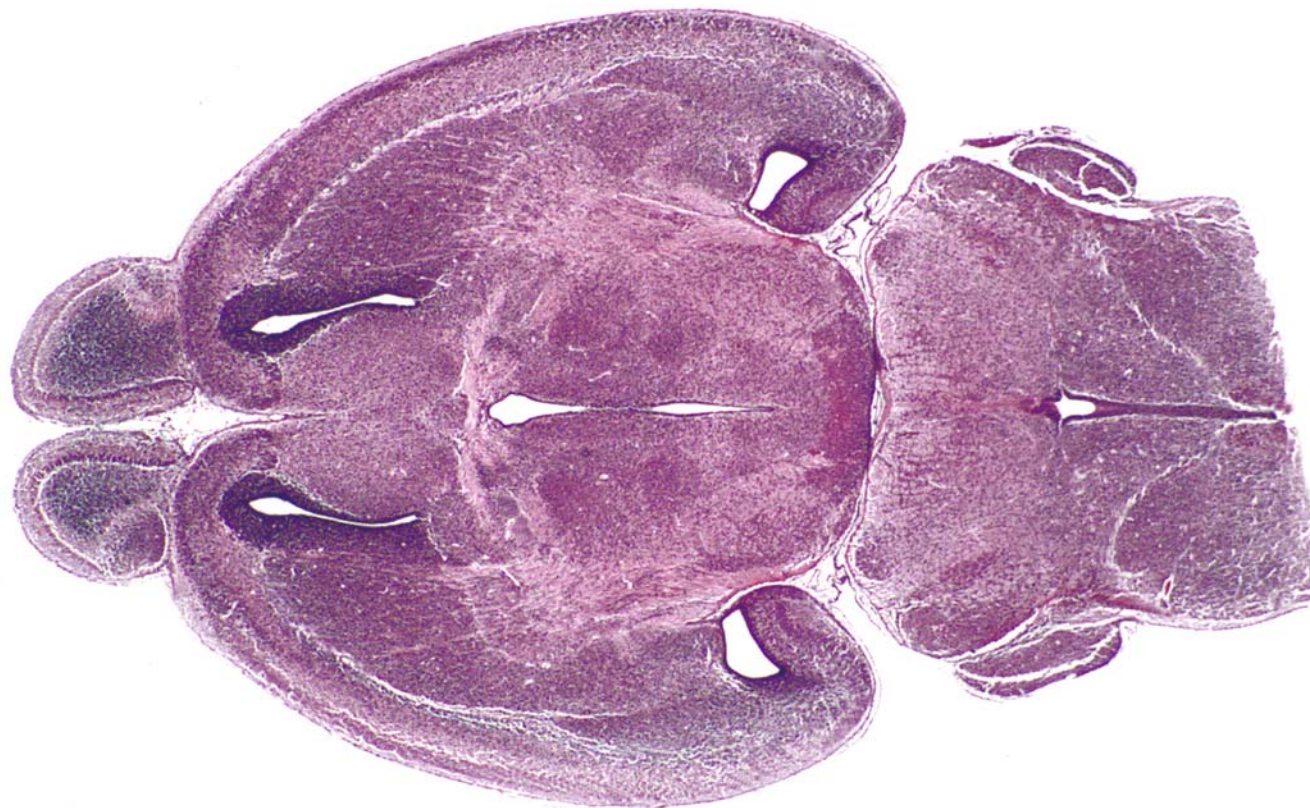
- Medial nucleus
- Nucleus of vertical limb of diagonal band
- Triangular nucleus
- Lateral nucleus

- Caudate-putamen
- Striatal neuroepithelium
- Bed nucleus of stria terminalis
- Nucleus of stria medullaris

- Globus pallidus
- Paraventricular hypothalamic nucleus

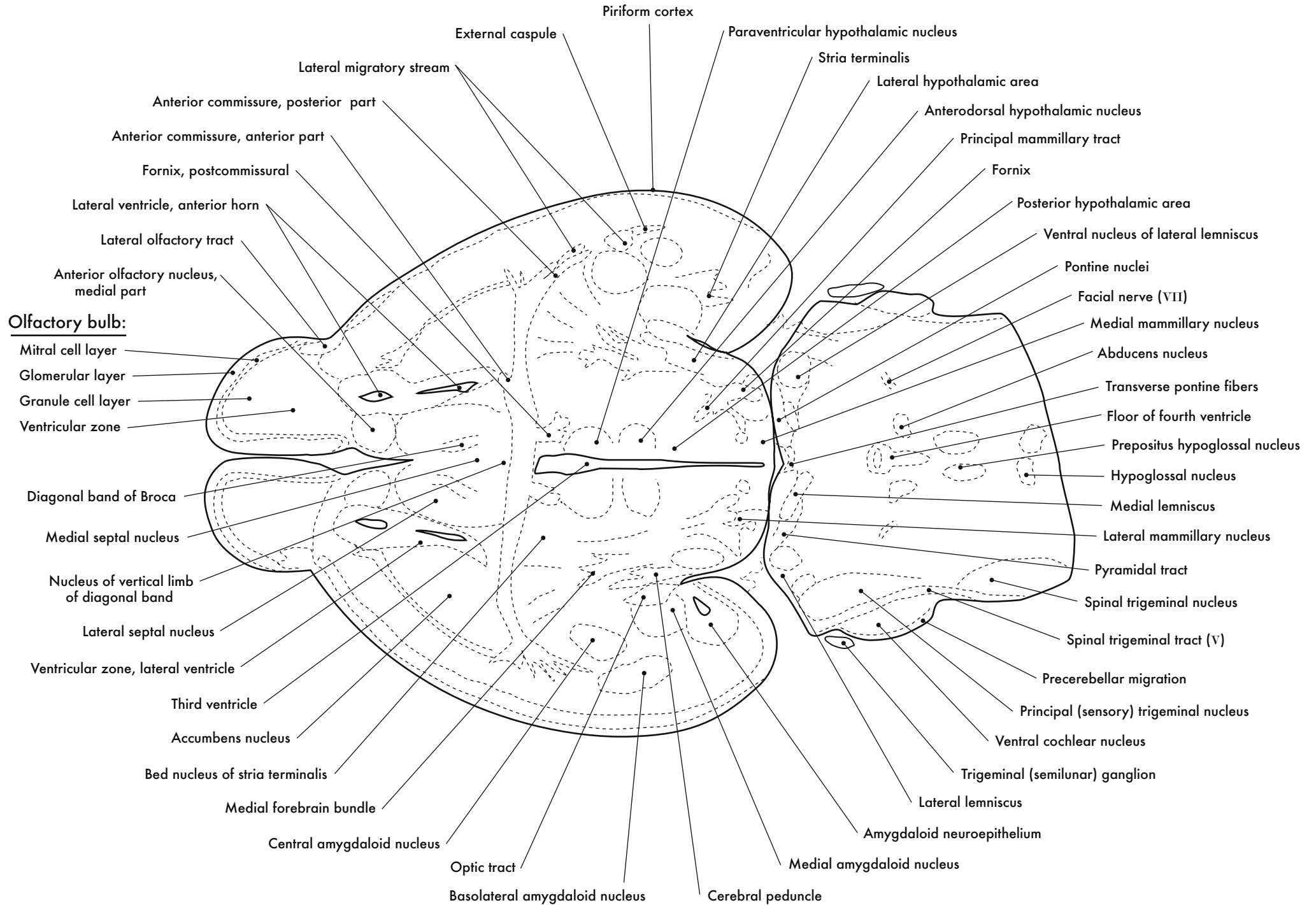
- Optic tract
- Cerebral peduncle
- Principal mammillary tract (mammillothalamic + mammillotegental tracts)
- Ventral nucleus of lateral lemniscus
- Trigeminal nerve (V), motor root
- Median raphe nucleus, pons (B5)
- Facial nerve (VII)
- Solitary tract
- Solitary tract nucleus
- Fourth ventricle
- Fourth ventricle, ventricular zone
- Hypoglossal nucleus
- Medial mammillary nucleus
- Posterior hypothalamic area
- Lateral mammillary nucleus
- Trigeminal motor nucleus
- Spinal trigeminal tract (V)
- Principal (sensory) trigeminal nucleus
- Ventral cochlear nucleus
- Precerebellar migration
- Lateral lemniscus
- Lateral hypothalamic area
- Subthalamic nucleus
- Forel's field

- Anterodorsal hypothalamic nucleus
- Extreme capsule

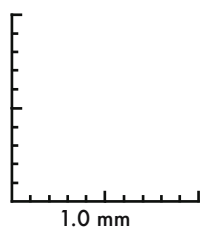
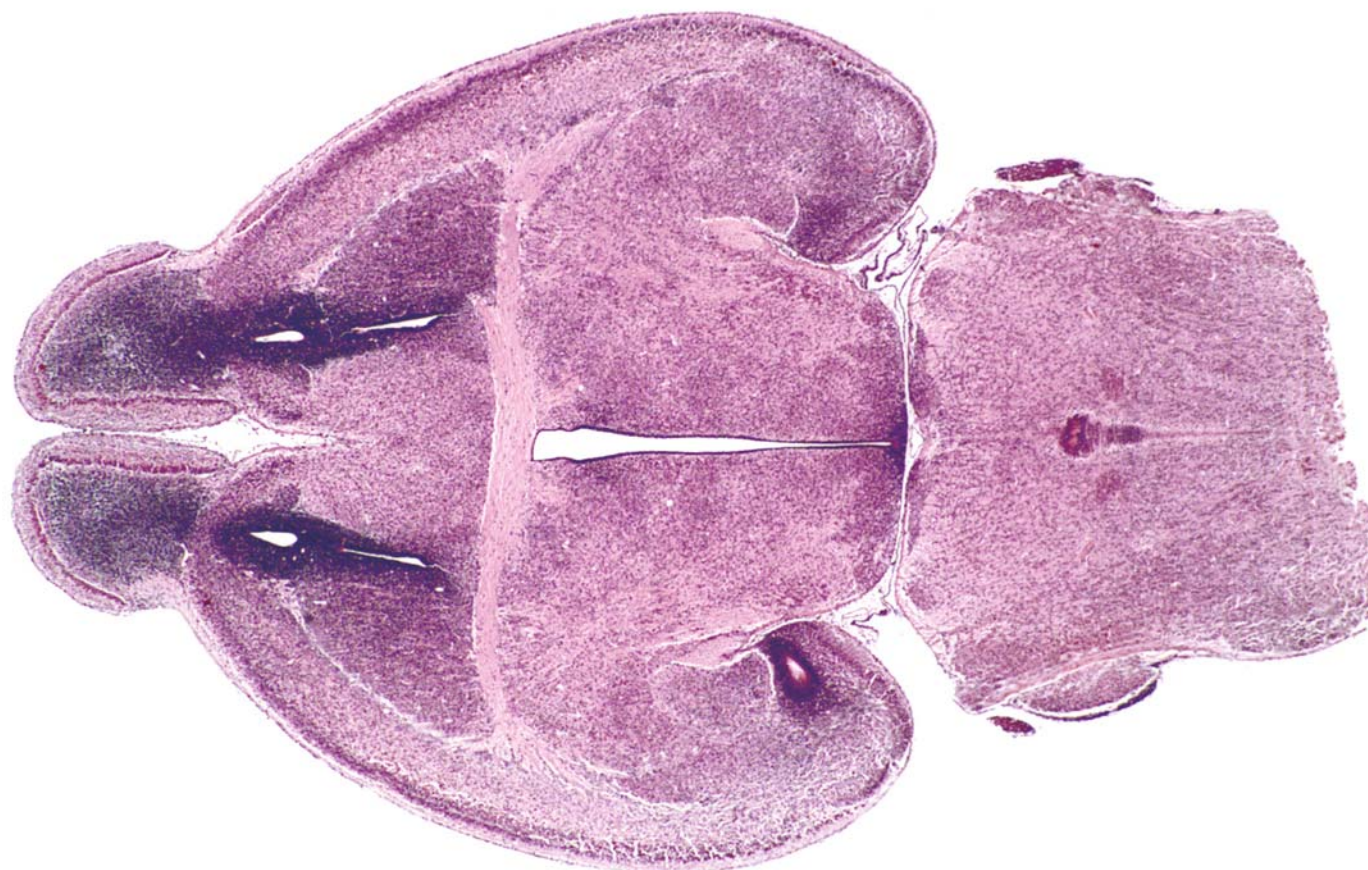

GD 18 HORIZONTAL 9










GD 18 HORIZONTAL 10

521



**Olfactory bulb:**

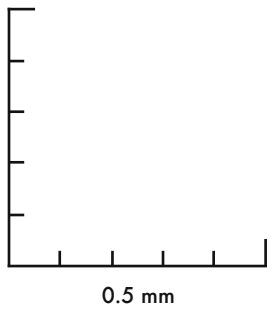
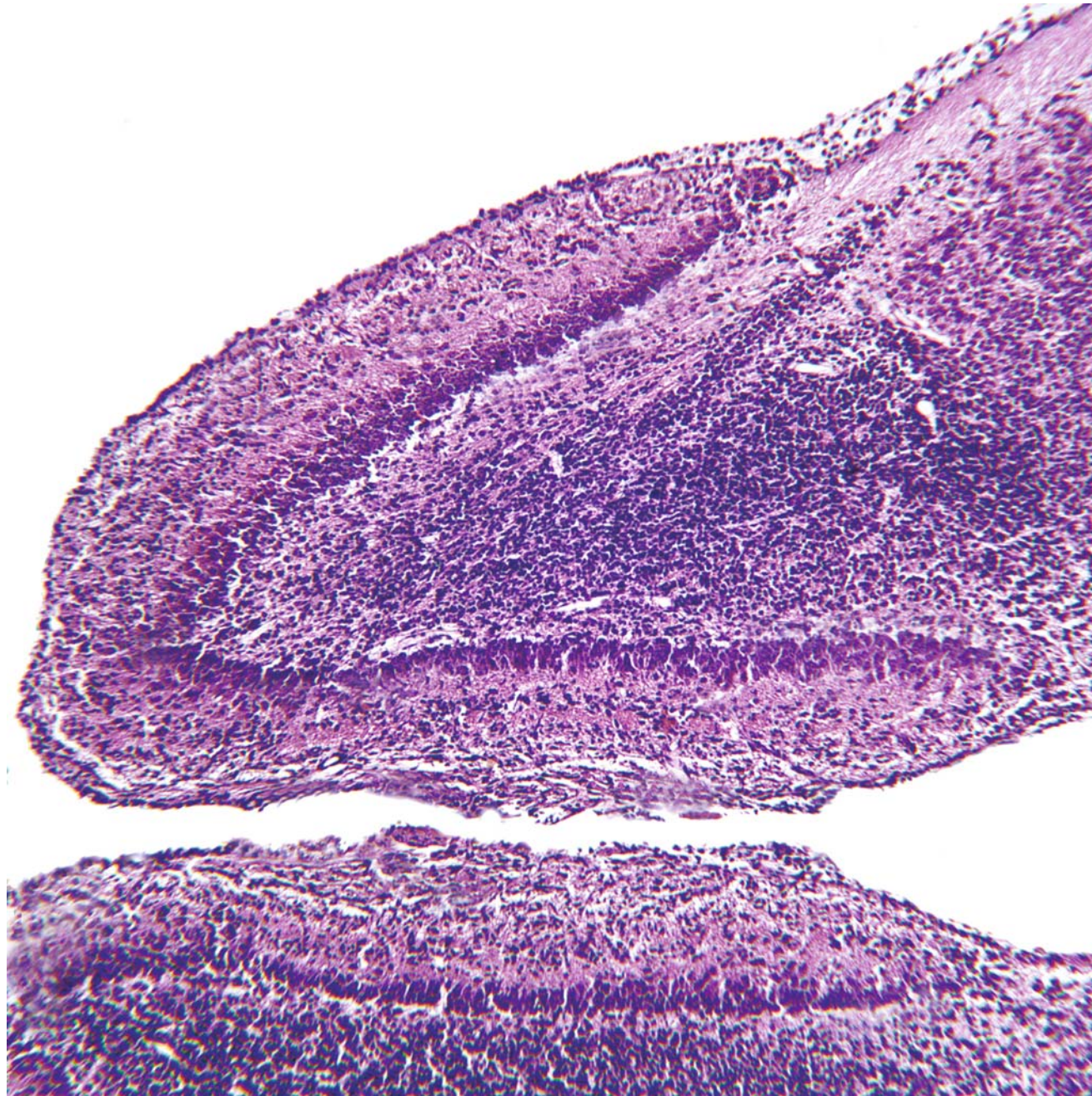
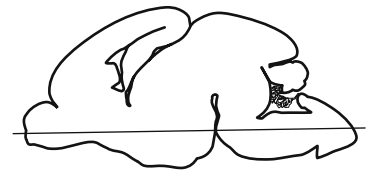
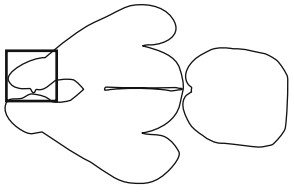
- Olfactory nerve layer
- Glomerular layer
- External plexiform layer
- Mitral cell layer
- Internal plexiform layer
- Granule cell layer

- Lateral olfactory tract
- Anterior commissure, intrabulbar part
- Anterior olfactory nucleus, ventral part

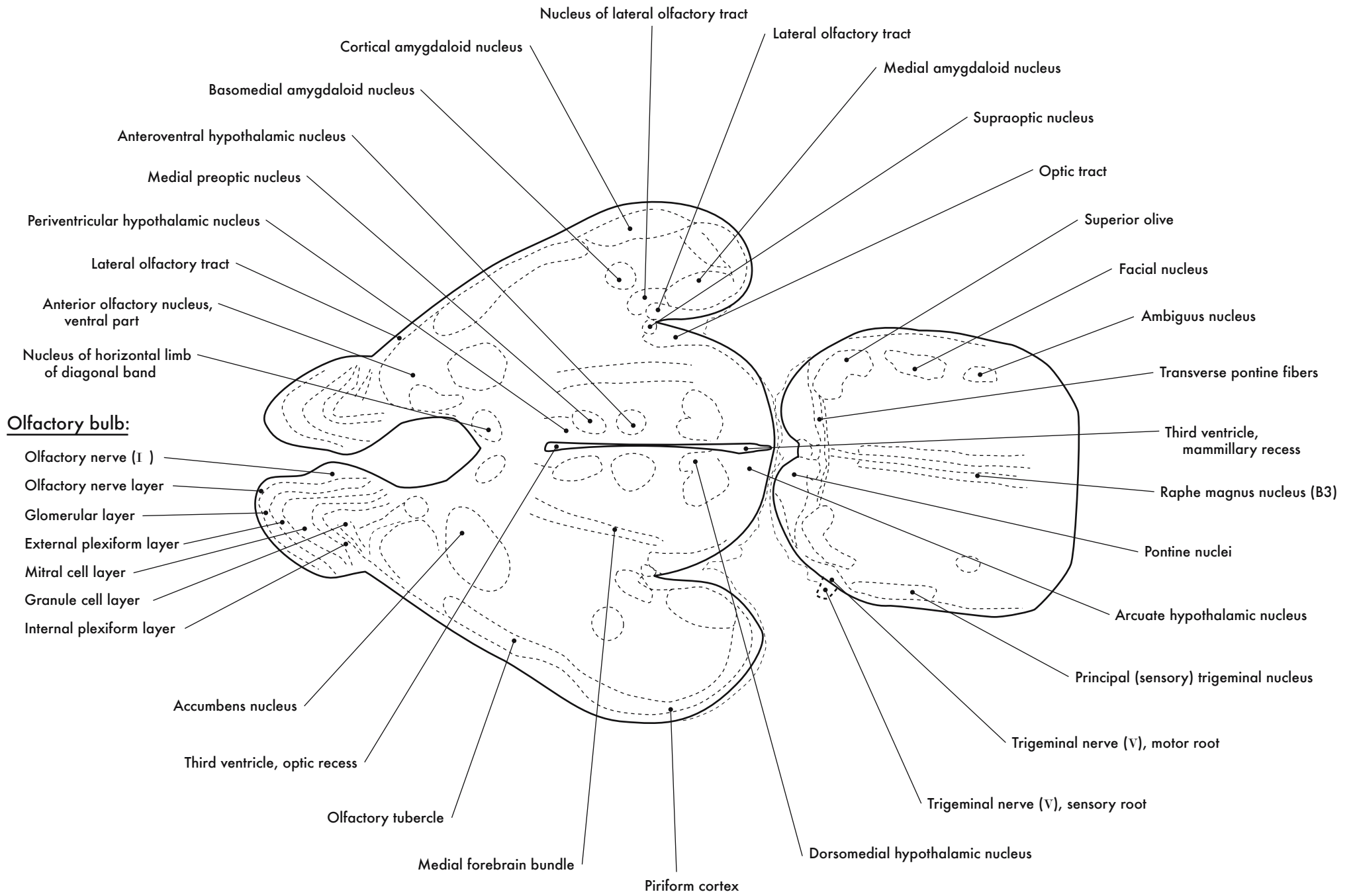
Olfactory nerve ( I )

Olfactory Bulbs

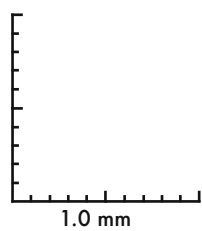
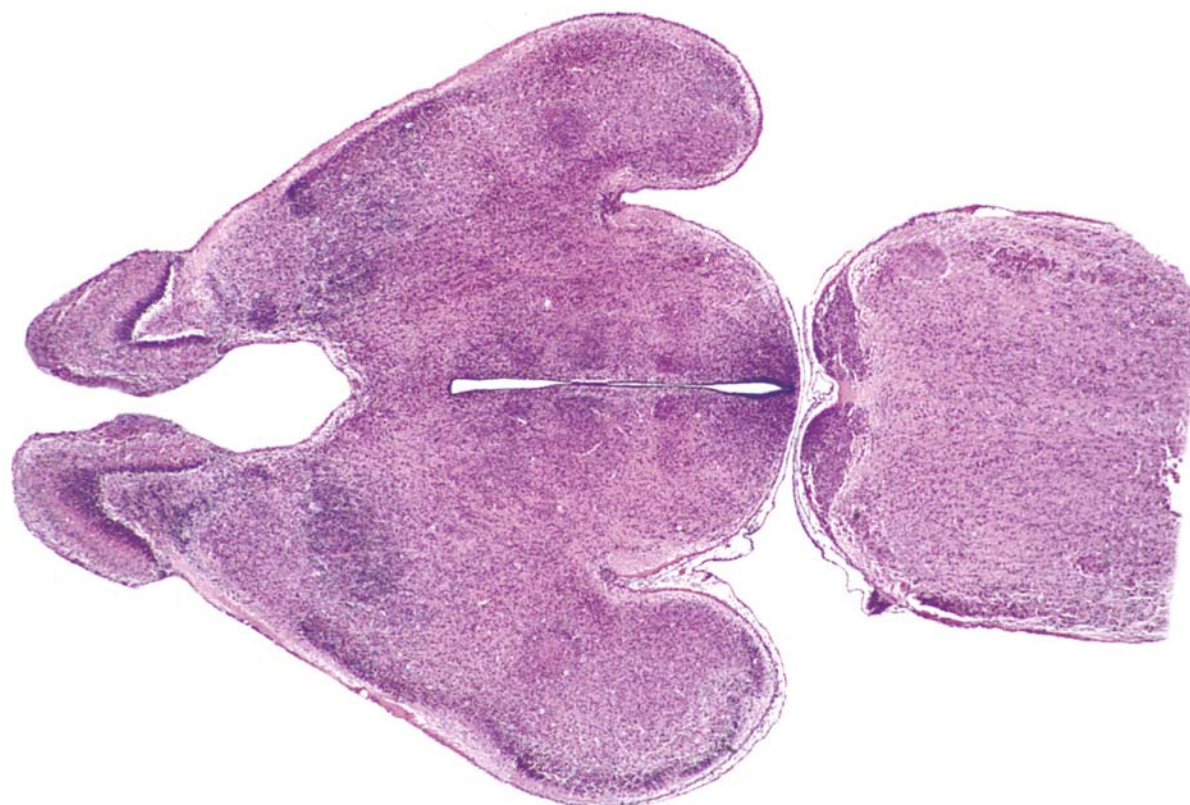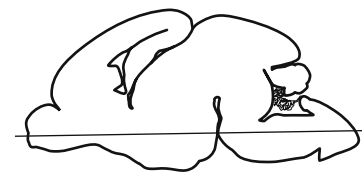




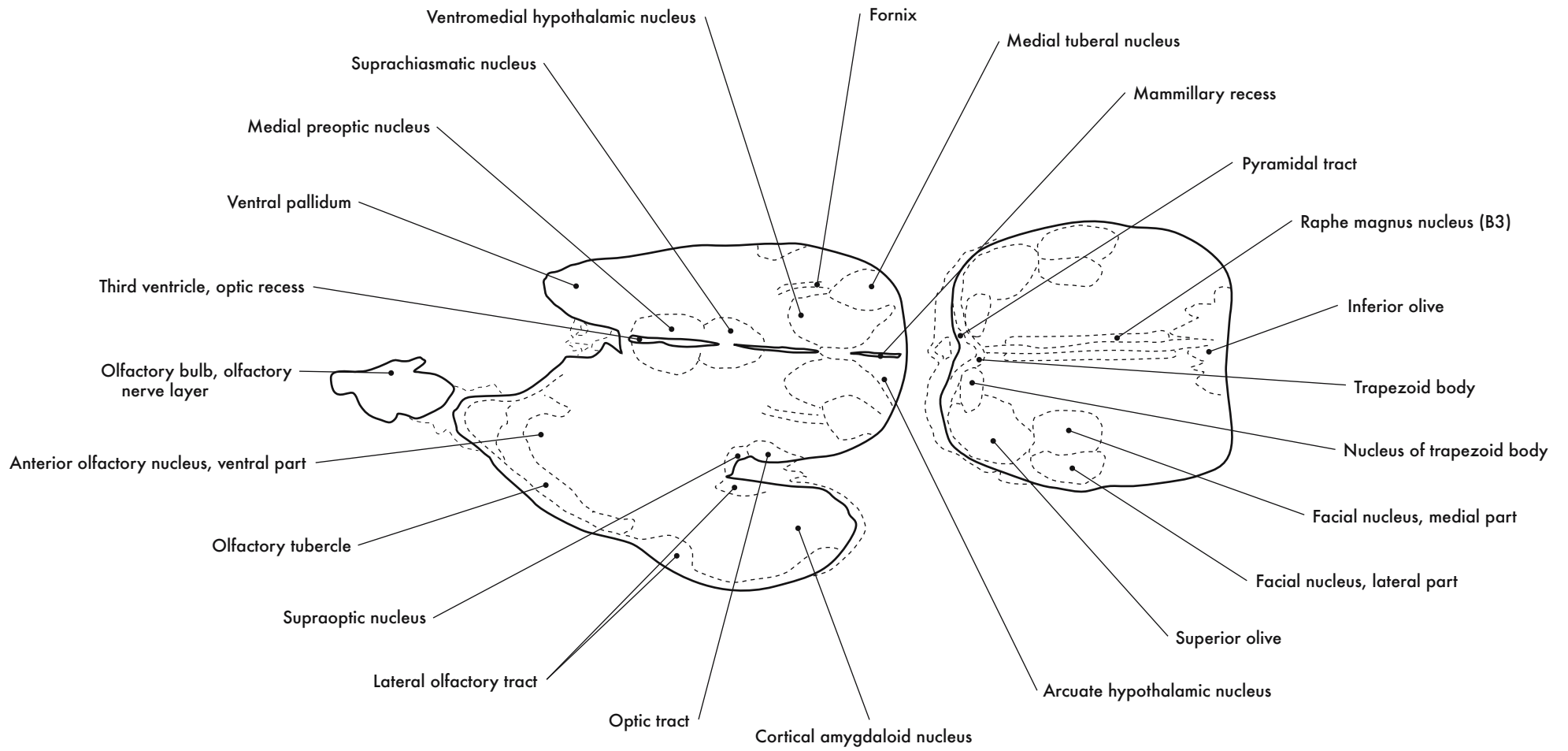
GD 18 HORIZONTAL 11

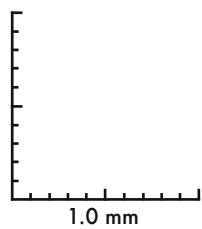
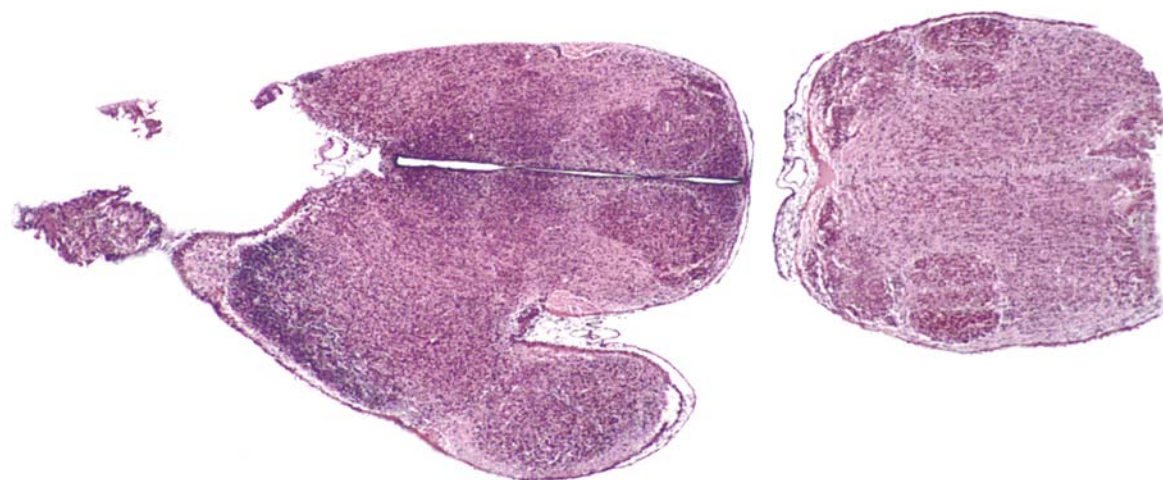





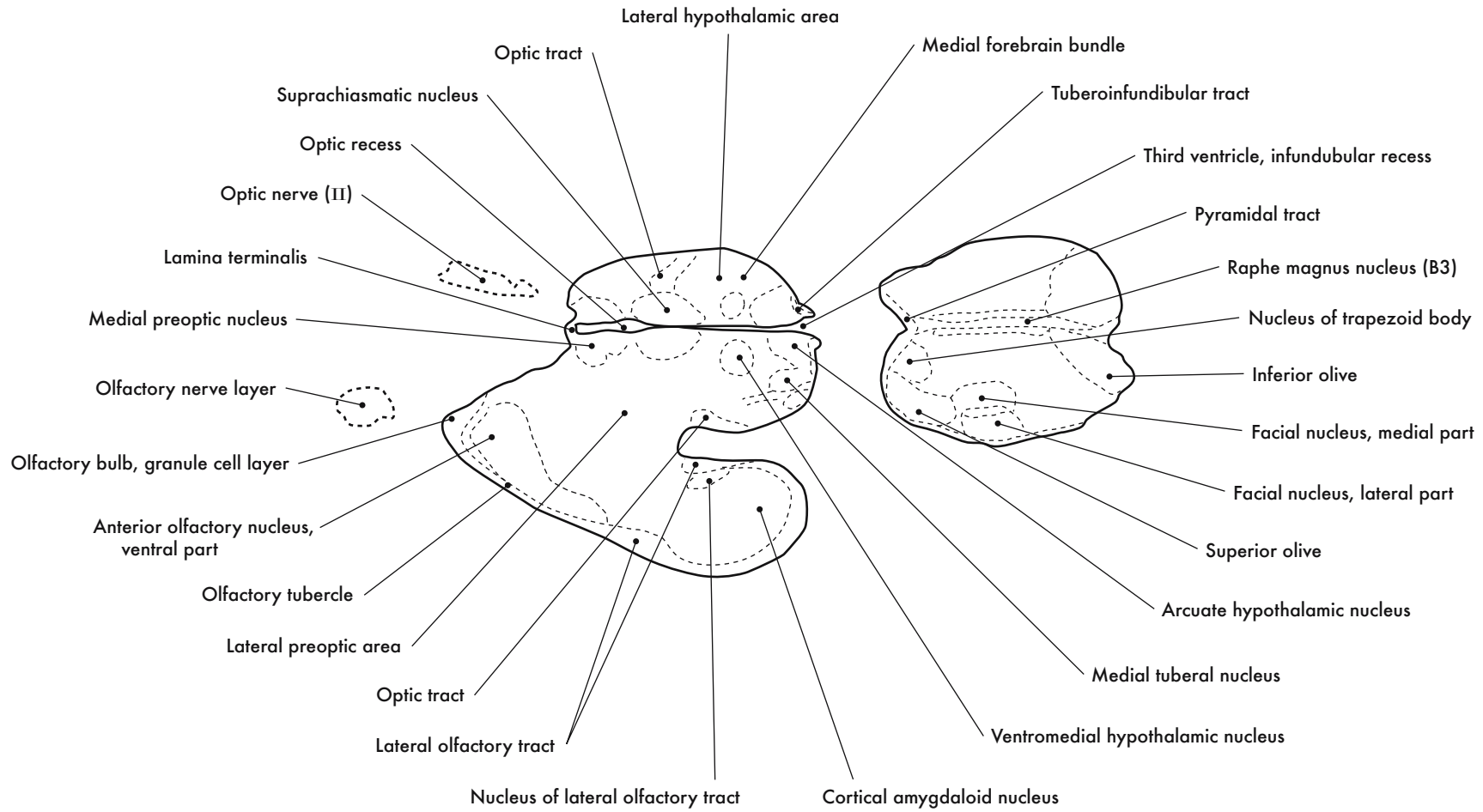


GD 18 HORIZONTAL 12

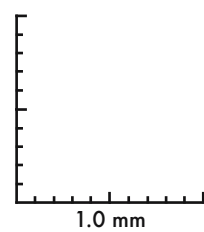
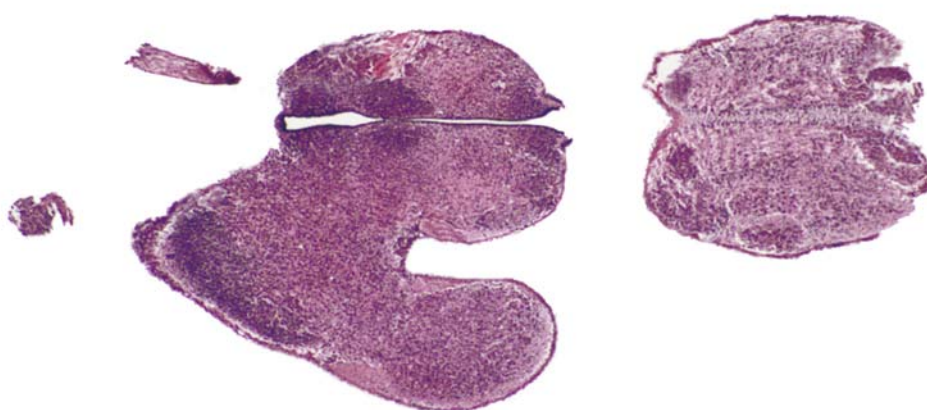




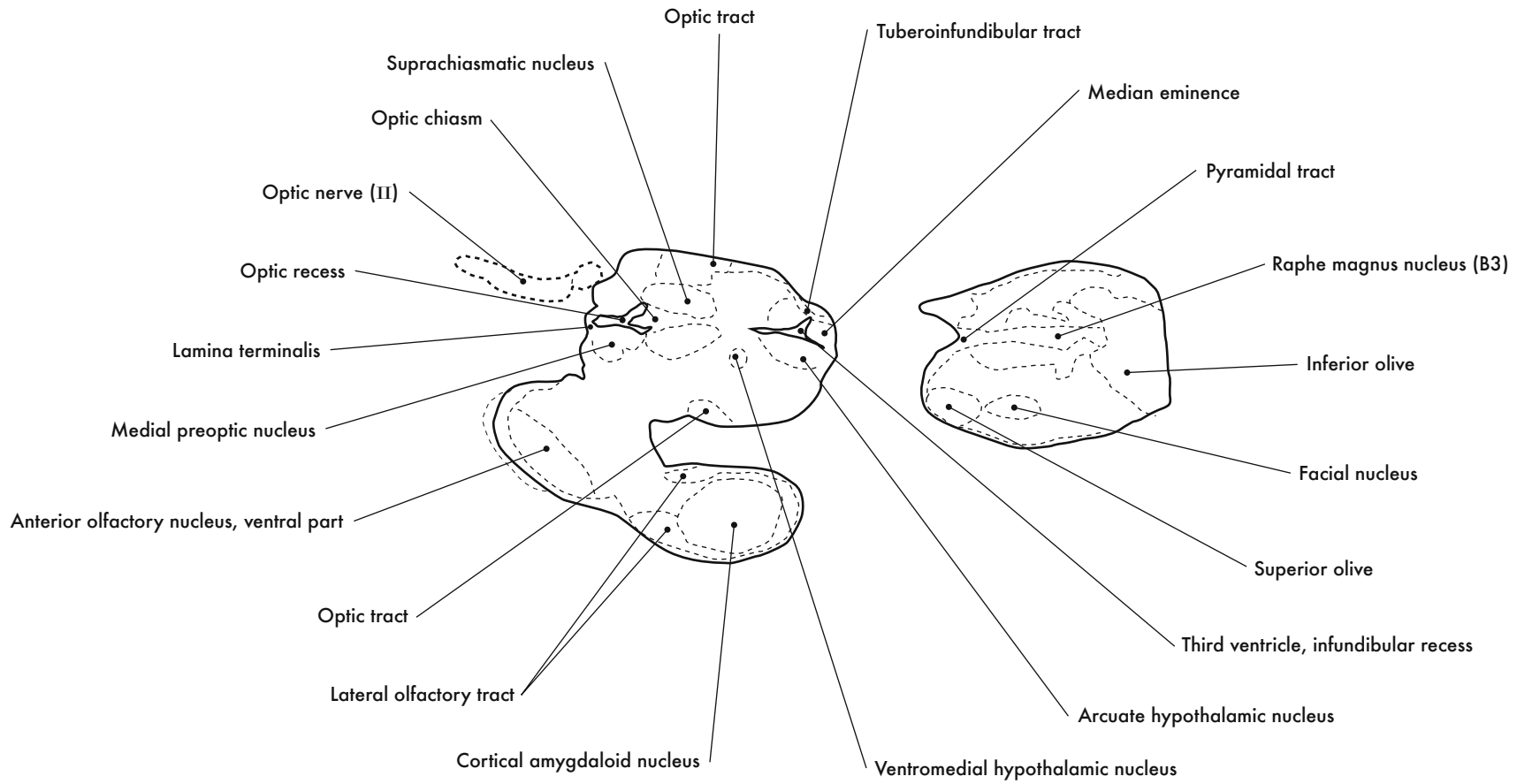
GD 18 HORIZONTAL 13

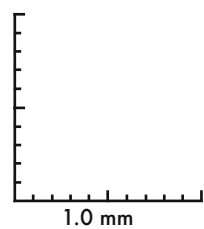
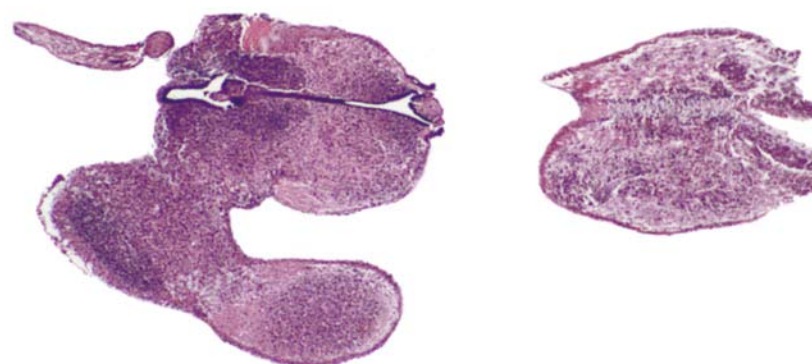







GD 18 HORIZONTAL 14





GD 18 HORIZONTAL 15